

Common complications and their managements after penoscrotal hypospadias repairs: comparison of one-stage and staged repairs

Esra Özçakır[✉], Sefer Tolga Okay[✉], Mete Kaya[✉]

Department of Pediatric Surgery, University of Health Sciences, Bursa Medical Faculty, Bursa, Turkey

ABSTRACT

Objectives: Surgical repair of hypospadias is challenging and the risk of complications is high, even for the most experienced specialists. In this study, we aim to present our experience with the management of the most common postoperative complications in patients who underwent proximal hypospadias repair.

Methods: We retrospectively reviewed the data of patients underwent proximal hypospadias surgery between December 2011 and February 2021. Patients who were repaired with single and staged methods were divided into two groups. Treatment methods of postoperative complications including wound dehiscence, fistula, stricture and diverticulum were examined and the results were noted and statistically compared.

Results: Forty-four patients, with a mean age of 34 months at the first surgery were reviewed, 17 of whom underwent a single-stage repair and 27 of whom staged. Except for a patient who underwent Onlay island flap urethroplasty, long TIPU was used in all single-session repairs, and Byar's and Bracka methods in 19 and 8 patients of the staged group, respectively. The overall complication rate was 34% at a mean follow-up of 41 months, and 18% in single-stage repair, and 44% in staged. Glans dehiscence, urethrocutaneous fistula, urethral stricture, and diverticula were seen 2 (4%), 4 (9%), and 4 (9%), respectively. All glans dehiscence and two fistulae along with distal stricture treated with Mathieu urethroplasty. Two proximal short strictures were relieved by single session dilation. Diverticula were repaired by urethroplasty. The complications were successfully treated, and no recurrence developed.

Conclusions: The risk of complications is higher due to proximal hypospadias, long urethroplasty and defective penile tissue. Hypoplastic glandular urethra, distal stricture and a neourethra devoid of spongiosum appear to be related for complications. Despite the more encountered, postoperative complications of proximal hypospadias repairs have been shown to be successfully treated with the appropriate techniques.

Keywords: proximal hypospadias, postoperative complications, glans dehiscence, urethrocutaneous fistula, urethral diverticulum, urethral stricture

In about 20% of cases with hypospadias, the urethral orifice is proximal, and it is opened anywhere from the penoscrotal region to the perineum [1]. Various techniques have been described to repair proximal hypospadias. Among the most popular are the single-

stage long Snodgras and Duckett's methods as the vascularized preputial island flap technique [2, 3]. As staged technique, Bracka repair consists of a free preputial graft with orthoplasty and urethral bed replacement, and the urethral plate formed from the free

Received: December 6, 2021; Accepted: February 4, 2022; Published Online: March 4, 2022



How to cite this article: Özçakır E, Okay ST, Kaya M. Common complications and their managements after penoscrotal hypospadias repairs: comparison of one-stage and staged repairs. Eur Res J 2022;8(2):256-265. DOI: 10.18621/eurj.938778

Address for correspondence: Mete Kaya, MD., Professor, University of Health Sciences, Bursa Medical Faculty, Department of Pediatric Surgery, 16310, Bursa, Turkey. E-mail: kayamete@hotmail.com, Tel (Mobil): +90 532 590 66 02, Tel (Office): +90 224 295 50 00, Fax: +90 224 295 54 97

©Copyright © 2022 by Prusa Medical Publishing
Available at <http://dergipark.org.tr/eurj>

graft is then tubularized to create the neourethra [4]. The Byars technique involves that vertical incision of the dorsal preputium and translocation of the preputial flaps to the ventral penile surface to provide adequate urethral plate for the subsequent tubularization [5]. In spite of developing techniques, hypospadias is one of the most difficult surgical procedures, and recent publications have shown that the complication rates ranged between 32-68% [6-9]. In addition to the most common complications such as fistula, glans dehiscence (GD), and urethral stenosis, other rare complications such as urethral diverticula, residual ventral penile curvature (VPC), hairy neourethra, and poor cosmetic appearance are encountered in proximal hypospadias repair [6-10]. Current surgical principles have significantly reduced complication rates; however, the knowledge about the management of postoperative complications is limited. In this study, we aim to present the results of our series of proximal hypospadias patients, and the managements of the most common postoperative complications.

METHODS

Following approval by the institutional ethics

board of clinical research, we retrospectively analyzed the patients who underwent penoscrotal hypospadias repair in our clinic between December 2011 and February 2021. Data retrieved from the medical records of our institution included age at first surgery, additional anomalies, the outcomes of hormonal and genetic screen, the number of stages, the type of operations at each stage, the postoperative complications, and the managements and the results of complications which required surgical intervention. All patients whose stages was not completed, less than six months since their last surgery, and sexual development disorders in hormonal and genetic screenings were excluded from the study. Patients were divided into two groups, as single stage repaired and as staged.

Surgical Techniques

The proximal hypospadias was defined exactly during surgery after an artificial erection test. The patients whose meatus opened to the penoscrotal region or more proximal and whose meatus displaced to the penoscrotal region after transection of the urethral plate were considered as proximal hypospadias. Urethroplasty with preserving urethral plate which described by Snodgrass and Prieto [7] (Fig. 1) and the

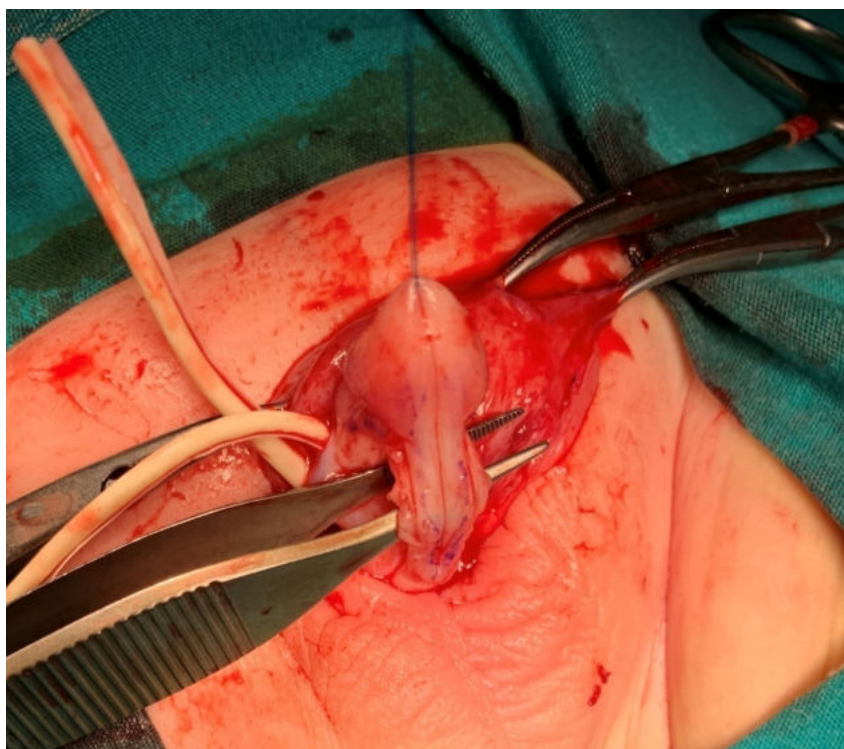


Fig. 1. Photo showing that was sufficiently straightened for urethroplasty by excision of the fibrous chordee on the corpus cavernosum, while preserving the urethral plate.

only island flap urethroplasty were used for single-stage repairs, and preputial flaps (Byar's) or graft (Bracka) methods (Fig. 2) for staged. The selection of repair type was made based on the evaluation of VPC and urethral plate quality during surgery. Whether in single-stage or staged repairs, all tethering fibrous chordee on the corporal bodies from the glans to the proximal normal membranous urethra were excised. If VPC persists more than 30o, it was corrected by the methods of Nesbit or dorsal midline plication. The neo-urethras were covered by dartos flaps prepared from the dorsal preputial tissue. In second stages, urethral plate tubularization (Tiersch-Duplay) were performed with 7/0 polydioxanone suture, by using a continuous subcuticular inverting technique over 6 or 8 Fr catheter (Fig. 3). We left glanuloplasty to the third stage in the patients who have hypoplastic glans and/or required very long urethroplasty. TIP or Mathieu method was performed in the third stage. The dressing and catheters were removed on ambulatory basis at the third and sixth postoperative day, respectively. Suprapubic drainage was not utilized. Staged repairs were performed at intervals of at least six months.

The patients were followed up for 2 weeks, 6 weeks, 3 months, 6 months and then annually to evaluate the outcome of the operation and to control any late complication. The postoperative complications requiring surgical correction were defined such as GD, urethrocutaneous fistula, urethral stricture which could be calibrated less than 6 Fr, residual VPC above 15o after repair, and urethral diverticulum which expanded with urine accumulation during urination.

Management of Postoperative Complications

Glans Dehiscence

All cases with GD were re-operated in single stage. Urethroplasty were performed by using Mathieu method along with deeply dissection of the glans wings.

Urethrocutaneous Fistula

If an urethrocutaneous fistula was encountered, the urethral calibration performed initially to be sure the adequate size of the urethra and to exclude any distal obstruction. Patients who developed fistula and urethral stenosis together underwent urethroplasty

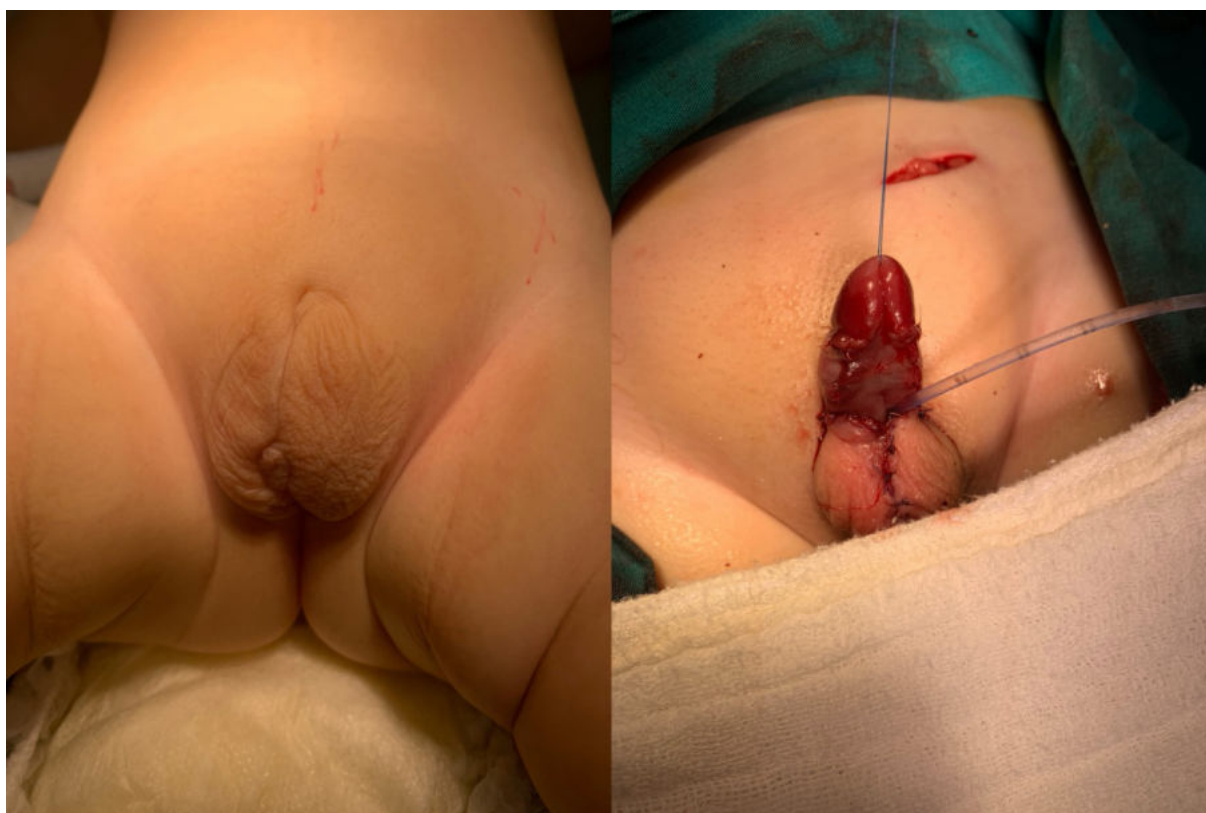


Fig. 2. Urethral plate formations with free preputial graft (Bracka method) along with Glenn-Anderson method in a patient with penoscrotal transposition at the first stage.

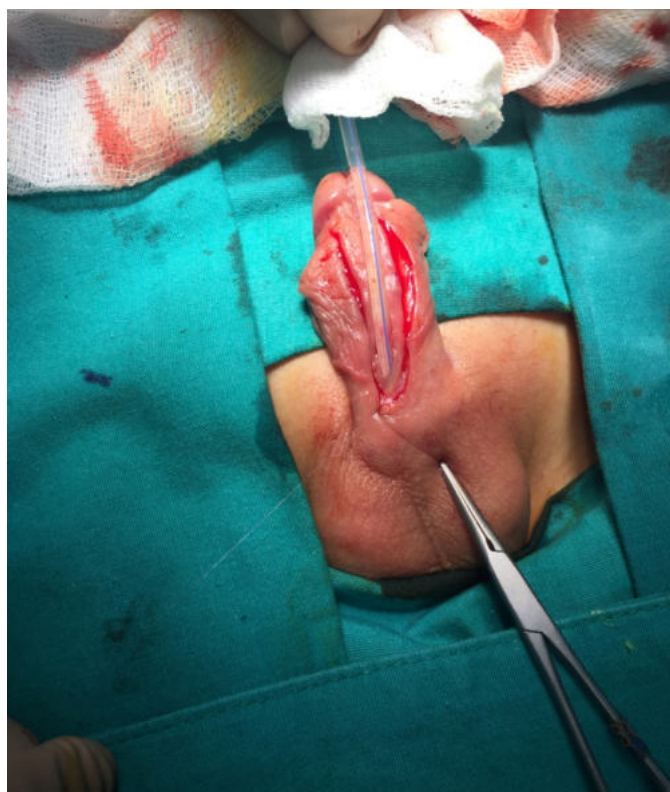

Fig. 3. Uretroplasty in the second stage with the Duplay-Tierisch method

using the Mathieu method. Otherwise the exact location of the fistula was detected by using methylene blue, the orifice of the fistula incised circumferentially and the tract removed. Fistula closure was performed by using subcuticular running suture without tension as to be inverted the epithelial edge into the lumen on transverse plane. A second layer of vascularized local tissue flap (dartos or soft subcutaneous tissue) was interposed over the suture line, and the penile skin sutured with a 7-0 polydioxanone suture in an interrupted vertical mattress closure. The urethral catheter was left in place for 6 days.

Urethral Stricture

The patients presenting with any voiding difficulty or low-calibration voiding, and those with a calibration less than 6F were accepted urethral stricture. To repair for severe distal urethral strictures, re-do urethroplasty performed by using Mathieu method. Visual urethrotomy was not performed, but cystourethroscopy by the 7 and 9 Fr cystoscopes was performed to visualize the neourethra directly and avoid the false passage (Fig. 4). After passing through the stricture by using cystoscope, urethral dilation was

performed by using bougie probes.

Urethral Diverticulum

In patients who developed a urethral diverticulum, presence of distal obstruction, length of the diverticulum and luminal septations of the neourethra was investigated by urethrogram or cystourethroscopy. To restore diverticulated urethra, a ventral midline incision was made on the urethral diverticulum, dilated urethra opened in same fashion, and excessive lateral mucosal walls were removed (Fig. 5). A suitable catheter introduced, urethroplasty carried out by using subcuticular running suture technique accompanied with a second layer covering of subcutaneous tissue or dartos flaps, and skin closed by using interrupted mattress sutures.

Residual Ventral Penile Curvature

Whether the cause of the residual VPC was due to fibrous chordee was investigated by performing artificial erection test. More than 150 degree of VPC at any stage accepted as residual. If the etiology of the VPC considered owing to fibrous chordee, the neourethral plate re-transected just below the glans, all fibrotic tissues removed, a new urethral plate created by using lateral preputial flaps, and partial tubularization performed. Otherwise, dorsal midline plication or Nesbit procedure was done in the patients who have a residual VPC.

Statistical Analysis

Demographic and clinical characteristics of the patients were compared. All statistical analyses were per-

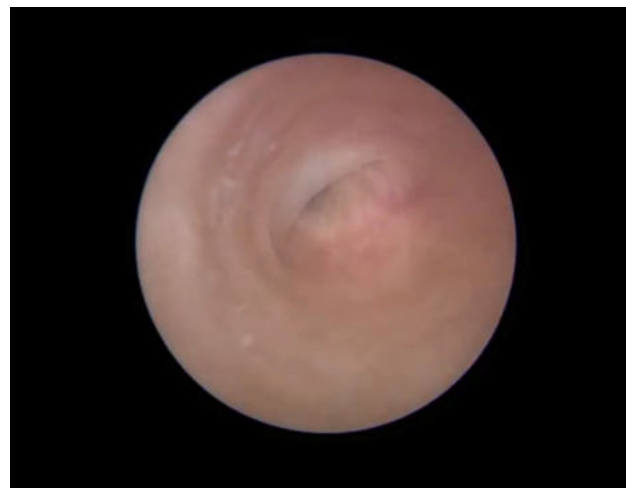

Fig. 4. Stricture in the proximal urethra during urethroscopy

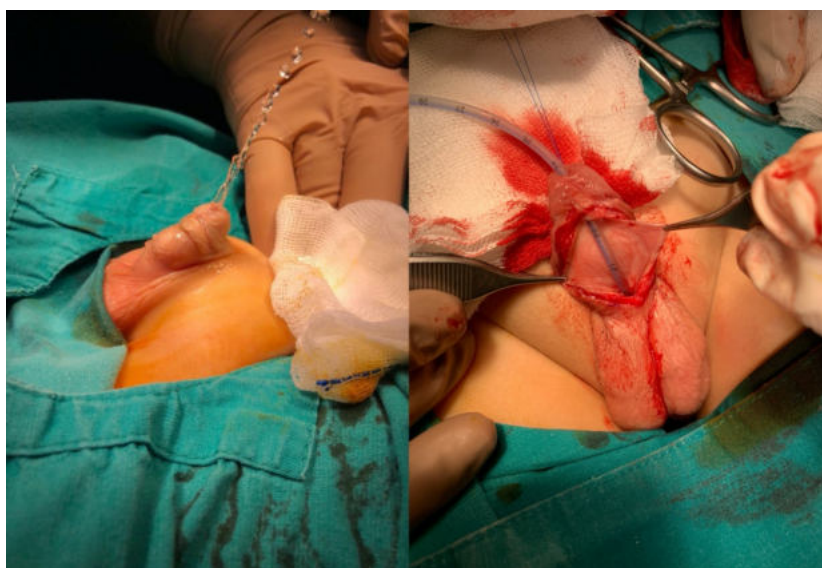


Fig. 5. Urethroplasty in a patient with postoperative urethral diverticulum

formed using the Statistical Package for the Social Sciences (SPSS 21.0; IBM, Armonk, NY). Comparisons between pre- and post-standards subgroups for categorical variables were compared using chi-square test, and using Mann-Whitney U tests for continuous variables. Data were expressed as means, standard deviation, frequency and percentages. Statistical significance was defined as a *p* value of less than 0.05.

RESULTS

Out of 49 patients, 44 who underwent penoscrotal hypospadias operation in our department from December 2010 to February 2020 were included in the study. Demographic, preoperative and operative characteristics of the patients are displayed in Table 1. The mean age at initial surgery was 34 months (range: 5-168

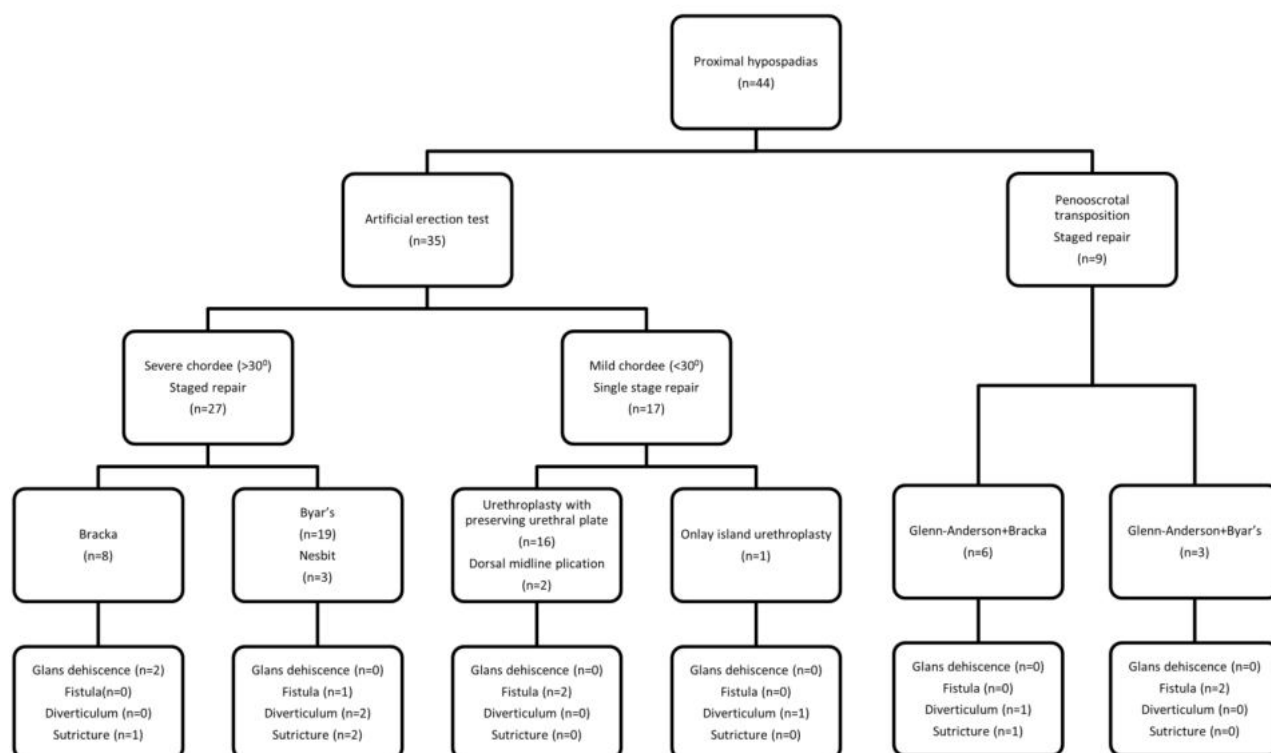


Fig. 6. Flow diagram showing our management and outcomes for 44 patients with proximal hypospadias

months). The mean age of the patients who underwent a single stage was significantly lower than those who underwent staged ones ($p < 0.05$). Our approaches to proximal hypospadias and the complications summarized in simplified flow diagram (Fig. 6). The single stage hypospadias repair was performed in 17 (39%) while a planned staged repair in 27 (61%) patients (Table 2). Preoperative testosterone treatment was not given except one patient with penoscrotal transposition and micropenis.

There was no significant difference between the groups in terms of the presence of additional anomaly ($p > 0.05$). Twenty-two proximal hypospadias cases were accompanied with additional anomaly such as

penoscrotal transposition/bifid scrotum ($n = 9, 21\%$), undescended testicle ($n = 8, 18\%$), inguinal hernia ($n = 4, 9\%$), and imperforate anus ($n = 1, 2\%$).

Urethral plate was preserved in all of the single stage repairs, except one case was underwent with onlay island flap. In the staged group, Byar’s method was applied to 19 patients for first stage, while 8 patients were applied Bracka. An aggressive chordee resection was enough to provide a straight penis in most of patients; a dorsal plication was required in 3 patients in staged group and 2 in single stage. Staged repairs were completed in two stages in 15 patients, and three stages in 12 patients. The planned third stage was carried out by TIPU method in 10 patients and by

Table 1. Patient’s age at first operation, and clinical features of the patients summarized

	Single stage (n = 17)	Staged (n = 27)	Total (n = 44)
Mean age at first surgery (months), mean (min-max)	14 (6-39)	56 (6-168)	34 (5-168)
Additional anomaly, n (%)			
Penoscrotaltransposition	-	9 (33%)	9 (21%)
Undescended testis	1 (6%)	7 (26%)	8 (18%)
Inguinalhernia	2 (12%)	2 (7%)	4 (9%)
Anal atresia	-	1 (4%)	1 (2%)
Total	3 (18%)	19 (70%)	22 (50%)
Chordee, n (%)			
Mild/moderate	15 (88%)	20 (74%)	35 (80%)
Severe	2 (12%)	7 (26%)	9 (20%)

Table 2. Types of operations performed at each stage

	Single stage (n = 17)	Staged (n = 27)
First operation, n (%)		
Urethroplasty preserving urethral plate	16 (94%)	-
Tubularized islang flap	1 (6%)	-
Byar’sfalp	-	19 (70%)
Bracka (preputial graft)	-	8 (30%)
Second operation, n (%)		
Tiersch-Duplay	-	24 (89%)
Mathieu	-	3 (11%)
Planned third operation, n (%)		
TIPU	-	10 (37%)
Mathieu	-	2 (7%)

Mathieu method in 2.

The mean follow up period in our series was 41 months. . There was no significant difference between the groups in terms of the mean follow-up period ($p > 0.05$). All complications are shown in Table 3, the overall complication rate was 34% (15/44 patients), and most of them was in staged group (44%). The most seen complication was urethrocutaneous fistula, (12%). GD, urethral stricture, and diverticulum were occurred 2 (4%), 4 (9%), and 4 (9%), in rates, respectively. In two cases, distal urethral stricture and fistula developed together. Although the number of complications was higher in the staged group, there was no difference between the groups in terms of the total number of complications ($p > 0.05$).

Patients who developed GD were cripple hypospadias that had a failed repair elsewhere and we applied the staged Bracka method. In these patients, the glans hypoplastic and urethral groove was very shallow. They were repaired by performing urethroplasty with the Mathieu method. Any GD did not recur in these patients.

Fistulectomy and multilayer repair were performed in two patients. A meatotomy was performed in the same session with fistula repair in one case. Distal urethroplasty was performed by Mathieu method in two patients of the staged group who developed fistula associated with distal stricture. Neither stricture nor fistula occurred again.

Strictures developed in 4 cases (9%) requiring re-operation, and all of them in staged group. The two had glandular localization that did not allow 6Fr calibrations, and a fistula developed proximally. The entire distal urethra was opened up to the fistula, and the re-urethroplasty was performed by Mathieu method.

Cystourethroscopy revealed proximal anastomotic stenosis at the level of the natural urethra. The 7 and 9 Fr cystoscopes were easily passed through the stricture and expanded with suitable size probes. Strictures were dilated in two times, but not persisted.

Urethral diverticulum occurred in four patients (9%). One of them was in the single stage group which was performed tubularized onlay island flap urethroplasty (6%), and three were in the staged group (11%), one underwent Bracka method, and two Byar's. Urethrography and cystourethroscopy revealed no distal stricture, but we noticed the very stiff glandular urethra. Diverticulum was successfully excised and urethroplasty was completed by performing a tight tubularization. There was occurred no postoperative recurrence or any other complication.

No residual VPC was observed in any patient in this series, with the exception of one patient who detected a residual fibrous chordee in the second stage. In this patient, more than 30o of VPC still remained, the neourethral plate was re-transected just below the glans, a dorsal plication was performed after all fibrotic tissues removing, urethral plate re-formed by using lateral preputial flaps.

DISCUSSION

In present series, overall complication rate for 44 patients was 34% at mean 41 months follow-up period. Since we prefer single-stage repair in the patients who have better penile development and less VPC, we believe that we achieve better results in these patients than in the staged group. A linear relationship has been found between hypospadias severity and complications regardless of the type of repair, therefore it is ob-

Table 3. Complications which required surgical intervention

	Single stage (n = 17)	Staged (n = 27)	Total (n = 44)
Mean follow-up (months), mean (range)	44 (6-107)	39 (6-96)	41 (6-107)
Complications (treatment), n (%)			
Dehiscence (Mathieu [n = 2])	-	2 (7%)	2 (4%)
Fistula (Mathieu [n = 2], multilayer repair [n = 3])	2 (12%)	3 (11%)	5 (12%)
Urethral stricture (Mathieu [n =2], dilation [n = 2])	-	4 (15%)	4 (9%)
Diverticulum (urethroplasty [n=4])	1 (6%)	3 (11%)	4 (9%)
Total	3 (18%)	12 (44%)	15 (34%)

vious that a repair of proximal hypospadias may result in increased risk of complications caused by the defective penile tissues [11, 12]. However, the most post-operative complications are related to the techniques, the surgeon's experience, and the underlying anatomical abnormalities [13]. Recently, it has also been reported the greater likelihood of complications in hypospadias patients with congenital anomalies suggests that the complications may partly to be have a biological basis [14]. Although not statistically large enough to compare, the most of the patients who occurred a complication in our series had an accompanied genital anomaly.

In our series, GD developed in two cases that were cripple hypospadias, and have not enough glans wings for urethroplasty (4%). It has been reported that the risk factors of GD include proximal hypospadias, re-operations and the host's wound healing ability [15, 16]. The width of the urethral plate, the size of the glans, and the depth of the groove has been also suggested to be other predisposing factors. Various staged inlay mucosal graft techniques have been reported to reduce the risk of GD in cases [16, 17]. Snodgrass and Bush [18] have stated that additional dissection of the glandular wings from the urethral plate reduces the approximation tension and GD. White and Hanna [16] have also suggested that a grooveless glans penis should be converted to a deep grooved plate to prevent recurrent GD. Although it has been suggested that pre-operative testosterone therapy may decrease the risk of GD by increasing the glans size, there is insufficient randomized data to prove this theory [15]. In order to prevent GD formation, we postponed glanuloplasty to the third stage in case of narrow grooved and hypoplastic glans. Two of our cases who developed GD were cripple, and a forced glanuloplasty performed at former stage. However, these cases were successfully repaired using the Mathieu method.

Urethrocutaneous fistula is one of the most common complications encountered after hypospadias repair, with rates up to 55% [13, 19]. In the presented series, it was found that the total incidence of fistula was 12%. Interposition of tissue flaps such as buccal mucosa, tunica vaginalis flaps, dartos flaps, spongy tissue, external spermatic fascia, adipose tissue and spermatic cord between layers has been reported to be important in reducing fistula formation [20-22]. Additionally, it has also been suggested that there are

many factors affecting fistula development, such as distal obstruction, diverticulum, repair under magnification, stent use, suture technique, and tension in the suture line [19, 23]. While simple closure techniques are sufficient in small fistulas, it has been suggested that if local tissue cannot be used due to severe scar formation, mucosal grafts are a reliable option for repairing large urethrocutaneous fistulas [22, 23]. The success rate of first simple closure of fistula after hypospadias surgery is over 90% [13, 23]. Large fistula was not developed in our series, small fistulas repaired in three layers. We believe that subcuticular closure of the urethral lumen without tension also affects success in fistula repair. It is well known that simple closure may cause recurrence in the presence of fistula with distal stricture. In two patients who developed fistula associated with distal glandular stricture, we performed urethroplasty with Mathieu method instead of fistula repair. No recurrence was observed in any patient during the follow-up period.

Urethral stricture is the second most common complications of hypospadias surgery. It has been reported that 7-12% urethral stricture develops after hypospadias repairs, in which most of them used graft or flap for repair [7, 8, 24]. Devascularization is always a possible risk when pedicled flaps are used, which can cause scarring and urethral stricture [25]. Our practices include the formation wide enough for urethral plate, the tubularization with appropriate calibration, and the repair in 3 stages instead of 2 in the patients with requiring long urethroplasty. Notwithstanding, a stricture requiring intervention was occurred in our four cases (9%), and all of them in staged group. There were typically two different localizations of the strictures which are at the border of native urethra in two patients, and at the glandular urethra in others. Possible reasons of strictures were that circular anastomosis in the first one, and that hypoplastic glans in the next. The traditional treatment of the urethral strictures has always begun with dilation or visual urethrotomy, but it has been suggested that dilations have no role in the management of urethral structures in children [24]. Nevertheless, dilation was found successful for short proximal anastomotic strictures in our series. We think that anastomotic strictures respond to dilation due to its short and ring-like nature. Although we have not used, the success of urethrotomy in the literature ranges from 0 to 72% regardless of the type

of hypospadias, used tissue, and the method of urethroplasty, however, early urethroplasty recommended in those who do not respond to urethrotomy once [26, 27]. Dilatation was not attempted in two patients who developed glandular stricture along with fistula, and re-do urethroplasty was performed by Mathieu method.

It has been reported that the incidence of diverticulum formation after hypospadias repair is 7-23%, and the most of them has been seen especially in the patients who have a perineal/proximal defect [7, 13, 28]. It has been suggested that diverticulum formation is associated with distal stenosis and flap / graft use (e.g., preputial, buccal or bladder mucosa) [29-31]. In addition other factors such as excessive use of plate for long tubularization, urine flow with high pressure and artificial thick urethral plate are associated with diverticulum formation. Diverticulum developed in 4 (9%) of our patients. The glandular urethra was normally calibrated in these cases, but it was too tight. There is no standard approach for the treatment of urethral diverticulum. Snyder *et al.* [13] have reported that if there is no other complication, simple partial excision with multi-layer closure is sufficient for diverticulum repair. If there are other complications such as stricture or fistula, other techniques such as 'pants over vest' closure could be applied. In our cases, simple closure of the diverticulum was easily performed and no recurrence occurred. However, it cannot be guaranteed that the distal stiffy glans will not cause re-expansion of the urethra, which is deprived of spongy tissue at an older age.

Snodgrass and Bush [32] have proposed that residual VPC was detected in 83% of patients who presented with complications after hypospadias surgery. Many techniques have been described to correct penile curvature. Dorsal plication performed easily and produces reliable straight erection. However, recently, the results show that this process is not durable to severe VPC [32]. The excision of the dysplastic ventral chordee with or without transecting the urethral plate is the second most common method for VPC correction [33]. Additionally, ventral lengthening with serial corporotomies with or without grafts is rarely used [32]. In our series, adequate excision of ventral fibrous cords was sufficient for VPC correction in most patients, five patients required dorsal plication, and no

residual VPC was detected.

Limitations

The limitations of this study are that it is retrospective and relatively few cases. In addition, our study does not include the effects on hairy urethra, psychological problems and sexual function and the results of operations that may be encountered in the long term.

CONCLUSION

In conclusion, proximal hypospadias has a higher risk for complications due to long urethroplasty and defective penile tissue. Complications are thought to be related to each other, such as narrow glandular plate-GD, fistula-distal stricture and diverticulum-stiffy glandular urethra. Despite the high rates, post-operative complications of proximal hypospadias repairs have been shown to be successfully treated with the appropriate techniques.

Ethics approval and consent to participate

All procedures performed in this retrospective study and data analysis were in accordance with the ethical standards of our IRB (Bursa Yuksek Ihtisas Training and Research Hospital Ethical Committee) with approval reference number of 2011-KAEK-25 2020/03-19, dated 18.03.2020. The IRB waived the need for informed consent for this retrospective study.

Authors' Contribution

Study Conception: EO, STO, MK; Study Design: EO, MK; Supervision: MK; Funding: N/A; Materials: EO, STO, MK; Data Collection and/or Processing: EO, STO, MK; Statistical Analysis and/or Data Interpretation: EO, MK; Literature Review: EO, MK; Manuscript Preparation: EO, MK and Critical Review: MK.

Conflict of interest

The authors disclosed no conflict of interest during the preparation or publication of this manuscript.

Financing

The authors disclosed that they did not receive any

grant during conduction or writing of this study.

REFERENCES

- Cilento BG Jr, Atala A. Proximal hypospadias. *Urol Clin North Am* 2002;29:311-28.
- Snodgrass W, Prieto J. Straightening ventral curvature while preserving the urethral plate in proximal hypospadias repair. *J Urol* 2009;182:1720-5.
- Duckett JW. Transverse preputial island flap technique for repair of severe hypospadias. *Urol Clin N Am* 1980;7:423-30.
- Byars, L.T. Functional restoration of hypospadias deformities. *Surg Gynaecol Obstet.* 1951;92:149-54.
- Bracka A. A versatile two-stage hypospadias repair. *Br J Plastic Surg.* 1995;345-52.
- Stanasel I, Le HK, Bilgutay A, Roth DR, Gonzales ET Jr, Janzen N, et al. Complications following staged hypospadias repair using transposed preputial skin flaps. *J Urol* 2015;194:512-6.
- McNamara ER, Schaeffer AJ, Logvinenko T, Seager C, Rosoklija I, Nelson CP, et al. Management of proximal hypospadias with 2-stage repair: 20-year experience. *J Urol* 2015;194:1080-5.
- Pippi Salle JL, Sayed S, Salle A, Bagli D, Farhat W, Koyle M, et al. Proximal hypospadias: A persistent challenge. Single institution outcome analysis of three surgical techniques over a 10-year period. *J Pediatr Urol* 2016;12:28.e1-7.
- Long CJ, Chu DI, Tenney RW, Morris AR, Weiss DA, Shukla AR, et al. Intermediate-term followup of proximal hypospadias repair reveals high complication rate. *J Urol* 2017;197:852-8.
- Retik AB, Atala A. Complications of hypospadias repair. *Urol Clin North Am* 2002;29:329-39.
- Merriman LS, Arlen AM, Broecker BH, Smith EA, Kirsch AJ, Elmore JM. The GMS hypospadias score: assessment of inter-observer reliability and correlation with post-operative complications. *J Pediatr Urol* 2013;9:707-12.
- van der Horst HJ, de Wall LL. Hypospadias, all there is to know. *Eur J Pediatr* 2017;176:435-41.
- Snyder CL, Evangelidis A, Hansen G, St Peter SD, Ostlie DJ, Gatti JM, et al. Management of complications after hypospadias repair. *Urology* 2005;65:782-5.
- Al-Juraibah F, Lucas-Herald A, Nixon R, Toka C, Wang C, Flett M, et al. Association between extra-genital congenital anomalies and hypospadias outcome. *Sex Dev* 2019;13:67-73.
- Snodgrass W, Cost N, Nakonezny PA, Bush N. Analysis of risk factors for glans dehiscence after tubularized incised plate hypospadias repair. *J Urol* 2011;185:1845-9.
- White CM, Hanna MK. Salvaging the dehisced glans penis. *J Pediatr Urol* 2018;14:422.e1-5.
- Kolon TF, Gonzales ET Jr. The dorsal inlay graft for hypospadias repair. *J Urol* 2000;163:1941-3.
- Snodgrass WT, Bush NC. Surgical complications of hypospadias and their management. In: Godbole PP, Koyle MA, Wilcox DT, editors. *Pediatric urology: surgical complications and management.* Hoboken: Wiley-Blackwell; 2015. p. 259-69.
- Richter F, Pinto PA, Stock JA, Hanna MK. Management of recurrent urethral fistulas after hypospadias repair. *Urology* 2003;61:448-51.
- Fahmy O, Khairul-Asri MG, Schwentner C, Schubert T, Stenzl A, Zahran MH, et al. Algorithm for optimal urethral coverage in hypospadias and fistula repair: a systematic review. *Eur Urol* 2016;70:293-8.
- Seo S, Ochi T, Yazaki Y, Okawada M, Doi T, Miyano G, et al. Soft tissue interposition is effective for protecting the neourethra during hypospadias surgery and preventing postoperative urethrocutaneous fistula: a single surgeon's experience of 243 cases. *Pediatr Surg Int* 2015;31:297-303.
- Kiss A, Pirót L, Karsza L, Merksz M. Use of buccal mucosa patch graft for recurrent large urethrocutaneous fistula after hypospadias repair. *Urol Int* 2004;72:329-31.
- Elbakry A. Management of urethrocutaneous fistula after hypospadias repair: 10 years' experience. *BJU Int* 2001;88:590-5.
- Snodgrass WT, Bush NC. Management of urethral strictures after hypospadias repair. *Urol Clin North Am* 2017;44:105-11.
- Malone P. Meatal stenosis and urethral strictures after hypospadias surgery. In: Hadidi AT, Azmy AF (eds.). *Hypospadias Surgery.* Berlin: Springer; 2004. p. 295-300.
- Gargollo PC, Cai AW, Borer JG, Retik AB. Management of recurrent urethral strictures after hypospadias repair: is there a role for repeat dilation or endoscopic incision? *J Pediatr Urol* 2011;7:34-8.
- Husmann DA, Rathbun SR. Long-term followup of visual internal urethrotomy for management of short [less than 1 cm] penile urethral strictures following hypospadias repair. *J Urol* 2006;176:1738-41.
- Radojicic ZI, Perovic SV, Djordjevic ML, Vukadinovic VM, Djakovic N. Pseudospongiosoplasty' in the repair of a urethral diverticulum. *BJU Int* 2004;94:126-30.
- Hueber PA, Salgado Diaz M, Chaussy Y, Franc-Guimond J, Barrieras D, Houle AM. Long-term functional outcomes after penoscrotal hypospadias repair: a retrospective comparative study of proximal TIP, Onlay, and Duckett. *J Pediatr Urol* 2016;12:198.e1-6.
- Vallasciani S, Berrettini A, Nanni L, Manzoni G, Marrocco G. Observational retrospective study on acquired megalourethra after primary proximal hypospadias repair and its recurrence after tapering. *J Pediatr Urol* 2013;9:364-7.
- Snyder CL, Evangelidis A, Snyder RP, Ostlie DJ, Gatti JM, Murphy JP. Management of urethral diverticulum complicating hypospadias repair. *J Pediatr Urol* 2005;1:81-3.
- Snodgrass W, Bush NC. Persistent or recurrent ventral curvature after failed proximal hypospadias repair. *J Pediatr Urol* 2019;15:344.e1-6.
- Palmer LS, Palmer JS, Franco I, Friedman SC, Kolligian ME, Gill B, et al. The "long Snodgrass": applying the tubularized incised plate urethroplasty to penoscrotal hypospadias in 1-stage or 2-stage repairs. *J Urol* 2002;168:1748-9.



This is an open access article distributed under the terms of Creative Commons Attribution-NonCommercial-NoDerivatives 4.0 International License.