



## The Effects of Cryopreserved Human Amniotic Membrane and Platelet-Rich Plasma on Seroma Development after Mastectomy and Axillary Dissection in Rats

Sıçanlarda Mastektomi ve Aksiller Diseksiyon Sonrası Seroma Gelişimi Üzerine Kriyoprezerve İnsan Amniyotik Membran ve Trombositten Zengin Plazmanın Etkileri

Muhammed GÖMEÇ<sup>1</sup>

 0000-0002-9127-3201

Mustafa ÖZKARACA<sup>2</sup>

 0000-0002-6359-6249

<sup>1</sup>Department of General Surgery,  
Cumhuriyet University Faculty of  
Medicine, Sivas, Turkey

<sup>2</sup>Department of Pathology, Cumhuriyet  
University Faculty of Veterinary,  
Sivas, Turkey

### ABSTRACT

**Aim:** Seroma is one of the most common complications after mastectomy and axillary dissection. It occurs as a result of prolongation of the exudative-inflammatory phase of wound healing. The aim of this study is to evaluate the effects of human amniotic membrane (HAM) and platelet-rich plasma (PRP) on seroma formation.

**Material and Methods:** A total of 24 rats were grouped as control, PRP, and HAM groups. All rats underwent radical mastectomy and axillary lymph node dissection. Saline in the control group, PRP in the second group, and HAM in the third group were applied to the dissection area. The groups were compared in terms of the condition of the surgical field, seroma volume, and histopathological changes.

**Results:** Seroma volume decreased in the PRP group, but not in the HAM group. Lymphocyte, eosinophil, histiocyte, and fibroblast levels were significantly lower both in the PRP and HAM groups compared to the control group. E-cadherin and TGF- $\beta$ 1 immunoreactivities of PRP and HAM groups were higher than in the control group.

**Conclusion:** In this study, it was observed that PRP and cryopreserved HAM increased tissue healing and decreased the inflammatory process. However, although local PRP application significantly reduced seroma formation, it was determined that HAM application did not reduce seroma formation. It was thought that this might be due to the fact that the smooth surface of HAM mechanically prevents the adhesion of the tissues. More beneficial results will be obtained with the modification to be made in the preparation and application of HAM.

**Keywords:** Axillary dissection; human amniotic membrane; mastectomy; platelet-rich plasma; seroma.

### ÖZ

**Amaç:** Seroma, mastektomi ve aksiller lenf nodu diseksiyonu sonrası en sık görülen komplikasyonlardan bir tanesidir. Yara iyileşmesinin eksüdatif ve inflamatuvar fazının uzamasının bir sonucu olarak ortaya çıkar. Bu çalışmanın amacı, insan amniyotik membran (human amniotic membrane, HAM) ve trombosit zengin plazma (platelet-rich plasma, PRP)'nin seroma oluşumu üzerindeki etkilerini değerlendirmektir.

**Gereç ve Yöntemler:** Toplam 24 adet sıçan kontrol, PRP ve HAM grubu olarak gruplara ayrıldı. Tüm sıçanlara radikal mastektomi ve aksiller lenf nodu diseksiyonu yapıldı. Diseksiyon bölgesine kontrol grubunda salin, ikinci grupta PRP ve üçüncü grupta ise HAM uygulandı. Tüm gruplar cerrahi alanın durumu, seroma hacmi ve histopatolojik değişiklikler açısından karşılaştırıldı.

**Bulgular:** PRP grubunda seroma hacminde azalma görüldü, ancak HAM grubunda azalma gözlenmedi. Hem PRP hem de HAM grubunda lenfosit, eozinofil, histiyosit ve fibroblast seviyeleri kontrol grubuna göre anlamlı derecede daha düşük olduğu tespit edildi. PRP ve HAM gruplarının E-cadherin ve TGF- $\beta$ 1 immünreaktivitelerinin de kontrol grubuna göre daha yüksek olduğu tespit edildi.

**Sonuç:** Bu çalışmada PRP ve kriyoprezerve HAM'ın doku iyileşmesini arttırdığı ve inflamatuvar süreci azalttığı gözlemlendi. Ancak lokal PRP uygulanması seroma oluşumunu önemli ölçüde azaltsa da lokal HAM uygulamasının seroma oluşumunu azaltmadığı belirlendi. Bunun HAM'ın pürüzsüz yüzeyinin mekanik olarak dokuların yapışmasını engellemesinden kaynaklanabileceği düşünüldü. HAM'ın hazırlanmasında ve uygulanmasında yapılacak olan modifikasyon ile daha faydalı sonuçlar elde edilecektir.

**Anahtar kelimeler:** Aksiller diseksiyon; insan amniyotik membran; mastektomi; trombosit zengin plazma; seroma.

### Corresponding Author

#### Sorumlu Yazar

Muhammed GÖMEÇ

muhammedgomec@cumhuriyet.edu.tr

Received / Geliş Tarihi : 14.01.2022

Accepted / Kabul Tarihi : 07.04.2022

Available Online /

Çevrimiçi Yayın Tarihi : 17.04.2022

## INTRODUCTION

Breast cancer is the most common malignancy among women worldwide and a leading cause of cancer-related death (1). Since the first radical mastectomy (RM) by William Halsted in 1894, surgical techniques have improved significantly, providing patients with exceptional survival rates. Seroma is one of the most common complications after breast cancer surgery (2). Its incidence varies between 10% to 52% (3). It usually regresses within a few weeks. However, in some patient groups, this process may take several months (2-4). In addition to RM and modified radical mastectomy (MRM) surgical procedures, performing axillary lymph node dissection (ALND) increases the likelihood of seroma formation. It has also been reported in more minor surgical techniques such as sentinel lymph node biopsy (SLNB), breast-conserving surgery, and subcutaneous mastectomy/nipple-sparing surgery (5).

The RM experimental animal model is a suitable model to evaluate the acute response and wound healing after the surgical procedure (6). During the mastectomy and ALND procedure, a large surgical area is formed, resulting in damage to many blood vessels and lymphatic structures. As a result of these damages, seroma is formed accompanied by blood and lymphatic leakage. It is stated that this fluid is an exudate containing cellular components of acute inflammation (7). In the study by McCaul et al. (3), it was reported that the fluid accumulated after breast cancer surgery was caused by the prolongation of the exudative-inflammatory phase of wound healing. In a study by Watt-Boolsen et al. (7), it was reported that seroma may be an indicator of prolongation of the first phase of wound healing.

Human amniotic membrane (HAM) is a medical biomaterial that has been used for a long time in corneal reconstruction, ocular surface injuries, skin burns, tissue fillings, and neural tube defect operations (8,9). It has been reported that HAM is valuable in clinical applications due to its beneficial functional properties that can facilitate biological activities without causing ethical debates regarding the use of human tissue (10). HAM has non-tumorigenic, low immunogenicity, antibacterial, antiviral and anti-inflammatory effects. It also secretes various active factors such as transforming growth factor-1 $\beta$  (TGF-1 $\beta$ ), epidermal growth factor, stromal cell-derived factor, vascular endothelial growth factor, and polymorphic collagen (11).

Platelet-rich plasma (PRP), which is a plasma portion 3-5 times richer than normal plasma levels in terms of platelets, at high concentrations; growth factors such as vascular endothelial growth factor (VEGF), platelet derived growth factor (PDGF), insulin-like growth factor (IGF), TGF-1 $\beta$  and fibrinogen, fibronectin, osteonectin, osteocalcin, vitronectin, thrombospondin certain proteins and peptides such as (12). For this reason, it has been used in many studies in terms of wound healing.

Tissue healing is a complex process involving many factors such as cytokines and growth factors (11). Exogenous cytokines are used in clinics to promote healing. These products usually use some type of growth factor, thus contributing to one stage of wound healing. However, it is known that more than one factor combination may be more effective in wound healing.

It is known that HAM and PRP contribute to wound healing by many factors and many pathways. Therefore, it is predicted that it may have positive effects on the healing of the flap created during mastectomy and the seroma, which is considered as a complication. The aim of this study is to examine the effects of local application of HAM and PRP as a biological material on seroma and wound healing after mastectomy and ALND.

## MATERIAL AND METHODS

### Animals

This experimental study was approved by Sivas Cumhuriyet University Animal Experiments Local Ethics Committee on 14.11.2020 with the number 367. All institutional and national guidelines for the care and use of laboratory animals were followed.

A total of 24 rats were divided into three groups; Control group (n=8), PRP application group (n=8), and HAM application group (n=8). In addition, 4 rats were used to obtain PRP.

### Supply and Preparation of Cryopreserved Human Amniotic Membrane (HAM)

Placenta was obtained after elective cesarean section (38 weeks) from the patient who had negative HBV, HCV, HIV, and syphilis tests and had no history of premature rupture of membranes, endometritis, or meconium ileus. The placenta was transferred to the laboratory at +4°C in a container under sterile conditions. The placenta with adherent fetal membranes was washed with Phosphate Buffer Saline (PBS) containing 50  $\mu$ g/ml penicillin, 50  $\mu$ g/ml streptomycin and 2.5  $\mu$ g/ml amphotericin B. The amnion was separated from the chorion by blunt and sharp dissection under sterile conditions in the processing area. HAM was washed several times with PBS. It was then laid on a nitrocellulose membrane (Whatman, Schleicher, and Schuell optitaran BA-S 85) with the epithelial surface facing up. Cryo tubes in which Dulbecco's Modified Eagle's Medium (DMEM) solution and glycerol solution were prepared in equal proportions were prepared. Prepared nitrocellulose papers were washed for the last time with PBS, cut into required sizes, and placed in cryo tubes. The tubes were placed in a -80°C cabinet. It was removed 24 hours before the procedure and kept at room temperature. It was removed from the tube during the operation and placed in physiological saline. The HAM was separated from the nitrocellulose paper with the help of forceps in SF and made ready for use in the appropriate size for the dissection area.

### Platelet Rich Plasma (PRP) Supply and Preparation

Venous blood was collected from donor rats (n=4) prepared to obtain PRP, placed in tubes containing 3.2% sodium citrate, and the supernatant was obtained by centrifugation at 400 G for 10 minutes. The collected supernatant was re-centrifuged at 800 G for 10 minutes. After centrifugation, the upper two-thirds of plasma was discarded, and the lower third was laboratory-confirmed as PRP. The obtained PRP was used in the study without waiting.

### Study Design and Surgical Procedure

The experimental study was carried out in the Experimental Animals Laboratory of the same center with the approval of the Animal Experiments Local Ethics

Committee of Sivas Cumhuriyet University, Faculty of Medicine, Experimental Medicine Research and Application Center. Before and after the experiment, the subjects were housed in detached cages of equal size and fed with standard feed and tap water. Rats were kept in a sound-insulated room with a 12-hour light/dark cycle at a room temperature of  $22\pm 1^{\circ}\text{C}$  and in a  $55\pm 6\%$  humidity environment and fed at an appropriate rate. The experiment was carried out between 9:00 and 16:00, and the light and sound levels of the experimental environment were kept under constant control. Rats were fasted at least 6 hours before the procedure. Anesthesia was administered with Xylazine HCL 3 mg/kg and Ketamine 90 mg/kg intraperitoneally. A total of 24 rats were randomly divided into 3 groups of 8 each. **Control Group:** After RM and ALND, primary closure was performed by washing with 1 cc saline. **PRP Group:** Before primary closure after RM and ALND, 0.5 ml of PRP prepared locally under the flap and in the axillary space was applied and the skin was closed by primary suturing. **HAM Group:** After RM and ALND, the HAM prepared under the flap was laid as a single layer before primary closure and the skin was closed with a primary suture (Figure 1). The mean dissection area was 3 cm<sup>2</sup>. Rats were not treated with antibiotics. Experimental animals were kept in the laboratory for 7 days after (13) surgery and were followed during the observation period to record the presence of infection, seroma, or abscess. On the 7<sup>th</sup> postoperative day after anesthesia, the seroma formed in the wounds of the patients was aspirated with injectors and the amount of seroma obtained was recorded as milliliters. Wound sites were evaluated in terms of wound infection and wound healing amount. In the evaluation of wound infection, it was investigated whether there was hyperemia, necrosis, temperature increase, and discharge at the wound site. After the evaluation of the subjects was completed, the subjects were sacrificed with 200 mg/kg pentothal. Tissue samples were taken for pathological examination.

#### Histopathological Method

Necropsies of the rats were made and the tissues taken were fixed in a 10% neutral formalin solution. Tissues were taken into paraffin blocks after routine alcohol-xytol follow-up procedures. Sections of 4  $\mu\text{m}$  taken from the tissues were stained with hematoxylin-eosin. The studies of Calisir et al. (14) were analyzed according to the modification of histopathological scoring (Table 1).

#### Immunohistochemical Study

4  $\mu\text{m}$  sections taken on slides containing polylysine were passed through the xytol and alcohol series, after washing with PBS, they were kept in 3% H<sub>2</sub>O<sub>2</sub> for 10 minutes to inactivate endogenous peroxidase. In order to reveal the antigen in the tissues, they were treated with antigen retrieval solution for 2x5 minutes at 500 watts. It was then incubated with primary antibodies of E-cadherin (Santa Cruz, Cat. No. sc-8426) and TGF $\beta$ 1 (Santa Cruz, Cat. No. sc-130348) (dilution 1/200) at room temperature for 45 min. left for incubation. Secondly; Large Volume Detection System: anti-Polyvalent, HRP (Thermofischer, Catalog no: TP-125-HL) was applied as recommended by the manufacturer. DAB (3,3'-Diaminobenzidine) was used as chromogen. After counterstaining with Mayer's Hematoxylin, it was covered with entellan and examined under a light microscope. In the examination, it was

evaluated as no immunoreactivity (0), mild (1), moderate (2), severe (3), and very severe (4).

#### Statistical Analysis

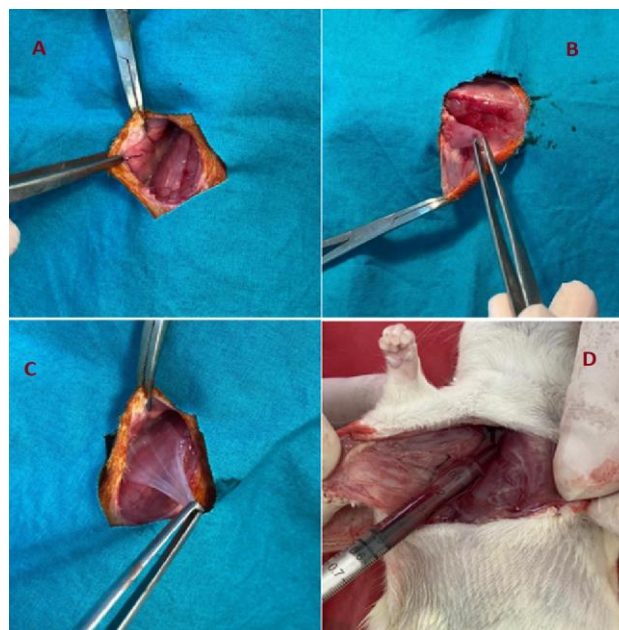
All of the data obtained as a result of the experiments were converted into numerical values. SPSS program (SPSS v.20.0 for windows) was used for statistical analysis. All experimental results were expressed as median, interquartile range, and minimum-maximum. In the histopathological examination, the difference between the groups of the data obtained semi-quantitatively was determined by the Kruskal-Wallis H test, and the determination of the groups forming the difference was determined by the Mann-Whitney U test with Bonferroni correction ( $p\cong 0.017$ ). Statistical significance was defined at the  $p < 0.05$  level.

#### RESULTS

Subjects were followed up for 7 days for complications after RM and ALND. At the end of the seventh day, all subjects were reevaluated and all groups were sacrificed. The macroscopic appearance of the surgical field and seroma volume were recorded and histopathological samples were taken from the tissues.

#### Macroscopic Assessment

The rats were followed throughout the experiment and the final evaluation was made on the 7<sup>th</sup> day. Wound infection was detected macroscopically in 2 subjects in the control



**Figure 1.** A) tissue dissection in mastectomy; B) pectoralis major muscle dissection for radical mastectomy; C) applying human amniotic membrane to the dissection area; D) seroma measurement 1 week after radical mastectomy

**Table 1.** Histological scoring criteria

Pathological State	Score	Definition
Lymphocytes,	0	Intact
Eosinophils,	1	A small amount and scattered
Histiocytes,	2	A small amount and all areas
Fibroblasts	3	There are a lot and scattered
	4	There are a lot and all area



group and in 1 subject in the PRP group. However, wound infection was not observed in any of the subjects in the HAM group. No flap necrosis or wound dehiscence was observed in any rat. There were changes in the surgical field consistent with seroma deposition.

**Seroma Volume**

Measurements of the amount of seroma formed were made by the same author. The amount of seroma formed was measured. An average of 3.5 ml of seroma was accumulated in the control group, 0.5 ml in the PRP group, and 4 ml in the HAM group (p=0.021, Figure 2). It was observed that less seroma occurred in the PRP group compared to the control group (p=0.015). The seroma formation in the HAM group was higher than in the control group (p=0.023).

**Histopathologic Assessment**

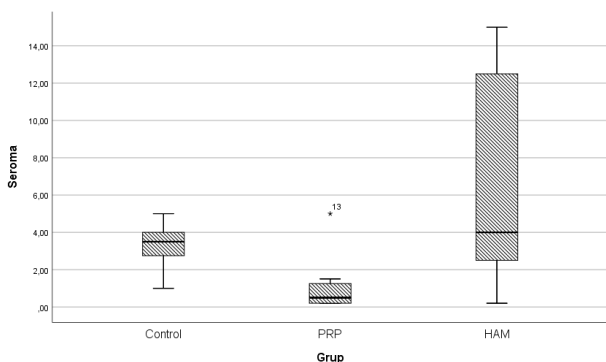
A statistically significant difference was found between the groups (Table 2, Figure 3). While lymphocyte, eosinophil, histiocyte, and fibroblast activity were moderate and severe in the control group, it was observed that the number of these cells decreased in the PRP and HAM groups (p<0.001, p=0.002, p<0.001, p<0.001, respectively).

**Immunohistochemical Findings**

Statistically significant differences were detected between the groups in immunohistochemical examinations (Table 3, Figure 4). While E-cadherin immunoreactivity was mild in the control group, it was severe in the PRP and HAM groups. TGFβ1 immunoreactivity, on the other hand, could not be detected at a significant level in the control group, but it was detected at a moderate level in the PRP and HAM groups (both p<0.001).

**DISCUSSION**

Dead spaces may occur in tissues where skin flaps are created and surgical dissection is performed, such as radical mastectomy, modified radical mastectomy, breast conserving surgery, ALND, sentinel lymph node biopsy, and breast biopsies. Seroma occurs as a result of leakage of lymphatic and vascular fluid into these dead spaces (15). It is one of the most common wound complications in the early postoperative period. Although the pathogenesis of seroma formation has not been clearly clarified, it has been reported that damage to the axillary lymph channels is one of the important causes (16). It is also known that the prolonged healing process is effective in the formation of this complication (17). With the creation of the skin flap during surgery, local inflammatory events and chemoreactant



**Figure 2.** Median seroma volumes in each group

**Table 2.** Lymphocyte, eosinophil, histiocyte, and fibroblast activity by groups

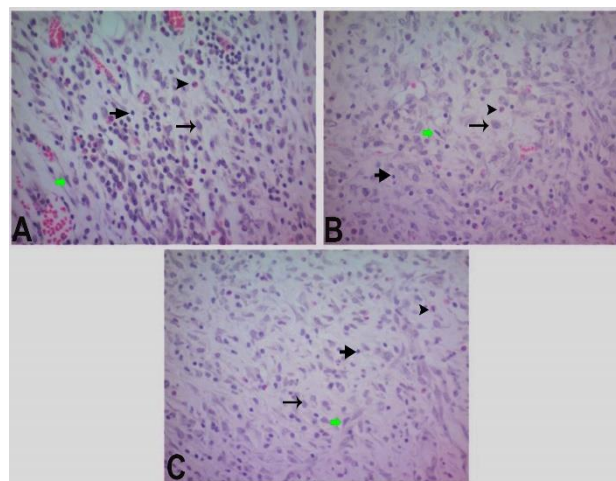
	Control	PRP	HAM	p
<b>Lymphocytes</b>	4 (0) [3-4]	2 (0) [2-3]	2 (0) [2-2]	<0.001 <sup>a</sup>
<b>Eosinophils</b>	2 (0.5) [1-2]	1 (0) [1-1]	1 (0) [1-2]	0.002 <sup>b</sup>
<b>Histiocytes</b>	3 (0) [3-4]	2 (0) [2-3]	2 (0) [2-2]	<0.001 <sup>c</sup>
<b>Fibroblasts</b>	3 (0) [3-4]	2 (0) [1-2]	2 (0) [2-3]	<0.001 <sup>d</sup>

PRP: platelet-rich plasma, HAM: human amniotic membrane, <sup>a</sup>: pControl-PRP<0.001; pControl-HAM<0.001; pPRP-HAM=0.317; <sup>b</sup>: pControl-PRP=0.003; pControl-HAM=0.015; pPRP-HAM=0.317; <sup>c</sup>: pControl-PRP=0.001; pControl-HAM<0.001; pPRP-HAM=0.317; <sup>d</sup>: pControl-PRP<0.001; pControl-HAM=0.001; pPRP-HAM=0.171

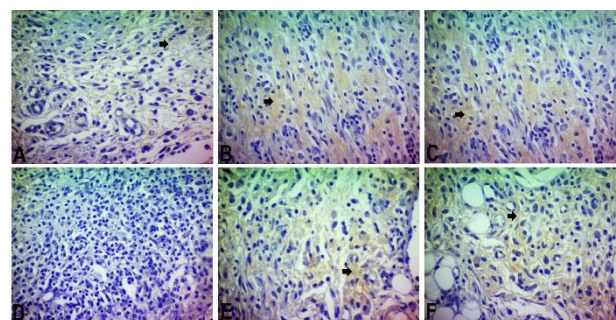
**Table 3.** E-Cadherin and TGFβ1 immunoreactivity

	Control	PRP	HAM	p
<b>E-Cadherin</b>	1 (0) [0-1]	3 (0) [3-3]	3 (0) [2-3]	<0.001 <sup>a</sup>
<b>TGFβ1</b>	1 (0.5) [2-3]	2 (0) [1-2]	2 (0) [2-2]	<0.001 <sup>b</sup>

TGFβ1: Transforming growth factor-1β, PRP: platelet-rich plasma, HAM: human amniotic membrane, <sup>a</sup>: pControl-PRP<0.001; pControl-HAM<0.001; pPRP-HAM=0.317; <sup>b</sup>: pControl-PRP<0.001; pControl-HAM<0.001; pPRP-HAM=0.317



**Figure 3.** A) very severe lymphocyte infiltration (arrow), severe histiocyte (thin arrow), and fibroblast activity (green arrow) with moderate eosinophil infiltration (arrowhead) in the control group; B) mild eosinophil infiltration (arrowhead) with moderate lymphocyte (arrow), histiocyte (thin arrow), and fibroblast activity (green arrow) in platelet-rich plasma group; C) moderate lymphocyte (arrow), histiocyte (thin arrow), fibroblast activity (green arrow), and mild eosinophil infiltration (arrowhead) in human amniotic membrane group; (x40, hematoxylin&eosin)



**Figure 4.** A) mild E-cadherin immunopositivity, D) TGFβ1 immunonegativity in the control group; B) severe levels of E-cadherin, E) moderate TGFβ1 immunopositivity in platelet-rich plasma group; C) severe levels of E-cadherin, F) moderate TGFβ1 immunopositivity in human amniotic membrane group; (arrows, x40, hematoxylin&eosin)

agents such as histamine, adenosine, and prostaglandin increase. As a result of increased vascular permeability due to these agents, serous fluid flows into the surgical area and contributes to seroma formation (18). One of the factors that increase this local inflammation is foreign bodies that are delayed in penetrating the tissue and ischemic tissue pieces left in the dissection area during surgery.

There are many studies in the literature that are thought to be effective in preventing seroma formation. The majority of these studies; it is designed on the basis of reducing the surgical cavity area, shortening the inflammatory process, and accelerating healing. In this context, different surgical techniques, pressure dressings, techniques that provide immobilization, tissue adhesives, and different agents have been involved in studies to prevent this complication (19,20). Platelets have an important role in hemostasis, tissue regeneration, and host defense. PRP is rich in various growth factors. Today, it is a biological material that is used in many surgical methods, chronic ulcers, and different clinical requirements. Its usage areas are increasing day by day (21). In the scope of the study, HAM with different biological properties such as PRP was examined. HAM, which is the avascular collagen matrix in the innermost layer of the placenta, is a biomaterial that is trying to find its place in current use. These properties differ depending on the preparation techniques of HAM and there is no consensus on the preparation techniques (22). HAM has anti-inflammatory, anti-fibrotic, and anti-adhesive properties. Known to accelerate wound healing (23). The extracellular matrix contains cytokines and growth factors. It has excellent biocompatibility as it shows low immunogenicity after decellularization (24). For all these reasons, in our study, the effects of PRP and cryopreserved HAM, which have extraordinary biological activity, on seroma formed after RM and ALND were examined.

There are many factors affecting the wound healing rate in surgeries with large flap areas. It has been reported that prolongation of the inflammatory process is effective in seroma formation (3). Therefore, the status of inflammatory cells is very important. Anti-inflammatory properties of PRP and HAM have been reported in studies (24,25). In our study, the levels of lymphocytes, eosinophils, and histiocytes were measured in the surgical field on the postoperative 7<sup>th</sup> day (13). Inflammatory cells were observed to be lower in the PRP and HAM applied groups compared to the control group. These results showed us that PRP and HAM have anti-inflammatory properties in line with the literature.

The activity of growth factors such as TGF- $\beta$  decreases in chronic wounds. However, after the application of PRP and HAM, which have specific biological activity, these growth factors are released and have an important role in supporting wound healing. TGF- $\beta$  accelerates epithelialization and healing by stimulating apoptosis of inflammatory cells, cell proliferation and collagen production (26). After wound formation, E-cadherin expression has an important role in cell maturation and regulation of cell layers (27). It has been reported that e-cadherin excretion increases as a result of amniotic membrane application, especially at the edges of wounds (28). In our study, E-cadherin and TGF- $\beta$ 1 levels, which are positive indicators of wound healing, were

examined in tissue. It was observed that it was significantly higher in both PRP and HAM groups compared to the control group. These results showed us that HAM and PRP have positive effects on wound healing.

When evaluated in terms of seroma volume, it was observed that there was a serious decrease in seroma formation in the subjects who underwent PRP, in line with the literature (14). We think that this positive effect is due to both the anti-inflammatory properties of PRP and its enhancing properties in local growth factors. However, it is predicted that the application of PRP to the surgical area after cancer operations may have negative effects in terms of tumor treatment (29). Because of this negativity, in our study, the effect of HAM, a biological material reported to have a non-tumorigenic effect, which can be an alternative to PRP, on seroma was investigated (30). When the group in which local cryopreserved HAM was applied to the flap area after RM and ALND was compared with the control group, it was observed that there was no decrease in seroma formation. Despite the decrease in inflammatory cells and the increase in factors such as TGF- $\beta$ 1 and E-cadherin, no decrease in seroma formation was observed. Although the reason for this is not fully elucidated, we think that the smooth surface of the HAM, which prevents adhesion, may have prevented the reduction of the dead space under the flap (31).

Cryopreserved HAM is a biological material with high biocompatibility. However, it may cause adverse effects in seroma formation due to reasons such as being a xenograft, being a foreign tissue, and slower adaptation by the host tissue than PRP. Therefore, autograft or allograft applications may be beneficial. In addition, we think that it may be beneficial to apply different techniques in HAM preparation. We think that the use of HAM as a whole, especially in practice, increases its anti-adhesion effectiveness. We think that changing the structure of its smooth surface or applying it in smaller particles may reduce the anti-adhesive effect. In this way, we predict that it may be beneficial in the formation of seroma by taking advantage of its anti-inflammatory properties and positive effects on wound healing.

There were some limitations of the present study. In experimental studies on seroma formation, many scoring systems that were not included in our study, such as adhesion score, were used. Not using these scoring systems can be considered a limitation of this study. In addition, the number of groups was expanded in different studies. This can be considered a limitation

## CONCLUSION

In our study, it was observed that PRP had positive effects on seroma formation after breast surgeries and ALND. However, its use is limited due to limitations in its use after cancer surgery. Therefore, HAM, a different biomaterial with non-tumorigenic properties, has been investigated. When examined in terms of infection and slow tissue healing, which are the mechanisms of action of seroma formation, it was seen that HAM had positive effects. However, cryopreserved HAM did not decrease seroma formation. We think this is due to the anti-adhesive properties of HAM. We think that the preparation and application of HAM have the potential to be beneficial against seroma formation if modifications are made.

**Ethics Committee Approval:** The study was approved by the Animal Experiments Local Ethics Committee of Sivas Cumhuriyet University (14.11.2020, 367). All institutional and national guidelines for the care and use of laboratory animals were followed.

**Conflict of Interest:** None declared by the authors.

**Financial Disclosure:** This study was supported by the Scientific Research Project Fund of Sivas Cumhuriyet University under the project numbers T-2021-909.

**Acknowledgments:** None declared by the authors.

**Author Contributions:** Idea/Concept: MG; Design: MG, MÖ; Data Collection/Processing: MG, MÖ; Analysis/Interpretation: MÖ; Literature Review: MG, MÖ; Drafting/Writing: MG, MÖ; Critical Review: MG.

## REFERENCES

- Sung H, Ferlay J, Siegel RL, Laversanne M, Soerjomataram I, Jemal A, et al. Global cancer statistics 2020: GLOBOCAN estimates of incidence and mortality worldwide for 36 cancers in 185 countries. *CA Cancer J Clin.* 2021;71(3):209-49.
- Kuroi K, Shimozuma K, Taguchi T, Imai H, Yamashiro H, Ohsumi S, et al. Pathophysiology of seroma in breast cancer. *Breast Cancer.* 2005;12(4):288-93.
- McCaul J, Aslaam A, Spooner RJ, Loudon I, Cavanagh T, Purushotham AD. Aetiology of seroma formation in patients undergoing surgery for breast cancer. *Breast.* 2000;9(3):144-8.
- Kuroi K, Shimozuma K, Taguchi T, Imai H, Yamashiro H, Ohsumi S, et al. Evidence-based risk factors for seroma formation in breast surgery. *Jpn J Clin Oncol.* 2006;36(4):197-206.
- Gubitosi A, Docimo G, Parmeggiani D, Pirozzi R, Vitiello C, Schettino P, et al. Acellular bovine pericardium dermal matrix in immediate breast reconstruction after Skin Sparing Mastectomy. *Int J Surg.* 2014;12(Suppl 1):S205-8.
- Chow LW, Loo WT, Yuen KY, Cheng C. The study of cytokine dynamics at the operation site after mastectomy. *Wound Repair Regen.* 2003;11(5):326-30.
- Watt-Boolsen S, Nielsen V, Jensen J, Bak S. Postmastectomy seroma. A study of the nature and origin of seroma after mastectomy. *Dan Med Bull.* 1989;36(5):487-9.
- O'Neill AC, Randolph MA, Bujold KE, Kochevar IE, Redmond RW, Winograd JM. Preparation and integration of human amnion nerve conduits using a light-activated technique. *Plast Reconstr Surg.* 2009;124(2):428-37.
- Fairbairn NG, Ng-Glazier J, Meppelink AM, Randolph MA, Winograd JM, Redmond RW. Improving outcomes in immediate and delayed nerve grafting of peripheral nerve gaps using light-activated sealing of neurotomy sites with human amnion wraps. *Plast Reconstr Surg.* 2016;137(3):887-95.
- Zhao YZ, Jiang X, Xiao J, Lin Q, Yu WZ, Tian FR, et al. Using NGF heparin-polyoxamer thermosensitive hydrogels to enhance the nerve regeneration for spinal cord injury. *Acta Biomater.* 2016;29:71-80.
- Mamede AC, Carvalho MJ, Abrantes AM, Laranjo M, Maia CJ, Botelho MF. Amniotic membrane: from structure and functions to clinical applications. *Cell Tissue Res.* 2012;349(2):447-58.
- Aydin O, Karaca G, Pehlivanli F, Altunkaya C, Uzun H, Özden H, et al. Platelet-rich plasma may offer a new hope in suppressed wound healing when compared to mesenchymal stem cells. *J Clin Med.* 2018;7(6):143.
- Choi MS, Kim HK, Kim WS, Bae TH, Kim MK. A comparison of triamcinolone acetonide and fibrin glue for seroma prevention in a rat mastectomy model. *Ann Plast Surg.* 2012;69(2):209-12.
- Calisir A, Ece I, Yormaz S, Colak B, Kirazli H, Sahin M. The effects of platelet-rich plasma to decrease the risk of seroma formation after mastectomy and axillary dissection. *J Surg Res.* 2020;256:156-62.
- Karaköse O, Pülüt H, Özçelik KÇ, Zihni İ, Bozkurt KK, Şenol S, et al. Effects of different applications on postoperative seroma formation and wound healing following mastectomy and axillary dissection in rats. *Galician Med J.* 2021;28(1):E202115.
- Harada RN, Pressler VM, McNamara J. Fibrin glue reduces seroma formation in the rat after mastectomy. *Surg Gynecol Obstet.* 1992;175(5):450-4.
- Anjani J, Amit O, Kuber S, Achal G. Factors affecting seroma formation after modified radical mastectomy in patients of carcinoma breast: A prospective study. *IJSS J Surg.* 2016;2(1):1-5.
- Gonzalez EA, Saltzstein EC, Riedner CS, Nelson BK. Seroma formation following breast cancer surgery. *Breast J.* 2003;9(5):385-8.
- McCarthy C, Lennox P, Germann E, Clugston P. use of abdominal quilting sutures for seroma prevention in TRAM flap reconstruction: a prospective, controlled trial. *Ann Plast Surg.* 2005;54(4):361-4.
- Aksoy SÖ, Tunk CO, Sevinç Aİ, Güray Durak M. Effects of locally applied clinoptilolite (Froximun®) on seroma formation in a rat mastectomy and axillary lymph node dissection model. *DEU Tıp Derg.* 2019;33(2):139-47.
- Marx RE. Platelet-rich plasma: evidence to support its use. *J Oral Maxillofac Surg.* 2004;62(4):489-96.
- Liu Z, Zhu X, Zhu T, Tang R. Evaluation of a biocomposite mesh modified with decellularized human amniotic membrane for intraperitoneal onlay mesh repair. *ACS Omega* 2020;5(7):3550-62.
- Parolini O, Soncini M, Evangelista M, Schmidt D. Amniotic membrane and amniotic fluid-derived cells: potential tools for regenerative medicine? *2009;4(2):275-91.*
- Iranpour S, Mahdavi-Shahri N, Miri R, Hasanzadeh H, Bidkhorri HR, Naderi-Meshkin H, et al. Supportive properties of basement membrane layer of human amniotic membrane enable development of tissue engineering applications. *Cell Tissue Bank.* 2018;19(3):357-71.
- Mazzocca AD, McCarthy MB, Intravia J, Beitzel K, Apostolakis J, Cote MP, et al. An in vitro evaluation of the anti-inflammatory effects of platelet-rich plasma, ketorolac, and methylprednisolone. *Arthroscopy.* 2013;29(4):675-83.

26. Chai J, Ge J, Zou J. Effect of autologous platelet-rich plasma gel on skin flap survival. *Med Sci Monit.* 2019;25:1611-20.
27. Kuwahara M, Hatoko M, Tada H, Tanaka A. E-cadherin expression in wound healing of mouse skin. *J Cutan Pathol.* 2001;28(4):191-9.
28. Choi JA, Jin HJ, Jung S, Yang E, Choi JS, Chung SH, et al. Effects of amniotic membrane suspension in human corneal wound healing in vitro. *Mol Vis.* 2009;15:2230-8.
29. Spartalis E, Tsilimigras DI, Charalampoudis P, Karachaliou GS, Moris D, Athanasiou A, et al. The “Yin and Yang” of platelet-rich plasma in breast reconstruction after mastectomy or lumpectomy for breast cancer. *Anticancer Res.* 2017;37(12):6557-62.
30. Kang NH, Hwang KA, Kim SU, Kim YB, Hyun SH, Jeung EB, et al. Potential antitumor therapeutic strategies of human amniotic membrane and amniotic fluid-derived stem cells. *Cancer Gene Ther.* 2012;19(8):517-22.
31. Kelekci S, Uygur D, Yilmaz B, Sut N, Yesildaglar N. Comparison of human amniotic membrane and hyaluronate/carboxymethylcellulose membrane for prevention of adhesion formation in rats. *Arch Gynecol Obstet.* 2007;276(4):355-9.