

## Case Report / Olgu Sunumu

### Rare cases of ectopic pregnancies in a tertiary care center: report of four cases

#### Üçüncü basamak bir merkezdeki nadir ektopik gebelik olguları: dört olgu sunumu

Özlem Bozoklu Akkar<sup>1</sup>, Çağlar Yıldız, Savaş Karakuş, Dinçer Sümer, Gülizar Özer, Yasin Bıyık, Abdullah Boztosun, Ayşe Gonca İmir Yenicesu, Ali Yanık

*Department of Obstetrics and Gynecology, Cumhuriyet University Faculty of Medicine, Sivas*

#### Abstract

In this report of four cases, we present cases of ovarian, cornual, and secondary abdominal ectopic pregnancies, and heterotopic pregnancy that are rare forms of ectopic pregnancies, in the absence of risk factors obtained from the history of the patients. All of the cases were managed with surgical methods successfully. These rare types of ectopic pregnancy should be considered in the differential diagnosis of the female patients of reproductive age admitting to the emergency service in order to manage these emergent diseases of the gynecology successfully.

**Keywords:** Ectopic pregnancy, ovarian, cornual, abdominal, heterotopic

#### Özet

Bu dört olgunun sunumunda, ektopik gebeliğin nadir görülen formları olan ve anamnezlerinde risk faktörleri tespit edilmeyen ovaryen, kornual, sekonder abdominal ve heterotopik gebelikler ele alındı. Vakaların tümü cerrahi yöntemlerle başarılı bir şekilde tedavi edildi. Ektopik gebeliğin bu nadir tiplerinin, alt batın ile ilişkili yakınmalar ile acil servise başvuran üreme dönemindeki kadın hastalarda uygulanan ayırıcı tanı sırasında, jinekolojinin acil hastalıkları arasında mutlaka düşünülmesi, bu olguların başarılı bir şekilde yönetilebilmesi için gerekli bir yaklaşımdır.

**Anahtar sözcükler:** Ektopik gebelik, ovaryen, kornual, abdominal, heterotopik

#### 1 Corresponding author:

Dr. Özlem Bozoklu Akkar, Kadın Hastalıkları ve Doğum Anabilim Dalı, Cumhuriyet Üniversitesi Tıp Fakültesi, Sivas  
Email: dr.ozlemakkar@yahoo.com

#### **Akkar et al.: Rare cases of ectopic pregnancies in a tertiary care center: report of four cases** 22

This is an open-access article distributed under the terms of the Creative Common Attribution License, which permits unrestricted use, distribution, and reproduction in any medium, provided the original author(s) and source are credited.

This article may be cited as: Akkar ÖB, Yıldız Ç, Karakuş S, Sümer D, Özer G, Bıyık Y, Boztosun A, Yenicesu AGI, Yanık A. Rare cases of ectopic pregnancies in a tertiary care center: report of four cases. Basic Clin Sci 2014; 3: 22-27. DOI: dx.doi.org/ 10.12808/bcs.v3i2.5000080441. Available from: dergipark.ulakbim.gov.tr/bcs.

## Introduction

Ectopic pregnancy is one of the most important gynecological emergencies. Non-tubal ectopic pregnancies and heterotopic pregnancy are rare diseases compared to tubal ectopic pregnancies [1]. Here, we present three cases of non-tubal ectopic pregnancy and a case of heterotopic pregnancy managed in a tertiary care center.

### Case 1

A 25-year-old woman with a history of having intrauterine device for three years presented to our gynecological emergency unit with amenorrhea and left inguinal pain. The first day of last menstrual period was 6 weeks ago.  $\beta$ -human chorionic gonadotropin concentration ( $\beta$ -hCG) was 10512 mIU/ml. Her gynecological examination revealed left adnexal tenderness. The transvaginal ultrasonography showed 10x8 mm gestational sac in the left ovary (Figure 1). The diagnostic laparoscopy was performed to confirm the diagnosis of ruptured left ovarian ectopic pregnancy. Then, with a pfannenstiel incision laparotomy was performed and the ectopic focus was visualized in the left ovary. We performed a wedge resection of the ectopic pregnancy from the left ovary. She was discharged on the second postoperative day with a good recovery. The histopathological evaluation confirmed the ruptured ovarian ectopic pregnancy.

### Case 2

A 37-year-old woman with an obstetrical history of three parity and three abortus admitted to our gynecological emergency unit with abnormal vaginal bleeding after a dilatation and curettage for a missed abortion. She did not remember her first day of last menstrual period. She had a normal gynecological examination and a  $\beta$ -hCG level of 21.48 mIU/ml. The transvaginal ultrasonography showed a gestational sac of 25x25x19 mm including an embryo 8.2 mm with a crown rump length and negative fetal cardiac activity in the right cornual region (Figure 2). Because of the future fertility desire she did not accept to have an operation, therefore we applied a single dose of 50 mg/m<sup>2</sup> of methotrexate. We followed her for a week and  $\beta$ -hCG levels did not change on the fourth and seventh day. We repeated the transvaginal ultrasonography on the seventh day, however there was also no change in the size of the cornual ectopic focus. We performed a diagnostic laparoscopy and observed the right cornual ectopic pregnancy. Then, we decided to perform laparotomy and excision of the right cornual ectopic pregnancy. The patient needed no blood transfusion during or after the operation and she recovered and discharged on the postoperative second day.

#### **Akkar et al.: Rare cases of ectopic pregnancies in a tertiary care center: report of four cases** 23

This is an open-access article distributed under the terms of the Creative Common Attribution License, which permits unrestricted use, distribution, and reproduction in any medium, provided the original author(s) and source are credited.

This article may be cited as: Akkar ÖB, Yıldız Ç, Karakus S, Sümer D, Özer G, Bıyık Y, Boztosun A, Yenicesu AGI, Yamık A. Rare cases of ectopic pregnancies in a tertiary care center: report of four cases. Basic Clin Sci 2014; 3: 22-27. DOI: [dx.doi.org/ 10.12808/bcs.v3i2.5000080441](https://doi.org/10.12808/bcs.v3i2.5000080441). Available from: [dergipark.ulakbim.gov.tr/bcs](http://dergipark.ulakbim.gov.tr/bcs).

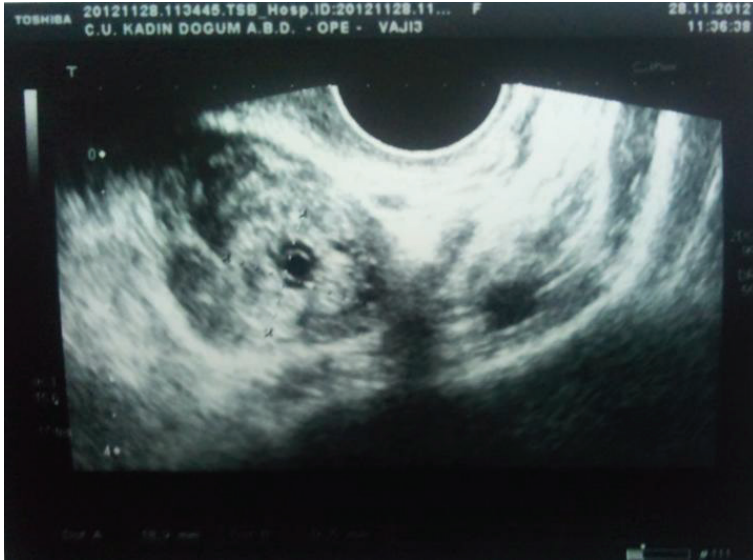

Figure 1. The ultrasonographic image of the ovarian ectopic pregnancy.

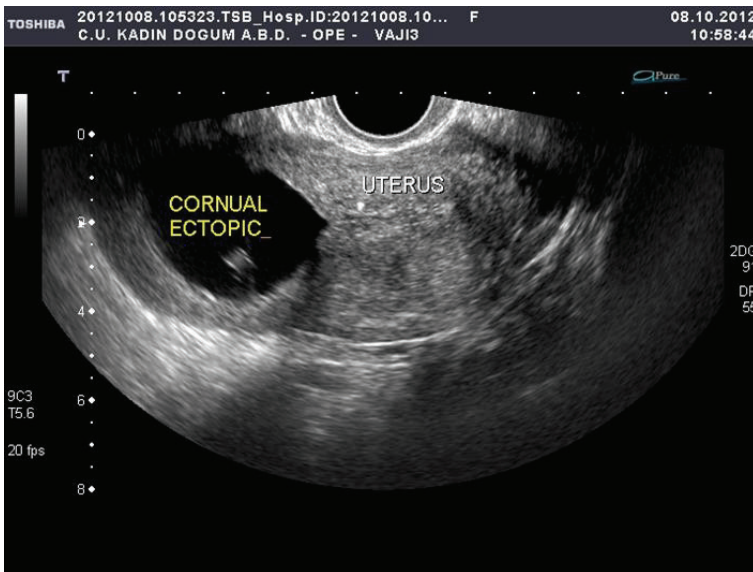


Figure 2. The ultrasonographic image of the cornual ectopic pregnancy.

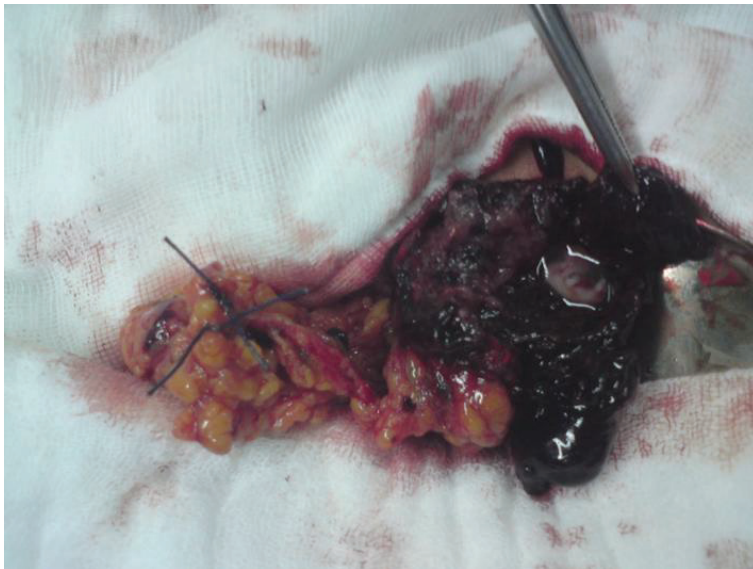**Akkar et al.: Rare cases of ectopic pregnancies in a tertiary care center: report of four cases** 24

This is an open-access article distributed under the terms of the Creative Common Attribution License, which permits unrestricted use, distribution, and reproduction in any medium, provided the original author(s) and source are credited.

This article may be cited as: Akkar ÖB, Yıldız Ç, Karakus S, Sümer D, Özer G, Bıyık Y, Boztosun A, Yenicesu AGI, Yanık A. Rare cases of ectopic pregnancies in a tertiary care center: report of four cases. Basic Clin Sci 2014; 3: 22-27. DOI: dx.doi.org/ 10.12808/bcs.v3i2.5000080441. Available from: dergipark.ulakbim.gov.tr/bcs.

### Case 3

A 31-year old patient admitted to the emergency service with symptoms of abdominal pain, nausea, dizziness and 10 weeks of amenorrhea. The physical examination was performed and hemodynamic instability and tenderness and rebound on four quadrants of the abdomen were found. She had hemoglobin value of 6.1 g/dL and  $\beta$ -hCG level of >15000 mIU/mL. The transvaginal ultrasonography revealed the signs of hemoperitoneum and an intrauterine device in the endometrial cavity. At laparotomy ruptured primary tubal ectopic pregnancy and fetus with 10-12 weeks of gestational age and its placenta implanted onto the omentum were visualized (Figure 3). The right salpingectomy, partial omentectomy, and extraction of intrauterine device were performed. Three units of erythrocyte suspension and 4 units of fresh frozen plasma were given to the patient intraoperatively. The postoperative hemoglobin level was 9.2 g/dL. The patient was discharged on the third day postoperatively with an uneventful recovery to health. The histopathological evaluation resulted as right tubal ectopic pregnancy, fetus with immature organ findings, and chorion villi on the omentum.



**Figure 3. The view of the secondary abdominal pregnancy lied on the omentum with its fetus and placenta.**

### Case 4

A 38-year old female admitted to the emergency unit with symptoms of abdominal pain, nausea, dizziness. She had an 8 weeks of gestational age of spontaneous pregnancy. She had a hemoglobin value of 5.3 g/dL. The transvaginal ultrasonographic evaluation of the

**Akkar et al.: Rare cases of ectopic pregnancies in a tertiary care center: report of four cases** 25

This is an open-access article distributed under the terms of the Creative Common Attribution License, which permits unrestricted use, distribution, and reproduction in any medium, provided the original author(s) and source are credited.

This article may be cited as: Akkar ÖB, Yıldız Ç, Karakus S, Sümer D, Özer G, Bıyık Y, Boztosun A, Yenicesu AGI, Yamık A. Rare cases of ectopic pregnancies in a tertiary care center: report of four cases. Basic Clin Sci 2014; 3: 22-27. DOI: dx.doi.org/ 10.12808/bcs.v3i2.5000080441. Available from: dergipark.ulakbim.gov.tr/bcs.

patient revealed intrauterine single fetal cardiac activity positive 8 weeks of gestational age of an embryo, free fluid image in the pelvis, and a heterogenous 73x70 mm of a mass on the right adnexal region. We performed an emergent laparotomy and ruptured right tubal ectopic pregnancy was visualized. Right salpingectomy was performed. 5 units of erythrocyte suspension and 3 units of fresh frozen plasma were given to the patient intraoperatively. She was discharged on the seventh day postoperatively.

## Discussion

Rare types of ectopic pregnancy present for only a minor part of the disease; ovarian pregnancy accounting for 0.5-3% of ectopic pregnancies, cornual pregnancy for 2-3%, abdominal pregnancy for 1.4%. The incidence of heterotopic pregnancy is estimated to be 1 in 30.000 pregnancies [1,2]. In this report of cases, uncommon forms of ectopic pregnancy were presented. The common feature of the cases was non-tubal ectopic pregnancies and heterotopic pregnancy being after natural cycles. All of the cases were managed with surgical methods successfully.

The risk of both ectopic and heterotopic pregnancies increase due to the use of assisted reproductive technologies [3]. In case 1, the patient negated the history of risk factors for ovarian pregnancy [4] such as assisted reproductive technologies or pelvic inflammatory disease. It can be supposed that the primary ovarian pregnancy ensued from the fertilisation in the follicle. In the second case report presented, the patient had a cornual pregnancy having none of the risk factors for the disease such as in vitro fertilization, previous ectopic pregnancy, or tubal surgeries [5], therefore it can be accepted to be a primary case of cornual pregnancy after a natural cycle. In case 3 we presented a secondary abdominal pregnancy after tubal rupture of an ectopic pregnancy. This condition may be due to some risk factors including assisted reproductive techniques, pelvic inflammatory disease, or endometriosis [6, 7]; none of that was found in the history of the patient. In the fourth case, a patient with a heterotopic pregnancy having none of the risk factors for the disease such as pelvic inflammatory disease, use of intrauterine device, smoking, history of infertility or treatment for infertility, pelvic surgery [2, 8].

Rare cases of ectopic pregnancies should be evaluated during the differential diagnosis in any case of a female patient in reproductive age presenting with lower quadrant abdominal pain, even in the absence of the common risk factors of the disease. In our cases, we found out none of the risk factors of the ectopic pregnancy from the history of the patient, however they were diagnosed and managed with surgical methods successfully. According to our experience of rare cases of ectopic pregnancies, we think that, these rare forms should be considered in the differential diagnosis of female patients in the reproductive age.

## Conflict of interest

The authors declare that no scientific and/or financial conflicts of interest exists with other people or institutions.

### **Akkar et al.: Rare cases of ectopic pregnancies in a tertiary care center: report of four cases** 26

This is an open-access article distributed under the terms of the Creative Common Attribution License, which permits unrestricted use, distribution, and reproduction in any medium, provided the original author(s) and source are credited.

This article may be cited as: Akkar ÖB, Yıldız Ç, Karakus S, Sümer D, Özer G, Bıyık Y, Boztosun A, Yenicesu AGI, Yamık A. Rare cases of ectopic pregnancies in a tertiary care center: report of four cases. *Basic Clin Sci* 2014; 3: 22-27. DOI: [dx.doi.org/ 10.12808/bcs.v3i2.5000080441](https://doi.org/10.12808/bcs.v3i2.5000080441). Available from: [dergipark.ulakbim.gov.tr/bcs](http://dergipark.ulakbim.gov.tr/bcs).

## References

1. Tulandi T. Incidence, risk factors, and pathology of ectopic pregnancy. In: UpToDate, Post TW (Ed), UpToDate, Waltham, MA. (Accessed on November 28, 2014.)
2. Molinaro TA, Barnhart KT. Abdominal pregnancy, cesarean scar pregnancy, and heterotopic pregnancy. In: UpToDate, Post TW (Ed), UpToDate, Waltham, MA. (Accessed on December 2, 2014.)
3. Strandell A, Thorburn J, Hamberger L. Risk factors for ectopic pregnancy in assisted reproduction. *Fertil Steril.* 1999 Feb;71(2):282-6.
4. Das S, Kalyani R, Lakshmi V, Harendra Kumar ML. Ovarian pregnancy. *Indian J Pathol Microbiol.* 2008 Jan-Mar;51(1):37-8.
5. Tulandi T, Al-Jaroudi D. Interstitial pregnancy: results generated from the Society of Reproductive Surgeons Registry. *Obstet Gynecol.* 2004 Jan;103(1):47-50.
6. Tsudo T, Harada T, Yoshioka H, Terakawa N. Laparoscopic management of early primary abdominal pregnancy. *Obstet Gynecol.* 1997 Oct;90(4 Pt 2):687-8.
7. Ludwig M, Kaisi M, Bauer O, Diedrich K. The forgotten child--a case of heterotopic, intra-abdominal and intrauterine pregnancy carried to term. *Hum Reprod.* 1999 May;14(5):1372-4.
8. Fouedjio JH, Fouelifack FY, Fouogue JT, Sando Z. Ruptured heterotopic pregnancy in a natural conception cycle: a case report at the Yaounde central Hospital (Cameroon). *Pan Afr Med J.* 2013 Nov 18;16:106.

### **Akkar et al.: Rare cases of ectopic pregnancies in a tertiary care center: report of four cases** 27

This is an open-access article distributed under the terms of the Creative Common Attribution License, which permits unrestricted use, distribution, and reproduction in any medium, provided the original author(s) and source are credited.

This article may be cited as: Akkar ÖB, Yıldız Ç, Karakus S, Sümer D, Özer G, Bıyık Y, Boztosun A, Yenicesu AGI, Yamık A. Rare cases of ectopic pregnancies in a tertiary care center: report of four cases. *Basic Clin Sci* 2014; 3: 22-27. DOI: [dx.doi.org/ 10.12808/bcs.v3i2.5000080441](https://dx.doi.org/10.12808/bcs.v3i2.5000080441). Available from: [dergipark.ulakbim.gov.tr/bcs](http://dergipark.ulakbim.gov.tr/bcs).