



An Abnormality of Medial Plantar Nerve: A Rare Case Report

Mediyal Plantar Sinir Anormalliği: Nadir Bir Olgu Sunumu

Burak KARİP¹

 0000-0002-6757-4960

Özlem ÖZTÜRK KÖSE²

 0000-0001-5107-3726

¹Department of Anatomy, University of Health Sciences Faculty of Medicine, İstanbul, Turkey

²Department of Anatomy, Biruni University Faculty of Medicine, İstanbul, Turkey

Corresponding Author
Sorumlu Yazar
Burak KARİP
burak.karip@sbu.edu.tr

Received / Geliş Tarihi : 03.02.2022
Accepted / Kabul Tarihi : 29.03.2022
Available Online /
Çevrimiçi Yayın Tarihi : 17.04.2022

ABSTRACT

There are not many articles about the anatomical knowledge of the variable conditions of the sole of the foot, but normally knowledge of this area is essential for surgeries such as reconstructive or peripheral nerve compression syndrome. In this region, medial plantar nerve (nervus plantaris medialis) innervates the abductor and flexor muscles of the thumb. In addition, there is a region where receives the skin sensation in the foot. When it is damaged or exposed to pressure by any muscle due to an abnormal course, it can't stimulate the relevant muscles and the person may experience numbness and loss of muscle function on the sole of the foot. During a routine cadaver dissection, an abnormal course of nervus plantaris medialis was observed on the left side of a male cadaver. In this case, we presented the abnormal course of some branches of medial plantar nerve and discussed the clinical significance.

Keywords: Medial plantar nerve; tibial nerve; flexor digitorum brevis; abnormality; anatomy.

ÖZ

Ayak tabanının değişken koşullarının anatomik bilgisi hakkında pek fazla makale yoktur, ancak normalde bu bölgenin bilgisi, rekonstrüktif veya periferik sinir sıkışma sendromu gibi ameliyatlara için çok önemlidir. Mediyal plantar sinir (nervus plantaris medialis), bu bölgede başparmağa ait abdükör kası ve fleksör kasları inerve eder. Ayrıca ayakta deri duyunu aldığı bir bölge de mevcuttur. Hasarlandığında ya da anormal bir seyir sebebiyle herhangi bir kas tarafından basıya maruz bırakıldığında ilgili kasları uyaramaz ve kişi için ayak tabanında bir uyuşukluk ve kas fonksiyon kaybı söz konusu olabilir. Rutin bir kadavra diseksiyonu sırasında, bir erkek kadavranın sol tarafında anormal bir nervus plantaris medialis seyri gözlemlendi. Bu vakada mediyal plantar sinirin bazı dallarının anormal seyri gösterilmiş ve klinik önemi tartışılmıştır.

Anahtar kelimeler: Mediyal plantar sinir; tibial sinir; flexor digitorum brevis; anomali; anatomi.

INTRODUCTION

Lateral plantar nerve (LPN) and medial plantar nerve (MPN) arise from tibial nerve. Generally tibial nerve divides proximal to the tarsal tunnel as two branches (1). After the bifurcation, MPN travels parallel to the medial plantar artery that is one of the terminal branches of the posterior tibial artery (2). MPN is a larger one and after the flexor retinaculum, before appears between abductor hallucis muscle and flexor digitorum brevis muscle, it passes deep to adductor hallucis muscle (3). After that, it divides a proper digital plantar nerve and separates as three common digital plantar nerves. Flexor hallucis brevis, abductor hallucis and the first lumbrical are innervated by MPN (4). After the MPN gives its proper digital branches, it courses towards the inner half of the thumb. It is a nerve with a long course and is located more superficially, so a clinical picture called Joplin's neuroma can be seen. If the nerves are examined with ultrasound in pain that does not go away under the feet, it is noticed that the trunk and rafts of the MPN can be seen very clearly (5).

There are few articles about the MPN. Even though there are some articles about the variation of the LPN (6). In this case report, we presented the abnormal course of some branches of MPN and discuss the clinical significance of this variation.

CASE REPORT

During educational dissection for the medical students, the MPN was observed with its abnormal course on the left side of a Caucasian male cadaver. The superficial fascia and the plantar fascia were cautiously lifted. The bifurcation for MPN and LPN was observed under the distal part of the flexor retinaculum. The MPN and the artery which lies with MPN were located superficial to the first layer of the sole. They were found among the plantar fascia and abductor hallucis muscle in Figure 1. Although we know that the MPN lies below the flexor digitorum brevis muscle and then branches towards the phalanges, the branches to phalanges I-IV were described above the muscle as shown in Figure 2. We could not observe any different abnormality in the other parts.

DISCUSSION

We presented the abnormal course and some branches of MPN. Until flexor digitorum brevis, the course was normal. MPN was observed to behave like cutaneous branches. Similar cases like this have been seen to be rare (5,6). Knowledge of the variant conditions of the MPN can prevent from undesirable situations during surgery such as reconstructive surgery which is for island pedicle flap (7). On the other hand, the position course of MPN is very important for peripheral nerve entrapment treatment and peripheral neuropathies affecting the peripheral nervous system like a distal sensory polyneuropathy (8,9). One of the most common problems associated with the MPN is neurofibroma, and one of the most common causes is hypertrophy of the nerve. It presents with difficulty in walking, difficulty in standing, and a painful period. Therefore, it can be confused with compression caused by a variation of the MPN (10). MPN tumors are most common in peripheral nerve sheaths, and therefore, conditions that present with pain under the foot should be emphasized if there is an abnormal course and therefore compression. Swelling and edema developing on the MPN trace can sometimes be a sign of a tumor with a variation (11).

Informed Consent: Since our study was a case report that includes a cadaveric study, there was no consent form.

Conflict of Interest: None declared by the authors.

Financial Disclosure: None declared by the authors.

Acknowledgments: None declared by the authors.

Author Contributions: Idea/Concept: BK, ÖÖK; Design: BK, ÖÖK; Data Collection/Processing: BK, ÖÖK; Analysis/Interpretation: BK, ÖÖK; Literature Review: BK, ÖÖK; Drafting/Writing: BK, ÖÖK; Critical Review: BK, ÖÖK.

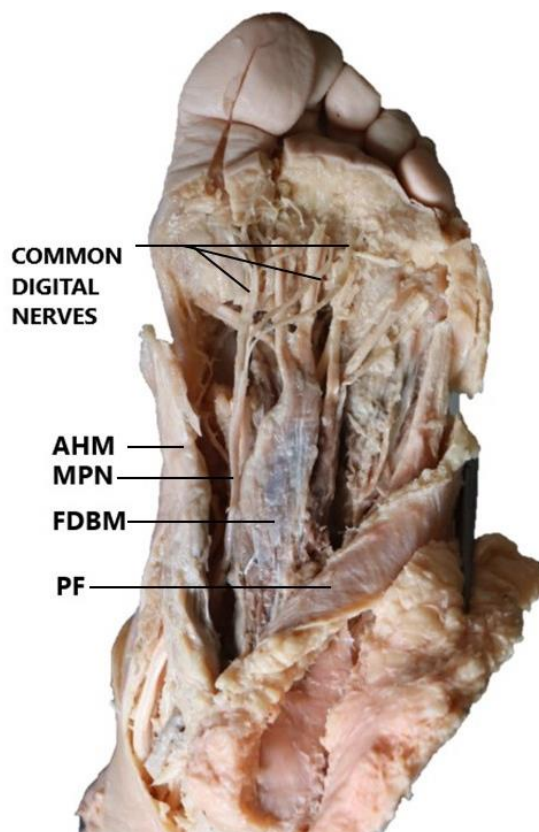


Figure 1. Abnormal course of the medial plantar nerve
MPN: medial plantar nerve (nervus plantaris medialis), AHM: abductor hallucis muscle, FDBM: flexor digitorum brevis muscle, PF: plantar fascia

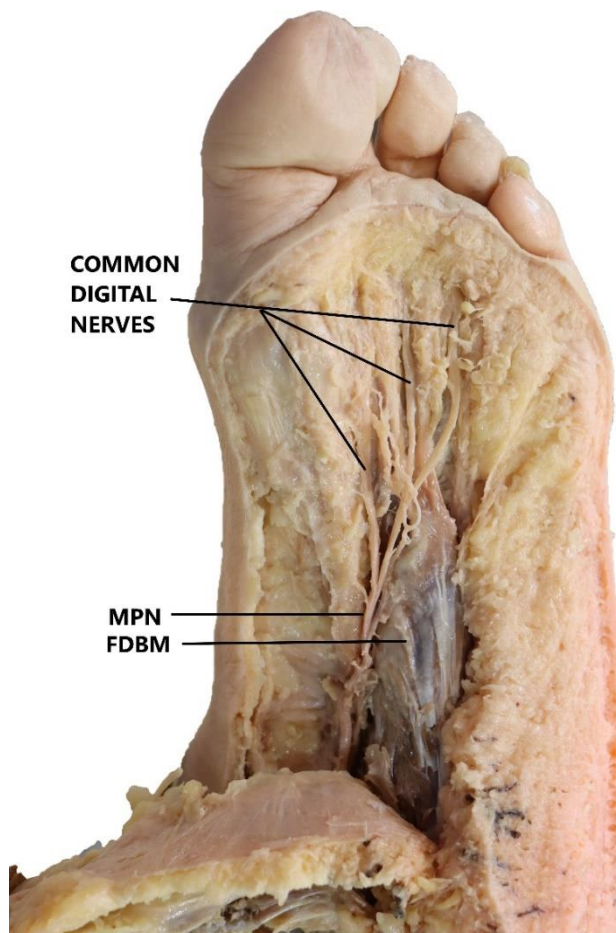


Figure 2. Abnormal course of the medial plantar nerve
MPN: medial plantar nerve (nervus plantaris medialis), FDBM: flexor digitorum brevis muscle

REFERENCES

1. Yang Y, Du ML, Fu YS, Liu W, Xu Q, Chen X, et al. Fine dissection of the tarsal tunnel in 60 cases. *Sci Rep.* 2017;7:46351. Erratum in: *Sci Rep.* 2021;11(1):11678.
2. Lohasammakul S, Turbpaiboon C, Chaiyasate K, Tatsanavivat P, Chompoopong S, Roham A, et al. Anatomy of medial plantar superficial branch artery perforators: Facilitation of medial plantar superficial branch artery perforator (MPAP) flap harvesting and design for finger pulp reconstruction. *Microsurgery.* 2018;38(5):536-43.
3. Standring S. *Gray's anatomy: the anatomical basis of clinical practice.* 41th ed. Edinburgh: Elsevier; 2015.
4. Koo GB, Lee JH, Jang JH, Song IH, Kim JY. Superficial course of the medial plantar nerve: case report. *Anat Cell Biol.* 2019;52(1):87-9.
5. Le Corroller T, Santiago E, Deniel A, Causeret A, Champsaur P, Guillin R. Anatomical study of the medial plantar proper digital nerve using ultrasound. *Eur Radiol.* 2019;29(1):40-5.
6. Astik RB, Dave UH, Gajendra KS. Variant position of the medial plantar nerve. *Int J Anat Var.* 2011;4:1-2.
7. Gu JX, Huan AS, Zhang NC, Liu HJ, Xia SC, Regmi S, et al. Reconstruction of heel soft tissue defects using medial plantar artery island pedicle flap: Clinical experience and outcomes analysis. *J Foot Ankle Surg.* 2017;56(2):226-9.
8. Flanigan RM, DiGiovanni BF. Peripheral nerve entrapments of the lower leg, ankle, and foot. *Foot Ankle Clin.* 2011;16(2):255-74.
9. Barrell K, Smith AG. Peripheral neuropathy. *Med Clin North Am.* 2019;103(2):383-97.
10. D'Orazi V, Venditto T, Panunzi A, Anichini S, Manzini G, Tallarico A, et al. Misdiagnosis of plexiform neurofibroma of the medial plantar nerve: case report. *Foot (Edinb).* 2014;24(3):143-5.
11. Kwon JH, Yoon JR, Kim TS, Kim HJ. Peripheral nerve sheath tumor of the medial plantar nerve without tarsal tunnel syndrome: a case report. *J Foot Ankle Surg.* 2009;48(4):477-82.