

## COVID-19 Presenting with Diabetic Ketoacidosis: A Case Report

Iffet Beril GOKMEN<sup>1</sup>, Sidelya Ecem YIGIT<sup>1</sup>, Yıldız OKUTURLAR<sup>1</sup>, Behiye OREN<sup>2</sup>

<sup>1</sup>Acibadem Mehmet Ali Aydınlar University Faculty of Medicine, Department of Internal Medicine, Division of General Internal Medicine, Istanbul, Turkey

<sup>2</sup>Acibadem University Atakent Hospital, Department of Anesthesiology and Reanimation, Intensive Care Unit, Istanbul, Turkey

### ABSTRACT

Diabetic ketoacidosis (DKA) is one of the most common fatal complications of diabetes and is often associated with severe underlying disease. The COVID-19 infection follows an intense course in patients with comorbidities such as diabetes. Herein we presented a case of diabetic ketoacidosis caused by COVID-19 infection.

*Turk J Int Med 2022;4(Supplement 1):S123-S125*  
DOI: [10.46310/tjim.1073576](https://doi.org/10.46310/tjim.1073576)

**Keywords:** COVID-19, infection, diabetes mellitus, complication, diabetic ketoacidosis, treatment.

### Introduction

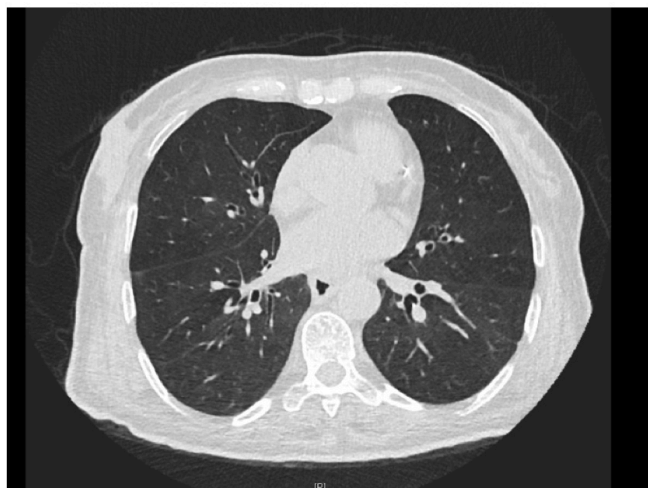
Diabetic ketoacidosis (DKA) is one of the most common complications of diabetes and has the highest mortality rate among hyperglycemic emergencies. Diabetes mellitus is a chronic inflammatory process, and DKA itself is considered an inflammatory condition but is often associated with severe underlying disease. Influencing infections, drug compliance, cerebrovascular accidents, and acute coronary syndromes can be considered facilitating factors for DKA. DKA has

been reported in COVID-19 disease and other concomitant serious infections. The expected DKA mortality in non-COVID-19 patients with a confirmed diagnosis is approximately 3% to 8%<sup>1</sup>, with the small case series reporting a mortality rate of up to 50% in patients with COVID-19.<sup>2</sup> Herein, a case of DKA caused by COVID-19 infection was discussed.



## Case Report

A 71-year-old female patient with a known diagnosis of type 2 diabetes mellitus, whose blood sugar was not regulated, was admitted to the emergency service with weakness and general condition deterioration. On physical examination, she had clouding of consciousness. There were no rales and rhonchi on auscultation of the lung sounds. On abdominal palpation no rigidity or rebound tenderness was spotted. Oxygen saturation in room air was 97%. The patient had sinus tachycardia and was prone to hypertension. Arterial blood pressure was 140/75 mmHg, heart rate was 123 bpm. There was severe metabolic acidosis with increased anion gap in the obtained venous blood gas sample. The pH was 6.8, the bicarbonate was 5 mmol/L. There was leukocytosis in the laboratory examinations on arrival. D-dimer 4.12 mg/L, blood glucose 740 mg/dL, creatinine 2.04 mg/dL, sodium 121 mmol/L, potassium 5.39 mmol/L, chlorine 88 mmol/L, C-reactive protein (CRP) 1.60 mg/dL, and hemoglobin A1c were obtained as 15.4%. In the complete urinalysis, glucose and ketone were 3+. After the patient's COVID-19 rapid antigen test was positive. Polymerase chain reaction (PCR) test was taken and it was confirmed that the patient was positive for COVID-19. The patient was not vaccinated against COVID-19. Low-dose thoracic computed tomography (CT) revealed bilateral mild ground-glass infiltrates (*Image 1*).

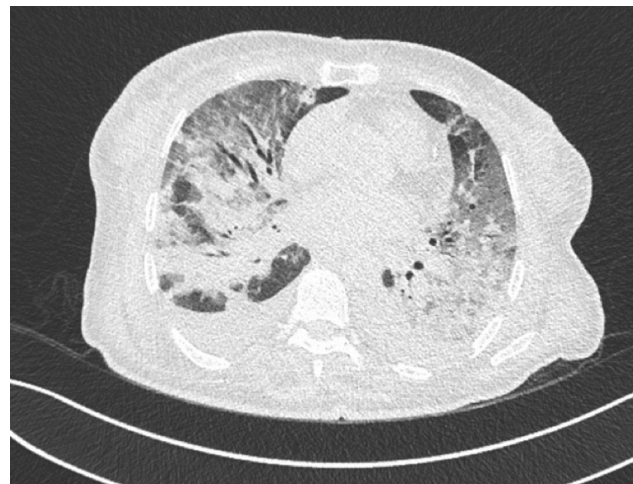

**Image 1.** Low dose thoracic CT, dated 28.09.2022.

Aggressive hydration, bicarbonate infusion and insulin infusion were started to the patient. Blood glucose, blood gases, electrolyte and kidney function tests were obtained with short intervals. During the close follow-ups, the metabolic acidosis of the patient, who was not desaturated in room air, was conscious and oriented, cooperative, and normouric, regressed, and the creatinine value decreased to 1.12 mg/dL. The patient, whose general condition and ketoacidosis improved, was followed up with COVID-19 supportive treatment and steroid treatment. Insulin infusion was stopped and quadruple subcutaneous insulin therapy was started. However, on the 9th day of the COVID-19 infection, the patient whose oxygen demand increased, was transferred to the intensive care unit and intubated (*Image 2*). The patient, who was intubated for 23 days, was then transferred to the internal medicine ward and was discharged 52 days after her first hospitalization, due to her general condition improving.

## Discussion

Patients with diabetes mellitus are at risk for serious COVID-19 complications. DKA can also be counted as one of these complications. Since it was seen in previous studies that COVID-19 may present with DKA as the first symptom, it should be considered that COVID-19 may cause DKA even in patients who have not been diagnosed with diabetes before. Among DKA admissions during



**Image 2.** Low dose thoracic CT prior to intubation, dated 05.10.2022.

the first wave, 12% had a diagnosis of COVID-19. 6% of admissions with type 1 diabetes, 23% with type 2 diabetes, and 7% with newly diagnosed diabetes had concurrent COVID-19.<sup>3</sup> SARS-CoV-2 infects the pancreas through angiotensin-converting enzyme 2 (ACE2), where it is highly expressed compared to other organs, leading to pancreatic damage with subsequent impairment of insulin secretion and development of hyperglycemia even in non-diabetic patients.<sup>4</sup> Data obtained underline that SARS-CoV-2 infection in diabetic patients is more severe and associated with poor clinical outcomes due to preexistence of comorbidities and inflammation disorders. SARS-CoV-2 infection impairs glucose homeostasis and metabolism in diabetic and non-diabetic patients due to cytokine storm (CS) development, downregulation of ACE2, and direct injury of pancreatic  $\beta$ -cells.<sup>4</sup> SARS-CoV-2 infection leads to dysregulation of insulin homeostasis, induction of apoptosis-associated signaling pathways, along with cell apoptosis, mainly in  $\beta$ -cells. These key observations support a mechanism through which SARS-CoV-2 can directly drive  $\beta$ -cell damage to cause clinical type 1 diabetes linked to hyperglycemia.<sup>5</sup> These factors are thought to have a role in the worsening of pancreatic beta cell function and the emergence of DKA in our patient.

Corticosteroids used in the management of COVID-19 infection aggravate hyperglycemia, complicating glycemic control in DKA. In our patient, 250 milligrams of methylprednisolone was started during the course of COVID-19, which resulted in the patient becoming hyperglycemic again and DKA redeveloping. Therefore, close follow-up with frequent blood gas control should be provided in patients whom glycemic control can not be achieved. Cases of COVID-19 presenting with DKA is rare in the literature and its pathogenesis has not been fully elucidated. In this case, we wanted to draw attention to the fact that COVID-19 may present with DKA.

### **Acknowledgment**

This study has been presented in 18<sup>th</sup> Uludag Internal Medicine National Winter Congress, 7<sup>th</sup> Bursa Family Medicine Association National Congress, 12<sup>th</sup> Uludag Internal Medicine Nursing Congress, 3-6 March 2022, Bursa, Turkey.

### **Conflict of interest**

The authors declared that there are no potential conflicts of interest with respect to the research, authorship, and/or publication of this article.

### **Authors' Contribution**

Study Conception: IBG, SEY; Study Design: IBG, SEY; Supervision: YO, IBG; Materials: BO, YO; Data Collection and/or Processing: BO, YO; Statistical Analysis and/or Data Interpretation: IBG, SEY; Literature Review: BO, YO; Manuscript Preparation: SEY, IBG; Critical Review: BO, YO.

### **References**

1. Pasquel FJ, Tsegka K, Wang H, Cardona S, Galindo RJ, Fayfman M, Davis G, Vellanki P, Migdal A, Gujral U, Narayan KMV, Umpierrez GE. Clinical outcomes in patients with isolated or combined diabetic ketoacidosis and hyperosmolar hyperglycemic state: A retrospective, hospital-based cohort study. *Diabetes Care*. 2020 Feb;43(2):349-57. doi: 10.2337/dc19-1168.
2. Pal R, Banerjee M, Yadav U, Bhattacharjee S. Clinical profile and outcomes in COVID-19 patients with diabetic ketoacidosis: a systematic review of literature. *Diabetes Metab Syndr*. 2020 Nov-Dec;14(6):1563-9. doi: 10.1016/j.dsx.2020.08.015.
3. Vellanki P, Umpierrez GE. Diabetic ketoacidosis risk during the COVID-19 pandemic. *Lancet Diabetes Endocrinol*. 2021 Oct;9(10):643-4. doi: 10.1016/S2213-8587(21)00241-2.
4. Al-Kuraisy HM, Al-Gareeb AI, Alblihed M, Guerreiro SG, Cruz-Martins N, Batiha GE. COVID-19 in relation to hyperglycemia and diabetes mellitus. *Front Cardiovasc Med*. 2021 May 20;8:644095. doi: 10.3389/fcvm.2021.644095.
5. Wu CT, Lidsky PV, Xiao Y, Lee IT, Cheng R, Nakayama T, Jiang S, Demeter J, Bevacqua RJ, Chang CA, Whitener RL, Stalder AK, Zhu B, Chen H, Goltsev Y, Tzankov A, Nayak JV, Nolan GP, Matter MS, Andino R, Jackson PK. SARS-CoV-2 infects human pancreatic  $\beta$  cells and elicits  $\beta$  cell impairment. *Cell Metab*. 2021 Aug 3;33(8):1565-76.e5. doi: 10.1016/j.cmet.2021.05.013.

