

## Endovascular embolisation of a hepatic pseudoaneurysm causing massive hemorrhage after a blunt hepatic trauma

Künt karaciğer travması sonrası masif kanamaya neden olan hepatic pseudoanevrizmanın endovasküler embolizasyonu

Suha AKPINAR

### ABSTRACT

Hepatic artery pseudoaneurysm is an uncommon and a late complication after a blunt hepatic trauma. Although hepatic artery pseudoaneurysms may stay silent, it is usually better to treat them due to the high hemorrhage risk they cause. We are presenting a patient with post traumatic hepatic laceration who had serious bleeding with late onset after percutaneous drainage of the old hematoma. On a multidetector computerised tomography (MDCT) scan, a large hematoma surrounding a pseudoaneurysm was diagnosed which was treated with endovascular cyanoacrylate (glue) embolisation.

**Key words:** Hepatic trauma, Hepatic artery pseudoaneurysm, Embolisation, Cyanoacrylate

### ÖZET

Hepatic arter psödoanevrizması künt karaciğer yaralanmasının nadir ve geç oluşan bir komplikasyonudur. Hastalık genellikle asemptomatik olarak seyretmektedir. Hepatik arter psödoanevrizmaları sessiz seyredebileceği gibi yüksek hemoraji riski taşımaları nedeniyle tedavileri tercih edilir. Travma sonrası karaciğer laserasyonu sonrasında, lizise uğramış hematoma boşaltılmasının ardından ortaya çıkan ciddi kanama olgusunu sunuyoruz. Çok kesitli bilgisayarlı tomografi (ÇKBT) incelemesinde hepatic arter psödoanevrizmasını çevreleyen büyük hematoma saptanmış olup, endovasküler siyanoakrilat (glue) embolizasyon ile tedavi edilmiştir.

**Anahtar kelimeler:** Karaciğer travması, Hepatik arter psödoanevrizması, Embolizasyon, Siyanoakrilat

### Introduction

Hepatic artery pseudoaneurysm is a rare and late complication after blunt abdominal trauma.

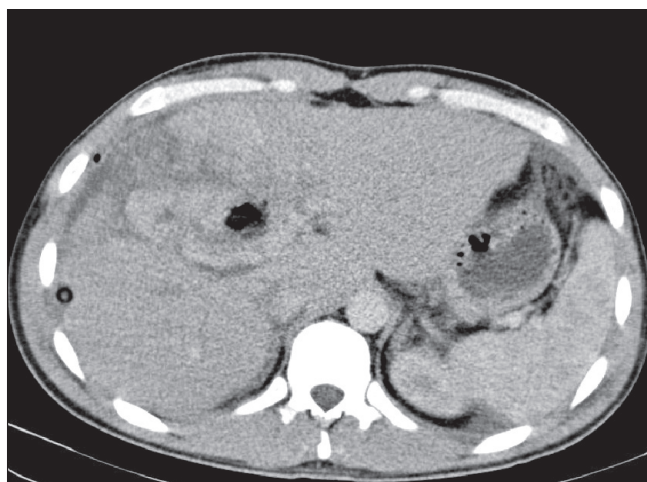
As such pseudoaneurysms are usually silent, diagnosis is frequently delayed. Hepatic artery pseudoaneurysms can be spotted either by multidetector computerized tomography (MDCT), angiography or by a selective digital subtraction angiography (DSA) scan. After the introduction into clinical practice of percutaneous embolization and selective catheterization, the need for surgical intervention has substantially decreased. We report the case of a twenty five year old male with a history of hepatic trauma. A subcapsular hematoma was diagnosed and the patient was followed after the hematoma had been depacked, it was drained by a percutaneous drainage catheter. After this procedure, fresh blood was noticed draining from the catheter. Enhanced multidetector computerized tomography (MDCT) was obtained and this confirmed the presence of a pseudoaneurysm originating from the right hepatic artery. The lesion was selectively catheterized by arteriography and managed with endovascular embolization.

### Case Report

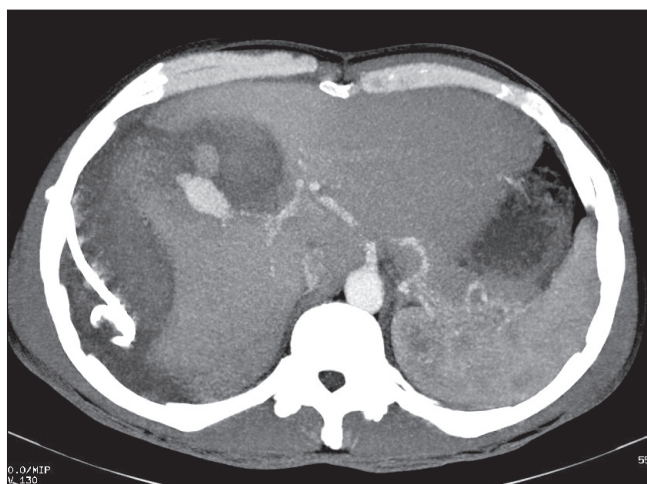
A 25-year-old male patient was brought to the emergency room with a compromised haemodynamic state with blood pressure of 90-50 mm Hg following a traffic accident. MDCT revealed Grade 4 hepatic lacerations at segments 5-8 and the patient underwent immediate surgical laparotomy [1]. Hepatic lacerations extended mainly from the anterior segment of the right lobe to the gall bladder bed (Figure 1). At the operation the gall bladder was resected, hepatic haemostatic sutures were placed and dense packing was applied to the severely bleeding sites. Abdominal drains were inserted. After eight hours, a new packing had to be

Suha Akpınar (✉)  
Radiology Department, School of Medicine, Near East University,  
Lefkosa, Northern Cyprus.  
Radiology Clinic, Burhan Nalbantoğlu State Hospital, Lefkosa, Northern  
Cyprus.  
e-mail: akpinarsuha@hotmail.com

Submitted/Gönderme: 21.08.2013 Accepted/Kabul: 22.09.2013



**Figure 1.** Initial MDCT scan of the multifocal hepatic laceration.



**Figure 2.** MDCT scan which shows the hepatic artery pseudoaneurysm with surrounding hematoma.

due to the increasing signs of rebleeding. After three days postoperatively the patient was stable and depacking was applied. The patient was doing quite well for one month on the follow-ups. However, after this follow up, abdominal ultrasonography revealed a loculated hematoma extending from the lacerated segments laterally. Under ultrasonographic guidance, an external 10 Fr pigtail drainage catheter was placed at the lysed hematoma pouch. During the first two days a total of 800 cc of lysed hematoma fluid was drained from the side of the hematoma and the drainage continued at the output rate of 100ml/day for the following 5 days. On the eighth day, abundant bleeding from the catheter had started and caused a 3 point drop of the hemoglobin level. As the patient's vital conditions were deteriorating slowly, he had a control MDCT scan with contrast. At the biphasic MDCT scan (arterial and portal phase), a hyperdense area in the

right lobe was observed. This finding was suggestive of a pseudoaneurysm with a large hematoma surrounding and compressing the liver parenchyma (Figure 2).

As the bleeding was progressive, the patient underwent diagnostic hepatic artery DSA to clarify the cause of the hemorrhage. According to the DSA, the pseudoaneurysm was located in the right liver lobe and some arteries with segmental stenosis were visible. Active bleeding was noted during the DSA and a 30% diluted cyanoacrylate with lipiodol was injected through a microcatheter to occlude the pseudoaneurysm. On the later control runs the pseudoaneurysm was not filling any longer (Figures 3a,b) and the embolization catheter was withdrawn without any complications. At the follow-up the patient's clinical condition rapidly improved. The patient was sent home after a few days. Monthly ultrasonographic studies showed no relapse of the pseudoaneurysm and no sign of recurrent hematoma.

At the Doppler ultrasonography, arteries showing a high flow pattern were noticed, which were compatible with the segmental stenotic arteries at the traumatized hepatic segments previously noted at the DSA.

## Discussion

Conservative treatment is generally the approach preferred in the treatment of hemodynamically stable patients having blunt hepatic trauma from a blunt object since such treatment has a high success rate of 85-94% [2-4]. In these patients, contrast enhanced CT is the preferred imaging modality. It gives detailed information about the extent of the solid organ involvement, the patient's response to the treatment and about the late onset complications which are the main reasons for morbidity. Hepatic artery pseudoaneurysm is a rare and late onset complication, which is extrahepatic in 80% of the patients, can be best detected at the arterial phase of hepatic MDCT scan, when used as a noninvasive method.

Delayed complications can occur from weeks to months after the trauma. These complications can be summarized as bilioma, delayed hemorrhage, post-traumatic pseudoaneurysm, abscesses and hemobilia [5,6].

Post-traumatic hepatic artery pseudoaneurysms are rare and usually asymptomatic. They are generally discovered by CT or ultrasound during the follow-up. As in our case, pseudoaneurysms can be diagnosed after a late onset of new bleeding which may be life threatening. They should be treated as early as possible because they have a high risk of rupture and are associated with high morbidity [5-7].

Treatment methods include surgery, endovascular embolization at DSA or percutaneous thrombin injection under ultrasonographic guidance [5,8].

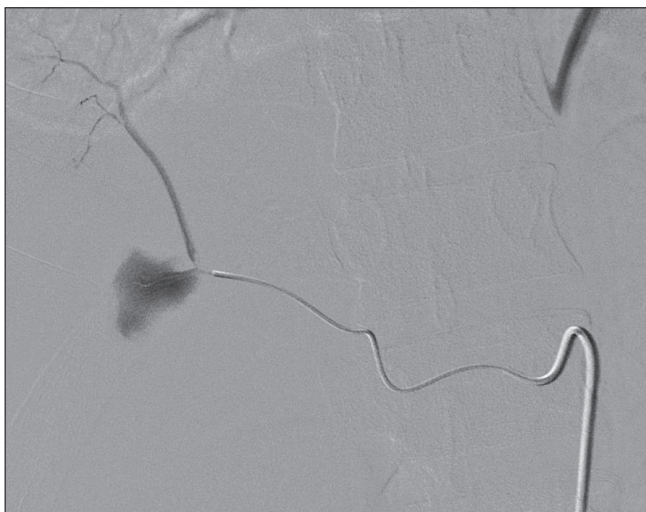


Figure 3a

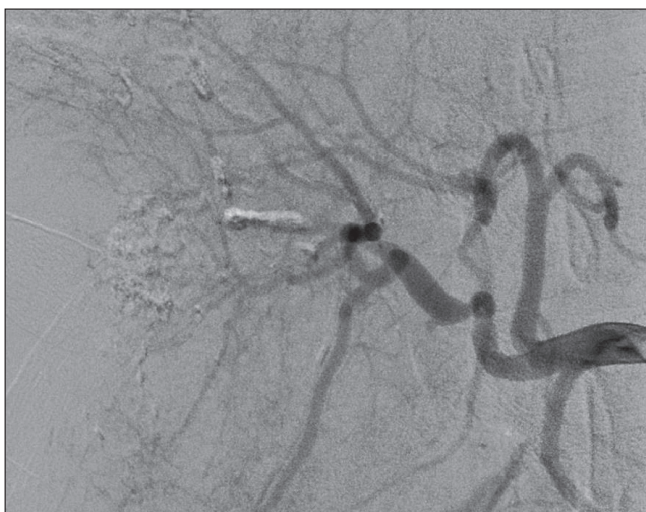

Figure 3b

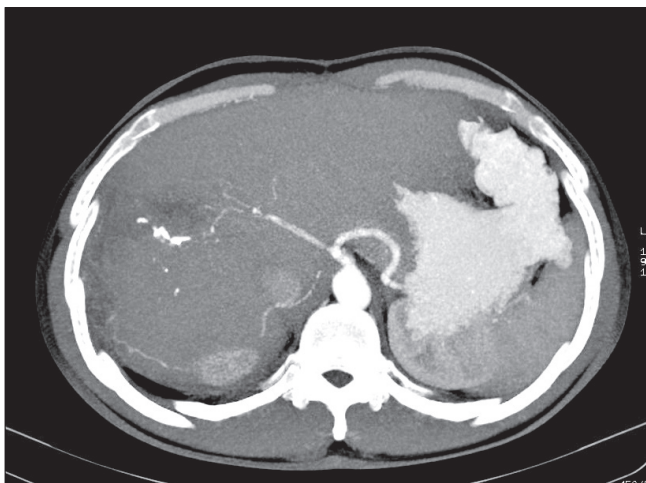


Figure 3c

**Figure 3.** DSA scan showing 3a) Pseudoaneurysm, 3b) Occluded hepatic pseudoaneurysm after endovascular cyanoacrylate embolisation, 3c) MDCT follow up scan 4 months later.

Endovascular approaches or percutaneous thrombin applications are the preferred methods as they can be performed without using general anesthesia. Also avoiding surgical re-operation is an advantage. During endovascular treatment of the pseudoaneurysm, coiling, stenting or glue injection can be used with low recanalisation rates. With the percutaneous method, a puncture is made under sonographic guidance and thrombin is injected to embolize the pseudoaneurysm.

Covered stent placement to the neck of the aneurysm can be an option by itself or after coiling the neck of the pseudoaneurysm [9]. It should be remembered that covered stents are stiff and could be difficult to move to the desired location, especially in traumatized stenotic arteries. Also if there is recanalisation after the deployment, it would be almost impossible to do a coil embolization through the covered walls.

Diluted glue injection with or without coiling can also be performed after catheterizing the lesion with flow control to the pseudoaneurysm. The size of the coils used are determined according to the diameter of the hepatic artery involved and the orifice of the malformation, keeping in mind that coils might migrate to the lumen without causing occlusion.

In our patient, after selective catheterization of the right hepatic artery, we found that the lesion was at the exact location we previously diagnosed at CT scan. Once we reached the orifice of the pseudoaneurysm, after checking the flow dynamics at the actively bleeding vessel, we injected 30% diluted glue (cyanoacrylate) which caused occlusion without any residual filling. On the control runs and on initially weekly then monthly follow-ups, no residual filling or relapse was noted at ultrasonography scans (Figure 3c).

It is safe and easy to apply diluted glue to the vascular arteriovenous fistulas and arterial pseudoaneurysms. We can state that glue embolization is cheap and promising in hepatic artery pseudoaneurysms. Its efficacy for occluding vascular malformations in other organs has also been proved previously [10].

## References

1. Moore EE, Cogbill TH, Jurkovich GJ, Shackford SR, Malangoni MA, Champion HR. Organ injury scaling: spleen and liver (1994 revision). *J Trauma* 1995 ;38:323-4. doi:http://dx.doi.org/10.1097/00005373-199503000-00001
2. Malhotra AK, Fabian TC, Croce MA et al. Blunt hepatic injury: a paradigm shift from operative to nonoperative management in the 1990s. *Ann Surg* 2000;231:804-13. doi: dx.doi.org/10.1097/0000658-200006000-00004
3. Velmahos GC, Toutouzas K, Radin R, et al. High success with nonoperative management of blunt hepatic trauma: the liver is a sturdy organ. *Arch Surg* 2003;138:475-81. doi: dx.doi.org/10.1001/archsurg.138.5.475

4. David Richardson J, Franklin GA, Lukan JK, et al. Evolution in the management of hepatic trauma: a 25-year perspective. *Ann Surg* 2000;232:324–30. doi: [dx.doi.org/10.1097/0000658-200009000-00004](https://doi.org/10.1097/0000658-200009000-00004)
5. Croce MA, Fabian TC, Spiers JP, Kudsk KA. Traumatic hepatic artery pseudoaneurysm with hemobilia. *Am J Surg* 1994;168:235–8. doi: [dx.doi.org/10.1016/S0002-9610\(05\)80193-X](https://doi.org/10.1016/S0002-9610(05)80193-X)
6. Yoon W, Jeong YY, Kim JK, et al. CT in blunt liver trauma. *Radiographics* 2005;25:87–104. doi: [dx.do.org/10.1148/rg.251045079](https://doi.org/10.1148/rg.251045079)
7. Pachter HL, Knudson MM, Esrig B, et al. Status of nonoperative management of blunt hepatic injuries in 1995: a multicenter experience with 404 patients. *J Trauma* 1996;40:31–8. doi: [dx.doi.org/10.1097/00005373-199601000-00007](https://doi.org/10.1097/00005373-199601000-00007)
8. Dambrin C, Marcheix B, Birsan T, et al. Posttraumatic pseudoaneurysm of the hepatic artery: treatment with ultrasound-guided percutaneous transhepatic thrombin injection. *J Trauma* 2005;59:239–42. doi: [http://dx.doi.org/10.1097/01.TA.0000171526.24911.B2](https://doi.org/10.1097/01.TA.0000171526.24911.B2)
9. Paci E, Antico E, Candelari R, Alborino S, Marmorale C, Landi E. Pseudoaneurysm of the common hepatic artery: treatment with a stent-graft. *Cardiovasc Intervent Radiol* 2000;23:472–4. [http://dx.doi.org/10.1007/s002700010107](https://doi.org/10.1007/s002700010107)
10. Kim DJ, Willinsky RA, Krings T, Agid R, Terbrugge K. Intracranial dural arteriovenous shunts: transarterial glue embolization--experience in 115 consecutive patients. *Radiology* 2011 ;258:554-61. doi: [http://dx.doi.org/10.1148/radiol.10100755](https://doi.org/10.1148/radiol.10100755)