



Morphometric and Morphological Evaluation of the Fovea Capitis Femoris

Fovea Capitis Femoris'in Morfometrik ve Morfolojik Değerlendirilmesi

Murat Golpinar

Hitit University, Faculty of Medicine, Department of Anatomy, Çorum, Turkey

Copyright@Author(s) - Available online at www.dergipark.org.tr/tr/pub/medr

Content of this journal is licensed under a Creative Commons Attribution-NonCommercial 4.0 International License.



Abstract

Aim: This study was performed to examine morphometric and morphological characteristics of the fovea for ligament of head of femur (FLHOF) on the dry femur to determine its location and morphological types.

Material and Method: FLHOF was analyzed morphometrically and morphologically on 57 dry adult femora (27 right; 30 left) and their digital images. Dimensions and surface area of the FLHOF were measured using a digital caliper on dry bone and ImageJ software on digital images.

Results: The transverse length of the FLHOF ($p<0.001$) and surface area of the FLHOF ($p=0.007$) were found to be greater in the left femur bones than in the right femur bones. Type 1 localization was the most common localization type of the FLHOF. The most common morphological type was found as oval-shaped FLHOF (43.8%), followed by round (40.4%), triangular (10.5%), and piriform shape types (5.3%).

Conclusion: This study indicates that FLHOF was located mostly posteroinferior quadrant and is usually oval or round in shape. Findings obtained in the present study could provide useful information in both clinical and anthropological practice.

Keywords: Fovea capitis, femur, localization, shape, type

Öz

Amaç: Bu çalışma, fovea capitis femoris'in (FCF) kuru femur üzerindeki morfometrik ve morfolojik özelliklerini incelemek, lokasyonunu ve morfolojik tiplerini belirlemek amacıyla yapılmıştır.

Materyal ve Metot: FCF, 57 yetişkin kuru femur (27 sağ; 30 sol) ve dijital görüntüleri üzerinde morfometrik ve morfolojik olarak analiz edildi. FCF'nin boyutları ve yüzey alanı, kuru kemik üzerinde bir dijital kumpas ve dijital görüntüler üzerinde ImageJ yazılımı kullanılarak ölçüldü.

Bulgular: FCF'nin enine uzunluğu ($p<0,001$) ve FCF'nin yüzey alanının ($p=0,007$) sol uyluk kemiklerinde sağ uyluk kemiklerine göre daha büyük olduğu bulundu. Tip 1 lokalizasyon, FCF'nin en yaygın lokalizasyon tipiydi. En yaygın morfolojik tip oval şekilli FCF (%43,8) olarak bulunurken, bunu yuvarlak (%40,4), üçgen (%10,5) ve piriform (%5,3) tipleri izledi.

Sonuç: Bu çalışma, FCF'nin çoğunlukla posteroinferior kadranda yerleştiğini ve genellikle oval veya yuvarlak olduğunu göstermektedir. Bu çalışmada elde edilen bulgular hem klinik hem de antropolojik uygulamada faydalı bilgiler sağlayabilir.

Anahtar Kelimeler: Fovea capitis, femur, lokasyon, şekil, tip

INTRODUCTION

The fovea of the femoral head (HOF) is a rough fovea of the HOF, which has a strong attachment to the ligament of the head of the femur (LHOF). FLHOF transmits vessels via LHOF for supplying blood to the femoral head. It is regarded as a clinically important anatomical structure as it is closely related to avascular necrosis of the HOF, especially in hip fractures and dislocations.

Morphometric and morphological characteristics of the FLHOF are essential for the surgical approaches for preservation or reconstruction of the injured LHOF due to its relationship with this ligament (1,2). It has been reported that the relationship between the morphometry of the FLHOF and its position with the development of dysplasia and osteoarthritis in the hip joint (3,4). Morphological features of FLHOF may provide useful information in clinical practice for objective evaluation of

Received: 22.04.2022 **Accepted:** 21.05.2022

Corresponding Author: Murat Golpinar, Hitit University, Faculty of Medicine, Department of Anatomy, Çorum, Turkey,

E-mail: muratgolpinar@hitit.edu.tr

the hip joint osteoarthritis and LHOF. Precise information about the position of the FLHOF may help clinicians for the determination of the rotational position of the HOF in femoral neck fractures (5). The FLHOF is an important anatomical structure for proximal femur measurements, radiological evaluation, arthroscopic surgery, and surgical approaches to the hip joint (6-8). The evaluation of the morphology of the FLHOF is also important in anthropological studies, used for sex determination of the individual and distinguishing femur from other long bones (9,10).

Although morphometry, position, and morphological types of the FLHOF are keystones in both clinical and anthropological practice, there have been very few published reports on the morphometric and morphological characteristics of FLHOF. In this study, it was aimed to analyze the morphology and morphometry of the FLHOF on the preserved dry femur to determine its precise position, size, and morphological shape in the HOF.

MATERIAL AND METHOD

Morphometric and morphological measurements were performed on 57 preserved adult femora with unknown sex and age (27 right and 30 left). The bones were collected from the Anatomy Department of Hitit University, Çorum. Samples with deformity of the proximal femur were not included in the study. Morphometric and morphological measurements of the FLHOF performed in the present study were described previously (11,12). The dimensions, location, and morphological types of the FLHOF were analyzed from digital images and dry femur. A digital camera (Canon, Inc, Tokyo, Japan) was used to obtain mediolateral images of the femur bone. The femur bones were placed on the horizontal table by means of both greater trochanter and lesser trochanter were in contact with the table surface. Reference scale bar was placed next to femur bones for calibration of the measurements. The mediolateral images were obtained by taking photos of the femoral head from medial view. All measurements were performed using ImageJ, which is distributed for free by the United States National Institute of Health. Longitudinal length, transverse length, depth, and surface area of the FLHOF was measured (Figure 1). The longitudinal length of FLHOF was measured as the longest diameter of the fovea. The transverse length of FLHOF was measured as the short diameter of the fovea. The depth of the FLHOF was measured by a digital caliper on dry bones. Surface areas of the HOF and FLHOF were measured by tracing the boundaries of these structures. For identification of the position of the FLHOF on head of femur, HOF is divided into four equal quadrants by drawing vertical and transverse straight lines which passing through the central point of the femoral head on mediolateral images. The localization of the FLHOF was classified according to its position within the quadrants. Morphological types of the fovea were also determined in oval, circular, triangular, and piriform according to the morphological characteristics of the fovea. Triangular and

piriform morphological types of the FLHOF were identified regarding their geometric appearance (Figure 2). Study data were analyzed using SPSS version 22.0 software (SPSS Inc., Chicago, IL, USA). Categorical variables were analyzed by Pearson's chi-square test. The independent t-test or the Paired t-test was used for comparison of the continuous variables.

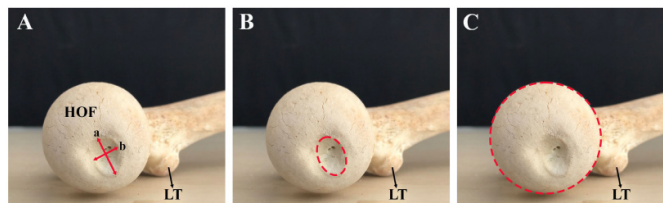


Figure 1. A. The longitudinal length of FLHOF (a); transverse length of FLHOF (b) B. Surface area of FLHOF C. Surface area of HOF. HOF: Head of the femur, LT: Lesser trochanter




Figure 2. Morphological types of FLHOF A. Round (or circular) type B. Oval type C. Triangular type D. Piriform type

RESULTS

Measurement values of the head of the femur and FLHOF are presented in Table 1. The mean longitudinal length, transverse length, and depth of the FLHOF were 15.01 ± 2.13 mm, 10.23 ± 1.52 mm, and 2.71 ± 1.09 mm, respectively. The mean surface area of the HOF and the FLHOF was 1475.35 ± 195.115 mm² and 171.51 ± 45.83 mm², respectively. The transverse length of the FLHOF and surface area of the fovea were observed to be greater in left femora than in right femora ($p < 0.001$ and $p = 0.007$, respectively). No significant differences were found between the right and left femora in terms of longitudinal length, depth, and surface area of the fovea ($p > 0.05$).

The distribution of the types of the fovea in terms of location on the HOF is presented in Table 2. No significant difference was found between the right and left femora in respect of localization of the fovea ($p = 0.212$). Type 1 was the most common localization type of the FLHOF at 45.61%, followed by Type 2 (24.5%) and Type 3 (14.1%). The distribution of the morphological types of the FLHOF is given in Table 3. There was no significant difference between the right and left femora regarding localization types of the FLHOF ($p = 0.550$). The oval type of FLHOF was the most common morphological type of FLHOF at 43.8%, followed by the round type (40.4%). Triangular and piriform types of FLHOF were found % at 10.5 and 5.3%, respectively.

Table 1. Mean and standard deviations (SD) of the femur and FLHOF parameters

Parameters	Side (mean \pm SD)		
	Left (n: 30)	Right (n: 27)	Total (n: 57)
Longitudinal length of the FLHOF (mm)	15.50 \pm 2.20	14.47 \pm 1.93	15.01 \pm 2.13
Transverse length of the FLHOF (mm)	10.88 \pm 1.44	9.51 \pm 1.27	10.23 \pm 1.52
Depth of the FLHOF (mm)	2.84 \pm 1.15	2.56 \pm 1.01	2.71 \pm 1.09
Surface area of the FLHOF (mm ²)	186.53 \pm 49.75	154.81 \pm 34.85	171.51 \pm 45.43
Surface area of the HOF (mm ²)	1491.47 \pm 199.01	1457.44 \pm 192.84	1475.35 \pm 195.11

FLHOF fovea capitis femoris, n number of cases

Table 2. Distribution of the localization types of the fovea capitis femoris (FLHOF)

Side	Localization types of the FLHOF [n (%)]				
	Type 1	Type 2	Type 3	Type 4	Type 5
Left (n:30)	12 (40.0%)	7 (23.4%)	3 (10%)	4 (13.3%)	4 (13.3%)
Right (n:27)	14 (51.85%)	7 (25.9%)	5 (18.51%)	-	1 (3.7%)
Total (n:57)	26 (45.6%)	14 (24.5%)	8 (14.1%)	4 (7.0%)	5 (8.8%)

n number of cases

Table 3. Distribution of the morphological types of the fovea capitis femoris (FLHOF)

	Shape types of the FLHOF [n (%)]			
	Round (or circular)	Oval	Triangular	Piriform
Left (n:30)	10 (33.4%)	15 (50.0%)	4 (13.3%)	1 (3.3%)
Right (n:27)	13 (48.1%)	10 (37.1%)	2 (7.4%)	2 (7.4%)
Total (n:57)	23 (40.4%)	25 (43.8%)	6 (10.5%)	3 (5.3%)

n number of cases

DISCUSSION

The morphometric and morphological characteristics of the FLHOF are crucial in clinical practice (6-8). In the present study, the morphometry, position, and morphological types of the fovea were investigated on dry preserved femora.

There are a few studies in the literature which have investigated the dimensions of FLHOF. Perumal et al. have examined 125 dry isolated femora and reported that the mean longitudinal length and transverse length of the FLHOF were 18mm and 14 mm, respectively. Foveal depth of FLHOF was not evaluated in their study (11). In another study that obtained morphometric measurements from 30 dry femur bones, the length, width, and depth of the fovea of the femur bones were found as 11.17mm, 12.64mm, and 2.80mm, respectively (12). In a recent study by Yazar et al., of the 146 dry femora (146 males, 154 females), the mean longitudinal length, transverse length, and depth of the FLHOF were found to be 15.25mm, 12.00mm, and 2.67mm, respectively (13). The authors reported that there

were no significant differences between right and left femur bones in respect of dimensions of the FLHOF. In this study, longitudinal length, transverse length, and depth of the FLHOF were found as 15.01mm, 10.23 \pm 1.52mm, and 2.71 \pm 1.09mm, respectively, in concordance with previous reports. On the other hand, the transverse length and area of the FLHOF were significantly greater in the left femora than in the right femora. In addition, morphometric features of the FLHOF, right and left side dependent differences in FLHOF morphometry should be taken into consideration when the surgical approach is used in FLHOF of the femur bone. In the present study, we also measured both surface areas of the FLHOF and HOF. Perumal et al. found that areas of the FCF and femoral head were 1.8cm² and 10.5cm², respectively (11). In another study conducted on 212 femur bones, Bertsatos et al. stated that the area of the FLHOF was larger in males than in females (219mm² vs. 177 mm²) (14). Yazar et al. found that areas of the femoral head and FLHOF were 1587.17mm² and 144.43mm², respectively (13). In this study, areas of the femoral head and FCF was

found as 171.51mm² and 1475.35mm². Although our results concur with these findings, in the measurement of the surface area of the FLHOF and HOF, methodological differences between previous reports and our findings are noteworthy.

Previous studies have stated that fovea is located posteroinferiorly on the HOF (2,13,15,16). In our study, in concordance with previous studies, FLHOF was located posteroinferiorly on the femoral head. Although FLHOF was mostly located posteroinferior quadrant of the head of the femoris, in the majority of the cases, the FLHOF was also related a little bit to the other quadrants. In 14 cases, FLHOF was related to the anteroinferior quadrant, while in 8 cases it was related to the posterosuperior quadrant. In 5 cases, with mostly located posteroinferiorly, FLHOF was also related other three quadrants of the femoral head. It was reported that FLHOF is more superior position in dysplastic hips, mostly due presence of increased femoral valgus in this condition (3,17). Perumal et al. found, in 123 of 125 bones, the FLHOF was located on the posteroinferior quadrant of the HOF (11). However, the authors did not state if the fovea had a relationship with the other three quadrants. Yarar et al. reported that type 2 localization of FLHOF was the most common localization type (13). Precise information about the position of the fovea is important for radiological evaluation of the images, and to assist diagnostic hip arthroscopic, especially in patients with absent or completely ruptured LHOF (11). Localization of the fovea could provide useful information for the identification of the rotational position of the head of the femur in the fixation approach in femoral neck fractures (5,18).

LHOF is also called the round ligament or ligamentum teres because the distal end of the LHOF is ovoid or round-shaped (19). Previous reports have shown FLHOF is an oval-shaped structure (15,16). Perumal et al. stated that FLHOF has main three morphological types oval-shaped (65.6%), circular-shaped (28%), and triangular-shaped (6.4%) (11). Eliopoulos et al. defined the shape of the FLHOF according to a femoral index of more than 85 as oval-shaped or round-shaped and a femoral index of less than 70 as irregular-shaped or triangular-shaped (9). The authors determined oval-shaped FLHOF was the most common morphological type at 39.73% by followed round-shaped (37.67%), triangular-shaped (11.64%), and piriform-shaped (10.96%) morphological types. The authors determined oval-shaped FCF was the most common morphological type at 39.73% by followed round-shaped (37.67%), triangular-shaped (11.64%), and piriform-shaped (10.96%) morphological types. We found that the most common morphological types were oval (43.80%) and round types (40.40%) in comparison to triangular (10.50%) and piriform (5.30%) morphological types. Our findings are consistent with the reports of previous studies.

The main limitation of the study is that we were not able to evaluate the FLHOF based on sex, age, and ethnicity as lack of demographic data in the present study. Therefore,

it is required future studies consist of a morphological evaluation of FLHOF on femur bones with known sex, age, and ethnicity for obtaining information on morphometric and morphological characteristics of FLHOF with age and sex.

CONCLUSION

In conclusion, in the present study, we investigated the morphometric and morphological characteristics of FLHOF. Our findings showed that FLHOF is not only located posteroinferior quadrant of the head of the femoris, in most cases, the FLHOF was also related a little bit to the other quadrants. The transverse length and surface area of the FLHOF exhibited right and left sides dependent differences. Oval types were the most common FCA type, followed by round, triangular, and piriform shape types. Detailed information about the localization and morphology of the FLHOF may help distinguish the FLHOF in both radiographic and arthroscopy images. Findings obtained in the present study could provide useful information in both clinical and anthropological practice.

Financial disclosures: *The authors declared that this study hasn't received no financial support.*

Conflict of interest: *The authors declare that they have no competing interest.*

Ethical approval: *The authors declare that the current study on donated cadaver skulls belonging to the Department of Anatomy was carried out in accordance with the 1964 Declaration of Helsinki. There were no human participants in the study or there was no human/animal experimentation, therefore no ethics committee approval.*

REFERENCES

1. Garabekyan T, Chadayammuri V, Pascual-Garrido C, et al. All-Arthroscopic Ligamentum Teres Reconstruction With Graft Fixation at the Femoral Head-Neck Junction. *Arthrosc Tech.* 2016;5:e143-7.
2. Lindner D, Sharp KG, Trenga AP, et al. Arthroscopic ligamentum teres reconstruction. *Arthrosc Tech.* 2013;2:e21-5.
3. Beltran LS, Mayo JD, Rosenberg ZS, et al. Fovea alta on MR images: is it a marker of hip dysplasia in young adults? *AJR Am J Roentgenol.* 2012;199:879-83.
4. Bensler S, Agten CA, Pfirrmann CWA, et al. Osseous spurs at the fovea capitis femoris-a frequent finding in asymptomatic volunteers. *Skeletal Radiol.* 2018;47:69-77.
5. Kurylo JC, Templeman D, Mirick GE. The perfect reduction: approaches and techniques. *Injury.* 2015;46:441-4.
6. Boughton OR, Uemura K, Tamura K, et al. Gender and disease severity determine proximal femoral morphology in developmental dysplasia of the hip. *J Orthop Res.* 2019;37:1123-32.
7. Brady AW, Chahla J, Locks R, et al. Arthroscopic reconstruction of the ligamentum teres: A guide to safe tunnel placement. *Arthroscopy.* 2018;34:144-51.
8. Rego P, Mascarenhas V, Mafra I, et al. Femoral neck

- osteotomy in skeletally mature patients: surgical technique and midterm results. *Int Orthop.* 2021;45:83-94.
9. Eliopoulos C, Murton N, Borrini M. Sexual dimorphism of the fovea capitis femoris in a medieval population from Gloucester, England. *G J Anthropol Res.* 2015;2:9-14.
 10. Scheuer L, Black S, Christie A. *The juvenile skeleton.* Elsevier Academic Press, Amsterdam, 2004.
 11. Perumal V, Woodley SJ, Nicholson HD. The morphology and morphometry of the fovea capitis femoris. *Surg Radiol Anat.* 2017;39:791-8.
 12. Tokpınar A, Yılmaz S, Şükrü A, et al. Morphometric Examination of the Proximal Femur in the Hip Joint. *Experimental Applied Med Sci.* 2020;1:82-8.
 13. Yazar B, Malas MA, Çizmeci G. The morphometry, localization, and shape types of the fovea capitis femoris, and their relationship with the femoral head parameters. *Surg Radiol Anat.* 2020;42:1243-54.
 14. Bertsatos A, Garoufi N, Chovalopoulou M-E. Advancements in sex estimation using the diaphyseal cross-sectional geometric properties of the lower and upper limbs. *Int J Legal Med.* 2021;135:1035-46.
 15. Bardakos NV, Villar RN. The ligamentum teres of the adult hip. *J Bone Joint Surg Br.* 2009;91:8-15.
 16. Cerezal L, Kassarian A, Canga A, et al. Anatomy, biomechanics, imaging, and management of ligamentum teres injuries. *Radiographics.* 2010;30:1637-51.
 17. Nötzli HP, Müller SM, Ganz R. The relationship between fovea capitis femoris and weight bearing area in the normal and dysplastic hip in adults: a radiologic study. *Z Orthop Ihre Grenzgeb.* 2001;139:502-6.
 18. Ceynowa M, Roślowski M, Pankowski R, et al. The position and morphometry of the fovea capitis femoris in computed tomography of the hip. *Surg Radiol Anat.* 2019;41:101-7.
 19. Perez-Carro L, Golano P, Vega J, et al. The ligamentum capitis femoris: anatomic, magnetic resonance and computed tomography study. *Hip Int.* 2011;21:367-72.