



CASE REPORT

MALIGNANT FIBROUS HISTIOCYTOMA OF THE PENIS A CASE REPORT AND REVIEW OF THE LITERATURE

Tufan Tarcan¹, Cenk Murat Yazıcı¹, Sevgi Küllü², Ferruh Şimşek¹

¹Marmara Üniversitesi, Tıp Fakültesi, Üroloji Anabilim Dalı, İstanbul, Türkiye ²Marmara Üniversitesi, Tıp Fakültesi, Patoloji Anabilim Dalı, İstanbul, Türkiye

ABSTRACT

Penile malignant fibrous histiocytoma is an extremely rare tumor. To the best of our knowledge, we present here the fifth primary malignant fibrous histiocytoma of the penis. The patient presented with lung metastasis which initially responded well to systemic chemotherapy with Adriamycin and Ifosfamide, but recurred soon after. The local lesion did not respond to chemotherapy and the patient had to undergo a palliative penectomy. The disease progressed rapidly and the patient died one year after the diagnosis.

Keywords: Penis, Malignant fibrous histiocytoma, Sarcoma

PENİSİN MALİGN FİBRÖZ HİSTİOSİTOMU; VAKA SUNUMU VE LİTERATÜR DERLEMESİ

ÖZET

Penisin malign fibroz histiositomu, oldukça ender görülen bir tümördür. Bizim bilgimize göre, bu vaka sunumunda, literatürdeki beşinci primer penil malğn fibröz histiositom olgusu sunulmaktadır. Hasta, Adriamisin ve İfosfamid sistemik kemoterapisine önceleri iyi cevap veren ancak sonrasında tekrarlayan akciğer metastazları ile kliniğimize başvurdu. Lokal lezyon kemoterapiye yanıt vermediğinden, palyatif penektomi uygulandı. Hastalık oldukça hızlı bir şekilde ilerledi ve hasta tanı konulduktan bir sene sonra kaybedildi.

Anahtar Kelimeler: Penis, Malign fibröz histiositom, sarkom

INTRODUCTION

Penile soft tissue tumors are very uncommon and have a wide spectrum from malignant to benign features, commonly originating from vascular, neurogenic or myogenic tissues¹⁻⁴. The incidence of penile cancer was reported to be 0.6-1/100.000 and only % 5 of these tumors were mesenchymal tumors⁵. Although malignant fibrous histiocytoma is the most

common soft tissue sarcoma in late adult life, primary involvement of the genitourinary tract is very rare. Because of the rarity of such tumors, there is no agreement concerning the best method for staging and managing these patients⁶. To the best of our knowledge, this is the fifth report of a malignant fibrous histiocytoma of the penis.

Corresponding author:

Cenk Murat Yazıcı, M.D.

Marmara Üniversitesi, Tıp Fakültesi, Üroloji Anabilim Dalı Altunizade, İstanbul, Türkiye

e-mail: drcenk yazici@yahoo.com

Marmara Medical Journal 2009;22(2);134-137



CASE REPORT

A 65-year old, circumcised, healthy male patient presented in February 1995 with a 3x3 cm painful soft and progressively enlarging mass on the middle-dorsum of the penis. It first appeared as a small nodule 6 months before the patient was admitted. There was no history of venereal disease and the patient was anti-HIV negative. The ultrasonography revealed a solid mass of heterogeneous echogenity localized under the tunica albuginea along the right corpus cavernosum. It was diagnosed as an organized hematoma since the penile skin was intact and the lesion was well demarcated. On surgical exploration, a dark-yellow lipomatous soft tissue protruded underneath the incision of grossly intact tunica albuginea. A tumor appeared to invade the whole corpus cavernosum on the right side (Figure 1). The operation was terminated when the frozen section of the incisional biopsy revealed malignant soft tissue sarcoma.

Further evaluation of the patient with thoraco-abdomino-pelvic computerized tomography revealed multiple pulmonary metastases. On histopathological examination, a neoplasm composed of fusiform cells with bizarre nuclei and prominent nucleoli with areas of mixoid stroma and storiform pattern was seen (Figure 2). Immunohistochemically, the lesion was negative cytokeratin, S-100 and Desmin. As it was both vimentin and alpha-1 antichymotripsin positive, it was interpreted as a malignant fibrous histiocytoma. Systemic chemotherapy was initiated with Adriamycin (50 mg/m^2) i.v. on day 1 and Ifosfamide (5000 mg/m^2) i.v. continuous over 24 hours with Mesna protection cycling every 21 days. After 6 cycles of chemotherapy, the metastatic lesions in the lung decreased significantly in size. so that only some milimetric lesions were apparent on a CT scan. However, there was no change in the penile lesion. The patient underwent a palliative penectomy which revealed positive surgical margins. Just after penectomy the disease recurred in the pelvis and in the lungs and the patient died soon after, before chemotherapy could be initiated again.

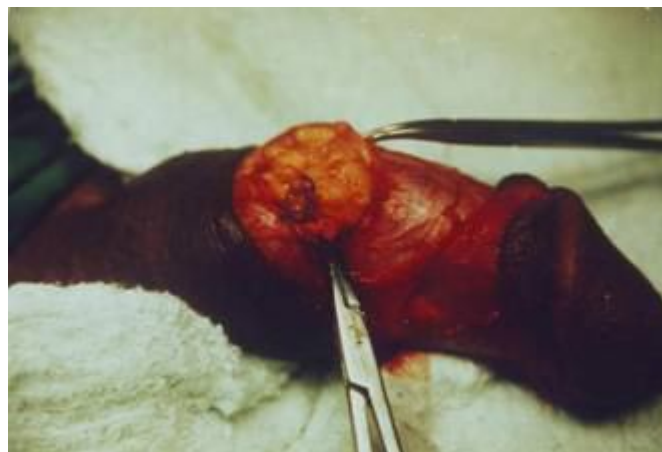

Figure 1: A right sided dark-yellow lipomatous soft tissue under the intact tunica albuginea.

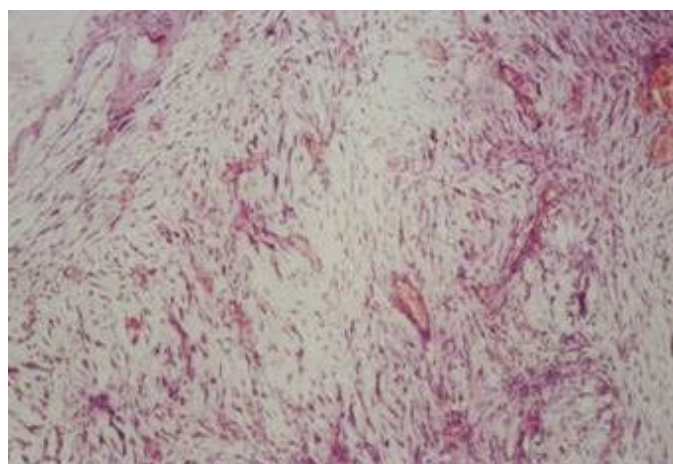


Figure 2: Hematoxylen + Eosin sections of the tumor (200x). Fusiform cells with bizarre nuclei and prominent nucleoli with areas of mixoid stroma and storiform pattern.

DISCUSSION

Malignant mesenchymal tumors of the penis are extremely rare. Ashley and Edwards reported 20 endotheliomas of erectile tissue, 19 fibrosarcomas, 7 Kaposi's sarcomas, 6 myosarcomas and 3 undifferentiated sarcomas in 1957¹. In the period between 1958 and 1969, 10 additional cases were reported from different centers with 4 leiomyosarcomas, 2 unclassified sarcomas, 1 fibrosarcoma, 1 hemangioendothelioma, 1 embryonal rhabdomyosarcoma and 1 myxosarcoma^{2-4,7-13}.



Dehner and Smith reviewed an additional 46 cases with primary mesenchymal penile tumors which appeared in the files of the Armed Forces Institute of Pathology during a 25-year period. 22 of the tumors were malignant¹⁴. A nontender mass was the most common presenting symptom. The age at diagnosis ranged between 2 and 83 years, and between 5 days and 47 years in the group of malignant and benign tumors, respectively. There were 19 vascular tumors representing the largest single group in this series including 12 benign and 7 malignant tumors. Neurogenic tumors were the next most frequent neoplasms with 8 benign and 2 malignant tumors. There were 6 neoplasms composed of smooth muscle which were malignant in half of the cases. The series also included 4 fibrous tumors, 2 primary malignant lymphomas and 5 malignant unclassified neoplasms. Considering all malignant tumors there were only two patients with radiologically detected metastasis in the lungs. The most common site was the penile shaft in 21 patients (46%), followed by glans penis in 17 patients (37%). Malignant neoplasms showed a tendency to be located on the penile shaft in 64% of the cases.

Malignant mesenchymal tumors of the penis can be classified as superficial or deep tumors, according to the tissues from which they derive¹⁵. Superficial lesions rarely reach deep tissues, are usually low-grade and show a small tendency to distant metastases. On the other hand, deep tumors which originate from the glans, smooth muscle of the spongy and cavernous bodies represent more aggressive behavior and have poorer prognosis¹⁶. Although these tumors are very rare, some characteristics such as recurrence and the metastatic dissemination of penile sarcomas have been well established. Local recurrence is a frequent phenomenon and the most frequent sites for distant metastases are the lungs, liver and brain¹⁷⁻¹⁹.

Malignant fibrous histiocytoma accounts for 10 to 22% of all soft tissue sarcomas in late adult life²⁰. The primary site of the tumor is located in an extremity in 71% of cases with

less common primary site locations including retroperitoneum, trunk, bone, head and neck²¹. Primary involvement of the genitourinary tract is very rare²⁰. The first malignant fibrous histiocytoma of the penis was reported by Fletcher and Lowe in 1984²². This was a 62-year-old man who presented with a painful ulcerated mass, on the dorsal surface of the foreskin. The adjacent glans and shaft of the penis were not affected by the tumor. He was treated with radiotherapy, but had to undergo partial penile amputation because of the local recurrence 1 year later. He died 7 years after the diagnosis from an irrelevant disease. Four years later, Parsons et al reported another case of penile malignant fibrous histiocytoma with multiple soft tissue metastasis. Their patient was a 77-year-old who admitted to hospital with toxemia and penile urethra obstruction and died 6 days after admission to hospital²³. In 1990, another case of malignant fibrous histiocytosis located at glans was reported by Moran et al. The patient was 57 years old and died 6 months after penectomy²⁴.

To the best of our knowledge, our case is the fifth malignant fibrous histiocytoma of the penis in the literature and the second who presented with lung metastasis. The disease progressed in spite of the chemotherapy and the patient died 1 year after the initial diagnosis.

Acknowledgment

We would like to thank Prof. Sharon W. Weiss, MD, (Department of Pathology, University of Michigan School of Medicine, USA) for her kind efforts in reviewing the pathological slides and Prof. Gerrit Stoter, MD (Rotterdam Cancer Institute, Rotterdam, Netherlands) for his kind assistance in consulting the case.

REFERENCES

1. Ashley DJB, Edwards EC. Sarcoma of the penis. *Brit J Surg* 1957; 45:170-179.
2. Bakhen CL, Hanna A, Seybold HM. Leiomyosarcoma of the penis. *J Urol* 1968; 99:769-771.
3. Chaudhuri S, Balasubrahmanyam M. Leiomyosarcoma of the penis: A case report. *Indian J Path Bact* 1966; 9:278-284.



4. Fagundes LA, Hampe O, Brentana L, Johann D. Leiomyosarcoma of the penis: A case report. *J Urol* 1962; 88:803-805.
5. Dehner LP, Smith BH. Soft tissue tumors of the penis. A clinicopathologic study of 46 cases. *Cancer* 1970; 25: 1431-1447.
6. Alberto AA, Luciano J. Deep-seated sarcomas of the penis. *Int Braz J Urol*. 2005; 31: 245-250.
7. Fraser GA. Myxosarcoma of the penis: A case report. *Brit J Urol* 1965; 37:465-467.
8. Kovacs J, Crouch RD. Sarcoma of the penis. *J Urol* 1958; 80:43-45.
9. Pack GT, Trinidad SS, Humpreys GA. Primary leiomyosarcoma of the penis: report of a case. *J Urol* 1963; 89:839-840.
10. Ramos JZ, Pack GT Primary embryonal rhabdomyosarcoma of the penis in a 2-year old child. *J Urol* 1965; 96:928-932.
11. Sundell B. Polymorphous -called sarcoma of the penis: report of a case. *J Urol* 1961; 86:612-613.
12. Tripathi VNP, Dick VS. Primary sarcoma of the urogenital system in adults. *J Urol* 1969; 101:898-904.
13. Zaffagnini V. Il sarcoma del pene. Contributo anatomo-clinico e sintesibibliografica. *Arch Ital Anat Istol Pat* 1963; 37:322-339.
14. Dehner LP, Bruce HC. Soft tissue tumors of the penis: A clinicopathological study of 46 cases. *Cancer* 1970; 25:1431-1447.
15. Pratt RM, Ross RT. Leiomyosarcoma of the penis. A report of a case. *Br J Surg* 1969; 56: 870-872.
16. Trojani M, Contesso G, Coindre JM, et al. Soft-tissue sarcomas of adults; study of pathological prognostic variables and definition of a histopathological grading system. *Int J Cancer* 1984; 33: 37-42.
17. Webber RJ, Alsaffar N, Bissett D, Langlois NE. Angiosarcoma of the penis. *Urology* 1998; 51: 130-131.
18. Lynch Jr. DF, Pettaway CA. Tumors of the Penis. In: Walsh PC, Retik AB, Vaughan Jr. ED, Wein AJ, eds. *Campbell's Urology*, 8th ed. Philadelphia, WB Saunders: 2002: 2945-2981.
19. Antoneli CB, Novaes PE, Alves AC, Cardoso H, Lopes A. Rhabdomyosarcoma of the penis in a 15-month-old boy. *J Urol* 1998; 160: 2200-2201.
20. Egawa S, Toyooki U, Koshiba K, Kagata Y, Iwabuchi K: Malignant fibrous histiocytoma of the bladder with focal rhabdoid differentiation. *J Urol* 1994; 154-156.
21. Leite C, Goodwin JW, Sincivics JG, Baker LH, Benjamin R. Chemotherapy of malignant fibrous histiocytoma: A Southwest Oncology Group report. *Cancer* 1977; 40:2010-2014.
22. Fletcher CDM, Lowe D. Inflammatory fibrous histiocytoma of the penis. *Histopathology* 1984; 8:1079-1084.
23. Parsons MA, Fox M. Malignant fibrous histiocytoma of the penis. *Eur Urol* 1988;14:75-76.
24. Moran CA, Kaneko M. Malignant fibrous histiocytoma of the glans penis. *Am J Dermatopathol* 1990;12:182-187.