

Uterine Arteriovenous Malformation: A Case Report and Review of the Literature

Uterin Arteriovenöz Malformasyonu: Olgu Sunumu ve Literatür İncelemesi

Ahmet Göçmen¹ ve Ömer İlker Göçmen²

ÖZET

Özet: Uterin arteriovenöz malformasyon yoğun uterin kanamaya yol açabilen nadir bir anormal uterin kanama sebebidir. 23 yaşında laparoskopik bilateral hipogastrik arter ligasyonu ile başarılı bir şekilde tedavi edilen Arterio Venöz Malformasyonu (AVM) olan bir olguyu sunuyoruz. Bu işlem hastanın fertilitatesini olumsuz etkilemedi ve işlemden 6 ay sonra gebe kaldı ve 38. haftada cesarean section ile doğum yaptı. Daha sonra 2 kez daha sezaryen ile doğum yaptı. Laparoskopik bilateral hipogastrik arter ligasyonu uterin arteriovenöz malformasyon tedavisinde uterin arter embolisine etkili bir alternatiftir.

Anahtar Kelimeler: Uterin arteriovenöz malformasyon, laparoskopik internal iliak arter ligasyonu

ABSTRACT

Summary: Uterine arteriovenous malformation (AVM) is a rare cause of abnormal uterine bleeding, which may lead to profuse uterine bleeding. We present the case of a 23-year-old woman with an AVM that was successfully managed by laparoscopic ligation of the internal iliak arteries. This procedure did not adversely affect the fertility of the patient and she became pregnant 6 months after the procedure and gave birth by cesarean section at 38 weeks. She later gave birth by cesarean section 2 more times.

It is an effective alternative to uterine artery embolization (UAE) in the management of uterine AVM.

Key words: Uterine arteriovenous malformation; laparoscopic internal iliak artery ligation

Geliş Tarihi: 6/03/2022

Kabul Tarihi: 30/05/2022

¹Department of Obstetrics and Gynecology, Ataşehir Medicana Hospital

²Department of Obstetrics and Gynecology, Istanbul Medeniyet University

İletişim: Ahmet Göçmen, M.D.

Department of Obstetrics and Gynecology, Ataşehir Medicana Hastanesi,
Ataşehir/Istanbul, Turkey

Tel: +90 532 287 21 02

E-posta: gocmenahmet@yahoo.com

Introduction

Uterine arteriovenous malformation (AVM) is a rare lesion which may lead to profuse uterine bleeding. Previous curettage, gestational trophoblastic disease, cesarean section, and endometrial neoplasm are the main causes of acquired AVM (1,2). Angiography is the gold standard method to diagnose uterine AVMs. Doppler ultrasound (US), pelvic magnetic resonance imaging (MRI), and hysteroscopy are also useful tools to identify an AVM (3). The usual management options for a patient who desires to preserve fertility are either embolization or ligation of the uterine arteries (4).

Case Presentation

A 23-year-old patient (gravida 1, para 0) was referred to our hospital because of intermittent heavy menstrual bleeding for six months. She had a history of gestational trophoblastic disease one and a half years ago. She was diagnosed with invasive molar disease due to increasing serum β -HCG levels following vacuum curettage without evidence of metastasis that was confirmed by computerized tomography scan of the thorax and

cranial MRI. Two cycles of methotrexate were initially given one week apart (25 mg/m²), with increasing levels of β -HCG. After that, a combined regimen of methotrexate (40 mg/m²) and folinic acid (0.1 mg/kg) was given within a week. However, she developed resistance. Finally, she responded completely to five cycles of multi-drug EMA-CO (etoposide, methotrexate, actinomycin-D, cyclophosphamide, vincristine) chemotherapy. After completion of the treatment, her β -HCG levels were undetectable. Although her β -HCG levels remained undetectable, the patient complained of intermittent profuse uterine bleeding episodes that required packed red blood cell (RBC) transfusions to restore low hemoglobin values. She was admitted to the clinic with life-threatening uterine bleeding six months after chemotherapy. Upon initial examination of the patient, transvaginal US showed a 29 mm \times 25 mm anechoic cystic mass in the posterior Wall of the uterus (Fig.1) and high velocity multi-directional blood flow was demonstrated within the lesion on Doppler examination (Fig.2). She had a hemoglobin value of 4.9 g/dl and four units of packed RBCs were immediately transfused. Contrast-enhanced pelvic MRI revealed hypointense, lobulated formations without evidence of prominent

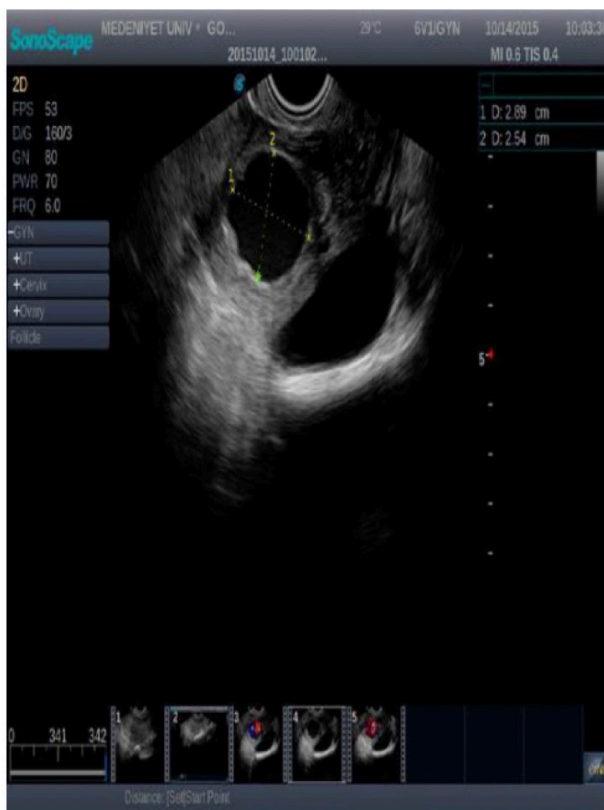

Figure 1. Ultrasound image of the uterine AVM at the time of diagnosis.

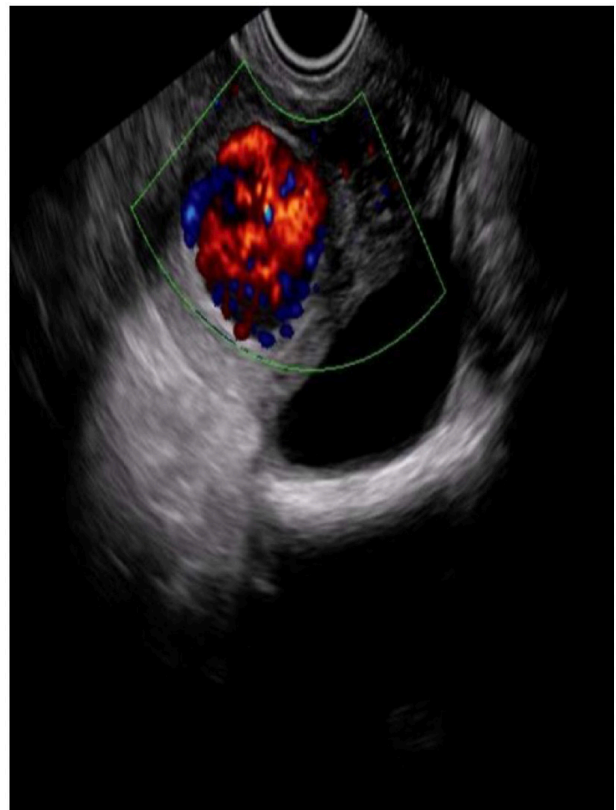

Figure 2. Color Doppler analysis illustrating high velocity multi-directional blood flow within the cystic lesion

contrast involvement on T2-weighted images. Because all of the findings were consistent with an AVM of the uterus, hysteroscopy and laparoscopy were planned. Informed consent about the risks and benefits of the procedures was obtained from the patient. Diagnostic hysteroscopy showed a reticulated mass of vessels, approximately 3 cm in diameter, which protruded from the right posterolateral side of the uterus through the cavity. The mass tended to bleed when it was in contact with the hysteroscopy tip. The hysteroscopy procedure was terminated and then laparoscopy was performed. Ecchymosis on the posterior side of the uterus near the cornual region, suggesting a reflection of the AVM, was seen (Fig 3). Both internal iliac and uterine arteries were occluded with nonresorbable clips on each side during the laparoscopy (Fig.4). The procedure was then completed. One month following the ligation of the internal iliac arteries, she didn't complain of any irregular bleeding. US examination revealed the disappearance of the lesion and color Doppler scan showed no blood flow within the lesion after one month (Fig. 5).

She became pregnant 6 months after the procedure and gave birth by cesarean section at 38 weeks. She later gave birth by cesarean section 2 more times.

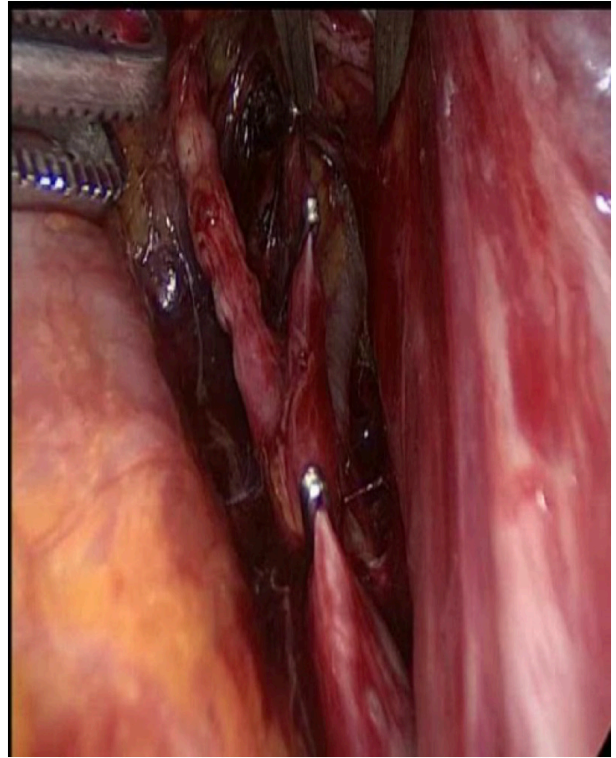


Figure 4. Laparoscopic occlusion of the internal iliac arteries

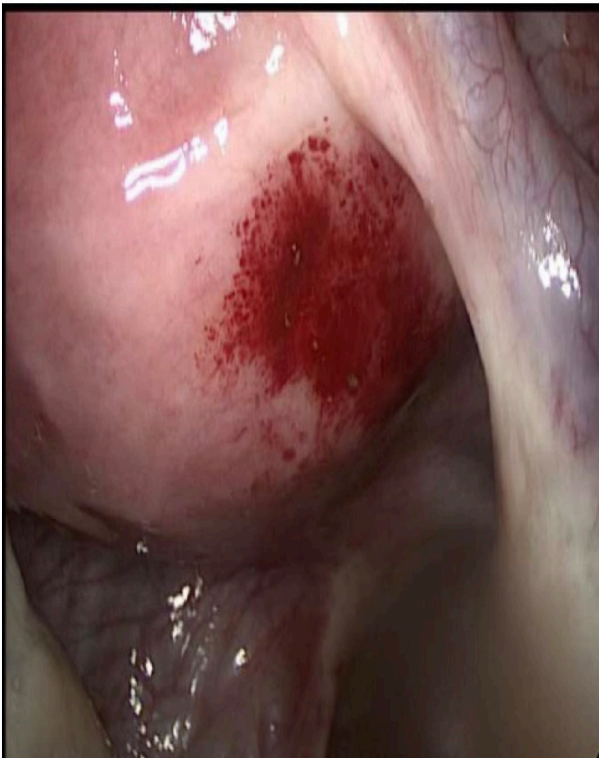

Figure 3. Ecchymosis on the posterior side of the uterus at laparoscopy

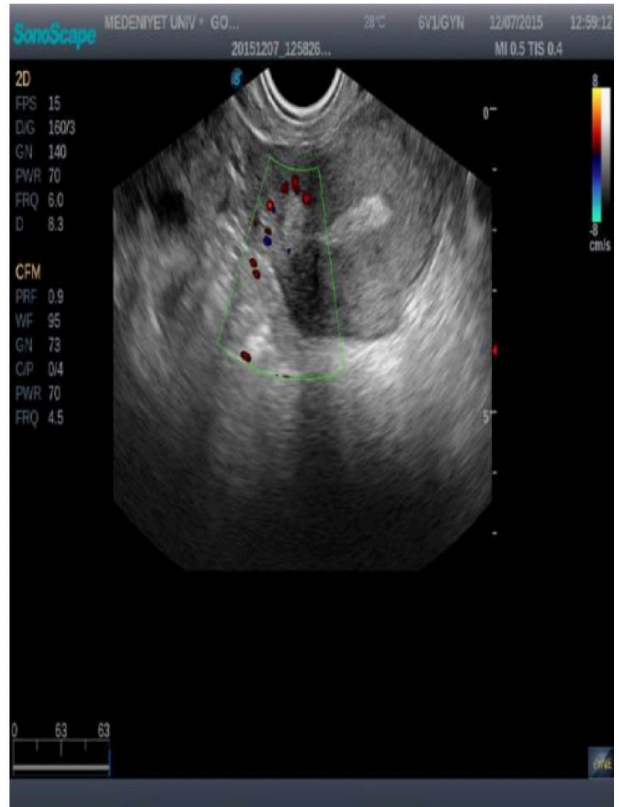


Figure 4. Ultrasound image of the uterus after one month of laparoscopic occlusion of the internal iliac arteries

Discussion

AVM is a rare cause of heavy uterine bleeding, however it should be considered in patients with previous curettage, cesarean section, and gestational trophoblastic disease. Although the gold standard for the definitive diagnosis of AVM is angiographic examination, it can be diagnosed by US and Doppler analysis. The advantage of angiography over other imaging modalities is that it provides information about the extent and precise localization of the lesion. AVM is suspected when heterogeneous cystic areas within the myometrium are seen on US. Tortuous vascular structures on color Doppler with high velocity flow on pulsed Doppler are typical findings of AVM (5). Both T1- and T2-weighted MRI images reveal multiple serpentine flow-related signal voids in the uterine wall and endometrial cavity.

Abnormal vessels enhance as intensely as normal vessels on contrast-enhanced dynamic MR angiography (6).

Historically, hysterectomy was the treatment of choice for women with AVM. With advancing techniques, however, fertility-preserving options have been used for the management of AVM. These include uterine artery embolization (UAE) and laparoscopic ligation of either the uterine or internal iliac arteries (7). In a recent review including 50 patients with AVM secondary to gestational trophoblastic disease, the diagnosis of AVM was made either before starting or after completion of chemotherapy. The overall success rate of UAE in controlling bleeding was 85%.

Seventy percent of patients undergoing UAE were managed on the first attempt, but a second attempt of UAE was necessary to control uterine bleeding in 24% of the patients. Following the diagnosis of AVM, 20 patients achieved pregnancy and most of them gave birth to a healthy baby with an uneventful pregnancy (8). On the contrary, Vilos et al. reported that more than one UAE procedure was required to control bleeding in patients with AVM, and pregnancy-related complications, including pre-eclampsia, intrauterine growth retardation, and chorioamnionitis, developed in most of the patients who became pregnant after UAE. They concluded that UAE as an initial therapy for AVM should be questioned with regard to fertility preservation and pregnancy outcomes (9). Additionally, multiple attempts of UAE to control bleeding in complex large inflow arteries seem to be necessary (10). These cases were successfully managed by bipolar coagulation of the uterine arteries (11,12,13).

Chen et al. described an effective method including laparoscopic occlusion of the uterine arteries and resection of the myometrial lesion when uterine AVM was extensive and multiple (14). As in the present case, laparoscopic ligation of the internal iliac arteries may be considered first because it is found to be successful when UAE fails to control bleeding in women with AVM (7). A recent review reporting fertility outcomes following UAE and internal iliac artery ligation in women with postpartum hemorrhage demonstrates that both are safe options to achieve a pregnancy in women desiring another pregnancy after the procedure. Seventy-five percent of patients achieved conception following UAE, in comparison to 85% of patients undergoing internal iliac artery ligation (15). Although the data concerning postpartum hemorrhage show a trend towards higher pregnancies when managed by ligation of the internal iliac arteries, it has yet to be evaluated in patients with AVM.

To date, there are two reports of cases with AVM (6, the present case) that were successfully treated by laparoscopic ligation of the internal iliac arteries. However, the present case is unique because laparoscopic ligation of the internal iliac arteries was used as a first option to manage AVM. Although UAE is the preferred method, laparoscopic ligation of the internal iliac arteries may be considered first to manage complex AVMs in gynecology clinics with sufficient laparoscopic experience.

Another technique reported to be successful in the management of AVM is balloon-occluded retrograde transvenous obliteration. If there are multiple feeding arteries and a single draining vein, transcatheter occlusion of the uterine vein with a sclerosing agent may be used instead of UAE. Despite the advantages, including preservation of the uterine arteries, prevention of a pulmonary embolism, and less pain after the procedure, this method can't be used in patients having an AVM with multiple sites of venous drainage (16). An alternative approach, percutaneous embolization, has also been reported that could be used successfully in the management of AVM. It includes direct puncturing and coil placement or injection of embolic materials into the nidus of the AVM with a 20-gauge spinal needle under transabdominal Doppler US guidance. This method should only be used in cases with small AVMs, however, because the embolic materials fail to occlude large AVMs.

The advantages of the procedure are its short duration and avoidance of radiation exposure (17). However, there is a need for a large case series to apply this method in the management of AVMs.

Effective medical management options have also been described. Medications used in the management of AVMs are reserved for hemodynamically stable patients and may be appropriate for patients with no history of heavy bleeding. Long-term use of combined oral contraceptives was found to cause the lesions to regress and even disappear (18).

Rosa E. Silva et al. reported that a patient with an extensive, large AVM was successfully treated with continuous combined oral contraceptive use without the need for any invasive management (19). Similarly, treatment with intramuscular followed by oral methylergonovine maleate has been reported to be effective for resolution of a lesion (20). Gonadotropin-releasing hormone (GnRH) agonist has been used as an adjunct to embolization. Long-term use of this medication followed by UAE results in complete resolution of the lesions (21). Nonaka et al. reported disappearance of lesions and spontaneous pregnancy following six months of GnRH agonist treatment without any other intervention (22). Furthermore, GnRH agonist or danazol use successfully managed recurrent episodes of bleeding following UAE and patients remained free from recurrence of the lesion. The authors concluded that these drugs may decrease the need for repeat embolization (23,24). Although a few reports have shown medical agents to be effective in the management of AVMs, there is not enough data to recommend medical treatment in those with AVM.

Conclusion

Laparoscopic ligation of the internal iliac arteries is an effective alternative to UAE in the management of uterine AVM

Kaynaklar

1. Grivell RM, Reid KM, Mellor A. Uterine arteriovenous malformations: a review of current literature. *Obstet Gynecol Surv.* 2005;60: 761–767.
2. Priyank Chatra. Iatrogenic uterine injury leading to uterine arteriovenous malformation *Radiology Case reports* 2021; 2146-50.
3. Cura M, Martinez N, Cura A, Dalsaso TJ, Elmerhi F. Arteriovenous malformations of the uterus. *Acta Radiol.* 2009;50:823-9.
4. Peitsidis P, Manolakos E, Tsekoura V, Kreienberg R, Schwentner L. Uterine arteriovenous malformations induced after diagnostic curettage: a systematic review. *Arch Gynecol Obstet.* 2011;284:1137-51.
5. Müngen E, Yergök YZ, Ertekin AA, Ergür AR, Uçmakli E, Aytaçlar S. Color Doppler sonographic features of uterine arteriovenous malformations: report of two cases. *Ultrasound in Obstetrics & Gynecology* 1997; 10: 215–219
6. Nasu K, Fujisawa K, Yoshimatsu J, Miyakawa I. Uterine arteriovenous malformation: ultrasonographic, magnetic resonance and radiological findings. *Gynecol Obstet Invest.* 2002;53:191-4.
7. Levy-Zaubermann YI, Capmas P, Legendre G, Fernandez H. Laparoscopic management of uterine arteriovenous malformation via occlusion of internal iliac arteries. *J Minim Invasive Gynecol.* 2012;19:785-8.
8. Touhami O, Gregoire J, Noel P, Trinh XB, Plante M. Uterine arteriovenous malformations following gestational trophoblastic neoplasia: a systematic review. *Eur J Obstet Gynecol Reprod Biol.* 2014;181:54-9.
9. Vilos AG, Vilos GA, Hollett-Caines J, Rajakumar C, Garvin G, Kozak R. Uterine artery embolization for uterine arteriovenous malformation in five women desiring fertility: pregnancy outcomes. *Hum Reprod.* 2015;30:1599-605.
10. Hasegawa A, Sasaki H, Wada-Hiraike O, Osuga Y, Yano T, Usman SM, Akahane M, Kozuma S, Taketani Y. Uterine arteriovenous fistula treated with repetitive transcatheter embolization: case report. *J Minim Invasive Gynecol.* 2012;19:780-4.
11. Corusic A, Barisic D, Lovric H, Despot A, Planinic P. Successful laparoscopic bipolar coagulation of a large arteriovenous malformation due to invasive trophoblastic disease: a case report. *J Minim Invasive Gynecol.* 2009;16:368- 71.
12. Yokomine D, Yoshinaga M, Baba Y, Matsuo T, Iguro Y, Nakajo M, Douchi T. Successful management of uterine arteriovenous malformation by ligation of feeding artery after unsuccessful uterine artery embolization. *J Obstet Gynaecol Res.* 2009;35:183-8.
13. Milingos D, Doumplis D, Sieunarine K. Uterine arteriovenous malformation: fertility-sparing surgery using unilateral ligation of uterine artery and ovarian ligament. *Int J Gynecol Cancer.* 2007;17:735–737.
14. Chen SQ, Jiang HY, Li JB, Fan L, Liu MJ, Yao SZ. Treatment of uterine arteriovenous malformation by myometrial lesion resection combined with artery occlusion under laparoscopy: a case report and literature review. *Eur J Obstet Gynecol Reprod Biol.* 2013;169:172-6.
15. Doumouchtsis SK, Nikolopoulos K, Talaulikar V, Krishna A, Arulkumaran S. Menstrual and fertility outcomes following the surgical management of postpartum haemorrhage: a systematic review. *BJOG.* 2014;121:382-8.
16. Kishino M, Miyasaka N, Takeguchi Y, Ohashi I. Retrograde transvenous obliteration for uterine arteriovenous malformation. *Obstet Gynecol.* 2014;123:427-30.
17. Ahmed Y, Davidson J, Azar N. Ultrasound-guided Transcatheter Embolization of Uterine Arteriovenous Fistula

- Performed for Treatment of Symptomatic, Heavy Vaginal Bleeding: Case Report with Brief Review of Literature. *Journal of Medical Ultrasound* 2015;23:146-149.
18. Oride A, Kanasaki H, Miyazaki K. Disappearance of a uterine arteriovenous malformation following long-term administration of oral norgestrel/ethinyl estradiol. *Journal of Obstetrics and Gynaecology Research* 2014;40: 1807– 1810.
 19. Rosa E Silva JC, de Aguiar FM, de Sá Rosa E Silva AC, Candido Dos Reis FJ, Poli Neto OB, Nogueira AA. Conservative management of large uterine arteriovenous malformation: case report. *Fertil Steril*. 2008 Dec;90(6):2406-7.
 20. Khatree MHD, Titiz H. Medical treatment of a uterine arteriovenous malformation. *Aust N Z J Obstet Gynaecol* 1999;39: 378–380.
 21. Morikawa M, Yamada T, Yamada H, Minakami H. Effect of gonadotropinreleasing hormone agonist on a uterine arteriovenous malformation. *Obstet Gynecol*. 2006;108:751-3.
 22. Nonaka T, Yahata T, Kashima K, Tanaka K. Resolution of uterine arteriovenous malformation and successful pregnancy after treatment with a gonadotropin-releasing hormone agonist. *Obstet Gynecol*. 2011;117:452-5.
 23. Takeuchi K, Yamada T, Iwasa M, Maruo T. Successful medical treatment with danazol after failed embolization of uterine arteriovenous malformation. *Obstet Gynecol*. 2003;102:843-4.
 24. Krishnaswamy P, Subbanna I, Sivasambu G, Thukral U. Gonadotropinreleasing hormone agonist and depot medroxyprogesterone acetate following uterine artery embolization in the management of uterine arteriovenous malformation. *Proc Obstet Gynecol*. 2014; 4:12