



## Retrospective Analysis of Metastatic Bone Tumors

### Metastatik Kemik Tümörlerinin Retrospektif Değerlendirmesi


Nazlı Sena ŞEKER<sup>1</sup>

 0000-0003-4588-7250


Funda CANAZ<sup>1</sup>

 0000-0002-5642-3876


Ulukan İNAN<sup>2</sup>

 0000-0002-1903-5516

Mustafa KAVAK<sup>2</sup>

 0000-0002-0280-2088

Özge BÜLBÜL<sup>1</sup>

 0000-0003-3856-1340

<sup>1</sup>Department of Medical Pathology,  
Eskişehir Osmangazi University  
Faculty of Medicine, Eskişehir,  
Türkiye

<sup>2</sup>Department of Orthopedics and  
Traumatology, Eskişehir Osmangazi  
University Faculty of Medicine,  
Eskişehir, Türkiye

Corresponding Author

Sorumlu Yazar

Nazlı Sena ŞEKER

nazlisenardem@gmail.com

Received / Geliş Tarihi : 12.06.2022

Accepted / Kabul Tarihi : 31.10.2022

Available Online /

Çevrimiçi Yayın Tarihi : 10.11.2022

#### ABSTRACT

**Aim:** Bone tissue is the primary organ of hematopoiesis and osteogenesis in healthy individuals. Bone tissue is one of the most frequently metastasized organs. In addition, for all types of cancer, it is an indication that cancer has reached a level where it can no longer be cured and the patient's life expectancy is reduced. The aim of this study was to retrospectively evaluate the cases operated for bone metastasis.

**Material and Methods:** A total of 67 patients who underwent a biopsy or operation due to bone tumors at Eskişehir Osmangazi University Medical Faculty Hospital between January 2020 and January 2022 were included in this study.

**Results:** Of the metastatic cases, 49 (73.1%) were male and 18 (26.9%) were female. The mean age of the patients was 61.7±19.8 (range, 9-88) years. The most frequently metastasized tumors were lung carcinoma and tumor of unknown primary in males, while lung and breast in females. Tumors most frequently metastasize to the spine region. There were 6 (9.0%) cases, 1 (1.5%) of which was mesenchymal, in which the primary origin couldn't be detected in metastatic tumors.

**Conclusion:** Bone pain is always a symptom that is suspicious for metastasis in a patient followed up with a diagnosis of cancer and requires further investigation. Treatment is more palliative after bone metastasis. There is a need for targeted studies to prevent metastasis. It should be kept in mind that the primary focus may not be detected in all clinical and imaging methods in a group of patients.

**Keywords:** Bone neoplasms; neoplasm metastases; unknown primary neoplasm metastases.

#### ÖZ

**Amaç:** Kemik dokusu sağlıklı bireylerde hematopoez ve osteogenezisin primer olarak yapıldığı organdır. Kemik dokusu en sık metastaz alan organlardan biridir. Ek olarak, tüm kanser türleri için kanserin artık iyileşemeyecek bir düzeye ulaştığının ve hastanın beklenen yaşam süresinin kısaldığının bir göstergesidir. Bu çalışmanın amacı, kemik metastazı nedeniyle ameliyat edilmiş olan olguların geriye dönük olarak değerlendirilmesidir.

**Gereç ve Yöntemler:** Ocak 2020 ve Ocak 2022 tarihleri arasında Eskişehir Osmangazi Üniversitesi Tıp Fakültesi Hastanesi'nde kemik tümörü nedeniyle biyopsi yapılan veya ameliyat edilen toplam 67 hasta bu çalışmaya dahil edilmiştir.

**Bulgular:** Metastatik olguların 49 (%73,1)'u erkek ve 18 (%26,9)'i kadın idi. Hastaların ortalama yaşı 61,7±19,8 (aralık, 9-88) yıl idi. En sık metastaz yapan tümörler erkeklerde akciğer karsinomu ve primeri bilinmeyen tümör iken, kadınlarda ise akciğer ve meme karsinomu olarak saptanmıştır. Tümörlerin en sık omurga bölgesine metastaz yaptığı tespit edilmiştir. Metastatik tümörlerin içinde primer odağın saptanamadığı 1'i (%1,5) mezenkimal olmak üzere toplam 6 (%9,0) olgu vardır.

**Sonuç:** Kemik ağrısı kanser tanısı ile takip edilen bir hastada her zaman metastaz açısından şüpheli olan ve ileri tetkik yapılması gereken bir semptomdur. Kemik metastazı sonrasında tedavi daha çok palyatif olmaktadır. Metastazı önlemeye yönelik hedefe yönelik çalışmalara ihtiyaç vardır. Ayrıca bir grup hastada tüm klinik ve görüntüleme yöntemlerine rağmen primer odağın tespit edilemeyeceği de akılda tutulmalıdır.

**Anahtar kelimeler:** Kemik neoplazileri; tümör metastazı; bilinmeyen primer neoplazm metastaz.

## INTRODUCTION

Bone tissue is the primary site of hematopoiesis and osteogenesis in healthy individuals. Bone tissue has a microenvironment called the bone niche, supported by stem cells, progenitor cells, and immune system cells (1). Metastatic cancer is an indication that cancer has become incurable. In addition, the most common cause of cancer-related death is untreatable metastatic cases (2). In metastatic cancer cases, treatment is mostly palliative. However, studies on this subject now show that this situation may change. As the bone metastasis mechanism of cancers is understood, new treatment modalities have begun to emerge (3). Before cancer cells metastasize to bone tissue, they must first be extravasated from their primary environment. As a second step, as a result of the mutual communication of cancer cells and the metastatic bone environment with mediators, cancer cells circulating in the bone are seen first. Then there is a period when cancer stays in a state of silence to survive. When it is reactivated, it first appears with micrometastasis and then with macro metastasis (4). Bone marrow tissue is a very suitable environment for tumor cells to come and settle. Cell types, connective tissue, and signaling mechanisms that create the appropriate environment constitute the “metastatic bone niche” (3). Recent studies are investigating treatments that target signaling mechanisms and support the metastatic bone niche (5).

It was first put forward in the study of Paget in 1889 in breast cancer cases that some tumors show tropism to some organs (6). Breast and prostate cancers show a greater affinity for bone and account for approximately 70% of all cases (7,8).

The most common cause of morbidity in cancer patients is bone metastasis. Complications such as fracture, spinal cord compression, nerve paralysis, hypercalcemia, and suppression of bone marrow function can be seen in cases with bone metastases (9-11). The most common reasons for patients to come to the hospital are bone pain, pathological fracture, and nerve compression (12).

This study, it was aimed to evaluate the cases presenting with metastasis to the bone of known or unknown primary, in the light of clinical and demographic findings.

## MATERIAL AND METHODS

In this study, diagnostic biopsy, curettage, or surgical excision materials of the cases who applied to the clinic of Eskişehir Osmangazi University Medical Faculty Hospital with pathological fracture, bone pain, or incidentally detected bone mass between January 2020 and January 2022 were included. Between these dates, incisional or excisional biopsy was applied to a total of 116 cases for definitive diagnosis. Among these cases, 67 (57.8%) cases diagnosed with metastatic tumors were included in the study. Cases diagnosed as primary bone tumors were not included in the study. Metastatic tumors were divided into epithelial, mesenchymal, and hematological malignancies according to the cell of origin. Epithelial, mesenchymal, and hematological malignancies other than primary bone tumors were included in the study. All neoplasms with the known or unknown primary focus, metastasizing to the bone, were evaluated in the study. Biopsy was not taken from the cases that were clinically and radiologically

certain for metastasis. Therefore, they were not included in this study. Demographic data of the cases included in the study were obtained from the pathology reports. The clinical data of the cases were obtained from the patient files of the Orthopedics and Traumatology department. The clinical pre-diagnosis of the cases, whether the primary focus was known during the operation, and whether the primary focus was detected later were recorded.

This study was approved by the Eskişehir Osmangazi University Non-Invasive Clinical Research Ethics Committee with decision number 18 on 26.04.2022.

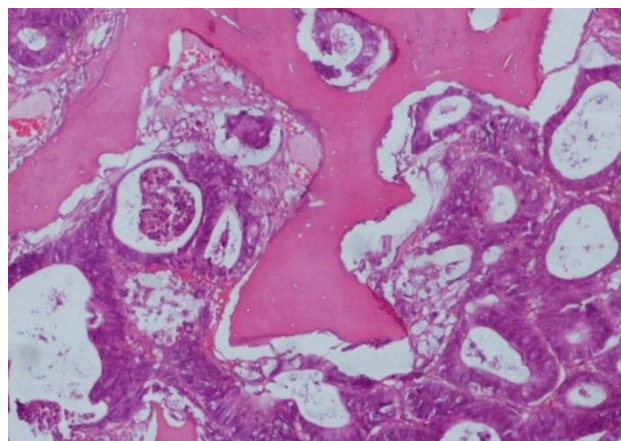
## Statistical Analysis

Data were recorded in the Microsoft Excel program. Gender, location of metastasis, type of metastatic tumor, and presence or absence of primary focus were evaluated. Continuous data were summarized as mean±standard deviation. Categorical data were reported as numbers and percentages.

## RESULTS

Of the 116 bone tumor materials evaluated, 49 (42.2%) were primary and 67 (57.8%) were metastatic tumors. Most metastatic bone tumors presented with bone pain (40 of the 67 patients, 59.7%). 52 of the metastatic tumor cases were cases with a previous diagnosis of tumor and presenting with the diagnosis of metastasis. Other cases were referred with the suspicion of primary bone tumor and without a previous diagnosis of other organ malignancy. Forty of the metastatic bone disease cases presented with bone pain. 49 (73.1%) of the cases were male and 18 (26.9%) were female. The mean age of the patients was 61.7±19.8 (range, 9-88) years. The mean age for males was 61.9±20.1 and for females 58.1±18.8 years. The most common age ranges for metastases were 60-69 and 50-59 years.

The majority of metastatic cases were tumors of epithelial origin. Of the cases, 54 (80.6%) were epithelial, 8 (11.9%) were hematological, and 5 (7.5%) were mesenchymal neoplasms. The most common metastatic primary origin was lung carcinomas (Figure 1). While breast and lung tumors were most common in female patients, respectively, lung tumors, tumors of unknown origin, kidney, and urothelial carcinomas were most



**Figure 1.** Metastatic lung adenocarcinoma (H&E, x100)

common in male patients, respectively (Table 1). The mean age of breast tumors, which is the most common metastatic carcinoma in females, was  $65.8 \pm 5.9$  years. The mean age of lung tumors, which is the most common metastasis in males, was  $62.1 \pm 6.9$  years.

Twenty-five (37.3%) of the tumors were in the vertebrae, 18 (26.9%) in the lower extremity, 9 (13.4%) in the upper extremity, 4 (6.0%) in the ribs, 3 (4.5%) in the cranial bones, 6 (9.0%) in the pelvic bones, 1 (1.5%) in the scapula, and 1 (1.5%) in the clavicle. Among the most frequently metastasizing carcinomas, primary lung carcinomas were most found to metastasize to the vertebrae and lower extremities, and breast carcinomas to the vertebrae most frequently. One of the prostate carcinoma metastases was to the lower extremity and one was to the cranial bones. Renal carcinomas most commonly metastasize to the vertebrae. The region with the most metastasis was the vertebral region, of which 19 (76%) were epithelial, 4 (16%) were hematological, and 2 (8%) were mesenchymal tumors.

The localization of tumors of hematological and mesenchymal origin was shown in Table 2.

Of the hematological origin metastases, 5 were plasma cell neoplasia, 2 were high-grade B-cell lymphoma, and 1 was Langerhans cell histiocytosis. Of the metastases of mesenchymal origin, 2 were Ewing sarcoma, 1 was monophasic synovial sarcoma, 1 was an undifferentiated solitary fibrous tumor (Figure 2), and 1 was a mesenchymal tumor of unknown primary.

Of the 8 cases of unknown primary, 1 was mesenchymal and reported as metastatic sarcoma. Of the 7 epithelial metastatic tumors unknown histopathologically, 2 were squamous cell carcinomas (Figure 3). There was no additional investigation to determine the squamous cell carcinoma primary histopathologically. For this reason, in metastatic squamous cell carcinoma cases, pathological interpretation cannot be made in terms of primary focus, and clinical radiological correlation is recommended. One of the primary foci in our cases was evaluated as lung and the other as skin squamous cell carcinoma.

As a result, there were 6 (9%) cases, 1 of whom was mesenchymal, whose primary focus could not be detected after the scans. Of the epithelial tumors, 2 were reported as poorly differentiated adenocarcinoma and 3 as poorly differentiated carcinoma.

## DISCUSSION

Bone is the most frequently metastasized organ after the lung and liver (13). The metastatic bone disease disrupts the process of balanced osteoblastic/osteoclastic activity of bone, resulting in skeletal complications resulting in an unbalanced bone turnover (14).

Bone pain in cancer follow-up cases is a finding that should be evaluated primarily in terms of metastatic bone disease. Bone pain is primarily due to the secretion of pain-inducing mediators such as bradykinin and Substance P by tumor cells, as well as the formation of microfractures in the trabecular bone and stimulation of the periosteum (15). The majority of the cases in this series presented with clinical bone pain.

Consistent with the literature, the majority of the cases were male. This may be because cancer rates are generally higher in males.

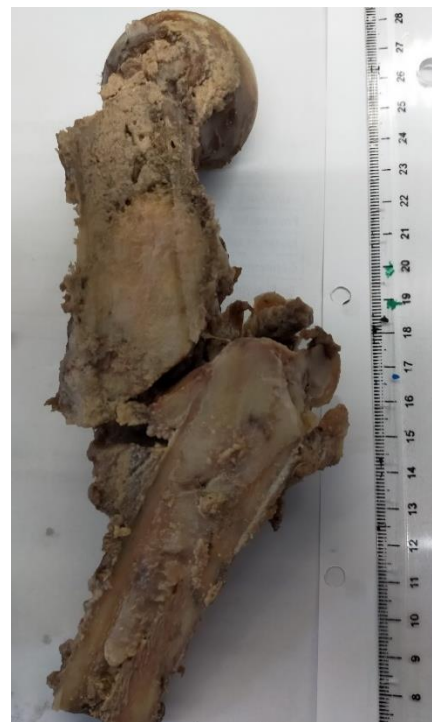**Table 1.** The most common bone metastasis epithelial tumors in male and female patients (n=54)

Female (n=11)	Male (n=43)		
Breast	5 (45.4)	Lung	14 (32.6)
Lung	3 (27.3)	UP Origin	5 (11.6)
GIS	1 (9.1)	Kidney	4 (9.3)
Other	2 (18.2)	Other	20 (46.5)

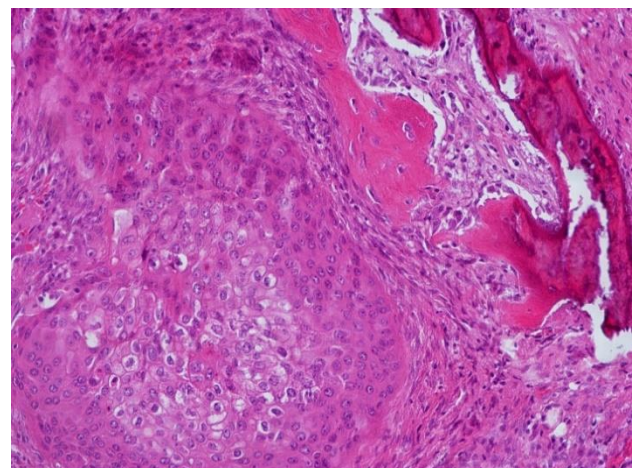
GIS: gastrointestinal system, UP: unknown primary

**Table 2.** Localization of mesenchymal and hematological malignancies (n=13)

Mesenchymal (n=5)	Hematological (n=8)		
Lower extremity	1 (20)	Lower extremity	2 (25)
Costa	1 (20)	Cranium	1 (12.5)
Pelvic bone	1 (20)	Upper extremity	1 (12.5)
Vertebra	2 (40)	Vertebra	4 (50)



**Figure 2.** Metastatic dedifferentiated solitary fibrous tumor. A gray-white mass with a pathological fracture in the femoral diaphyseal region is seen



**Figure 3.** Metastatic squamous cell carcinoma (H&E, x200)



Lung, breast, prostate, and kidney tumors constitute the majority of metastatic bone tumors. The condition for all cancer types are as follows; bone metastasis is an indication that the tumor is advanced and the survival time is shortened (16-18). Even in cases with only bone metastases, life expectancy is less than 5 years (19).

Of breast carcinomas, 75% metastasize to bone in the late stage. As with other types of cancer, the disease becomes incurable in bone metastasis of breast cancer. In the literature, there are studies in terms of agents that can predict bone metastasis of breast cancer and that can be used in treatment (20,21). In one of these studies, it was determined that both breast cancer cells and the tumor microenvironment secrete interleukin 1B, and it was reported that agents against this molecule can be used in targeted therapy (22).

Bone metastases are seen at a similar rate to the contralateral lung and liver metastases in lung carcinomas. Compared to breast carcinoma, treatments for bone metastases are used less often because the overall survival effect is not great. However, there are also studies reporting positive effects on mean survival in the literature. Metastases in lung carcinomas are frequently encountered with multiple bone metastases. The region where they metastasize most is the vertebral region, which is consistent with the present study (23-25).

In cases where the primary origin cannot be detected, clinical imaging methods such as thorax CT, PET-CT, mammography, as well as endoscopic examination, and tumor markers in the blood can be examined. In addition, a histopathological examination is necessary. However, after all these examinations, the primary origin may still not be detected. In literature, this rate varies between 2.3% and 11% (19,26,27). In the current study, this rate was 9%. Morphologically, most of these tumors were reported as poorly differentiated adenocarcinoma or poorly differentiated carcinoma. In the literature, carcinomas of unknown origin are reported as well-moderately differentiated adenocarcinoma, poorly differentiated carcinoma, squamous cell carcinoma, and undifferentiated carcinoma, respectively. Solitary bone metastases have a relatively better prognosis in metastatic cases where the primary origin cannot be detected, compared to other organ metastases (28).

Axial skeletal metastases are more common than appendicular skeletal metastases (13). Similarly, in cases included in the present study, metastasis was most frequently seen in the vertebrae. In the appendicular skeleton, metastases were most common in the femur. In another study, the most common metastasis was found in the femur, followed by the vertebra (13,25). In the literature, lung, breast, and kidney cancers are most frequently encountered with vertebral metastases, which is consistent with this study (16,29,30). Although the primary treatment of vertebral metastases is radiotherapy, surgery is performed in case of treatment failure. Because according to the literature, surgery has no superiority over radiotherapy. In the case series in this study, most of the vertebral surgeries were performed for decompression of the vertebrae or definitive diagnosis (31).

The most important limitation of this study is that sampling was not made from all tumor cancer cases that metastasized to the bone. Palliative therapies are applied

in cases with multiple organ metastases and biopsy is not needed. We think that this is the most important reason for the low number of cases in this study.

## CONCLUSION

Bone pain is always a symptom that should be considered in a patient followed up with a diagnosis of cancer. The data in this study were generally compatible with the literature. It should be kept in mind that the primary origin may not be detected in a group of patients despite all clinical and imaging methods. We have discussed all types of cancer in this study, but there is a need for more specific studies on the type of cancer and its localization at the molecular level, which may affect the treatment, based on such studies.

**Ethics Committee Approval:** The study was approved by the Non-Invasive Clinical Researches Ethics Committee of Eskişehir Osmangazi University (26.04.2022, 18).

**Conflict of Interest:** None declared by the authors.

**Financial Disclosure:** None declared by the authors.

**Acknowledgments:** None declared by the authors.

**Author Contributions:** Idea/Concept: NSS; Design: NSS, FC; Data Collection/Processing: Uİ, MK; Analysis/Interpretation: NSS, FC; Literature Review: NSS, FC, Uİ, MK, ÖB; Drafting/Writing: NSS, ÖB; Critical Review: NSS, FC, Uİ, MK, ÖB.

## REFERENCES

1. Reise SP, Waller NG. Item response theory and clinical measurement. *Annu Rev Clin Psychol.* 2009;5:27-48.
2. Ban J, Fock V, Aryee DNT, Kovar H. Mechanisms, diagnosis and treatment of bone metastases. *Cells.* 2021;10(11):2944.
3. Ren G, Esposito M, Kang Y. Bone metastasis and the metastatic niche. *J Mol Med (Berl).* 2015;93(11):1203-12.
4. Zhang W, Bado I, Wang H, Lo HC, Zhang XH. Bone metastasis: find your niche and fit in. *Trends Cancer.* 2019;5(2):95-110.
5. Shiozawa Y, Pienta KJ, Taichman RS. The hematopoietic stem cell niche is a potential therapeutic target for bone metastatic tumors. *Clin Cancer Res.* 2011;17(17):5553-8.
6. Paget S. The distribution of secondary growths in cancer of the breast. *Lancet.* 1889;133(3421):571-3.
7. Weilbaecher KN, Guise TA, McCauley LK. Cancer to bone: a fatal attraction. *Nat Rev Cancer.* 2011;11(6):411-25.
8. Cecchini MG, Wetterwald A, van der Pluijm G, Thalmann GN. Molecular and biological mechanisms of bone metastasis. *EAU Update Series.* 2005;3(4):214-26.
9. Coleman RE, Brown J, Holen I. Bone metastases. In: Niederhuber JE, Armitage JO, Doroshow JH, Kastan MB, Tepper JE. *Abeloff's clinical oncology.* 6<sup>th</sup> ed. Philadelphia, PA: Elsevier; 2020. p.809-30.e3.

10. Shiozawa Y, Pedersen EA, Havens AM, Jung Y, Mishra A, Joseph J, et al. Human prostate cancer metastases target the hematopoietic stem cell niche to establish footholds in mouse bone marrow. *J Clin Invest.* 2011;121(4):1298-312.
11. Sethakorn N, Heninger E, Sánchez-de-Diego C, Ding AB, Yada RC, Kerr SC, et al. Advancing treatment of bone metastases through novel translational approaches targeting the bone microenvironment. *Cancers (Basel).* 2022;14(3):757.
12. Xiong Z, Deng G, Huang X, Li X, Xie X, Wang J, et al. Bone metastasis pattern in initial metastatic breast cancer: a population-based study. *Cancer Manag Res.* 2018;10:287-95.
13. Mayadağlı A, Bulut G, Ekici K. Management of metastatic bone tumors. *South Clin Ist Euras.* 2011;22(1):49-55. Turkish.
14. Brown JE, Cook RJ, Major P, Lipton A, Saad F, Smith M, et al. Bone turnover markers as predictors of skeletal complications in prostate cancer, lung cancer, and other solid tumors. *J Natl Cancer Inst.* 2005;97(1):59-69.
15. Anract P, Biau D, Boudou-Rouquette P. Metastatic fractures of long limb bones. *Orthop Traumatol Surg Res.* 2017;103(1S): S41-S51.
16. Sugiura H, Yamada K, Sugiura T, Hida T, Mitsudomi T. Predictors of survival in patients with bone metastasis of lung cancer. *Clin Orthop Relat Res.* 2008;466(3):729-36.
17. Ibrahim T, Flamini E, Mercatali L, Sacanna E, Serra P, Amadori D. Pathogenesis of osteoblastic bone metastases from prostate cancer. *Cancer.* 2010;116(6):1406-18.
18. Suva LJ, Griffin RJ, Makhoul I. Mechanisms of bone metastases of breast cancer. *Endocr Relat Cancer.* 2009;16(3):703-13.
19. Coleman RE. Metastatic bone disease: clinical features, pathophysiology and treatment strategies. *Cancer Treat Rev.* 2001;27(3):165-76.
20. Rose AA, Siegel PM. Emerging therapeutic targets in breast cancer bone metastasis. *Future Oncol.* 2010;6(1):55-74.
21. Miller K, Clementi C, Polyak D, Eldar-Boock A, Benayoun L, Barshack I, et al. Poly(ethylene glycol)-paclitaxel-alendronate self-assembled micelles for the targeted treatment of breast cancer bone metastases. *Biomaterials.* 2013;34(15):3795-806.
22. Tulotta C, Ottewill P. The role of IL-1B in breast cancer bone metastasis. *Endocr Relat Cancer.* 2018;25(7):R421-34.
23. Hirsh V, Major PP, Lipton A, Cook RJ, Langer CJ, Smith MR, et al. Zoledronic acid and survival in patients with metastatic bone disease from lung cancer and elevated markers of osteoclast activity. *J Thorac Oncol.* 2008;3(3):228-36.
24. Scagliotti GV, Hirsh V, Siena S, Henry DH, Woll PJ, Manegold C, et al. Overall survival improvement in patients with lung cancer and bone metastases treated with denosumab versus zoledronic acid: subgroup analysis from a randomized phase 3 study. *J Thorac Oncol.* 2012;7(12):1823-9.
25. Kuchuk M, Addison CL, Clemons M, Kuchuk I, Wheatley-Price P. Incidence and consequences of bone metastases in lung cancer patients. *J Bone Oncol.* 2013;2(1):22-9.
26. Çelik ZE, Harmankaya İ, Aydın BK, Yıldırım A. Retrospective analysis of 129 patients with metastatic bone tumors. *Genel Tıp Derg.* 2021;31(1):59-64. Turkish.
27. Pavlidis N, Fizazi K. Carcinoma of unknown primary (CUP). *Crit Rev Oncol Hematol.* 2009;69(3):271-8.
28. Pavlidis N, Pentheroudakis G. Cancer of the unknown primary site. *Lancet.* 2012;379(9824):1428-35.
29. Kuchuk I, Hutton B, Moretto P, Ng T, Addison CL, Clemons M. Incidence, consequences and treatment of bone metastases in breast cancer patients-Experience from a single cancer centre. *J Bone Oncol.* 2013;2(4):137-44.
30. Grünwald V, Eberhardt B, Bex A, Flörcken A, Gauler T, Derlin T, et al. An interdisciplinary consensus on the management of bone metastases from renal cell carcinoma. *Nat Rev Urol.* 2018;15(8):511-21.
31. Steinmetz MP, Mekhail A, Benzel EC. Management of metastatic tumors of the spine: strategies and operative indications. *Neurosurg Focus.* 2001;11(6):e2.