



LETTER

RECONSTRUCTION of FULL -THICKNESS NASAL ALAR DEFECT WITH COMPOSITE AURICULAR GRAFT and HYPERBARIC OXYGEN TREATMENT

Yakup Çil, Mehmet Sezgin

Eskişehir Asker Hastanesi, Plastik Cerrahi, Eskişehir, Türkiye

ABSTRACT

Aesthetic and functional reconstruction of full-thickness nasal alar defect has always been a challenge to the surgeon. Although several techniques are described in the literature, none has proved to be ideal. We used the combination of composite ear graft with hyperbaric oxygen treatment for 21-year-old man who has full-thickness nasal alar defect. Composite ear grafts may provide good functional and aesthetic results when combined with hyperbaric oxygen treatment for full-thickness nasal alar defects.

Anahtar Kelimeler: Nasal Alar Defect, Composite Graft, Hyperbaric Oxygen

TAM KALINLIKTAKI NASAL ALAR DEFEKTİNİN KOMPOZİT KULAK GREFTİ ve HİPERBARİK OKSİJEN TEDAVİSİ İLE ONARIMI

ÖZET

Nasal alar bölge defektlerinin estetik ve fonksiyonel açıdan onarımının yapılması cerrah için oldukça zordur. Literatürde değişik teknikler tarif edilmiş olsada, ideal onarım tekniği mevcut değildir. Biz kompozit kulak grefti ile hiperbarik oksijen tedavisini kombine olarak 21 yaşındaki erkek hastadaki nasal alar defekti için kullandık. Kompozit kulak grefti hiperbarik oksijen tedavisi ile kombine edilerek tam kalınlıktaki nasal alar defektlerinin onarımında kullanıldığında iyi fonksiyonel ve estetik sonuç sağlanabilir.

Anahtar Kelimeler: Nasal Alar Defekt, Kompozit Greft, Hiperbarik Oksijen

Dear Editor;

Aesthetic and functional reconstruction of full-thickness nasal alar defect has always been a challenge to the surgeon. Although several techniques are described in the literature, none has proved to be ideal¹. Reconstruction of this anatomical area has some difficulties due to complexity of the anatomy of the nose. The contours of the nose are variable, with convex and concave surfaces in close contact with each other, and the skin texture and color is not easy to match. Alar region of the nose is one of the sub-units of the nose and it contains skin, cartilage and lining². Composite ear graft offers sufficient amount of similar tissue for nasal alar reconstruction. But, composite ear grafts used

for restoration of the inner nasal lining may get deformed or partial necrosis of graft resulting impairment of nasal airway patency³. Therefore, surgeons use caution performing these techniques. Effectiveness of hyperbaric oxygen therapy for enhance the survival of auricular composite grafts in the rabbit model was reported recently⁴. In that reason; we used the combination of composite ear graft with hyperbaric oxygen treatment for full-thickness nasal alar defect treatment. 21-year-old male patient who had nasal alar defect caused by dog bit at the age of 5 years old was admitted to our clinic (Figure-1, 2). Composite skin and cartilage grafting had been taken from right ear under local anesthesia. After preparation of composite

İletişim Bilgileri:

Yakup Çil, MD.

Eskişehir Asker Hastanesi, Plastik Cerrahi, Eskişehir, Türkiye
e-mail: yakupcil@yahoo.com

Marmara Medical Journal 2008;21(3);296-297



graft and nasal alar defect, composite graft was transferred to the nasal alar defect. Patient received twice-daily hyperbaric oxygen treatments for 5 days. Postoperative period was eventful. The graft take was 100 % (Figure-1, 2). After 10 months follow-up;

cosmetic results was satisfactory (Figure-1, 2). Composite ear grafts may provide good functional and aesthetic results when combined with hyperbaric oxygen treatment for full-thickness nasal alar defects.

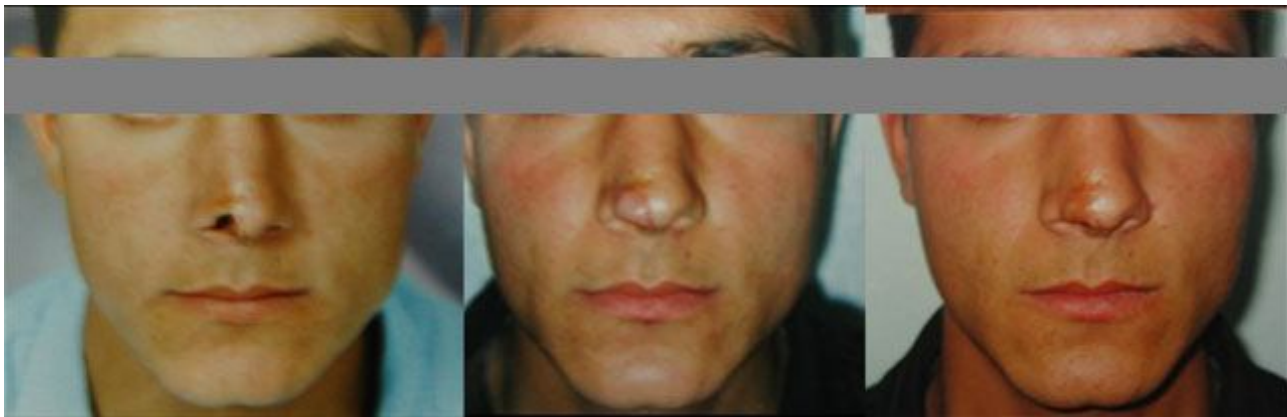


Figure-1: Anterior view of right nasal alar defect: preoperative (left), one month postoperative (middle), ten months postoperative (right).

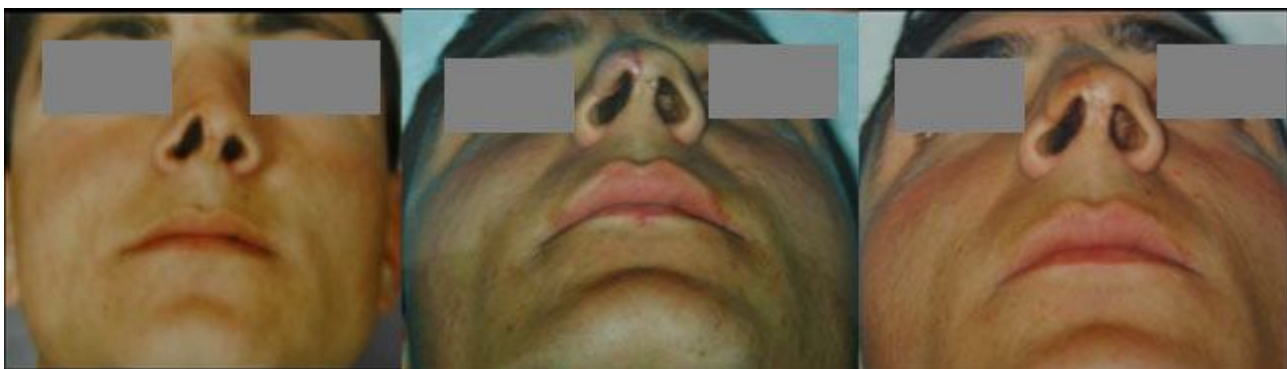

Figure-2: Basal view of right nasal alar defect: preoperative (left), one month postoperative (middle), ten months postoperative (right).

REFERENCES

1. Svedman P. Advancement flaps for alar reconstruction. *Ann Plast Surg* 1990;25(6):502-7.
2. Burget GC, Menick FJ. The subunit principle in nasal reconstruction. *Plast Reconstr Surg* 1985;76(2):239-47.
3. Keck T, Lindemann J, Kuhnemann S, et al. Healing of composite chondrocutaneous auricular grafts covered by skin flaps in nasal reconstructive surgery. *Laryngoscope* 2003;113(2):248-53.
4. Lewis D, Goldztein H, Deschler D. Use of hyperbaric oxygen to enhance auricular composite graft survival in the rabbit model. *Arch Facial Plast Surg* 2006;8(5):310-13.