

Case Report | Olgu Sunumu

TREATMENT OF HEPATIC HYDATID CYST RUPTURE INTO THE BILIARY TRACT: ENDOSCOPIC EVACUATION

SAFRA YOLUNA RÜPTÜRE HEPATİK KİST HİDATİK TEDAVİSİ: ENDOSKOPIK DRENAJ

 Esat Taylan Ugurlu¹,  Mehmet Baykan^{2*},  Yunus Donder²

¹Mehmet Akif Inan Education and Research Hospital, Sanliurfa, Türkiye. ²Kayseri City Hospital, Department of General Surgery, Kayseri, Türkiye.



ABSTRACT

Hydatid cyst disease is a zoonotic disease caused by the transmission of Echinococcus granulosus, which is in the cestode class, to humans during the larval period. This disease causes serious problems by affecting public health and national economy as an important parasitic disease, especially in many developing countries. Liver cyst cysts can be complicated according to their diameter and location. Complication rate reaches 60%. The leading complications are bile duct involvement and related complications. Bile duct problems should be solved first in cysts associated with biliary tract. ERCP and endoscopic sphincterotomy can be performed. Here we discussed the treatment and management of a 35-year-old male patient with hydatid cyst that opened into the biliary tract with ERCP, who presented to the emergency room with fever and signs of infection.

Keywords: Endoscopic cyst evacuation, cholangitis, endoscopic retrograde cholangiopancreatography

ÖZ

Kist hidatik hastalığı sestod sınıfında yer alan Echinococcus granulosus'un larval döneminde insana bulaşmasıyla oluşan zoonotik bir hastalıktır. Bu hastalık özellikle gelişmekte olan birçok ülkede önemli parazitik hastalık olarak halk sağlığını ve ulusal ekonomiyi etkileyerek ciddi problemler oluşturur. Karaciğer kist hidatikleri çapına ve yerleşim yerine göre komplike olabilirler. Komplike olma oranı %60'ları bulmaktadır. Komplikasyonların başında safra yolu iştiraki ve buna bağlı gelişen komplikasyonlardır. Safra yollarıyla iştiraki olan kistlerde safra yolu sorunları öncelikle çözümlenmelidir. Bunun için ERCP ve endoskopik sfinterotomi yapılabilir. Bizde burada acile ateş ve enfeksiyon bulguları ile başvuran 35 yaşındaki safra yoluna açılan kist hidatik hastasının ERCP ile tedavisini ve yönetimini tartıştık.

Anahtar Kelimeler: Endoskopik kist drenajı, kolanjit, endoskopik retrograde kolanjiopankreatikografi

Introduction

Hydatid cysts are a parasitic disease caused by *Echinococcus granulosus*, most commonly located in the liver with a rate of 50-70%.¹ The most frequent complication of hepatic hydatid cysts is intrabiliary rupture, with an incidence of 5-25% in some series.² Endoscopic retrograde cholangiopancreatography (ERCP) is accepted as the gold standard for determining the relationship between the cyst and the biliary tract; it is also used for treatment.³ Surgery used to have a crucial role in diagnosing and treating all the complications due to hydatid cyst rupture into the biliary tract. However, today, less invasive or noninvasive methods are used.

As the cyst ruptures into the biliary tract, mechanical jaundice and ascending bacterial infection may develop.⁴ There have been rare cases of acute pancreatitis resulting from the intrabiliary rupture of a liver hydatid cyst.⁵ In this case report, we presented the diagnosis and follow-up of a patient with hepatic hydatid cyst, who presented with complications of obstructive jaundice acute cholangitis, and acute pancreatitis due to intrabiliary rupture, and their treatment by endoscopic cyst evacuation.

Case Report

A 35-year-old male patient was admitted to our hospital's emergency department with complaints of abdominal pain, vomiting, fever, and jaundice lasting for two days. He had no previously known disease or any significant finding in his family history. Physical examination revealed severe tenderness in the epigastric region and in the right upper quadrant of the abdomen. His body temperature was 38.4 °C. Some laboratory findings were very high: serum aspartate transaminase (AST) was 161 U/L (reference range: 5-41), alanine aminotransferase (ALT) 299 U/L (reference range: 5-40), total bilirubin 6.70

mg/dl (reference range: 0.2-1.2), direct bilirubin 5.23 mg/dl (reference range: 0-0.3), amylase 2402.40 U/L (reference range: 28-100), and lipase 1445.80 IU/L (reference range: 13-60). Besides, leukocyte was 13.55 (reference range: 3.7-10.1) and CRP (C-Reactive protein) 44.71 mg/L (reference range: <5). Computed tomography (CT) of the abdomen revealed a 37-mm-diameter cystic lesion with a calcified wall in liver segment 4 and dilatation in the biliary tract adjacent to the cyst. We also observed a connection between the cyst and the biliary tract (Figure 1). MR and MRCP images revealed a fistula between the cyst and the intrahepatic biliary tract, an enlarged common bile duct, and membranes of the cyst in the common bile duct lumen (Figure 2). With these findings, the patient was diagnosed with a rupture of the hydatid cyst into the biliary tract, acute cholangitis and acute pancreatitis.

Treatment and Management

The patient was started on ciprofloxacin 10 mg/kg IV and fluid replacement. After IV antibiotic treatment, the patient underwent ERCP. Ampulla of Vater was difficult to cannulate because it was very edematous. A 10 fr 10 cm plastic stent was placed in the common bile duct to ensure bile flow. The patient was discharged on the 1st day after ERCP. Two months after discharge, the patient was taken to the ERCP procedure again. Using basket-tipped catheter and balloon catheters, a large amount of the hydatid cyst, daughter vesicles, and cyst membranes were evacuated into the duodenum (Figure 3). The patient was discharged on the 1st day after the second ERCP procedure. Two months later, the patient was invited to the hospital for re-evaluation. Clinical findings and biochemical laboratory values were observed to be within normal limits. Post-treatment CT of the abdomen revealed that the cyst was completely disappeared, and the bile duct dilatation was improved. Only a 2-cm-diameter hypodensity remained, which was interpreted as sequelae change at the lesion site (Figure 4).

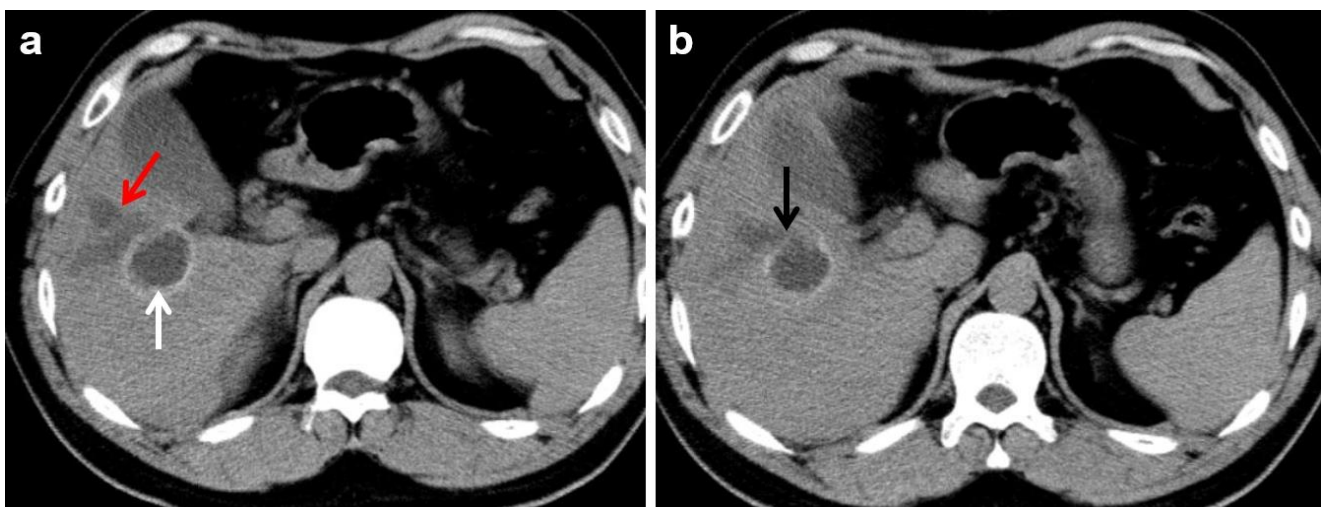


Figure 1. Axial sectional images on CT of the abdomen show hydatid cyst with calcified wall (white arrow) and biliary tract dilatation (red arrow) adjacent to the cyst (a). A fistula is visible between the cyst and the biliary tract (black arrow) (b)

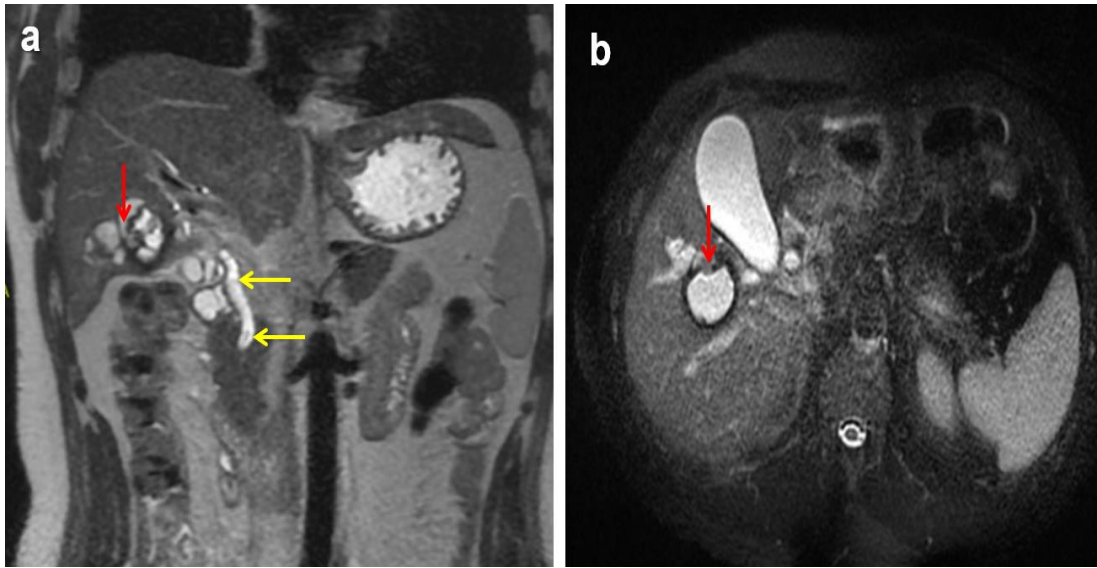


Figure 2. Coronal (a) and axial (b) T2-weighted MR images show the junction between the cyst and the biliary tract (red arrows). Also, the coronal T2-weighted image (a) shows enlarged common bile duct and filling defects of the cyst in the lumen (yellow arrows)

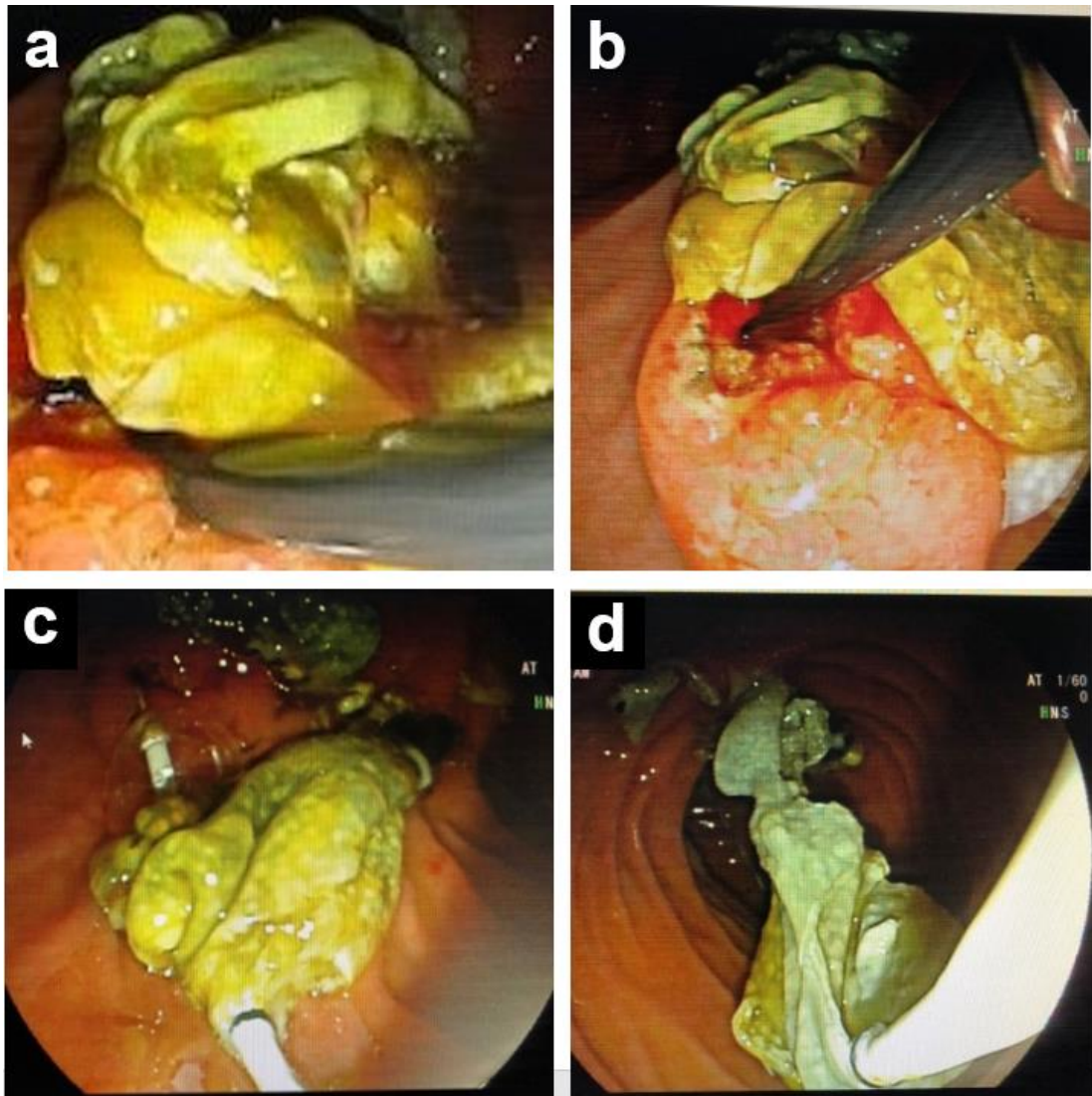


Figure 3. ERCP examination shows bile-stained membranes (a), papillotomy (b), cyst membranes being swept into the duodenum with balloon catheter (c), and cyst content reduced into the duodenum (d)

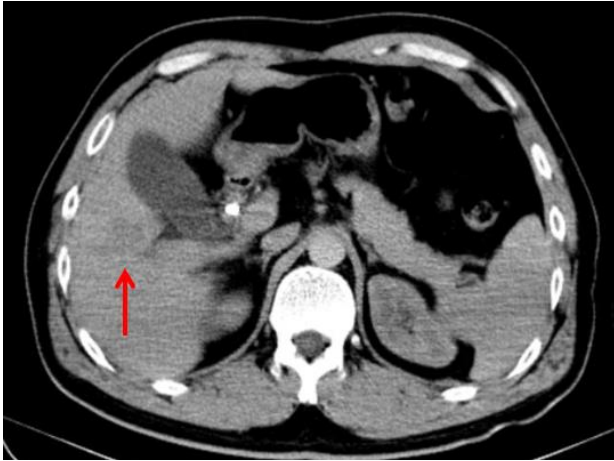

Figure 4. Post-treatment CT of the abdomen shows that the cyst disappeared and the biliary tract dilation improved (red arrow)

Discussion

Rupture into the biliary tract may have various clinical presentations, ranging from asymptomatic cases to jaundice, cholecystitis, cholangitis, liver abscess, pancreatitis, and septicemia, in proportion to the size of the cysto-biliary communication.⁶

One of complications associated with intrabiliary rupture is acute pancreatitis.² Hydatid cyst rupture into the biliary tract is a rare and serious complication. For cysts that are connected to the bile duct, the treatment approach changes vastly compared to normal cysts.⁷ Daughter vesicles and their membranes can obstruct the biliary tract, resulting in obstructive jaundice and cholangitis.

Liver hydatid disease is asymptomatic in 40-60% of cases, while the rest may present with minor or major complications.⁸ Since hydatid cysts are involved in different organs, it presents with different clinical findings. Hence, we emphasize that it is crucial to keep in mind the complications that may develop during the course of hydatid cyst and the clinical findings associated with them for early diagnosis and treatment. Cyst rupture, which can occur spontaneously or with trauma, is the best known complication. Findings for such cases include elevated liver enzymes and bilirubin levels, right upper quadrant pain in the abdomen, recurrent cholangitis, haemobilia findings, and if there is obstruction at the level of the ampulla of Vater, pancreatitis and elevated amylase levels.

Hydatid cyst rupture into the bile duct is the most common complication, with a 5-25% prevalence among patients with hydatid liver cysts. The contents of the ruptured hydatid cyst (membranes, scolexes, daughter cysts) are excreted into the biliary tract. Hydatid cyst rupture may cause jaundice and cholangitis attacks by obstructing the bile ducts. The inflammatory cascade of acute pancreatitis is triggered by increased intrapancreatic pressure because of the mechanical obstruction due to membranes in the papillary orifice.¹ In addition local allergic reaction to echinococcal antigens in the ampulla may play a role in the onset of pancreatitis.²

Centrally located cysts cause compression and push on the bile ducts. Continued contact between the cyst and the biliary tract may result in rupture into the biliary tract because of increased intra-cyst pressures, depending on the fragility of the cyst wall. Major biliary ruptures may be symptomatic and can be recognized preoperatively. In these cases, the cyst materials discharge into the biliary ducts, causing obstruction, thus leading to obstructive jaundice and cholangitis findings. Sometimes, this clinical picture may include complications like acute pancreatitis. There are numerous studies on hydatid cyst rupture into the bile duct treated with ERCP. Researchers report that the cyst volume decreased significantly during follow-up, 25% of the patients recovered completely and no further surgical treatment was required. Extraction of cyst contents can be performed with endoscopic sphincterotomy (ES), a balloon catheter, or a basket catheter. Some treatment modalities can be applied with ERCP, including endoscopic cyst evacuation, nasobiliary drain (NBD) placement, and biliary stent placement.⁹ For eligible patients, we consider endoscopic cyst evacuation alone to be a safe and effective technique for the treatment of hydatid cyst rupture into the bile duct.

Conclusion

Cystobiliary ruptures can be diagnosed at a high rate using MRCP in addition to USG and CT. In cases where imaging reveals hydatid remnants in the bile ducts, ERCP should be the first treatment choice. If needed, additional stent placement and NBD can be performed on the common bile duct. The most common complication of hydatid cyst rupture into the biliary tract is acute cholangitis; this is rarely accompanied by acute pancreatitis. Our case report demonstrates that endoscopic cyst evacuation is safe and effective for treating hydatid cyst rupture into the biliary tract.

Compliance with Ethical Standards

Consent was obtained from the patient.

Conflict of Interest

The authors declare no conflicts of interest.

Author Contribution

ETU, YD: Concept; ETU, MB: Design; ETU: Supervision; MKY, YD: References; ETU, MB: Data collection; YD, MB: Analysis and interpretation; ETU, MB: Literature review; ETU, MB: Writing.

Financial Disclosure

None.

References

1. Coşkun O, Ödemiş B, Alpua M, et al. Endoscopic cyst evacuation as a treatment for liver hydatid cysts in patients who present with acute pancreatitis. *Endoscopy Gastrointestinal*. 2017;25:49-51. doi:10.17940/endoskopi.339876

2. Toka B, Karaman K, Eminler AT, et al. A Case of Cyst Hydatid which is Diagnosed By Apperarence of Girl Vesicles in Choledoc with ERCP. *Sakarya Tıp Dergisi*. 2016;6(4):240-244. doi:10.5505/sakaryamedj.2016.33602
3. Şahin DA, Kuşaslan R, Türel KS, ve ark. Karaciğer Kist Hidatik Olgularımızda Cerrahi Tedavive ERCP ile Sfinkterotominin Etkinliği. *The Medical Journal of Kocatepe*. 2006;6:11-16.
4. Sayek İ, Tırnaksız MB, Doğan R. Cystic Hydatid Disease: Current trends in diagnosis and management. *Surg Today*. 2004;34:987-996. doi: 10.1007/s00595-004-2830-5
5. Beltsis A, Chatzimavroudis G, Iliadis A, et al. Intrahepatic rupture of hepatic hydatid cyst presenting as acute pancreatitis and treatment with endoscopic sphincterotomy: report of two cases. *Ann Gastroenterol* 2005;18:353-356.
6. Dolay K, Hatipoğlu E. ERCP in the Management of Hydatid Cyst Disease. *Turkiye Klinikleri J Gen Surg-Special Topics*. 2010;3(2):60-68.
7. Tekin A, Küçükkartallar T, Aksoy F, et.al Our patients with hepatic hydatid cyst rupturing into bile ducts. *Turkish Journal of Surgery*. 2007;23(4):125-128.
8. Coşkun İ, Sezer A, Sağıroğlu T, ve ark. Complications Due to Liver Hydatid Cyst Disease. *Turkiye Klinikleri J Gen Surg-Special Topics*. 2010;3(2):51-55.
9. Dolay K, Akbulut S. Role of endoscopic retrograde cholangiopancreatography in the management of hepatic hydatid disease. *World J Gastroenterol* 2014;20:15253-15261. doi:10.3748/wjg.v20.i41.15253.