

Morphometric Evaluation of the Lacrimal Sac Fossa in Anatolian Population Using Multidetector Computed Tomography

Anadolu Toplumunda Fossa Sacci Lacrimalis'in Multi-Dedektör Bilgisayarlı Tomografi Kullanarak Morfometrik Açından Değerlendirilmesi

Huseyin ERDEM¹, Umur Anil PEHLIVAN², Nazli Totik DOĞAN³, Yigit CEVİK¹,
Nazire KILIC SAFAK¹, Neslihan BOYAN¹, Ozkan OGUZ¹

¹Department of Anatomy, Faculty of Medicine, Cukurova University, Adana, TÜRKİYE

²Department of Radiology, Van Baskale State Hospital, Van, TÜRKİYE

³Department of Biostatistics, Faculty of Medicine, Cukurova University, Adana, TÜRKİYE

Abstract

Background: To investigate the morphometric characteristics of the lacrimal sac fossa in Anatolian population using multidetector computed tomography (MDCT) images in surgical aspect.

Materials and Methods: A total of 77 cranial MDCT scans were evaluated. The dimensions of the maxillary and the lacrimal bones forming the lacrimal sac fossa were measured in 3 axial planes (upper, middle, and lower planes).

Results: The mean maximum thickness of the maxillary bone at the upper, middle and lower planes were: 3.58 mm, 4.27 mm, and 5.81 mm; the mean midpoint thickness at each plane were: 2.76 mm, 2.51 mm, and 1.48 mm; the mean lacrimal bone thickness at each plane were: 0.72 mm, 0.65 mm, and 0.66 mm; the mean distance between anterior and posterior lacrimal crests at each plane were: 5.96 mm, 8.1 mm, and 4.63 mm; the mean angle between the lacrimal bone and the sagittal plane in males and females at the middle plane were: 132.73° and 131.46°; the mean length of the lacrimal sac fossa in males and females were: 15.82 mm and 14.02 mm.

Conclusions: In Anatolian population, bone thicknesses of the lacrimal sac fossa were higher in males, while the angle between the lacrimal bone and the sagittal plane was higher in females. This study indicated that osteotomies, which are the main target of dacryocystorhinostomy (DCR) interventions, can be easily performed in the Anatolian population.

Key Words: Dacryocystorhinostomy, Maxilla, Morphometry, Multidetector computed tomography, Nasolacrimal duct

Öz.

Amaç: Anadolu toplumunda, *fossa sacci lacrimalis*'in morfometrik özelliklerini cerrahi açıdan multidedektör bilgisayarlı tomografi (MDBT) görüntüleri kullanarak araştırmak.

Materyal ve Metod: Toplam 77 kranial MDBT taraması değerlendirildi. *Fossa sacci lacrimalis*'i oluşturan *maxilla* ve *os lacrimale*'ye ait kemik kısımlarının boyutları 3 aksiyal düzlemde (üst, orta ve alt düzlem) ölçüldü.

Bulgular: Üst, orta ve alt düzlemlerde *maxilla*'nın ortalama maksimum kalınlığı: 3,58 mm, 4,27 mm ve 5,81 mm; tüm düzlemlerde ortalama orta nokta kalınlığı: 2,76 mm, 2,51 mm ve 1,48 mm; tüm düzlemlerde ortalama *os lacrimale* kalınlığı: 0,72 mm, 0,65 mm ve 0,66 mm; tüm düzlemlerde *crista lacrimalis anterior maxillae* ve *crista lacrimalis posterior* arasındaki ortalama mesafe: 5,96 mm, 8,1 mm ve 4,63 mm; orta düzlemde erkek ve kadınlarda *os lacrimale* ile sagittal düzlem arasındaki ortalama açı: 132,73° ve 131,46°; erkek ve kadınlarda *fossa sacci lacrimalis*'in ortalama uzunluğu: 15,82 mm ve 14,02 mm olarak ölçüldü.

Sonuç: Anadolu toplumunda *fossa sacci lacrimalis*'in kemik kalınlıkları erkeklerde daha yüksek iken, *os lacrimale* ile sagittal düzlem arasındaki açı kadınlarda daha yüksek bulundu. Bu çalışma, dakriyosistorinostomi (DSR) girişimlerinin ana hedefi olan osteotomilerin Anadolu toplumunda kolaylıkla yapılabileceğini göstermiştir.

Anahtar kelimeler: Dakriyosistorinostomi, Maxilla, Morfometri, Multidetektör bilgisayarlı tomografi, Nazolakrimal kanal

Corresponding Author/Sorumlu Yazar

Dr. Huseyin ERDEM
Department of Anatomy,
Faculty of Medicine,
Cukurova University, Adana,
TÜRKİYE

E-mail: herdem@cu.edu.tr

Received / Geliş tarihi: 30.06.2022

Accepted / Kabul tarihi: 29.07.2022

DOI: 10.35440/hutfd.1138470

Introduction

The lacrimal sac fossa is a concavity located on the antero-medial wall of the orbit and is formed by the maxillary and lacrimal bones (1). This concavity is limited by the anterior and posterior lacrimal crests, and the lacrimal sac fits into this cavity. The nasolacrimal sac continues as the nasolacrimal duct and drains into the inferior meatus (2, 3). An obstruction might occur at any point in the ductal system and such an occurrence usually causes chronic dacryocystitis (4). The resulting epiphora and suppuration significantly reduce the patients' quality of life (5). External dacryocystorhinostomy (DCR) is considered the gold standard method for managing nasolacrimal duct obstruction with high success rates of 80-98% (6). With this conventional method, a fistula is formed between the lacrimal sac and nasal mucosa to provide efficient tear drainage (7). However creating a small bone window by osteotomy during the external DCR seems as a relatively easy manipulation, variable thicknesses of both the maxillary and the lacrimal bones must be taken into consideration (3). Otherwise, shrinkage of the mucosa, which is an expected alteration during the healing phase, might obstruct the bony window fully or partially, ultimately resulting in a blockage of tear flow to the nasal cavity (8). With a successful DCR, optimal patency of the nasolacrimal duct can be achieved by the removal of bony elements between the anterior and posterior lacrimal crests (9). Therefore, it should be considered that the variational morphology of this relatively small region might affect the outcomes of the DCR (10).

Since the morphology of the lacrimal sac fossa shows significant variations between different and even in the same populations, extensive morphological knowledge about the area is a necessity while performing osteotomy (10-12). Several studies have demonstrated the morphological and surgical importance of this narrow region (3, 10-13). In the Japanese population higher proportion of the bony part of the lacrimal sac fossa is formed by the lacrimal bone (11). Thinner maxillary bones has been found in Caucasians (10). In East Asians, maxillary bone is thicker than those of the Caucasians (10). When it comes to focusing on differences arising from sexual characteristics, it is evident that all the bony components constituting the lacrimal sac fossa is thicker in males (11, 14, 15). Therefore, in this study, in order to determine the anatomical characteristics and serve as a guide for surgical interventions, complete morphological measurements of the lacrimal sac fossa were performed in Anatolian population on multidetector computed tomography (MDCT) images.

Materials and Methods

This study was a retrospective study approved by the local non-interventional clinical research ethics committee (Protocol no: 6.12.2019/94) and conducted in accordance with the Declaration of Helsinki. The axial MDCT scan images,

with the thickness of 0.5 mm, belonging to the patients who were screened between December 2020 and December 2021 were included in this study. One hundred thirty-two (132) cranial MDCT images were obtained. Our inclusion criteria were the presence of normal anatomical morphology of bilateral orbital and sinus structures. Patients with any history, clinical signs, or radiological findings of trauma or ophthalmic surgery, inflammation, neoplastic formations involving the orbits or sinuses were excluded from the study. In addition, patients with dental implants that cause severe artifacts in the MDCT series and any unfixed cranium appearance which was incompatible with Frankfurt horizontal plane were excluded as well. According to these criteria, a total of 77 cranial MDCT images were used.

All scans were performed by a 160-slice MDCT scanner (Toshiba Aquilion™ PRIME; Otawara, Japan) with the following standard protocol: 0.6 mm collimation with 0.5 mm slice thickness, 120 kV, and 250 m. The images, 0.5 mm axial sections, and 3D reformatted, were evaluated using a bone window setting (Width: 2500; Level:500) and a digital workstation (Vitrea CT workstation, Toshiba; Otawara, Japan). Measurements were performed based on the methods described by Gore et al. (2015) (10). The "upper plane" was determined as the first axial plane just below the fronto-lacrimal-maxillary suture that corresponds to the uppermost and concave point of the lacrimal sac fossa (Fig. 1A). The "lower plane" was determined as the last axial plane before the appearance of the complete ring of the nasolacrimal canal entrance (Fig. 1C). The "middle plane" was chosen as the cut midway between the upper and lower planes (Fig. 1B). In the upper and middle planes, the maximum thickness of the maxilla was measured at the point where the concavity of the lacrimal sac fossa starts its curve (Fig. 2A and Fig. 2B, line 1). In the lower plane, since the lacrimal sac fossa starts to get encircled like a ring, it was measured tangentially to the anteriormost portion of it (Fig. 2C, line 1). Thickness of the lacrimal bone was measured at the point just posterior to lacrimo-maxillary suture (Fig. 2, line 3). The midpoint thickness was measured at the half-way between the line of the maximum thickness of the maxilla and the line of the thickness of the lacrimal bone (Fig. 2, line 2). Bone thicknesses were measured on the viewing software with a digital caliper tool at 30° from the coronal plane, by the corresponding author. Also, the distances between anterior and posterior lacrimal crests were measured at all three planes (Fig. 2, line 4). Numbers of the sections between the first and last axial planes were recorded and multiplied by 0.5 and presented as the "length of the lacrimal sac". Moreover, the angle between the lacrimal bone and the sagittal plane was measured at the level of the middle plane (Fig. 3, α). Measurements were performed using a dedicated workstation (Vitrea®; Vital Images Inc., MN, USA).

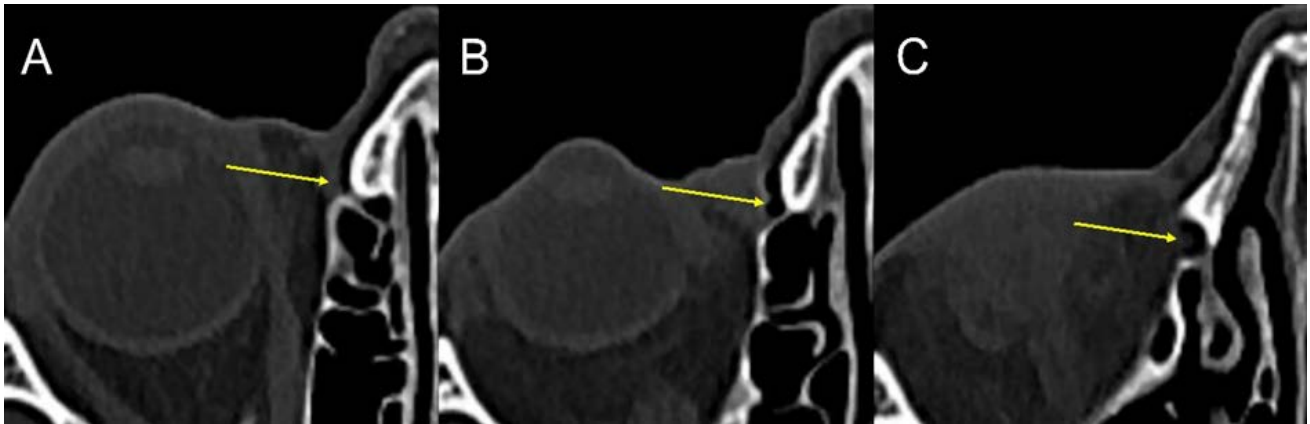

Figure 1. Axial-section images of the right lacrimal sac fossa. Arrows are showing the right lacrimal sac fossa. **A:** Upper plane. **B:** Middle plane. **C:** Lower plane.

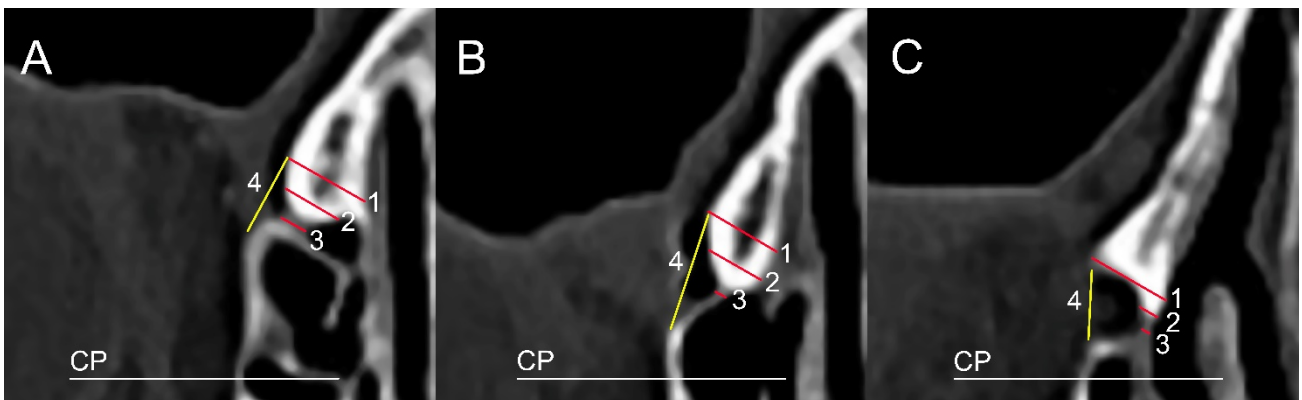


Figure 2. Dimensions of the right lacrimal sac fossa. Red lines are showing the bone thicknesses, yellow lines are showing the distance between the anterior and posterior lacrimal crests. Bone thicknesses were measured 30° to coronal plane. **1:** Maximum thickness of the maxilla. **2:** Midpoint thickness. **3:** Thickness of lacrimal bone. **4:** Distance between anterior and posterior lacrimal crests. **CP:** Coronal plane

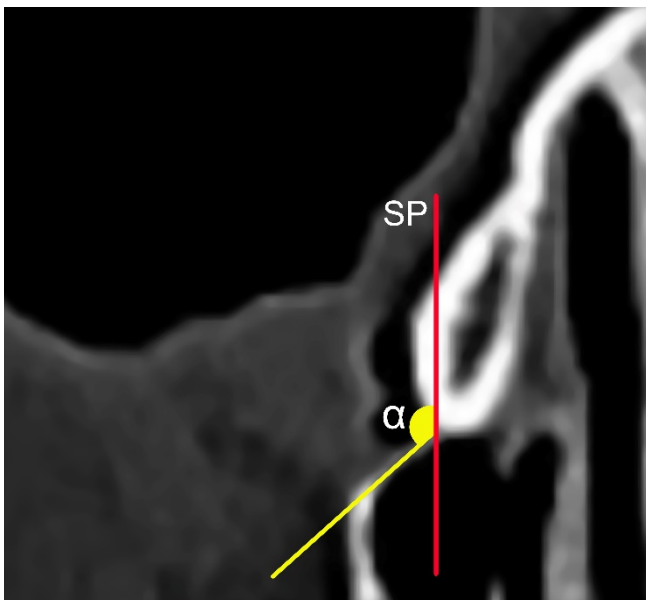

Figure 3. The angle between the lacrimal bone and the sagittal plane at the middle plane (α). **SP:** Sagittal plane

All statistical analyses were performed using IBM SPSS Statistics Version 20.0 statistical software package (SPSS Inc.,

Chicago, IL, USA). Categorical variables were expressed as numbers and percentages, whereas continuous variables were summarized as mean and standard deviation and as median and minimum-maximum where appropriate. The Kolmogorov-Smirnov test was used to analyze the distribution of each data set into parametric and nonparametric data. For comparison of continuous variables between two groups, the Student's t-test or Mann-Whitney U test was used depending on whether the statistical hypotheses were fulfilled or not. Repeated Measurements Analysis was applied to evaluate the variation of measurements in planes. Intraobserver variability was evaluated by examining Bland Altman and Pearson correlation coefficients. The statistical level of significance for all tests was considered to be 0.05.

Results

Multidetector computed tomography (MDCT) images of 77 patients were included in this study (36 males, 41 females). The average age was 44.81±20.70 years (male: 45.19±21.11; female: 44.46±20.58; range: 6-81 years) and statistical significance was not observed between genders (p=0.822). The average and median values of the parameters are shown in Table 1.

Table 1. Distribution of male and female morphometric measurements means in all planes (upper, middle, and lower) in the lacrimal sac fossa.

Measurements		Upper Plane	p	Middle Plane	p	Lower Plane	p	
Maximum thickness of the maxillary bone (mm)	Total	3.58±1.1 3.55 (1.48-06)		4.27±1.12 4.28 (2.02-.92)		5.81±1.46 5.69 (3.18-9.99)	p<0.001†	
	Male	3.72±1.21 3.58 (1.48-.06)	0.350	4.42±1.15 4.53 (2.08-.92)	0.254	6.18±1.4 6.2 (3.89-8.77)	0.029†	
	Female	3.47±0.99 3.06 (1.94-.51)		4.13±1.1 4.23 (2.02-.91)		5.49±1.45 5.39 (3.18-9.99)		
Midpoint thickness (mm)	Total	2.76±0.85 2.68 (1.4-5.06)		2.51±0.77 2.49 (1.06-5.17)		1.48±0.43 1.44 (0.77-3)	p<0.001†	
	Male	2.90±0.92 2.84 (1.4-5.06)	0.255	2.44±0.72 2.38 (1.38-4.3)	0.434	1.50±0.41 1.48 (0.77-2.62)	0.420	
	Female	2.64±0.78 2.50 (1.5-4.19)	0.255	2.57±0.82 2.51 (1.06-5.17)	0.434	1.47±0.45 1.44 (0.88-3)		
Lacrimal bone thickness (mm)	Total	0.72±0.16 0.71 (0.38-.13)		0.65±0.14 0.64 (0.31-1.12)		0.66±0.14 0.62 (0.37-1.02)	p<0.001†	
	Male	0.79±0.17 0.78 (0.44-.13)	<0.001†	0.69±0.13 0.67 (0.45-0.96)	0.015†	0.69±0.16 0.66 (0.37-1.02)	0.042†	
	Female	0.66±0.12 0.65 (0.38-.91)		0.61±0.14 0.60 (0.31-1.12)		0.62±0.1 0.62 (0.46-0.95)		
Distance between anterior and posterior lacrimal crests (mm)	Total	5.96±0.94 5.90 (3.62-.33)		8.1±1.83 7.75 (4.61-16.49)		4.63±1.1 4.45 (2.14-8.38)	p<0.001†	
	Male	6.04±0.92 5.86 (4.44-.33)	0.493	8.42±2.17 7.82 (5.85-16.49)	0.209	4.64±0.98 4.66 (3.09-7.62)	0.838	
	Female	5.89±0.96 5.92 (3.62-.62)		7.82±1.44 7.54 (4.61-11.29)		4.62±1.22 4.35 (2.14-8.38)		
Age		Angle (°; degree)			Length of the lacrimal sac fossa (mm)			
Male	Female	p	Male	Female	p	Male	Female	p
45.19±21.11 50 (6-77)	44.46±20.58 45 (12-81)	0.822	132.73±11.77 132.75 (106.08-164.89)	131.46±12.38 129.49 (103.14-153.27)	0.647	15.82±5.12 13.75 (8.5-27.25)	14.20±4.63 13.75 (8-26.75)	0.140

Values are given as mean±standard deviation and median (min-max).

† These values indicate statistical significance (p<0.05).

Tables 2, 3, and 4 show the results of repeated measurements in the lacrimal sac fossa of the first ten patients. Considering the correlation coefficient >0.80, and narrow LoA limits (are defined as -1.96 s and +1.96 s, with s the standard deviation of the difference between the two measurements), it can be said that there is a good agreement between repeated measurements. A good intraobserver agreement was found for repeated measurements of the maximum thickness of the maxillary bone at the left upper

plane (-0.054±0.274), the distance between the anterior and posterior lacrimal crests at the left upper and middle planes (-0.055±0.591 and 0.076±0.79), maximum thickness of the maxillary bone at right lower plane (-0.062±0.294) and length of the left lacrimal sac fossa (0.000±0.707) at the lower plane.

Correlations between measurements at all planes for male and female patients were examined (Table 5).

Table 2. Means and mean differences of the measurements in the upper plane results with 95% agreement limits according to the Bland-Altman analyses and with Pearson correlation coefficients.

Upper Plane		Measure I Mean±SD	Measure II Mean±SD	Mean Difference Mean±SD	LoA/mm	Pearson Correlation Coefficient (p-value)
LEFT	Maximum thickness of the maxillary bone (mm)	3.39±1.49	3.45±1.39	-0.054±0.274	-0.590; 0.482	0.984 (<0.001)
	Midpoint thickness (mm)	2.52±0.93	2.85±0.99	-0.332±0.300	-0.919; 0.255	0.953 (<0.001)
	Lacrimal bone thickness (mm)	0.65±0.15	0.73±0.09	-0.084±0.135	-0.347; 0.179	0.452 (0.190)
	Distance between anterior and posterior lacrimal crests (mm)	5.96±0.96	6.02±1.24	-0.055±0.591	-1.213; 1.103	0.884 (0.001)
RIGHT	Maximum thickness of the maxillary bone (mm)	3.30±1.09	3.70±1.26	-0.402±0.609	-1.595; 0.791	0.876 (0.001)
	Midpoint thickness (mm)	2.77±1.01	2.69±1.09	0.083±1.04	-1.954; 2.120	0.514 (0.129)
	Lacrimal bone thickness (mm)	0.63±0.17	0.73±0.1	-0.106±0.147	-0.394; 0.182	0.481 (0.160)
	Distance between anterior and posterior lacrimal crests (mm)	6.04±1.59	5.82±1.68	0.217±1.481	-2.685; 3.119	0.590 (0.073)

SD: Standard Deviation; LoA, denotes limits of agreement with 95%.

Table 3. Means and mean differences of the measurements in the middle plane results with 95% agreement limits according to the Bland-Altman analyses and with Pearson correlation coefficients.

Middle Plane		Measure I Mean±SD	Measure II Mean±SD	Mean Difference Mean±SD	LoA/mm	Pearson Correlation Coefficient (p-value)
LEFT	Maximum thickness of the maxillary bone (mm)	4.11±1.23	4.49±1.34	-0.382±0.515	-1.391; 0.627	0.924 (<0.001)
	Midpoint thickness (mm)	2.34±0.84	2.57±0.89	-0.230±0.581	-1.369; 0.909	0.775 (0.008)
	Lacrimal bone thickness (mm)	0.61±0.15	0.68±0.09	-0.071±0.106	-0.277; 0.135	0.701 (0.024)
	Distance between anterior and posterior lacrimal crests (mm)	7.84±1.27	7.76±1.47	0.076±0.79	-1.472; 1.624	0.843 (0.002)
	Angle (°; degree)	139.1±20.62	136.7±19.82	2.392±8.229	-13.737; 18.521	0.918 (<0.001)
RIGHT	Maximum thickness of the maxillary bone (mm)	4.09±1.20	4.44±1.25	-0.344±0.779	-1.870; 1.182	0.798 (0.006)
	Midpoint thickness (mm)	2.73±1.07	2.65±0.84	0.083±0.901	-1.683; 1.849	0.579 (0.079)
	Lacrimal bone thickness (mm)	0.59±0.17	0.65±0.13	-0.060±0.194	-0.439; 0.319	0.210 (0.560)
	Distance between anterior and posterior lacrimal crests (mm)	8.67±1.67	7.72±1.31	0.959±1.683	-2.339; 4.257	0.382 (0.275)
	Angle (°; degree)	130.66±15.96	131.74±15.91	-1.080±5.105	-11.084; 8.924	0.949 (<0.001)

SD: Standard Deviation; LoA, denotes limits of agreement with 95%.

Table 4. Means and mean differences of the measurements in the lower plane results with 95% agreement limits according to the Bland-Altman analyses and with Pearson correlation coefficients.

Lower Plane		Measure I Mean±SD	Measure II Mean±SD	Mean Difference Mean±SD	LoA/mm	Pearson Correlation Coefficient (p-value)
LEFT	Maximum thickness of the maxillary bone (mm)	5.68±1.68	6.19±1.90	-0.512±0.569	-1.626; 0.602	0.957 (<0.001)
	Midpoint thickness (mm)	1.15±0.20	1.32±0.29	-0.170±0.172	-0.507; 0.167	0.812 (0.004)
	Lacrimal bone thickness (mm)	0.59±0.12	0.70±0.07	-0.111±0.135	-0.375; 0.153	-0.004 (0.991)
	Distance between anterior and posterior lacrimal crests (mm)	5.14±1.26	4.79±1.52	0.347±0.511	-0.655; 1.349	0.948 (<0.001)
	Length of the lacrimal sac fossa (mm)	14.7±5.32	14.7±5.07	0.000±0.707	-1.385; 1.385	0.992 (<0.001)
RIGHT	Maximum thickness of the maxillary bone (mm)	5.96±1.95	6.02±1.78	-0.062±0.294	-0.638; 0.514	0.992 (<0.001)
	Midpoint thickness (mm)	1.15±0.39	1.51±0.41	-0.354±0.253	-0.849; 0.141	0.799 (0.006)
	Lacrimal bone thickness (mm)	0.61±0.17	0.76±0.17	-0.151±0.251	-0.642; 0.340	-0.060 (0.870)
	Distance between anterior and posterior lacrimal crests (mm)	5.07±1.42	4.84±1.21	0.230±0.361	-0.478; 0.938	0.975 (<0.001)
	Length of the lacrimal sac fossa (mm)	15.3±4.18	14.9±4.45	0.400±1.174	-1.900; 2.700	0.965 (<0.001)

SD: Standard Deviation; LoA, denotes limits of agreement with 95%.

Table 5. Correlation coefficients of measurements between upper, middle, and lower planes in males and females.

Measurements		Middle	Lower	Middle	Lower
		Upper	0.312 (0.064)	0.272 (0.108)	0.524 (<0.001)
Maximum thickness of the maxillary bone (mm)	Middle		0.676 (<0.001)		0.759 (<0.001)
	Upper	0.233 (0.172)	0.448 (0.006)	0.411 (0.008)	0.242 (0.127)
Midpoint thickness (mm)	Middle		0.316 (0.060)		0.202 (0.206)
	Upper	0.376 (0.024)	0.255 (0.133)	0.324 (0.039)	0.495 (0.001)
Lacrimal bone thickness (mm)	Middle		0.525 (0.001)		0.401 (0.009)
	Upper	0.351 (0.036)	0.201 (0.239)	0.601 (<0.001)	0.223 (0.160)
Distance between anterior and posterior lacrimal crests (mm)	Middle		0.084 (0.626)		0.339 (0.030)

Values are given as correlation coefficients (p-value).

In total, for all measurements (maximum thickness of the maxillary bone, midpoint thickness, lacrimal bone thickness, distance between anterior and posterior lacrimal crests) between planes (from upper to lower) was found to be statistically significant (p<0.001 for all) (Table 1). When this change was analyzed from gender perspective, it was not statistically different from each other in all four measurements (p=0.242, p=0.193, p=0.259, p=0.399, respectively).

The mean thickness of the maxillary bone at the lower plane was higher in males than in females (p=0.029). Similarly, the mean lacrimal bone thickness was lower for females at all planes (p<0.001, p=0.015, p=0.042) (Table 1). There is a moderate and positive relationship between the middle and lower planes in terms of the maximum thickness of the maxillary bone measurement in males (r=0.676, p<0.001). Similarly, when females were evaluated for the same measurement, a strong and positive relationship was

found ($r=0.759$, $p<0.001$). Furthermore, no correlation was observed between the length of the lacrimal sac fossa and the angle ($r=0.038$, $p<0.742$).

Discussion

Variations in bony structures are thought to arise from racial and gender characteristics (16). However, even in the same isolated geography or race, there are considerable anatomical variations observed in cranial bones and as well as lacrimal sac fossa (1, 11, 12, 17). Kang et al. (2017) found that maxillary bone in the lacrimal sac fossa was thicker in males (15). The study of Sarbajna et al. (2019) showed that the maxillary bone is thicker and the lacrimal bone is thinner in males, they also showed that the angulation of the lacrimal bone was higher in females (11). In a Taiwanese study, the lacrimal bone thickness was found to be higher in males (18). However, the reported measurements in the Taiwanese study (male, 5.8 ± 0.9 mm; female, 4.2 ± 0.8 mm) were much higher than those in other documented results (10, 11, 15, 19-22). In our study, the thicknesses of both maxillary and lacrimal bones were higher in males at all three axial planes. Nevertheless, our results were consistent with the literature.

Maxillary bone thicknesses at all planes were found to be higher in males. However, this difference was statistically significant solely at the lower plane ($p=0.029$). As in our study, the reported data in such studies indicate that the maxillary bone is thicker in males (2, 10, 11, 14, 15). In black Africans, thicker maxillary bone joins the lacrimal sac fossa (upper, 5.6 mm; middle, 5.2 mm, lower: 8.5 mm) (10). In the middle plane, current study revealed higher measurements (male, 4.42 mm; female, 4.13 mm; general average, 4.27 mm) than Caucasians (4.0 mm) (10) but not than black Africans (5.2 mm) (10) or Japanese (5.07 mm) (11). However, in our study, thinner maxillary bone was observed at the upper and lower planes compared to black Africans, Caucasians, and Japanese (Anatolian: upper, 3.58 mm; lower, 5.81 mm. Black Africans: upper, 5.6 mm; lower, 8.5 mm. Caucasians: upper, 3.6 mm; lower, 6.6 mm. Japanese: upper, 4.6 mm; lower, 6.30 mm) (10, 11). Purevdorj et al. (2021) reported that thicker maxillary bone at the lacrimal sac fossa might lead to decreased success rates for endoscopic and external DCR interventions (23).

In this study, midpoint thickness was higher at upper and lower planes in males. At the middle plane, it was found to be higher in females. However those differences were not significant between genders (upper, $p=0.255$; middle, $p=0.434$; lower, $p=0.420$). Midpoint thickness also shows variability between different populations. While East Asians (3.3 mm) (20), Black Africans (3.1 mm) (10), and Japanese (3.04 mm) (11) have higher, Caucasians (10) have the lowest midpoint thickness at the upper plane (2.0 mm) (10, 20). It was found to be relatively thinner in Korean (2.42 mm) (15) and Anatolian (our study, 2.76 mm) populations. At the middle plane, the Japanese have the highest value

for midpoint thickness (3.0 mm) (11). Following the Japanese, East Asians (2.6 mm) (20), Koreans (2.56 mm) (15), Anatolians (2.51 mm), Black Africans (2.0 mm) (10) and Caucasians (1.5 mm) (10) are respectively listed. At the lower plane, Black Africans (1.2 mm) (10), Caucasians (1.3 mm) (10) and Anatolians (our study, 1.48 mm) have lower; East Asians (2.0 mm) (20), Japanese (2.17 mm) (11) and Koreans (2.18 mm) (15) have higher midpoint thickness values. A significant decrease was observed in Black Africans (10) through the upper to lower plane, whereas Koreans (15) did not show any significant change. Unlike the other populations, in Koreans, the midpoint thickness at the upper plane was reported to be lower than that of the middle plane (15).

In our study, lacrimal bone thicknesses were significantly higher in males at all three axial planes (upper, $p<0.001$; middle, $p=0.015$; lower, $p=0.042$). Our results were higher than those of Black Africans (upper, 0.12 mm; middle, 0.10 mm, lower: 0.09 mm) and Caucasians (upper, 0.10 mm; middle, 0.09 mm, lower: 0.09 mm) (10), but lower than Japanese (upper, 1.13 mm; middle, 1.13 mm, lower: 1.08 mm) (11). Yung and Logan (1999) showed a much thinner lacrimal bone in their study on cadavers but did not mention the races of the cadavers (22). The lacrimal bone is much thinner than the maxillary bone, therefore the puncture must be carefully performed during the osteotomy in DCR to prevent damage to adjacent mucosa of turbinates. The average length of the lacrimal sac fossa was not significantly different between genders in our study, but it was slightly higher in males ($p=0.140$). On the other hand, Lee et al. (2021) found the length of the lacrimal sac fossa + nasolacrimal duct to be 22.5 mm in a CT study on the craniums of individuals whom underwent autopsies (13). It was reported as 22.2 mm in the cadaveric study of Ali et al. (2018) (12). However, we mainly focused on evaluating the bony components that precisely form the lacrimal sac fossa. Therefore we did not evaluate the morphometric features of the nasolacrimal duct. On the other hand, Tao et al. (2018) reported the length of the lacrimal sac fossa as 13.40 mm in a cadaveric study which is lower than ours (12). This discrepancy may originate from the variational morphology of the facial structures. For instance, Liu et al. (2014) reported that African-Americans had a significantly greater nasion to subnasale distance than Chinese (24). Nonetheless, this relationship should be supported by further studies.

We also measured the angle between the lacrimal bone and the sagittal plane at the middle plane. It is difficult to perform osteotomy using an elevator or Kerrison rongeur in external DCR surgery in patients with a 90° angle between the lacrimal bone and sagittal plane. However, in endonasal DCR, this procedure is easily performed with Kerrison rongeur (25). The aforementioned angle was higher in males in our study (male, 132.73°; female, 131.46°). On the contrary, in the Japanese population, Sarbajna et al. (2019) reported higher angle in females (male, 131.69°; female, 132.00°) (11). However, in both studies, the angles

were not significantly different between genders (Anatolian, $p=0.647$; Japanese, $p=0.902$) (11). As a result of the wider angle between lacrimal bone and sagittal plane, it may be quite easy to create a bony window in the lacrimal sac fossa in Anatolian population during both the external and endonasal DCR surgeries.

In external DCR, bony elements between anterior and posterior lacrimal crests are removed to facilitate tear drainage for relief of epiphora. Therefore we measured the distances between anterior and posterior lacrimal crests at all three axial planes. It was initially relatively narrower at the upper plane (5.96 mm) and became wider at the middle plane (8.10 mm). It has the lowest value at the lower plane (4.63 mm).

Our study has several limitations. First of all it was designed as a retrospective study and included merely the normal anatomical structures. Therefore we did not compare our results with post-orbital fracture or post-DCR monitoring concepts to link with clinical practice. Moreover, due to the absence of a free-hand measurement tool in the digital workstation, we were unable to measure the maxilla and lacrimal bone lengths to analyze their contribution ratio in the formation of the lacrimal sac fossa.

Conclusion

To the best of our knowledge, this is the first study that investigates the detailed morphometric characteristics of the lacrimal sac fossa in such a demographic. Our results showed bone thicknesses were higher in males, while the angle between the lacrimal bone and the sagittal plane was higher in females. In the light of the results of our study, it can be concluded that osteotomies can be easily performed in external and endonasal DCR interventions in the Anatolian population. However, the anatomical characteristics of the lacrimal sac fossa should be well known to create an ostium of sufficient size, and in this context, we believe that our study will make an important contribution to the literature.

Ethical Approval: Ethical approval was waived by the local Ethics Committee in view of the retrospective nature of the study and all the procedures being performed were part of the routine care (Çukurova University Faculty of Medicine Non-interventional clinical research ethics committee Protocol No: 6.12.2019/94).

Author Contributions:

Concept: H.E., N.B., O.O.

Literature Review: H.E.

Design : H.E., N.B., O.O.

Data acquisition: H.E., U.A.P.

Analysis and interpretation: N.T.D., H.E.

Writing manuscript: H.E., Y.C., N.K.S.

Critical revision of manuscript: H.E., Y.C., U.A.P., N.K.S.

Conflict of Interest: The authors have no conflicts of interest to declare.

Financial Disclosure: Authors declared no financial support.

References

1. Kurihashi K, Imada, M, Yamashita A. Anatomical analysis of the human lacrimal drainage pathway under an operating microscope. *Int Ophthalmol*, 1991; 15 (6): 411-16.
2. Rajak SN, Psaltis AJ. Anatomical considerations in endoscopic lacrimal surgery. *Ann Anat*. 2019;224:28-32.
3. Ali MJ, Nayak JV, Vaezeafshar R, Li G, Psaltis AJ. Anatomic relationship of nasolacrimal duct and major lateral wall landmarks: cadaveric study with surgical implications. *Int Forum Allergy Rhinol*. 2014;4(8):684-88.
4. Woog JJ, Kennedy RH, Custer PL, Kaltreider SA, Meyer DR, Camara JG. Endonasal dacryocystorhinostomy. *Ophthalmology* 2001; 108 (12), 2369-77.
5. Ali MJ. Commentary: Subjective outcomes and quality of life following external dacryocystorhinostomy. *Indian J Ophthalmol*. 2021;69(7):1887.
6. Giordano Resti A, Vinciguerra A, Bordato A, Rampi A, Tanzini U, Mattalia L, et al. The importance of clinical presentation on long-term outcomes of external dacryocystorhinostomies: Our experience on 245 cases. *Eur J Ophthalmol*. 2021:11206721211059702.
7. Bulut A, Aslan MG, Oner V. Transcanalicular Multidiode Laser Versus External Dacryocystorhinostomy in the Treatment of Acquired Nasolacrimal Duct Obstruction. *Beyoglu Eye J*. 2021;6(4):315-19.
8. Chan W, Selva D. Ostium shrinkage after endoscopic dacryocystorhinostomy. *Ophthalmol*. 2013;120(8):1693-96.
9. Jin Y, Guo Y, Liu Y, Wang Y, Qin G, Tian Y, et al. Prevalence and Risk Factors of Dry Eye Symptoms after Successful Dacryocystorhinostomy for Patients with Lacrimal Passage Obstruction. *Eur J Ophthalmol*. 2021:11206721211069739.
10. Gore SK, Naveed H, Hamilton J, Rene C, Rose GE, Davagnanam I. Radiological Comparison of the Lacrimal Sac Fossa Anatomy Between Black Africans and Caucasians. *Ophthalmic Plast Reconstr Surg*. 2015;31(4):328-31.
11. Sarbajna T, Takahashi Y, Valencia MRP, Ito M, Nishimura K, Kakizaki H. Computed tomographic assessment of the lacrimal sac fossa in the Japanese population. *Ann Anat*. 2019;224:23-7.
12. Ali MJ, Schicht M, Paulsen F. Morphology and morphometry of lacrimal drainage system in relation to bony landmarks in Caucasian adults: a cadaveric study. *Int Ophthalmol*. 2018;38(6):2463-69.
13. Zhang L, Han D, Ge W, Xian J, Zhou B, Fan E, et al. 3D morphological classification of the nasolacrimal duct: Anatomical study for planning treatment of tear drainage obstruction. *Clin Anat*. 2021;34(4):624-33.
14. Zhang L, Han D, Ge W, Xian J, Zhou B, Fan E, et al. Anatomical and computed tomographic analysis of the interaction between the uncinat process and the agger nasi cell. *Acta Otolaryngol*. 2006;126(8):845-52.
15. Kang D, Park J, Na J, Lee H, Baek S. Measurement of Lacrimal Sac Fossa Using Orbital Computed Tomography. *J Craniofac Surg*. 2017;28(1):125-28.
16. Dalal DH, Smith HF. Developmental Changes in Morphology of the Middle and Posterior External Cranial Base in Modern Homo sapiens. *Biomed Res Int*. 2015;2015:324702.
17. Ramey NA, Hoang JK, Richard MJ. Multidetector CT of nasolacrimal canal morphology: normal variation by age, gender, and race. *Ophthalmic Plast Reconstr Surg*. 2013;29(6):475-80.
18. Colon GA. Principles and Practice of Ophthalmic Plastic Reconstructive Surgery. *Plast and Reconstr Surg*.

- 2000;105(7):2618-19.
19. Hartikainen J, Aho HJ, Seppa H, Grenman R. Lacrimal bone thickness at the lacrimal sac fossa. *Ophthalmic Surg Lasers*. 1996;27(8):679-84.
 20. Woo KI, Maeng HS, Kim YD. Characteristics of intranasal structures for endonasal dacryocystorhinostomy in asians. *Am J Ophthalmol*. 2011;152(3):491-98 e491.
 21. Alherabi A, Marglani O, Herzallah I, Shaibah H, Alaidarous T, Alkaff H, et al. Endoscopic anatomy of the lacrimal sac for dacryocystorhinostomy. A cadaveric study. *Saudi Med J* 2017; 38 (3):245-50.
 22. Yung MW, Logan BM. The anatomy of the lacrimal bone at the lateral wall of the nose: its significance to the lacrimal surgeon. *Clin Otolaryngol Allied Sci*. 1999;24(4):262-65.
 23. Purevdorj B, Dugarsuren U, Tuvaan B, Jamiyanjav B. Anatomy of lacrimal sac fossa affecting success rate in endoscopic and external dacryocystorhinostomy surgery in Mongolians. *Anat Cell Biol*. 2021;54(4):441-47.
 24. Liu Y, Kau CH, Talbert L, Pan F. Three-dimensional analysis of facial morphology. *J Craniofac Surg*. 2014;25(5):1890-94.
 25. Chong KK, Ali MJ. Primary Endoscopic Dacryocystorhinostomy. In: Ali MJ, editor. *Principles and Practice of Lacrimal Surgery*. 2nd ed. Singapore: Springer Nature Singapore Pte Ltd.; 2018. p. 211-19.