

## EVALUATION OF RARE MAXILLARY SINUS PNEUMATIZATIONS WITH CBCT AND ITS RELATIONSHIP WITH PATHOLOGY

### NADİR OLARAK GÖRÜLEN MAKSİLLER SİNÜS PNÖMATİZASYONLARININ KONİK IŞINLI BİLGİSAYARLI TOMOGRAFİ (KİBT) İLE RETROSPEKTİF OLARAK DEĞERLENDİRİLMESİ VE PATOLOJİ İLE İLİŞKİSİ

Beliz GÜRAY<sup>1</sup> , Hülya ÇAKIR KARABAŞ<sup>1</sup> , Sevde GÖKSEL<sup>1</sup> , Sedef Ayşe TAŞYAPAN<sup>1</sup> ,  
İlknur ÖZCAN<sup>2</sup> 

<sup>1</sup>Istanbul University, Faculty of Dentistry, Department of Oral and Maxillofacial Radiology, Istanbul, Turkey

<sup>2</sup>Biruni University, Faculty of Dentistry, Department of Oral and Maxillofacial Radiology, Istanbul, Türkiye

ORCID ID: B.G. 0000-0003-3961-2074; H.Ç.K. 0000-0001-9258-053X; S.G. 0000-0003-0092-7079; S.A.T. 0000-0003-1880-9276; İ.Ö. 0000-0001-9006-5630

**Citation/Atf:** Guray B, Cakir Karabas H, Goksel S, Tasyapan SA, Ozcan I. Evaluation of rare maxillary sinus pneumatizations with CBCT and its relationship with pathology. Journal of Advanced Research in Health Sciences 2023;6(2):166-172. <https://doi.org/10.26650/JARHS2023-1167981>

#### ABSTRACT

**Objective:** This study aims to evaluate maxillary sinus pneumatizations with Cone-beam Computed Tomography (CBCT) and correlate sinus pneumatizations with pathology.

**Material and Method:** Maxillary sinus pneumatization can be listed as frontal process pneumatization (FPP), zygomatic process pneumatization (ZPP), nasal cavity pneumatizations (NCP), palatal process pneumatizations (PPP), orbital process pneumatization (OPP), palatal pneumatization to sphenomaxillary plate (SPP), pneumatization caused by tooth loss, and alveolar bone pneumatization (ABP).

Istanbul University Faculty of Dentistry Department of Oral and Maxillofacial Radiology Volumetric Tomography images of patients entering the image region of the maxillary sinus were examined between December 2015 and December 2017 in this study.

The images were examined with the software called OnDemand 3D™ (Cybermed, California, USA). CBCT device is Scanora 3Dx brand CBCT (Scanora® 3Dx, Soredex, Tuusula, Finland). It was subjected to appropriate statistical analysis retrospectively using CBCT images.

**Results:** Our study has revealed that some pathologies such as mucosal thickening, polypoidal mucosal thickening, partial opacification, total opacification, and effusion are due to maxillary sinus pneumatization. Statistically significant differences were found between ABP, PPP, and ZPP with mucosal thickenings ( $p<0.05$ ).

Mucosal thickening is the most common which is seen with alveolar bone pneumatization statistically (36.5% on the right, 38% on the left).

In addition, a significant correlation was found between ABP and total opacification on the left side ( $p=0.001$ ).

**Conclusion:** CBCT is the most appropriate imaging method for imaging the pneumatization of the maxillary sinus. Knowing maxillary sinus pneumatizations is of great importance in terms of dentistry in order to prevent complications that may occur during and after surgical operations. Our study will make an important contribution to the dentistry literature in order to define rare maxillary sinus pneumatizations and to explain the relationship of these pneumatizations with pathology.

**Key words:** Pneumatization, CBCT, maxillary sinus

#### ÖZ

**Amaç:** Bu çalışmanın amacı, Konik Işınli Bilgisayarlı Tomografi (KİBT) ile maksiller sinüs pnömatizasyonlarının değerlendirilmesi ve pnömatizasyonlarının sinüs patolojileri ile ilişkilendirilmesidir.

**Gereç ve Yöntem:** Maksiller sinüs pnömatizasyonlarını; frontal proses pnömatizasyonları, zigomatik proses pnömatizasyonları, palatal proses pnömatizasyonları, orbital proses pnömatizasyonları, palatinalden sfenomaksiller plakaya pnömatizasyonlar dışı kayının neden olduğu pnömatizasyonlar ve alveolar kemiğe pnömatizasyon olarak sıralayabiliriz. Bu çalışmada İstanbul Üniversitesi Diş Hekimliği Fakültesi Ağız Diş Çene Radyolojisi Anabilim Dalında 2015-2017 yılları arasında alınan, maksiller sinüsün görüntüleme alanına girdiği KİBT görüntüleri incelenmiştir. Scanora 3Dx marka KİBT cihazı (Scanora® 3Dx, Soredex, Tuusula, Finland) ile alınan görüntüler, OnDemand 3D™ (Cybermed, California, USA) adlı yazılım ile incelenmiştir. Retrospektif olarak değerlendirilen görüntüler uygun istatistiksel analize tabi tutulmuştur.

**Bulgular:** Çalışmamız, mukozal kalınlaşma, polipoidal mukozal kalınlaşma, parsiyel opasifikasyon, total opasifikasyon ve efüzyon gibi bazı patolojilerin maksiller sinüs pnömatizasyonlarına bağlı olduğunu ortaya çıkarmıştır. İstatistiksel olarak en çok karşılaşılan alveolar kemik pnömatizasyonlarında mukozal kalınlaşmadır (%36,5 sağda ve %38 solda).

Alveolar kemik pnömatizasyonu, palatal proses pnömatizasyonu ve zigomatik kemik pnömatizasyonu'nun mukozal kalınlaşmalar ile arasında istatistiksel olarak anlamlı farklılıklar bulunmuştur ( $p<0,05$ ). Ayrıca sol tarafta alveolar kemik pnömatizasyonu ile total opasifikasyon arasında anlamlı ilişki bulunmuştur ( $p=0,001$ ).

**Sonuç:** Maksiller sinüs ile ilgili pnömatizasyonlarını görüntüleme de uygun görüntüleme yöntemi KİBT' tir. Cerrahi operasyonlar sırasında ve sonrasında oluşabilecek komplikasyonları önlemek amacıyla maksiller sinüs pnömatizasyonlarının bilinmesi diş hekimliği açısından büyük önem arz etmektedir.

Bizim çalışmamız; nadir görülen maksiller sinüs pnömatizasyonlarını tanımlamak ve bu pnömatizasyonların patoloji ile ilişkisi açıklamak amacıyla diş hekimliği literatürüne önemli katkı sağlayacaktır.

**Anahtar Kelimeler:** Pnömatizasyon, KİBT, maksiller sinüs

**Corresponding Author/Sorumlu Yazar:** Beliz GÜRAY E-mail: beliz1986@gmail.com

**Submitted/Başvuru:** 28.08.2022 • **Revision Requested/Revizyon Talebi:** 03.09.2022 • **Last Revision Received/Son Revizyon:** 03.03.2023

• **Accepted/Kabul:** 03.03.2023 • **Published Online/Online Yayın:** 26.06.2023



This work is licensed under Creative Commons Attribution-NonCommercial 4.0 International License

## INTRODUCTION

The maxillary sinus is the largest paranasal sinus, and the first to form (1, 2). The maxillary sinus volume at birth is 6-8 ml (2). Maxillary sinus size is approximately 34x33x23 mm in adults, and its volume is 14.75 ml (3). The anterior/posterior part is the maximum volume (2). The maxillary sinus volume decreases after growth reaches its maximum (4). As the minerals in the bone matrix of the body are lost, this also affects the volume of the maxillary sinus. Maxillary sinus dimensions are affected by anatomical variations. The volume of the maxillary sinus is significant in the planning of surgical treatment (5).

The maxillary sinus resembles a pyramid in shape. The base of this pyramid is formed by the lateral wall of the nasal cavity; the apex is towards the zygomatic process and the anterior wall is associated with the fossa canina. The maxillary sinus is adjacent to the nasal cavity medially and the zygoma laterally (1, 3).

Maxillary sinus pneumatization is a physiological process. Pneumatization begins in the ethmoid sinuses, then in the maxillary sinus, sphenoid sinuses, and frontal sinuses. Although the pneumatization of the paranasal sinuses is different on the right and left, it can also vary from person to person (6).

The sinus with the most pneumatization is the frontal sinus, followed by the ethmoid and sphenoid sinuses, respectively (7). Maxillary sinus pneumatization is rare. Pneumatization causes increased sinus volume (8). The maxillary sinus pneumatization begins in the third week of pregnancy and continues to be pneumatized after birth (4, 7). In the first three years, growth is rapid, and change is slower between ages 3 and 7 (4). Between 7-12 years, growth accelerates again and slows further into adulthood (4). Pneumatization of the maxillary sinus ends after the third molars erupt at age 20 (8, 9).

The panoramic radiograph gives limited information about maxillary sinus pneumatization. CBCT (cone beam computed tomography) is a required imaging method in dentistry (10). CBCT plays an essential role in diagnosing anatomical variations (11). CBCT is a gold standard and significant imaging method. (10). Sinus pneumatization is best evaluated with CBCT (8).

This study aims to evaluate maxillary sinus pneumatizations with CBCT and to associate these pneumatizations with

pathology. Rare pneumatizations will contribute to the dentistry literature, and their relationship with pathology will enable dentists to obtain information before surgical operations.

## MATERIAL and METHODS

Approval for this study was obtained by the Istanbul University Faculty of Dentistry Clinical Research Ethics Committee (Date/File no:28.08.2018/72). The study was carried out by the Helsinki Declaration of Human Rights guidelines at every stage. Patients admitted to the Department of Oral and Maxillofacial Radiology at Istanbul University Faculty of Dentistry between 2015 and 2017 for any reason were examined, and 4158 patients who entered the field of imaging of the maxillary sinus were included in the study. These Fields of View (FOV) were 8x10,14x16,24x16 mm. Data were evaluated by using technical properties of 60-90 kVp, 4-10mA, 18-34s, and 0.2 mm slice thickness in the coronal, axial, and sagittal planes. Patients were excluded from the study in the presence of a history of maxillofacial trauma or surgery, any syndrome, and artifacts that reduce image quality. A total of 621 patients (1242 maxillary sinuses), aged 18-51, over 51 years old were evaluated retrospectively with CBCT images. Patient images were obtained with a Scanora 3Dx brand CBCT device (Scanora® 3Dx, Soredex, Tuusula, Finland). Images were analyzed using the device's original program OnDemand 3D™ (Cybermed, California, USA), and a medical monitor.

Radiological evaluation was performed by an oral and maxillofacial radiologist and four investigators. CBCT images were examined in axial, sagittal, and coronal sections, and maxillary sinus pneumatization was detected. Maxillary sinus pathologies, mucosal thickening, polypoidal mucosal thickening, partial opacity, total opacity, and effusion were examined in 5 categories.

Data were analyzed using the Statistical Package for and Social Sciences (SPSS) program. Chi-square tests (Pearson Chi-square, Yates Chi-square, and Fisher Exact Test) were used to compare categorical variables. A p-value of <0.05 was considered statistically significant in all analyses.

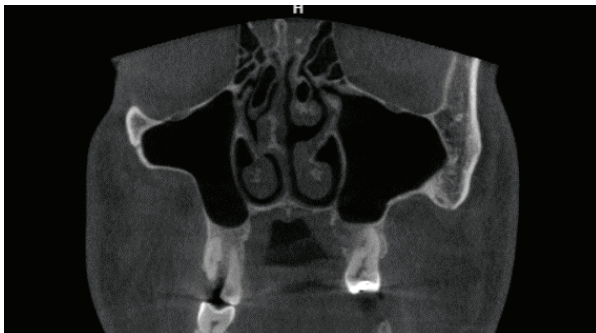


Figure 1: Frontal process pneumatization

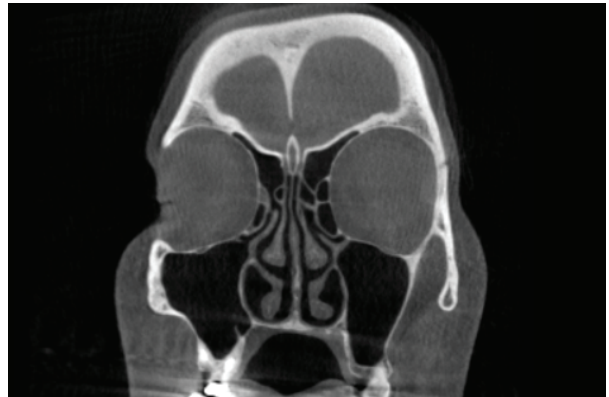

Figure 2: Zygomatic process pneumatization

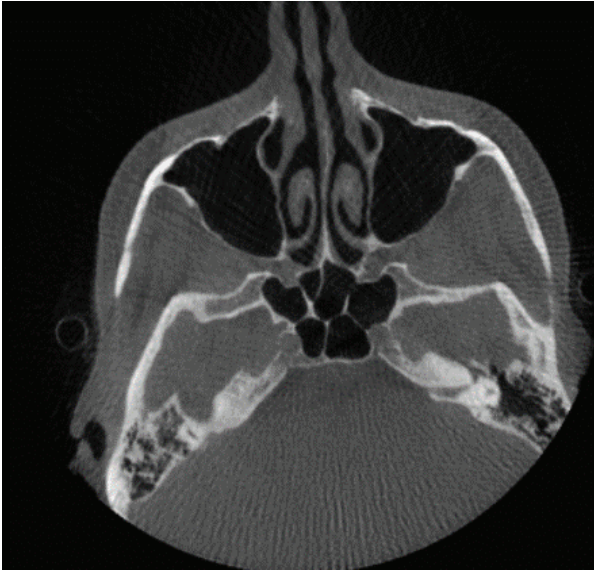


Figure 3: Zygomatic process pneumatization

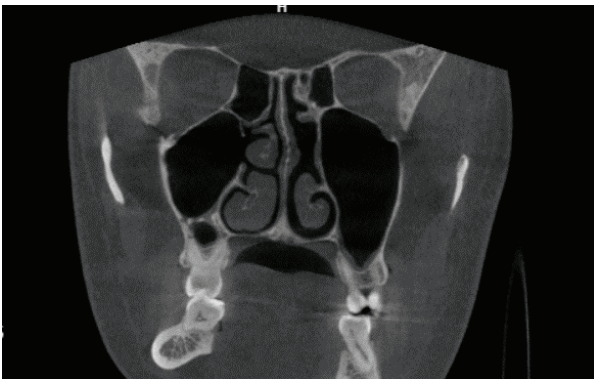


Figure 4: Maxillary sinus pneumatization into the nasal cavity

Maxillary sinus pneumatization is classified as:

-Frontal process pneumatization: This type of pneumatization is pneumatization towards the frontal recess (Figure 1). It is an extremely rare pneumatization (12). This is a pneumatization to the superomedial side.

Zygomatic process pneumatization: This type of pneumatization pneumatizes the malar bone, and this type of pneumatization pneumatizes laterally (Figure 2,3) (7).

- Maxillary sinus pneumatization into the nasal cavity: The most common anatomical variation is concha bullosa in the middle turbinate. These are called concha bullosa or bullous concha (13). Some variations can cause nasal congestion or facial pain. Nasal turbinate variations can be easily diagnosed with CBCT (14). This type of pneumatization is rare, and the maxillary sinus is pneumatized into the nasal cavity (Figure 4).
- Pneumatization to the orbit: This type of pneumatization is of two types, wavy tapered and vertical (Figure 5) (12).

- Pneumatization from palatal to sphenomaxillary plate: This type of pneumatization connects the maxillary sinus to the sphenoid sinus via the septum (15). Sphenomaxillary plate pneumatization is essential to avoid orbital complications during maxillary sinus surgery (12).
- Palatal pneumatization: This type of pneumatization pneumatizes the hard palate towards the midline (Figure 6) (12).
- Pneumatizations caused by tooth loss (inferior pneumatization, alveolar): After tooth extraction, alveolar bone size reduction is observed. This causes insufficient bone volume, and dental implant placement becomes difficult due to reduced bone volume. Bone resorption is observed after tooth extraction due to maxillary sinus pneumatization (16). Pneumatization with tooth loss may require various clinical treatments (e.g., sinus lift, bone graft applications, use of oral implants) (5, 15).

The rate and degree of alveolar pneumatization are affected by some conditions. These situations are:

1. The cortical bone layer of the root may break during tooth extraction, and the maxillary sinus may become pneumatized.
2. A significant defect occurs in the alveolar bone, unlike other teeth, after molar extraction (Figure 7) (7,8).

Rare pneumatizations will contribute to the dentistry literature, and their relationship with pathology will enable dentists to obtain information before surgical operations.

## RESULTS

A total of 621 patients (1242 maxillary sinuses) aged 18-51, over 51 years old, were evaluated retrospectively with CBCT images.

Maxillary sinus pneumatization can be listed as frontal process pneumatization (FPP), zygomatic process pneumatization (ZPP), nasal cavity pneumatization (NCP), palatal process pneumatizations (PPP), orbital process pneumatization (OPP), palatal pneumatization to sphenomaxillary plate (SPP), pneumatization caused by tooth loss, and alveolar bone pneumatization (ABP).

It has been revealed that some pathologies such as mucosal thickening, polypoidal mucosal thickening, partial opacification, total opacification, and effusion are due to maxillary sinus pneumatization.

Table 1 shows the pneumatizations and pneumatizations associated with right and left mucosal thickening, polypoidal mucosal thickening, partial opacification, total opacification, and effusion.

As seen in Table 1, there is a significant relationship between ABP and mucosal thickening ( $p=0.006$ ) and polypoidal thickening ( $p=0.008$ ) on the right side ( $p<0.05$ ), but there is

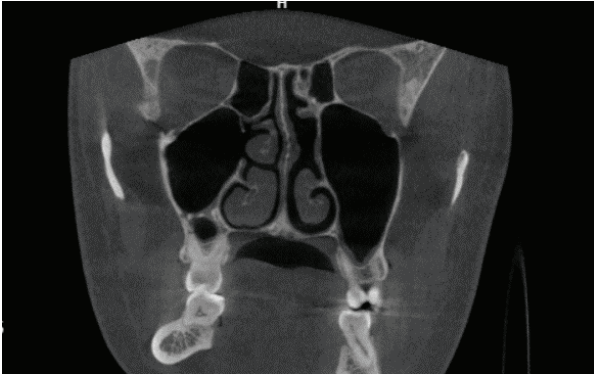


Figure 5: Pneumatization to the orbit (Orbital)

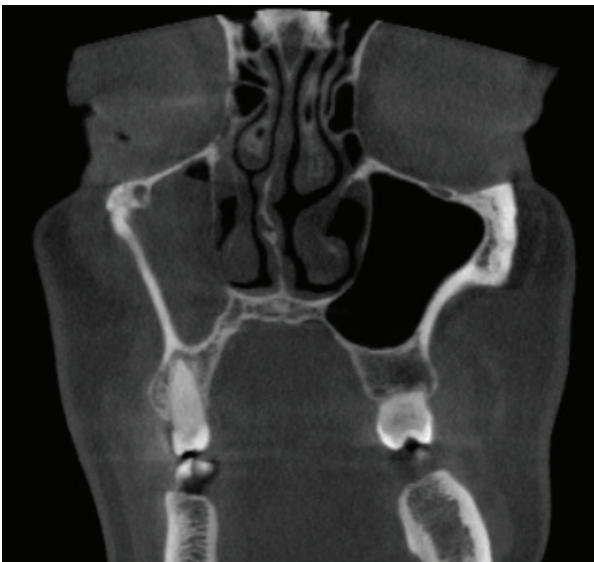

Figure 6: Pneumatization in the palatal

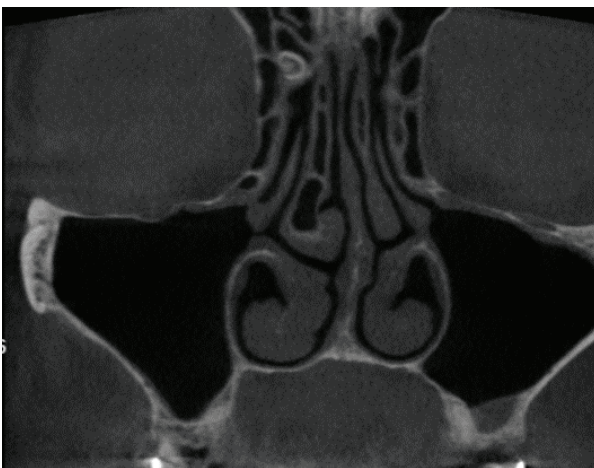


Figure 7: Alveolar pneumatization

a substantial relationship between ABP and only mucosal thickening ( $p=0.016$ ) on the left side ( $p<0.05$ ). This relationship tells us that ABP affects maxillary sinus pathology in both dimensions of thickening.

There is also a significant relationship between PPP and polypoidal mucosal thickening ( $p=0.008$ ) on the right side ( $p<0.05$ ). This relationship tells us that PPP affects maxillary sinus pathology only at the extent of partial mucosal thickening.

There is also a significant relationship between ZPP and mucosal thickening ( $p=0.032$ ) on the right side ( $p<0.05$ ). This relationship shows that ZPP affects maxillary sinus pathology in one dimension called mucosal thickening.

On the left side, ABP and total opacification have an important relationship ( $p=0.001$ ,  $p<0.05$ ). This means that total opacification affects maxillary sinus pathology. Also, there is a significant relationship between ABP and mucosal thickening ( $p=0.016$ ) on the left side ( $p<0.05$ ).

Table 2 shows the distribution of alveolar pneumatization by age groups.

According to the chi-square test, right and left alveolar pneumatizations show significant differences according to age groups ( $p<0.05$ ). From this analysis, it can be determined that alveolar pneumatization increases with increasing age.

Kalavagunta and Reddy detected 8% of maxillary sinus pneumatization in the UK population (3.5% male and 4,5 female) (8,12).

200 CBCT were detected, and 16 patients had pneumatizations in their study.

## DISCUSSION

Pneumatization begins in the ethmoid sinuses, then in the maxillary sinus, sphenoid sinuses, and frontal sinuses. Although the pneumatization of the paranasal sinuses is different on the right and left, it can also vary from person to person (6).

The cause of pneumatization is not fully understood. Possible causes are heredity, craniofacial configuration, growth hormones, bone density, sinus surgery, sinus air pressure, and age-related process. (7, 17). Another theory is trauma that precedes maxillary sinus pneumatization (18).

If the patient is asymptomatic and the pneumatization does not affect other structures, it is called hypersinus (5). If the patient has symptomatic and local pressure symptoms and the pneumatization occurs to other structures, it is called pneumosinus (4). The general appearance of the patient is a facial deformity. Other possible manifestations are cheek pain with pressure, nasal congestion, and sinusitis (18). These deformities require surgical operation.

The aim is to evaluate maxillary sinus pneumatizations with CBCT and to correlate the pneumatizations with any associated pathology. The pneumatizations examined will contribute to the dentistry literature and enable dentists to obtain information about their relationship with pathology before surgical operations.

**Table 1:** Pneumatization types and the relationship with maxillary sinus pathologies

	No finding			Mucosal thickening			Polypoidal mucosal thickening			Partial opacification			Total opacification			Effusion			Total P value		
	Absent		P value	Absent		P value	Absent		P value	Absent		P value	Absent		P value	Absent		P value			
	n (%)	n (%)		n (%)	n (%)		n (%)	n (%)		n (%)	n (%)		n (%)	n (%)		n (%)	n (%)			n (%)	n (%)
Right	ABP	76 (66.1)	39 (33.9)	0.987	73 (63.5)	42 (36.5)	0.006	80 (69.6)	35 (30.4)	0.008	108 (93.9)	7 (6.1)	0.271*	114 (99.1)	1 (0.9)	0.698**	110 (95.7)	5 (4.3)	1*	115	
	PPP	9 (90.0)	1 (10.0)	0.201*	6 (60.0)	4 (40.0)	0.849*	4 (40)	6 (60)	0.008**	10 (100)	0 (0)	1**	9 (90)	1 (10)	0.151**	10 (100)	0 (0)	1**	10	
	ZPP	11 (47.8)	12 (52.2)	0.06	17 (73.9)	6 (26.1)	0.032	17 (73.9)	6 (26.1)	0.751*	23 (100)	0 (0)	1**	23 (100)	0 (0)	1**	22 (95.7)	1 (4.3)	1**	23	
	FRP	5 (62.5)	3 (37.5)	1**	4 (50)	4 (50)	1*	7 (87.5)	1 (12.5)	1**	8 (100)	0 (0)	1**	8 (100)	0 (0)	1**	8 (100)	0 (0)	1**	8	
	OPP	0	0	-	0	0	-	0	0	-	0	0	-	0	0	-	0	0	0	-	0
	SPP	0	0	-	0	0	-	0	0	-	0	0	-	0	0	-	0	0	0	-	0
Left	NCP	2 (66.7)	1 (33.3)	1**	2 (66.7)	1 (33.3)	1**	2 (66.7)	1 (33.3)	0.512**	3 (100)	0 (0)	1**	3 (100)	0 (0)	1**	3 (100)	0 (0)	1**	3	
	ABP	73 (60.3)	48 (39.7)	0.153	75 (62)	46 (38)	0.016	95 (78.5)	26 (21.5)	0.347	114 (94.2)	7 (5.8)	0.225*	116 (95.9)	5 (4.1)	0.001**	113 (93.4)	8 (6.6)	0.138*	121	
	PPP	25 (83.3)	5 (16.7)	0.039	13 (43.3)	17 (56.7)	0.32	20 (66.7)	10 (33.3)	0.267	29 (96.7)	1 (3.3)	1**	30 (100)	0 (0)	1**	27 (90)	3 (10)	0.104**	30	
	ZPP	11 (57.9)	8 (42.1)	0.457	10 (52.6)	9 (47.4)	0.968	17 (89.5)	2 (10.5)	0.233*	18 (94.7)	1 (5.3)	0.501**	19 (100)	0 (0)	1**	19 (100)	0 (0)	1**	19	
	FRP	10 (62.5)	6 (37.5)	0.774	9 (56.3)	7 (43.8)	0.741	11 (68.8)	5 (31.3)	0.755*	16 (100)	0 (0)	1**	16 (100)	0 (0)	1**	16 (100)	0 (0)	1**	16	
	OPP	3 (75)	1 (25)	1**	2 (50)	2 (50)	1**	3 (75)	1 (25)	1**	4 (100)	0 (0)	1**	4 (100)	0 (0)	1**	4 (100)	0 (0)	1**	4	
SPP	0	0	-	0	0	-	0	0	-	0	0	-	0	0	-	0	0	0	-	0	
NCP	2 (40)	3 (60)	0.344**	4 (80)	1 (20)	0.375**	4 (80)	1 (20)	1**	5 (100)	0 (0)	1**	5 (100)	0 (0)	1**	5 (100)	0 (0)	1**	5		

\* Yates Chi-square; \*\* Fisher's exact test, ABP: Alveolar bone pneumatization, PPP: Palatal process pneumatization, ZPP: Zygomatic process pneumatization, FRP: Frontal process pneumatization, OPP: Orbital process pneumatization, SPP: Palatal pneumatization to sphenomaxillary plate, NCT: Nasal cavity process pneumatizations

**Table 2:** Distribution of alveolar pneumatization according to age

	Alveolar right			Total	p	Alveolar left			Total	p
			Total					Total		
	-	+				-	+			
Age Groups	18-30	180	31	211		176	35	211		
	19-50	182	35	217	0.012*	180	37	217		0.044*
	51+	144	49	193		144	49	193		
Total		506	115	621		500	121	621		

\*Chi-square test

Preoperative evaluation is critical in evaluating maxillary sinus variations and detecting pathological problems (10).

This study provides information about different pneumatizations. CBCT is a gold standard that contributes to different pneumatizations. In this study, CBCT was used to identify pneumatizations. These pneumatizations are frontal process pneumatizations, zygomatic process pneumatizations, orbital pneumatizations, pneumatizations from palatal to sphenomaxillary plate, and pneumatizations caused by tooth loss (pneumatizations to alveolar bone). The present research made the following contributions:

- broadened our knowledge between pneumatizations and pathologies.
- provided data on rare pneumatizations

The prevalence of pneumatization in Turkey is 27.7%.

In the literature, the overall pneumatization in the world is 8% to 83.2%.

Schuh et al. reported the rate of alveolar pneumatization as 50% and as 100% by Lana et al. Shaidi et al. found alveolar pneumatization at a rate of 57.5% (10). With CBCT, it is possible to detect anatomical variations and perform more successful surgical applications.

Ketenci et al. found 244 alveolar pneumatizations in 300 patients in the CBCT evaluation in their study (8). In their assessment, mucosal thickening was stated as 63%. In this research, it was determined as 42% on the right and 46% on the left. Ketenci et al. achieved a higher result than this study.

Lana et al. 83.2% reported alveolar pneumatization in the Brazilian population (19). In 2003, Kalavagunta and Reddy detected 8% of maxillary sinus pneumatization in the UK population (8, 12). In 2015, Göçmen et al. reported that maxillary sinus pneumatization was 27.7% in the Marmara

region of Turkey (9). Alveolar pneumatization increases with age (8). The results of the authors' study are similar to this finding.

The rate of mucosal thickening was stated as 48.8% and reported the rate of mucosal thickening as 27.5% (8). In this study, the incidence of mucosal thickening was 36.5%. The results of this study are similar to these two studies.

Yang et al. reported 8 cases of maxillary sinus pneumatization into the nasal cavity (20). Timurlen et al. reported the ninth case (21). In this study, maxillary sinus pneumatization occurred in 4 nasal cavities.

Kalavagunta et al. reported sphenomaxillary plaque pneumatization as 3%, frontal process pneumatization 0.5%, and pneumatization to the orbit as 6% (12). This study found 1 pneumatization to the orbit and 9 pneumatizations to the frontal process.

## CONCLUSION

CBCT best detects pneumatizations of the maxillary sinus. Maxillary sinus pneumatizations and pathologies should be diagnosed and understood to prevent complications that may occur during and after surgical operations. Rare maxillary sinus pneumatizations will make a significant contribution to the dentistry literature. Maxillary sinus pneumatizations are observed due to some pathologies such as mucosal thickening, polypoidal mucosal thickening, partial opacification, total opacification, and effusion. The most common is mucosal thickening with alveolar bone pneumatizations.

To prevent complications that may occur during and after surgical operations, it is necessary to know the pneumatizations of the maxillary sinus. Pathologies with maxillary sinus pneumatizations will contribute to the dentistry literature.

**Ethics Committee Approval:** This study was approved by Istanbul University Faculty of Dentistry Clinical Research Ethics Committee (Date: 28.08.2018, No: 72).

**Peer Review:** Externally peer-reviewed.

**Author Contributions:** Conception/Design of Study- B.G., H.Ç.K.; Data Acquisition- S.G., S.A.T.; Data Analysis/Interpretation- İ.Ö.; Drafting Manuscript- B.G.; Critical Revision of Manuscript- H.Ç.K.; Final Approval and Accountability- İ.Ö., B.G.; Material and Technical Support- S.G., S.A.T.; Supervision- İ.Ö., B.G.

**Conflict of Interest:** The authors have no conflict of interest to declare.

**Financial Disclosure:** The authors declared that this study has received no financial support.

## REFERENCES

1. Iwanaga J, Wilson C, Lachkar S, Tomaszewski KA, Walocha JA, Tubbs RS. Clinical anatomy of the maxillary sinus: application to sinus

- floor augmentation. *Anat Cell Biol* 2019;52(1):17-24.
2. Scuderi AJ, Harnsberger HR, Boyer RS. Pneumatization of the paranasal sinuses: normal features of importance to the accurate interpretation of CT scans and MR images. *AJR Am J Roentgenol* 1993;160(5):1101-4.
  3. Demir K. Polipozis Tanılı Hastalarda Endonazal Anatomik Varyasyonların Görülme Sıklığının Tespiti ve Toplum ile Karşılaştırılması (dissertation). İstanbul: İstanbul Eğitim ve Araştırma Hastanesi K.B.B. Kliniği. 2006.
  4. Lawson W, Patel ZM, Lin FY. The development and pathologic processes that influence maxillary sinus pneumatization. *Anat Rec (Hoboken)* 2008;291(11):1554-63.
  5. Anbiaee N, Khodabakhsh R, Bagherpour A. Relationship between Anatomical Variations of Sinonasal Area and Maxillary Sinus Pneumatization. *Iran J Otorhinolaryngol* 2019;31(105):229-34.
  6. Al-Taei JA. Computed tomographic measurement of maxillary sinus volume and dimension in correlation to the age and gender (comparative study among individuals with dentate and edentulous maxilla). *J BaghColl Dent* 2013;25(1):87-93.
  7. Sharan A, Madjar D. Maxillary sinus pneumatization following extractions: a radiographic study. *Int J Oral Maxillofac Implants* 2008;23(1):48-56.
  8. Ketenci F, Yalçın Yeler D, Koraltan M, Ünal Y. Maksiller sinüste alveolar pnömatizasyon ve ilişkili faktörlerin panoramik ve kıbt görüntüleme yöntemleri ile değerlendirilmesi. *7tepe Klinik* 2019;15(3):339-44.
  9. Göçmen G, Borahan MO, Aktop S, Dumlu A, Pekiner FN, Göker K. Effect of septal deviation, concha bullosa and Haller's cell on maxillary sinus's inferior pneumatization; a retrospective study. *Open Dent J* 2015;9:282-6.
  10. Shahidi S, Zamiri B, Momeni Danaei S, Salehi S, Hamedani S. Evaluation of anatomic variations in maxillary sinus with the aid of cone beam computed tomography (CBCT) in a population in south of Iran. *J Dent (Shiraz)* 2016;17(1):7-15.
  11. De Miranda CM, de Miranda Maranhão CP, Arraes FM, Padilha IG, De Farias LD, de Araujo Jatobá, MS. Anatomical variations of paranasal sinuses at multislice computed tomography: what to look for. *Radiol Bras* 2011;44(4):256-62.
  12. Kalavagunta S, Reddy KT. Extensive maxillary sinus pneumatization. *Rhinology* 2003;41(2):113-7.
  13. Rusu MC, Sava CJ, Stoiculescu MD. Bilateral pneumatization of middle and superior nasal turbinates. *Romanian Journal of Military Medicine* 2019;123(3):196-201.
  14. Ozcan KM, Selcuk A, Ozcan I, Akdogan O, Dere H. Anatomical variations of nasal turbinates. *J Craniofac Surg* 2008;19(6):1678-82.
  15. Selcuk A, Ozcan KM, Akdogan O, Bilal N, Dere H. Variations of maxillary sinus and accompanying anatomical and pathological structures. *J Craniofac Surg* 2008;19(1):159-64.
  16. Lombardi T, Bernardello F, Berton F, Porrelli D, Rapani A, Camurri Piloni A, et al. Efficacy of alveolar ridge preservation after maxillary molar extraction in reducing crestal bone resorption and sinus pneumatization: a multicenter prospective case-control study. *Biomed Res Int* 2018;2018: 9352130. doi: 10.1155/2018/9352130.
  17. Cavalcanti MC, Guirado TE, Sapata VM, Costa C, Pannuti CM, Jung RE, César Neto JB. Maxillary sinus floor pneumatization and alveolar ridge resorption after tooth loss: a cross-sectional study. *Braz Oral Res* 2018;32(e64):1-10.
  18. Nayak DR, Pujary K, Ramaswamy B, Mahesh SG, Muddaiah D. Anterior pneumatization of the maxillary sinus - Presenting as a facial swelling. *Indian J Otolaryngol Head Neck Surg* 2007;59(3):277-9.
  19. Pelinsari Lana J, Moura Rodrigues Carneiro P, de Carvalho Machado V, Eduardo Alencar de Souza P, Ricardo Manzi F, Campolina Rebello Horta M. Anatomic variations and lesions of the maxillary sinus detected in cone beam computed tomography for dental implants. *Clin Oral Implants Res* 2012;23(12):1398-403.
  20. Yang BT, Chong VFH, Wang ZC, Xian JF, Chen QH. CT appearance of pneumatized inferior turbinate. *Clin Radiol* 2008;63(8):901-5.
  21. Timurlenk E, Eğilmez OK, Uzun L, Acar G, Kafkaslı Ç. Common cavity of pneumatized inferior turbinate and maxillary sinus: A case report. *CausePedia* 2014;3:1-5.