

ORIGINAL ARTICLE

# Minimally Invasive Atrial Septal Defect Closure: A Single Center Experience

## Minimal İnvaziv Atriyal Septal Defekt Kapatılması: Tek Merkez Deneyimi

<sup>1</sup>Mehmet Çelik , <sup>1</sup>Asım Çağrı Günaydın , <sup>1</sup>Mehmet Özlükü 

<sup>1</sup>Başkent Üniversitesi Konya Uygulama ve Araştırma Merkezi

Correspondence

Mehmet Çelik, Başkent Üniversitesi Konya Uygulama ve Araştırma Merkezi, Hocacıhan Mahallesi Saray Caddesi No:1, 42080 Selçuklu/Konya/TÜRKİYE

E-Mail: mehmer1981@gmail.com

How to cite ?

Çelik M. , Günaydın A. Ç. , Özlükü M. Minimally Invasive Atrial Septal Defect Closure: A Single Center Experience. Genel Tıp Dergisi. 2022; 32(6): 756-760.

ABSTRACT

**Objective:** In this study, we wanted to share our clinic's minimally invasive atrial septal defect closure results.

**Materials and methods:** Thirty-six patients who underwent minimally invasive atrial septal defect closure in our clinic were included in the study between September 2016 and September 2022. Patients who underwent atrial septal defect closure accompanying another cardiac anomaly were excluded from the study. Redo cases in which the sternum was opened before were excluded from the study. Demographic data, physical examination findings, transthoracic echocardiographic and angiographic examination data of the patients were obtained retrospectively from the database of our hospital. Patients with genetic anomalies were noted.

**Results:** Thirty-six patients (male:11 (31%), female:25 (69%)) were included in the study. The median age of the patients was 57 months (IQR: 43-83 months), and the median body weight was 16 kg (IQR: 12.7-21.7 kg). A chromosomal anomaly was detected in two (5.5%) patients. A Secundum atrial septal defect was detected in 31 (86%) patients, high venosum atrial septal defect in four (11%), and low venosum atrial septal defect in one (3%). Partial sternotomy was performed in 20 patients (56%), and total sternotomy was performed in 16 (44%). The median cardiopulmonary bypass time of the patients was 46.5 minutes (IQR: 36.8-57.2 minutes), and the median X-clamp times was 21.5 minutes (IQR: 15-28.7 minutes). Nine (25%) patients defects were closed with a patch, and 27 (75%) were closed primarily. No mortality was observed in any patient. The median hospital stay was five days (IQR: 4-5 days).

**Discussion:** In our study, no mortality or morbidity was found in cases of atrial septal defect closure performed with the minimally invasive method. Minimally invasive atrial septal defect closure can be performed with similar safety and better cosmetic results compared to the standard method. The aim of the study is to present our own experiences on this subject.

**Keywords:** Atrial Septal Defect, Congenital Heart Disease, Minimally Invasive Cardiac Surgery

ÖZ

**Amaç:** Bu çalışmada, kliniğimizde minimal invaziv atriyal septal defekt kapatılması yapılan hastaların sonuçlarını paylaşmak istedik.

**Gereç ve Yöntemler:** Kliniğimizde Eylül 2016-Eylül 2022 tarihleri arasında minimal invaziv yöntemle atriyal septal defekt kapatılması yapılan 36 hasta çalışmaya alındı. Başka bir kardiyak anomaliye eşlik eden atriyal septal defekt kapatılması yapılan hastalar çalışma dışı bırakıldı. Sternumun daha önce açıldığı redo vakalar çalışma dışı bırakıldı. Hastaların demografik verileri, fizik muayene bulguları, transtorasik ekokardiyografik ve anjiyografik incelemelerine ait veriler hastanemiz veri tabanından retrospektif olarak elde edildi. Genetik anomalisi olan hastalar not edildi.

**Bulgular:** Çalışmaya 36 hasta (erkek:11, kız:25) dâhil edildi. Hastaların yaşları medyan 57 ay (IQR: 43-83 ay) ve vücut ağırlıkları medyan 16 kg (IQR: 12,7-21,7 kg) olarak saptandı. İki (%5,5) hastada kromozom anomalisi saptandı. Otuz bir (%86) hastada sekundum atriyal septal defekt, dört (%11) hastada high venosum atrial septal defekt ve bir (%3) hastada low venosum atriyal septal defekt saptandı. Yirmi hastada (%56) parsiyel sternotomi, 16 (%44) hastada total sternotomi yapıldı. Hastaların kardiyopulmoner by-pass süreleri medyan 46,5 dakika (IQR: 36,8-57,2 dakika) ve X klem süreleri medyan 21,5 dakika (IQR: 15-28,7 dakika) olarak saptandı. Dokuz (%25) hastanın defekti yama ile, 27 (%75) hastanın defekti ise primer kapatıldı. Hiçbir hastada mortalite izlenmedi. Hastanede kalış süresi medyan 5 gün (IQR: 4-5 gün) olarak saptandı.

**Sonuç:** Çalışmamızda minimal invaziv yöntemle yapılan atriyal septal defekt kapatılması olgularında mortalite ve morbiditeye rastlanmadı. Minimal invaziv atriyal septal defekt kapatılması standart yöntemle oranla benzer güvenlikle ve daha iyi kozmetik sonuçlarla yapılabilir. Çalışmanın amacı bu konudaki kendi deneyimlerimizi sunmaktır.

**Anahtar Kelimeler:** Atriyal Septal Defekt, Konjenital Kalp Hastalığı, Minimal İnvaziv Kalp Cerrahisi

### Introduction

Minimally invasive surgery is an almost standardized approach today in relatively 'simple' cardiac anomalies such as atrial septal defect (ASD), mainly due to its satisfactory cosmetic results and reducing surgical trauma, inflammatory process, and

postoperative pain (1). Today, closure with percutaneous devices seems to be the first preferred method for ASD closure (1). However, when it is impossible to place the device anatomically, the surgical option comes to the fore. Although rare, nickel content in percutaneous occlusion devices may cause allergic reactions

that may require the removal of the device (2-5). Percutaneous occluder device embolism may also occur (6). Moreover, percutaneous ASD closure is a more costly procedure in our country.

Today, the minimally invasive approach results are excellent, like classical sternotomies. Moreover, it has less pain, shorter hospital stays, and more satisfactory cosmetic results. Therefore, minimally invasive ASD closure can be considered a safe and reasonable alternative to conventional sternotomy (7).

## Material and Method

This study examined 36 patients who underwent minimally invasive ASD closure in our clinic between September 2016 and September 2022. Patients who underwent ASD closure with accompanying another cardiac anomaly were excluded from the study. In addition, redo cases in whom the sternum was opened before were excluded from the study. Data were analyzed retrospectively from the hospital database. This study was approved by our institution's Medical and Health Sciences Research Board (Project no: KA22/400).

Detailed physical examinations and laboratory tests of all patients were performed, and additional cardiac anomalies and genetic anomalies were noted. Patients who were closed with a percutaneous device were excluded from the study.

All patients were evaluated echocardiographically immediately after the surgical procedure and before discharge. In addition, they were examined for residual defect and pericardial effusion. Antibiotic prophylaxis was given until the chest drainage tubes were removed.

## Operative Technique

Routine cleaning and dressing procedures were performed in the standard supine position before surgery. Midsternal line, jugulum, and xiphoid borders were determined with a surgical marker pen. The incision line planned to be 2-3 cm from the lower end of the xiphoid was determined with a surgical marker pen (Picture 1). The skin incision line was planned as 3.5-5.5 cm according to the patient's body weight and anatomical features. The planned skin incision was made. Subcutaneous tissue was dissected. Total or partial sternotomy was performed depending on the surgeon's preference according to the patient's anatomical characteristics. In partial sternotomy, a lower partial sternotomy was performed, starting from the xiphoid and ending at the angle of Louis. The sternal manubrium was left intact. The thymus was not removed. The pericardium was opened, and surgical vision was provided with slings. After heparinization, aortobicaval cannulation was performed.

The superior vena cava cannula and aortic cannula were inserted through the sternotomy. In contrast,

the inferior vena cava cannula was inserted into the mediastinum through the skin incision, where a mediastinal drain was later placed (Picture 2). In secundum ASD cases, the superior vena cava cannula was inserted through the right atrial appendage. In high venosum ASD cases, the superior vena cava cannula was placed selectively. Antegrade, cold, crystalloid, single dose cardioplegia was administered after the X-clamp, and diastolic arrest was achieved. Then, the right atrium was opened, and the ASD was closed with a primer suturing or a patch. After the right atrium was closed, intracardiac air was removed duly. To prevent pericardial effusion in the postoperative period, the right pleura was opened widely, and the tip of the drain placed in the mediastinum was directed to the right pleura. (8). After the bleeding control, the layers were closed with the standard method by the anatomical plan (Picture 3).

## Statistical analysis

Statistical analyzes were performed using SPSS Statistical Software. Descriptive and frequency data were analyzed separately. The distribution of numerical variables was evaluated with the Kolmogorov Smirnov test. Numerical variables were expressed as median-IQR since normal distribution could not be obtained. Values and other results after statistical analysis are presented in the article.

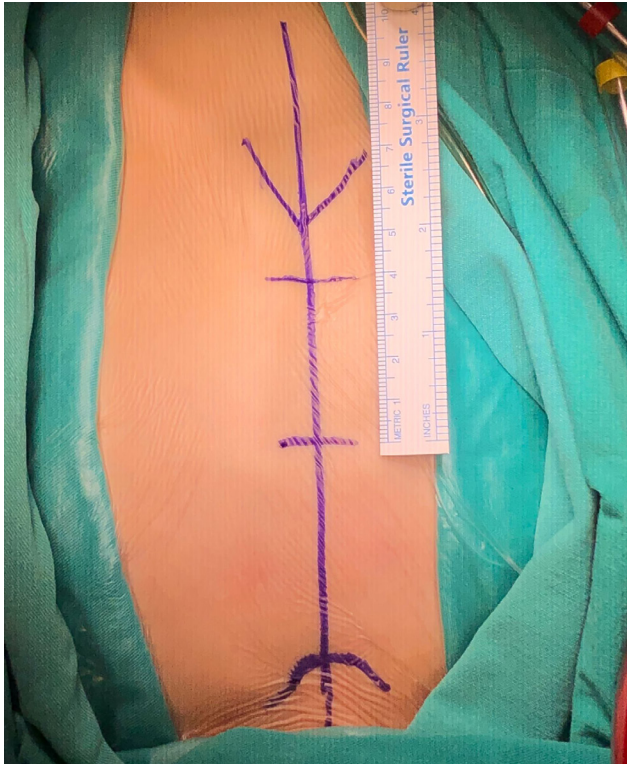
## Results

Thirty-six patients (male:11, female:25) were included in the study. The median age of the patients was 57 months (IQR: 43-83 months), and the median body weight was 16 kg (IQR: 12.7-21.7 kg). Two (5.5%) patients (one patient with Down syndrome and one with DiGeorge syndrome) had chromosomal abnormalities. A secundum ASD was detected in 31 (86%) patients, high venosum ASD in four (11%), and low venosum ASD in one (3%).

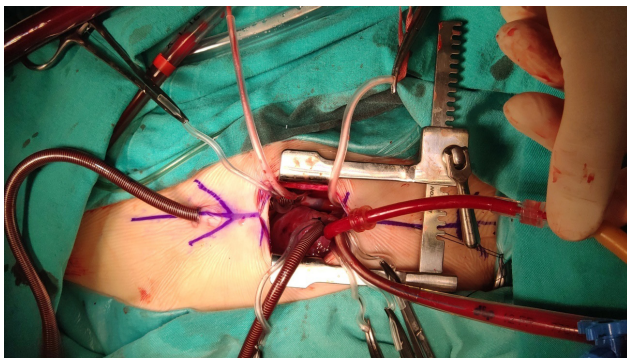
The median skin incision length was 4 cm (IQR: 4-5 cm). Partial sternotomy was performed in 20 patients (56%), and total sternotomy was performed in 16 (44%). The median cardiopulmonary bypass time of the patients was 46.5 minutes (IQR: 36.8-57.2 minutes), and the median X-clamp time was 21.5 minutes (IQR: 15-28.7 minutes). Defects in nine (25%) patients were closed with a patch, and in 27 (75%) patients with primary suturing. Twenty-one (58%) patients were extubated in the operating theater. Fifteen (42%) patients were extubated within the first five hours after surgery in the intensive care unit.

The median drainage in the first 24 hours was 105 ml (IQR: 70-165 ml), and the median duration to remove the chest drainage tube was two days (IQR: 2-2 days). No mortality was observed. Pleural effusion was not observed. No complications were observed. No wound laceration wound infection, hematoma in the subcutaneous tissue, sterile dehiscence or mediastinitis were observed in any of the patients. The median

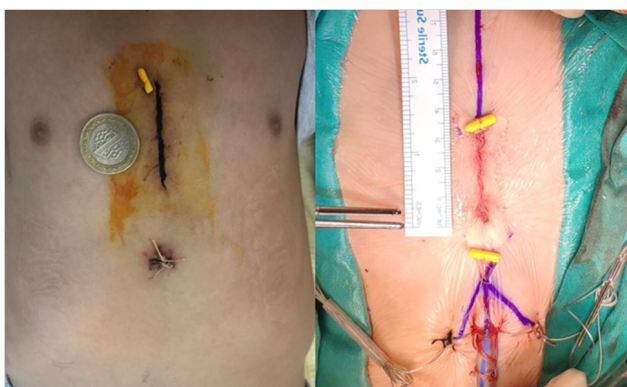
hospital stay was five days (IQR: 4-5 days). The data of the patients are shared in Table 1.



**Figure 1:** Marking the incision line and anatomical landmarks.



**Figure 2:** Placement of inferior vena cava cannula through chest drain incision



**Figure 3:** Postoperative image (photos belong to different patients)

**Table 1:** Preoperative, operative, and postoperative data

Parameters	n=36
Gender (male/female)	11 (31%) / 25 (69%)
Age (months), median, IQR	57 (43 - 83)
Genetic Syndrome	2 (5.5%)
Defect type	
Secundum ASD	31 (86%)
High Venosum ASD	4 (11%)
Low Venosum ASD	1 (3%)
Skin incision length (cm), median, IQR	4 (4 - 5)
Sternotomy type	
Total	16 (44%)
Partial	20 (56%)
CPB time (minute), median, IQR	46.5 (36.8 - 57.2)
X clamp time (minute), median, IQR	21.5 (15 - 28.7)
Defect closure method	
Primary	27 (75%)
Patch	9 (25%)
Extubation time	
Operating theater	21 (58%)
Intensive care unit	15 (42%)
Drainage in the first 24 hours (ml), median, IQR	105 (70 - 165)
Hospital stay (day), median, IQR	5 (4-5)
ASD: atrial septal defect, CPB: cardiopulmonary bypass	

## Discussion

Minimally invasive surgery is preferred due to its advantages, such as less surgical stress on the patient, less inflammation, less pain, and shorter hospital stay, in addition to its cosmetic results (1,9,10). Minimally invasive techniques in congenital heart surgery were initially applied in relatively more uncomplicated anomalies such as ASDs. However, as the experience in this field increased, it became preferred in more complicated surgeries (11-14). However, in minimally invasive methods, good cosmetic results should be aimed without increasing the surgical risk.

In congenital heart surgery, partial sternotomy, transxiphoidal approach, anterolateral/posterolateral right thoracotomy, right axillary approach, and video-assisted thoracoscopic surgery can be described as minimally invasive (15-24).

The advantages of the right axillary approach include sparing chest wall muscles, keeping distance from breast tissue, and providing a direct view of the atrial septum. However, it is necessary to pay attention to the phrenic nerve injury during dissection and opening of the pericardium. In most patients, aortic cannulation can be performed through the existing incision. However, alternative arterial cannulation should be performed in cases where aortic cannulation is not possible from a surgical view (25). However, in patients weighing less than 10-15 kg, femoral artery cannulation is generally considered a relative contraindication

(11,26). No mortality was observed in the series of 123 patients operated on with the right axillary approach by Dave et al. (11). With the same approach, Dave et al. intervened in other cardiac anomalies such as partial abnormal pulmonary venous return anomaly, partial atrioventricular septal defect, and ventricular septal defect in addition to ASD. Their study found temporary left arm paralysis, superior vena cava stenosis, related superior vena cava stenting, bleeding revision, and minor residual defects in the postoperative period. They applied the cardiac fibrillation technique in the ASD closure and stated that they did not detect any neurological complications. In our opinion, it is thought-provoking if a small residual defect remains in an anomaly whose surgery is relatively 'simple,' such as an ASD. Moreover, we consider performing surgery with ventricular fibrillation instead of cardioplegic arrest as a risk that should not be taken. In the series of Dave et al., the minimally invasive approach seems to increase the surgical risk.

The main disadvantage of the anterolateral thoracotomy approach is that it is not possible to determine the borders of the immature breast tissue, so the location and length of the incision cannot be determined clearly. In addition, possible damage to the breast tissue may result in breast asymmetry and loss of sensation in the tissue around the breast in the subsequent process (27,28). We think that such a cosmetic problem, which can be very important, especially in girls, is against the basic principles of minimally invasive surgery.

Although the cosmetic results are excellent in the transxiphoidal approach, it can make the procedures performed in the aorta risky and complicated due to the difficulty of surgical access to the ascending aorta. These include difficulties in cross-clamping, cardioplegia, and deairing (29). In this respect, we think that the transxiphoidal approach also increases the risk of the surgical procedure for the sake of cosmetic results.

Although the video-assisted thoracoscopic method is common in adult patients, it is also applied in the pediatric population. Since femoral cannulation is performed in the thoracoscopic method, its application is difficult in patients with low body weights. In addition to the femoral incision, three ports are required (30,31). For this reason, it seems to be a difficult technique to apply, especially in low body weight patients.

In our clinic, we perform inferior partial sternotomy or total sternotomy with a limited skin incision. With this method, we can reach the anatomical structures in the surgical field in the usual way. Arterial cannula, cardioplegia cannula, and right atrial cannula can be placed using the standard method. To increase the surgical vision, we insert the inferior vena cava cannula into the mediastinum through the incision, where the mediastinal drainage tube will then be placed.

Being able to easily switch to total sternotomy

when necessary, having full command of the entire surgical field, not needing specially produced surgical instruments, and being a relatively 'easy' technique with a fast-learning time, it stands out as an advantageous technique. In his study, Kadner et al. shared the results of patients whose ventricular septal defect was closed with sub-partial sternotomy and stated that sternal stability is better with this method and infection rates are lower than standard methods (32). Although they preferred a 'T' incision to the lower sternum as a surgical technique, they stated sternal stability was better. In our clinic, we prefer an incision that starts from the xiphoid and ends at the angle of Louis, where the corpus is cut vertically, and the manubrium is left intact. We provide surgical vision with a sternum retractor. There was no separation, tear or fracture at the junction of the corpus sterni and manubrium in any of our patients. We consider this as the high bone elasticity in the young age group and the inability to open the sternum retractor due to the tiny skin incision.

Considering that patient safety is more important than cosmetic concerns, we think that the most important advantages of the technique are that it is very easy to extend the incision in a possible problem, it can be done in a short time, and it provides full control of the entire surgical field.

There was no mortality in any of the patients in our study group. No residual defect was detected in any of our patients, albeit minor. Partial sternotomy and total sternotomy decisions have been made and applied beforehand. None of the patients were switched from partial sternotomy to total sternotomy. No patient required skin incision widening. Complications such as infection, dehiscence, or mediastinitis related to wound sites were not observed.

We think that the quality of repair should not be sacrificed for the sake of cosmetic concerns, especially in the surgery of diseases such as ASD and ventricular septal defect, which can be completely repaired after surgery, and the heart defect can be completely corrected, with minimal mortality today. However, since full anatomical control of the mediastinum and cardiac structures cannot be achieved in the other methods mentioned, it may not be sufficient to widen the existing skin incision in case of a possible problem. Therefore, we think that in such cases, it may compromise the quality of the cardiac repair. For this reason, we prefer the limited sternal skin incision, which has the opportunity to switch to the conventional method at any time to keep the repair quality at the highest level in our clinic.

## Conclusion

Minimally invasive surgery is the method that reduces surgical stress, inflammation, postoperative pain, and hospital stay and has good esthetic results. It can be safely applied as long as it does not increase the risk of surgical procedures.

## Limitations

Our study is a retrospective study. Therefore, there is a need for larger series in terms of the number of patients and its application in other cardiac anomalies.

## References

- Konstantinov, I.E. Kotani Y, Buratto E et al.(2022). Minimally invasive approaches to atrial septal defect closure. *JTCVS Techniques* 2022 ;14 :184-90
- Sharma V, DeShazo RA, Skidmore CR, et al. Surgical explantation of atrial septal closure devices for refractory nickel allergy symptoms. *J Thorac Cardiovasc Surg* 2020;160:502-9.
- Naimo PS, Konstantinov IE. Commentary: a nickel for your thoughts: an overlooked allergen in implantable devices? *J Thorac Cardiovasc Surg* 2020;160: 512-4.
- Wertman B, Azarbal B, Riedl M, et al. Adverse events associated with nickel allergy in patients undergoing percutaneous atrial septal defect or patent foramen ovale closure. *J Am Coll Cardiol* 2006;47:1226-7.
- Verma DR, Khan MF, Tandar A, et al. Nickel elution properties of contemporary interatrial shunt closure devices. *J Invasive Cardiol* 2017;27:99-104.
- Boysan E, Cicek OF, et al. Surgical removal of an atrial septal occluder device embolized to the main pulmonary artery. *Tex Heart Inst J*. 2014 Feb;41(1):91-3.
- Schreiber C, Bleiziffer S, Kostolny M, et al. Minimally invasive midaxillary muscle sparing thoracotomy for atrial septal defect closure in prepubescent patients. *Ann Thorac Surg* 2005;80:673-6.
- Özkan M, Beyazpınar D.S, Çelik M. Et al. Pleuropericardial Window Prevents Pericardial Effusion Following Surgical Atrial Septal Defect Closure. *Anatolian Journal of Cardiology/Anadolu Kardiyoloji Dergisi* 2022; 26: 696-701.
- Luo H,Wang J, Qiao C, Zhang X, et al. Evaluation of different minimally invasive techniques in the surgical treatment of atrial septal defect. *J Thorac Cardiovasc Surg* 2014;148:188-93.
- Formigari R, Di Donato RM, Mazzer E, et al. Minimally invasive or interventional repair of atrial septal defects in children: experience in 171 cases and comparison with conventional strategies. *J Am Coll Cardiol* 2001;37:1707-12.
- Dave HH, Comber M, Solinger T. et al Midterm results of right axillary incision for the repair of a wide range of congenital cardiac defects. *Eur J Cardiothorac Surg* 2009;35:864-70.
- Liu Y, Zhang H, Sun H, et al. Repair of cardiac defects through a shorter right lateral thoracotomy in children. *Ann Thorac Surg* 2000;70:738-41.
- Giamberti A, Mazzer E, Di Chiara L, et al. Right submammary minithoractomy for repair of congenital heart defects. *Eur J Cardiothorac Surg* 2000;18:678-82.
- Lee T, Weiss AJ, Williams EE, Kiblawi F, et al. The right axillary incision: a potential new standard of care for selected congenital heart surgery. *Semin Thorac Cardiovasc Surg* 2018;30:310-6.
- Sebastian VA, Guleserian KJ, Leonard SR, et al. Ministernotomy for repair of congenital cardiac disease. *Interact Cardiovasc Thorac Surg* 2009;9: 819-21.
- Bichell DP, Geva T, Bacha EA, et al. Minimal access approach for the repair of atrial septal defect: the initial 135 patients. *Ann Thorac Surg* 2000;70:115-8.
- Black MD, Freedom RM. Minimally invasive repair of atrial septal defects. *Ann Thorac Surg* 1998;65:765-7.
- Yan L, Zhou Z-C, Li H-P, et al. Right vertical infraaxillary mini-incision for repair of simple congenital heart defects: a matchedpair analysis. *Eur J Cardiothorac Surg* 2013;43:136-41.
- Yoshimura N, Yamaguchi M, Oshima Y, et al. Repair of atrial septal defect through a right posterolateral thoracotomy: a cosmetic approach for female patients. *Ann Thorac Surg* 2001;72:2103-5.
- Mishaly D, Ghosh P, Preisman S. Minimally invasive congenital cardiac surgery through right anterior minithoracotomy approach. *Ann Thorac Surg* 2008;85: 831-5.
- Barbero-Marcial M, Tanamati C, Jatene MB, et al. Transxiphoid approach without median sternotomy for the repair of atrial septal defects. *Ann Thorac Surg* 1998;65:771-4.
- Grinda J-M, Folliguet TA, Dervanian P, et al. Right anterolateral thoracotomy for repair of atrial septal defect. *Ann Thorac Surg* 1996;62:175-8.
- Schreiber C, Bleiziffer S, Lange R. Midaxillary lateral thoracotomy for closure of atrial septal defects in pre-pubescent female children: reappraisal of an "old technique." *Cardiol Young* 2003;13:565-7.
- van deWal H. Cardiac surgery by transxiphoid approach without sternotomy. *Eur J Cardiothorac Surg*. 1998;13:551-4.
- Naimo PS, Konstantinov IE. Small incisions for small children: is right lateral thoracotomy a right approach in open heart surgery in infants? *Heart Lung Circ* 2016;25:104-6.
- Vida VL, Tessari C, Putzu A, et al. The peripheral cannulation technique in minimally invasive congenital cardiac surgery. *Int J Artif Organs* 2016;39:300-3.
- Bleiziffer S, Schreiber C, Burgkart R, et al. The influence of right anterolateral thoracotomy in prepubescent female patients on late breast development and on the incidence of scoliosis. *J Thorac Cardiovasc Surg* 2004;127:1474-80.
- Isik O, Ayik MF, Akyuz M, et al. Right anterolateral thoracotomy in the repair of atrial septal defect: effect on breast development: thoracotomy effect on breast. *J Card Surg* 2015;30:714-8.
- Hagl C, Stock U, Haverich A, et al. Evaluation of different minimally invasive techniques in pediatric cardiac surgery. *Chest* 2001;119:622-7.
- Wang F, Li M, Xu X, et al. Totally thoracoscopic surgical closure of atrial septal defect in small children. *Ann Thorac Surg* 2011;92:200-3.
- Yu SQ, Cai ZJ, Cheng YG, et al. Video-assisted thoracoscopic surgery for congenital heart disease. *Asian Cardiovasc Thorac Ann* 2002;10:228-30.
- Kadner, A, Dave, H, Dodge-Khatami A., Bettexet al. Inferior partial sternotomy for surgical closure of isolated ventricular septal defects in children. In *Heart Surg Forum* 2004, January Vol. 7, No. 5, pp. E467-70.