

## Oral Lichen Planus in Childhood with Unique Histological Finding: A Case Report

### Çocukluk Çağında Benzersiz Histolojik Bulgusu Olan Oral Liken Planus: Olgu Sunumu

Ayat GAMAL-ABDELNASER

0000-0003-3564-8539

Department of Oral Medicine and  
Periodontology, Ahran Canadian  
University Faculty of Oral and Dental  
Medicine, Giza, Egypt

#### ABSTRACT

Oral lichen planus is a chronic inflammatory disease that targets adults. Over the years, few reports documented solitary cases of children being affected by oral lichen planus. In this report, a case of an 8-year-old, medically uncompromised boy who complained of a severe burning sensation in the tongue with a history of one year of remission and exacerbation was presented. When examined, the tongue showed a large irregular superficial non-indurated ulcer occupying the whole anterior 2/3 of the tongue sparing the tip and was surrounded by white radiating lines. The ulcerative lesion showed a peculiar butterfly pattern. Histopathological examination of the incisional biopsy showed intraepithelial civatte bodies and dense subepithelial lymphocytic infiltrate arranged in a pseudo-lymphomatous shape. Although the clinical and histological pictures suggest lichen planus, the atypical arrangement of lymphocytes brought up a question mark. This report demonstrates a peculiar clinical picture of a rare disease combined with a unique histopathologic finding.

**Keywords:** Civatte bodies; juvenile oral lichen planus; oral lichenoid lesions; tertiary lymphoid follicle.

#### ÖZ

Oral liken planus yetişkinleri hedef alan kronik inflamatuvar bir hastalıktır. Yıllar boyunca, oral liken planustan etkilenen tekil çocuk vakaları az sayıda raporla belgelenmiştir. Bu raporda, 8 yaşında, medikal açıdan herhangi bir sorunu olmayan, dilde şiddetli yanma şikayeti ile başvuran, bir yıldır remisyon ve alevlenme öyküsü olan bir erkek çocuk olgusunu sunulmuştur. Dil muayenesinde dil ucu hariç anterior 2/3'lük bölümün tamamını kaplayan, etrafı beyaz yayılan çizgilerle çevrili, büyük, düzensiz, yüzeysel, sertleşmemiş ülser saptandı. Ülseratif lezyon tuhaf bir kelebek paterni gösterdi. İnsizyonel biyopsinin histopatolojik incelemesinde intraepitelyal civatte cisimcikleri ve psödo-lenfomatöz bir şekilde düzenlenmiş yoğun subepitelyal lenfositik infiltrat görüldü. Klinik ve histolojik tablo liken planusu düşündürse de, lenfositlerin atipik dizilimi bir soru işareti yaratmıştır. Bu rapor, benzersiz bir histopatolojik bulguya sahip nadir bir hastalığın kendine özgü klinik tablosunu göstermektedir.

**Anahtar kelimeler:** Civatte cisimcikleri; juvenil oral liken planus; oral likenoid lezyonlar; üçüncül lenfoid folikül.

#### Corresponding Author

#### Sorumlu Yazar

Ayat GAMAL-ABDELNASER  
ayat.gamal@dentistry.cu.edu.eg

Received / Geliş Tarihi : 30.09.2022  
Accepted / Kabul Tarihi : 23.01.2023  
Available Online /  
Çevrimiçi Yayın Tarihi : 23.02.2023

#### INTRODUCTION

Lichen planus (LP) is a chronic inflammatory disease that affects the skin, nails, and mucous membranes. Oral lichen planus (OLP) generally affects patients of middle age or older (1). However, it has rarely been detected in pediatric patients (1-9).

Like adult OLP, OLP in childhood (OLPc) is diagnosed clinically and histopathologically -but in individuals <20 years old-; after excluding oral lichenoid reaction through evidence negating mucosal contact with dental restorative materials or exposure to medications that are known to induce oral lichenoid reactions (10).

Although OLP is relatively rare in childhood, it often presents in asymptomatic forms. This suggests that cases of OLPC are commonly unnoticed and thus, pass undiagnosed; and if symptomatic, it is suggested to be misdiagnosed (11). Consequently, OLPC is believed to have a higher prevalence but is under-reported for the aforementioned causes. Such few reports hinder drawing sound conclusions about OLPC regarding its demographic preference of age, sex, race, predisposing factors, clinical picture, treatment, and prognosis (12). In this report, a case of a child affected by OLP with a characteristic clinical picture and a unique histopathological presentation was presented.

### CASE REPORT

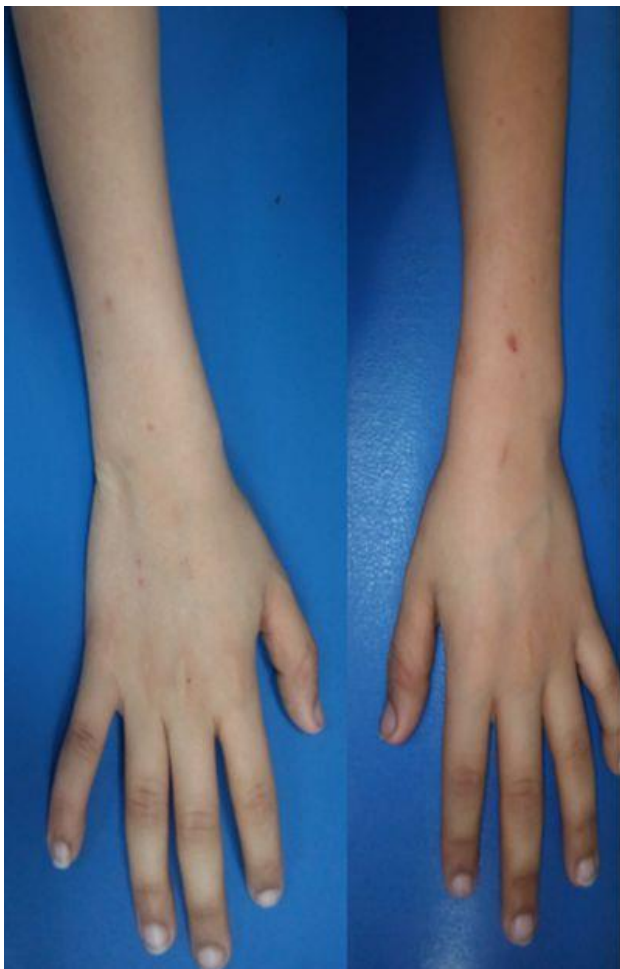An 8-year-old Caucasian boy presented with a severe burning sensation in the tongue that progressed gradually through the past year, with a course of remission and exacerbation. The pain was precipitated by eating salty and spicy food but nothing relieved it. Other than the oral complaint, the child had no significant medical, family, or dental history. However, he adopted poor nutritional habits of depending on candies and chips only.

Extraoral clinical examination revealed multiple small round pigmentations on the forearms marking for healed lesions that the patient reported were itchy (Figure 1). Intraorally, a large butterfly-shaped superficial non-indurated

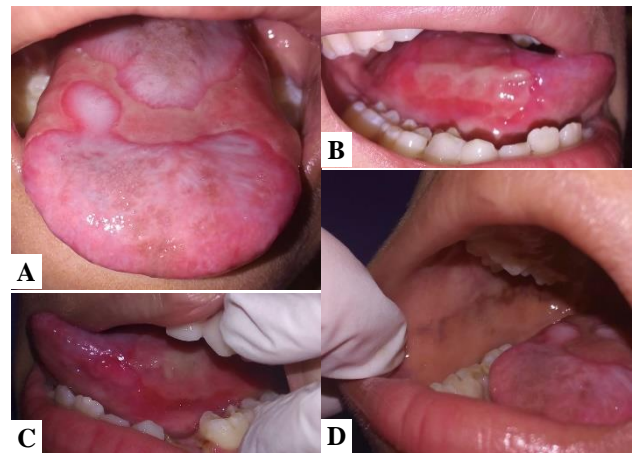
ulcer was detected, occupying the whole anterior 2/3 of the tongue sparing the tip, and extending to the lateral borders of the tongue bilaterally. The ulcer was covered by a pseudomembrane and surrounded by a depapillated tongue that appeared as an erythematous atrophic area covered by white radiating lines. Besides, the buccal mucosa showed linear melanotic pigmentation bilaterally along the occlusal plan (Figure 2).

The differential diagnosis list included oral lichenoid reaction to preservatives in candies, OLP, and systemic lupus erythematosus. Therefore, further investigations were performed; showing mild normocytic normochromic anemia and a normal level of C-reactive protein (CRP). On the other hand, histopathological examination of the incisional biopsy taken from the tongue dorsum revealed severe atrophy of the epithelium, intraepithelial civatte bodies, subepithelial clefting, and very dense subepithelial lymphocytic infiltrate with pseudo-lymphomatous arrangements giving the shape of a lymphoid germinal center (Figure 3).

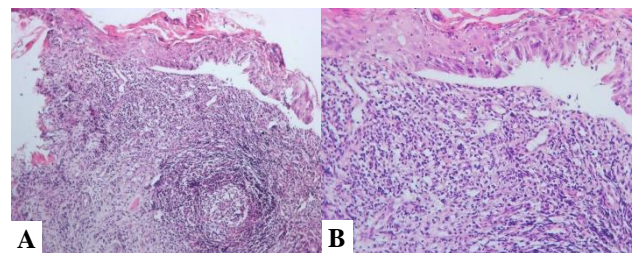
The clinical and histopathologic pictures were more consistent with OLPC. The parents and patient were instructed that they should start a healthier diet and also refrain from consuming candies. Besides, a topical antifungal (Miconazole 20 mg/g) was prescribed for one week to clear away candidal superimposition. Afterward, topical steroids (Triamcinolone acetonide 0.1%) were



**Figure 1.** Discolored skin lesions on the forearms



**Figure 2.** The clinical picture of the lesions appearing on the A) dorsal surface of the tongue, B) right lateral border of the tongue, C) left lateral border of the tongue, and D) buccal mucosa



**Figure 3.** Histopathological picture of the specimen in magnification of A) x100 showing the tertiary lymphoid follicle, and B) x200 showing the intraepithelial changes

prescribed to be used 4 times daily, after meals and at bedtime; just in the same regimen as the topical antifungal. Unfortunately, the parent and the patient did not comply with the diet instructions. However, after one month of applying topical steroids, the pain was relieved. Consequently, the father did not show up at follow-up appointments as long as his son was not complaining. He only then came seeking treatment through the subsequent periods of exacerbation. This pattern extended for 7 months, where the father only showed at the peaks of the exacerbation (at 1, 3, and 7 months); while refraining from following up during the healing or remission periods. Afterward, the patient was lost to follow-up.

## DISCUSSION

The occurrence of OLP in children is rare; where the total prevalence of OLP ranges between 0.1 and 1.2%; yet the prevalence of OLPC counts only as 0.03% (1). This case report presented an 8-year-old child with a peculiar ulcerative form of OLPC that -histopathologically- shows a lymphoid follicle-like structure.

The complaint of the presented patient started at 7 years of age; which falls within the target age range of OLPC between 6 and 17 years (1).

Just like OLP, the exact etiology of OLPC is unknown; but other autoimmune diseases and positive family history are frequently associated with the incidence of OLPC (3). However, in the presented case, there was no history of OLP in any of the family members, nor was there a history of autoimmune diseases or allergy to any type of drug or food.

Clinically, most commonly (70.5%) the juvenile OLP manifests as reticular lesions and least commonly (5.8%) in the ulcerative form (1). Moreover, skin lesions are reported in only 12.6% of cases of OLPC (1). In the presented case, extraoral lesions were detected on the flexor surfaces of the arms; besides the ulcerative form of the intraoral lesion. Such a picture highlights the uncommon presentation of the herein-reported case.

Intraorally, a typical clinical picture of the presented case (extensive butterfly-shaped ulcer affecting the tongue dorsum and its lateral borders sparing the tip) has been previously reported only twice (1,13). The two affected children were females, 3 and 9 years old. The 3-year-old child had no significant medical history nor had she any extraoral manifestations (13). Similarly, the 9-year-old child had no extraoral symptoms. However, she had a history of autoimmune polyendocrinopathy candidosis ectodermal dystrophy (APECED) (1). In the presented case in this report, other than having extraoral lesions, the boy did not have any symptoms of endocrinal abnormalities or ectodermal dystrophy.

Another similar ulcerative lesion was also reported but affecting only the mid-dorsum of the tongue of an otherwise healthy 12-year-old boy; with no other intra- or extraoral manifestations (14).

Therefore, differential diagnosis of the case included OLPC, oral lichenoid lesion (OLL), and lupus erythematosus. Normal levels of CRP, together with the absence of other symptoms, excluded lupus erythematosus from the list.

Despite the clinical differences between childhood and adult forms of OLP, they both have the same histopathologic picture. They are seen as basal cell degeneration and band-like sub-epithelial lymphocytic infiltration (6,15). In the presented case, an extra finding was added to the list; namely the presence of a lymphoid-follicle-like structure.

Such benign lymphoid hyperplasia forming extranodal lymphoid lesions in a site that normally lacks secondary lymphoid tissues is referred to as pseudolymphomas. If detected, it is considered a "tertiary" lymphoid follicle. These follicles represent an aggregation of lymphocytes and dendritic cells where B-cells undergo maturation and immunoglobulin isotype switching (16).

In case of OLLs, T-lymphocyte aggregates may organize forming an extrafollicular T-cell zone where B-cells become activated, together with antigen-specific T-cells. This finding draws attention to the presence of the antigen in close proximity as it is frequently reported by oral lichenoid contact lesions related to amalgam restorations (16).

Leaving OLPC and OLL in the differential diagnosis list, candies and their preservatives were suspected to have a role in the disease. This suspicion was corroborated by a previous report which stated that allergy to flouring agents and preservatives may induce lichenoid reaction (17). In the presented case, the presence of skin lesions together with the widespread oral lesions on the tongue and buccal mucosae were not pointing to support the diagnosis of lichenoid reaction.

Therefore, the case was diagnosed as OLPC, and treatment was planned using topical steroids. Like adult OLP, symptomatic OLPC is primarily treated by topical corticosteroids. Other topical treatments have provided successful results as well including topical tacrolimus, tretinoin, and cyclosporin. However, the safety of the long-term use of these topical medications was not evaluated in pediatrics. On the other hand, systemic steroids are not favorably used due to their significant effect on the growth and metabolism of children (1,15).

Using topical steroids, luckily, OLPC was reported to resolve completely after the treatment in 38.2% of the cases (1). However, this conclusion is believed to be reached based on reports that lack long-term follow-up. In the presented case, OLPC followed a chronic clinical course similar to OLP with periods of remission and exacerbation.

The good news about OLPC is the absence of reports -to date- indicating malignant transformation (1). Nevertheless, in the presented case, the parents were instructed to perform regular follow-ups as long as the lesion persists. This was planned in accordance with recommendations suggesting one or two visits per year for persistent lesions and even more frequent visits for symptomatic OLPC (1,12,14).

## CONCLUSION

Although information lacks about its real prevalence, sporadic reports are accumulating to document OLPC cases. The diagnosis of OLPC should not be overlooked in suspicious lesions under the preconception of being a rare disease in childhood.

**Informed Consent:** All the management steps, together with the publication of this data and images, were performed after obtaining a written signed informed consent from the patient's father (guardian). The case was managed in accordance with the ethical standards of the ethics committee of the Faculty of Dentistry, Cairo University; and with the Declaration of Helsinki and its revision.

**Conflict of Interest:** None declared by the authors.

**Financial Disclosure:** None declared by the authors.

**Acknowledgments:** Special thanks to the staff of the Dermatopathology Lab, Dermatology Department, Faculty of Medicine, Cairo University for their histopathological assessment of the case.

**Author Contributions:** Idea/Concept: AG; Design: AG; Data Collection/Processing: AG; Analysis/Interpretation: AG; Literature Review: AG; Drafting/Writing: AG; Critical Review: AG.

## REFERENCES

- Cascone M, Celentano A, Adamo D, Leuci S, Ruoppo E, Mignogna MD. Oral lichen planus in childhood: a case series. *Int J Dermatol.* 2017;56(6):641-52.
- George S, John SA, Anandaraj S, Issac JS, Harris A, Reshmi J. Childhood oral lichen planus: report of two cases. *J Dent (Tehran).* 2015;12(5):374-8.
- Jahan AJ, Vandana S, Rangdhol V, Palla S. Juvenile oral erosive lichen planus - A rare case report. *Int J Med Dent Case Reports.* 2017;4(1):1-3.
- Chatterjee K, Bhattacharya S, Mukherjee CG, Mazumdar A. A retrospective study of oral lichen planus in paediatric population. *J Oral Maxillofac Pathol.* 2012;16(3):363-7.
- Chaitra TR, Telgi RL, Kishor A, Kulkarni AU. Juvenile oral lichen planus: a clinical rarity. *BMJ Case Rep.* 2012;2012: bcr2012006192.
- Hugar SM, Reddy R, Gokhale N, Hugar SS. Oral lichen planus in childhood: A rare case report. *J Adv Clin Res Insights.* 2015;2(5):226-8.
- Wang F, Tan YQ, Zhang J, Zhou G. Familial oral lichen planus in a 3-year-old boy: a case report with eight years of follow-up. *BMC Oral Health.* 2020;20(1):341.
- Sharma G, Sardana D, Vohra P, Rehani S, Nagpal A. Oral lichen planus in a pediatric patient: a novel therapeutic approach. *J Dent (Tehran).* 2017;14(2):109-14.
- Chinnasamy NK, Venugopal DC, Sankarapandian S, Narasimhan M. Oral lichen planus in a 7-year-old child: A rare case report. *Int J Clin Pediatr Dent.* 2020;13(1):91-3.
- Woo VL, Manchanda-Gera A, Park DS, Yoon AJ, Zegarelli DJ. Juvenile oral lichen planus: A report of 2 cases. *Pediatr Dent.* 2007;29(6):525-30.
- Alam F, Hamburger J. Oral mucosal lichen planus in children. *Int J Paediatr Dent.* 2001;11(3):209-14.
- Laeyendecker R, Van Joost T, Tank B, Oranje AP, Neumann HAM. Oral lichen planus in childhood. *Pediatr Dermatol.* 2005;22(4):299-304.
- Georgaki M, Andreou A, Tziveleka S, Nikitakis NG. Oral erosive/ulcerative lichen planus in a 3 years old child: a case report. *Int J Res Reports Dent.* 2022;5(2):1-6.
- Padmini C, Bai KY, Chaitanya V, Reddy MS. Ulcerative lichen planus in childhood. *Case Rep Dent.* 2013;2013:874895.
- Shikha, Gupta S, Mahajan A, Ambika, Garg R, Ghosh S. Childhood oral lichen planus: a case series with review of literature. *Eur Arch Paediatr Dent.* 2022;23(2):341-53.
- Larsson A, Warfvinge G. Immunohistochemistry of 'tertiary lymphoid follicles' in oral amalgam-associated lichenoid lesions. *Oral Dis.* 1998;4(3):187-93.
- Yiannias JA, el-Azhary RA, Hand JH, Pakzad SY, Rogers RS 3rd. Relevant contact sensitivities in patients with the diagnosis of oral lichen planus. *J Am Acad Dermatol.* 2000;42(2 Pt 1):177-82.