

Unilateral Uterine Torsion in a Shorthair Scottish Queen

Ali RIŞVANLI^{1a*}, Abuzer TAŞ^{1b}, Aiperi AİTMYRZA KYZY^{1c}, Nur ABDYMANAP UULU^{1d}
Sezim BELEK KYZY^{1e}, Aiturgan DUYSHOBAYEVA^{1f}

¹Kyrgyz-Turkish Manas University, Faculty of Veterinary Medicine, Bishkek, KYRGYZSTAN

^a<https://orcid.org/0000-0001-5653-0025>, ^b<https://orcid.org/0000-0002-7326-1768>,

^c<https://orcid.org/0000-0003-3363-0941>; ^d<https://orcid.org/0000-0001-6814-4842>,

^e<https://orcid.org/0000-0002-5866-2045>, ^f<https://orcid.org/0000-0002-0564-4628>;

*Corresponding author: arisvanli@firat.edu.tr

ABSTRACT

In this case report, it is aimed to present unilateral uterine torsion in a 7-year-old Shorthair Scottish queen. The queen, which had full-term pregnancy, was brought to the Kyrgyz-Turkish Manas University Veterinary Faculty Teaching hospital with complaints of stagnation, vomiting and hypothermia. In the ultrasonography examination, 3 kittens without a heartbeat were detected. After the abdominal incision made in the queen for whom emergency cesarean section was decided, a 1080° counterclockwise torsion was noticed on the caudal side of the cervix uterine in the left uterine horn of the queen. It was observed that the left uterine horn was cyanotic due to torsion-related ischemia. For this reason, it was decided to perform N-block ovariohysterectomy instead of cesarean section. As a result, it was concluded that the presented case report of unilateral uterine torsion, which is rare in cats, will make useful contributions to veterinarians and students in the field.

ARTICLE INFO

Case report

Received: 10.10.2022

Accepted: 05.11.2022

Keywords:

Uterine torsion, queen,
N-block
ovariohysterectomy

INTRODUCTION

Although uterine torsion in queens has been reported in many studies, there is not enough information about parameters such as incidence rates, age, breed, number of lactations and severity of torsion (Johnston et al. 2001). In most of the cases presented, the diagnosis of uterine torsion is in a wide range from the fourth week of pregnancy to the period when symptoms of difficult labor appear two weeks after the expected delivery date. The clinical course of symptoms is presented in an interval of 2 hours to 3 days, and clinical symptoms include depression, anorexia, collapse, abdominal pain, pale mucous membranes, hypothermia, bloody vaginal discharge, shallow breathing, tachycardia, and convulsions in advanced pregnant animals. Diagnosis is usually made during experimental surgery or necropsy following death or euthanasia. The prognosis varies according to the severity of the symptoms, the duration of the torsion and the operation performed. In most of the cases, the death of the kittens and the life of the mother continue (Johnston et al. 2001; Kuroda et al. 2017; Noakes 2019; Ali et al. 2021; Köker and Ergün, 2022)

In this case report, it is aimed to present unilateral uterine torsion in a Shorthair Scottish queen.

CASE DEFINITION

In September 2022, a 7-year-old Shorthair Scottish queen, who full term pregnancy, was brought to the the Kyrgyz-Turkish Manas University Veterinary Faculty Teaching hospital with complaints of stagnation, vomiting and hypothermia. The queen also had symptoms of dyspnea and depression. Body temperature was below 32 °C. The owner stated that the queen jumped from a height 24 hours ago, but the symptoms started 12 hours ago. There was no vaginal discharge and no signs of abdominal pain. The results of the laboratory blood tests were WBC 4.7x10⁹/L, Lymph 1.3x10⁹/L, Mid 0.9x10⁹/L, Gran 2.5x10⁹/L, RBC 11x10¹²/L, PLT 370x10⁹/L, Lymph% 28.2%, Mid% 19.8%, Gran% 52%, HCT 48.6%, HGB 185 g/L, MCV 44.2 fL, MCH 16.8 pg, MCHC380 g/L, RDW-CV 16.7%, RDV-SD 23.3 fL, MPV 16.1 fL, PDW 14.5 and PCT 0.595%.

To Cite: Rişvanlı A, Taş A, Aitmyrza Kzyz A, Abdymanap Uulu N, Belek Kzyz S, Duyshobayeva A. 2022. Unilateral Uterine Torsion in a Shorthair Scottish Queen, MJAVL Sciences. 12 (2) 166-168

In the ultrasonography examination, 3 kittens without a heartbeat were detected (fetal fluids were decreased and placentation was intact) and an emergency cesarean section operation was decided.

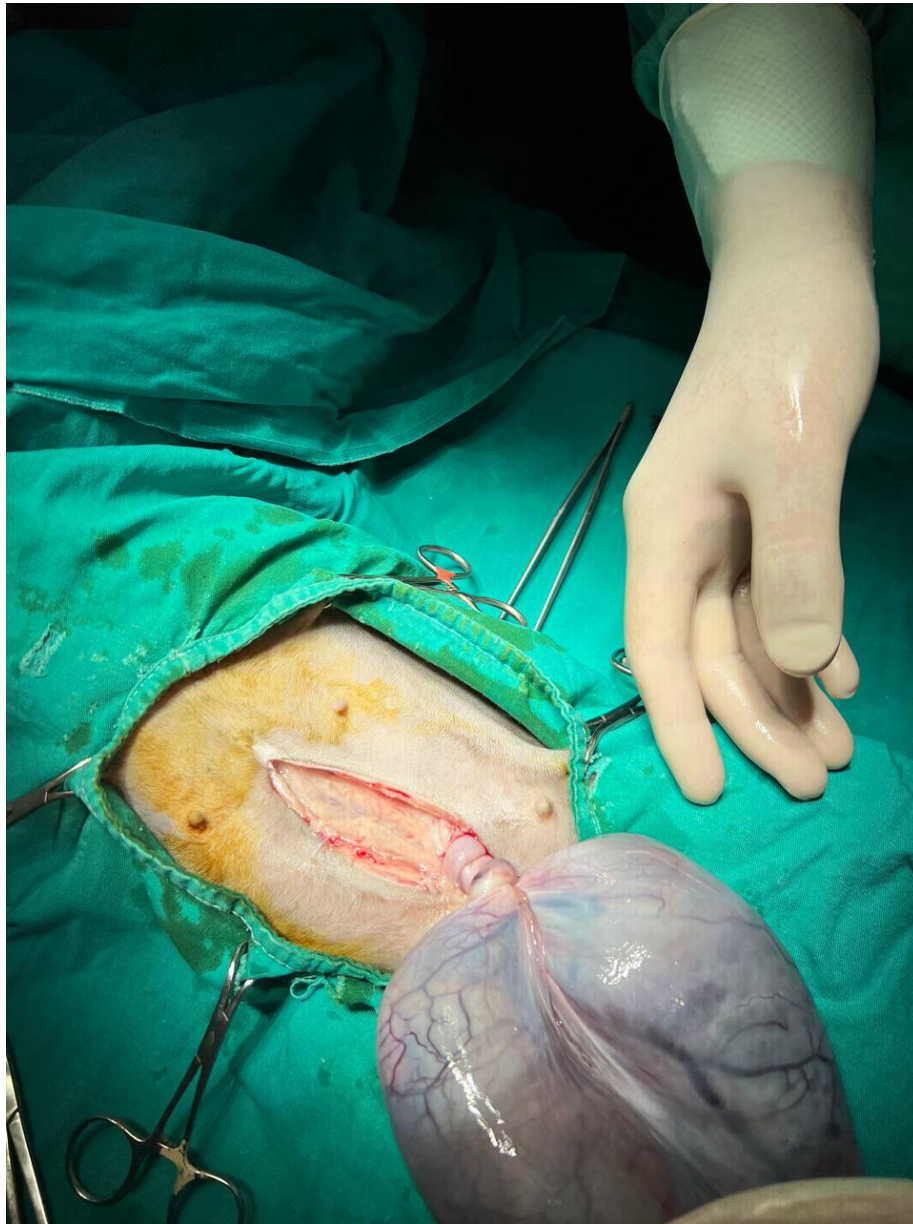


Figure 1. 1080° counterclockwise torsion of the left uterine horn

DISCUSSION

Before the operation, intravenous saline, 5% dextrose and lactate Ringer's solution was started to be administered to the queen, and atropine sulfate (Atropin Vetař, Istanbul, Turkey) (0.045 mg/kg) was administered subcutaneously. Intramuscular xylazine hydrochloride (Vetaxyl Vetař, Istanbul, Turkey) (1 mg/kg) and ketamine (Ketamidor Vetař, Istanbul, Turkey) (15 mg/kg) were administered as anesthesia. After the abdominal incision, a 1080° counterclockwise torsion was noticed on the caudal side of the uterine cervix in the left uterine horn of the queen (Figure 1). It was observed that the left uterine horn was cyanotic due to torsion-related ischemia. For this reason, N-block ovariohysterectomy was performed instead of cesarean section. After N-block ovariohysterectomy, 3 dead kittens were removed, two in the left uterine horn and one in the right uterine horn. The surgical wound was closed as per standard procedure and the patient was treated with ceftriaxone sodium (Novosef 1 g Sanofi Istanbul, Turkey) at 20 mg/kg and meloxicam (Meloksikam Bavet Istanbul, Turkey) 0.1 mg/kg postoperatively. The animal was then taken to the intensive care unit and intravenous fluid administration was continued at 37 °C. 3 hours after the operation, his body temperature above 35 °C. Five hours after the operation, the queen's heart rate increased to over 130 beats per minute and she died.

The diagnosis of possible uterine torsion in pregnant female queens can be based on the presence of acute abdominal symptoms such as abdominal pain, shock or collapse. In suspected queens, abdominal ultrasonography is recommended to determine the viability of the fetus(s). OHE operation to be performed following experimental celiotomy to confirm the diagnosis is a suitable option for treatment. The option of correcting the torsion with or without cesarean section is often not recommended. Because, due to torsion, it is often not possible for the tissues to recover themselves. Supportive treatment (such as liquid supplementation, corticosteroid, antibacterial) determines the condition of the female queen affected by torsion at the time of diagnosis (Roberts 1986; Johnston et al. 2001; Long, 2009). In the presented case report, after celiotomy in an advanced pregnant queen, 1080° counterclockwise torsion was detected in the left uterine horn and the animal died 5 hours after the N-block ovariohysterectomy.

As a conclusion; in rare cases of uterine torsion in queens, N-block ovariohysterectomy operation can be performed due to tissue damage in the uterus after ischemia, but it has been observed that the general condition of the animal plays an important role in determining the prognosis in such operations.

ETHICAL STATEMENT

During the writing process of the study titled "Unilateral Uterine Torsion in a Shorthair Scottish Queen", scientific rules, ethical and citation rules were followed; No falsification has been made on the collected data and this study has not been sent to any other academic media for evaluation. Ethics committee approval is not required as the presented article is a case report. However, approval was obtained from the animal owner.

CONFLICT OF INTEREST

The authors declare no conflicts of interest related to this report.

AUTHORS CONTRIBUTION

Authors have equal right to contribute to the manuscript.

REFERENCES

- Ali M, Suresh A, Sarath T, Arunmozhi N, Sureshkumar R, Joseph C 2021. Surgical management of dystocia due to unilateral uterine torsion in a domestic shorthair queen. *Top. Companion. Anim. Med.*, 45: 100577.
- Johnston SD, Root Kustritz MV, Olson PNS 2001. *Canine and Feline Theriogenology*, 1st ed. Saunders, Philadelphia.
- Köker A, Ergün Y 2022. Pregnancy pathology, pp. 273-290, In: *Obstetrics and Gynecology in Dogs and Queens* 3rd ed. Kaymaz M, Fındık M, Riřvanlı A, Köker A (eds), Medipres Publishing, Malatya.
- Kuroda K, Osaki T, Harada K, Yamashita M, Murahata Y, Azuma K, TsukaT, Ito N, Imagawa T, Okamoto Y 2017. Uterine torsion in a full-term pregnant queen. *J. Feline Med. Surg. Open Rep.*, 3 (1):1-4.
- Long S 2009. Abnormal development of the conceptus and its consequences. In: *Veterinary Reproduction and Obstetrics*. 9th ed. Noakes DE, Parkinson TJ, England GCW (eds). Saunders Elsevier, USA.
- Noakes DE 2019. Maternal dystocia: causes and treatment, pp. 232-246, In: *Veterinary Reproduction and Obstetrics*, 8th ed. Noakes DE, Parkinson TJ, England GCW (eds), WB Saunders Ltd, London.
- Roberts SJ 1986. *Veterinary Obstetrics and Genital Diseases (Theriogenology)*, 3rd ed. Edwards Brothers Inc, Michigan