



Case Report

J Exp Clin Med
2023; 40(1): 183-185
doi: 10.52142/omujecm.40.1.34

A rare case: Coexistence of noncompaction cardiomyopathy and Ebstein anomaly

Ahmet CINAR*^{ORCID}, Ömer GEDİKLİ^{ORCID}

Department of Cardiology, Faculty of Medicine, Ondokuz Mayıs University, Samsun, Türkiye

Received: 07.10.2022

Accepted/Published Online: 02.01.2023

Final Version: 18.03.2023

Abstract

Noncompaction cardiomyopathy is a rare type of cardiomyopathy that can result in left ventricular failure, thromboembolic events, tachyarrhythmias, and sudden cardiac death. It is a congenital cardiomyopathy in which deep trabeculations and cavities in the left ventricle are formed due to the cessation of the development of myocardial tissue in the intrauterine period. Ebstein's anomaly is a congenital anomaly characterized by apical displacement of the tricuspid valve septal leaflet. Although the association of non-compaction cardiomyopathy and Ebstein is a rare disease, there are cases described in the literature. A 23-year-old male patient presented with palpitations and fatigue and was diagnosed with non-compaction cardiomyopathy and Ebstein anomaly. After the diagnosis, the patient is followed closely without complications with appropriate medical follow-up. Congenital heart diseases can be seen alone or in association with other cardiac malformations. When there are suspicious findings in a patient with Ebstein's anomaly, it may be associated with non-compaction cardiomyopathy, and screening with echocardiographic and cardiac MRI should be considered.

Keywords: noncompaction cardiomyopathy, Ebstein anomaly, congenital heart diseases

1. Introduction

Noncompaction cardiomyopathy is a rare type of cardiomyopathy that can result in left ventricular failure, thromboembolic events, tachyarrhythmias, and sudden cardiac death. It is a congenital cardiomyopathy in which deep trabeculations are formed, and cavities in the left ventricle are formed due to the cessation of the development of myocardial tissue in the intrauterine period. (1) Since normal compaction develops at the apex of the last ventricle, the apex is involved in the vast majority of cases. (2) End-systolic non-compact/compact myocardium ratio >2 in echocardiography is important in the diagnosis. (3) On the other hand, in cardiac MRI, according to Peterson's criteria, end-diastolic non-compact myocardium/compact myocardium rate ≥ 2.3 also makes the diagnosis. (4) Again, with cardiac MRI, Jacquier et al., in their study in which they measured trabecular and global left ventricular mass, showed that a trabecular myocardial mass greater than 20% of the global myocardial mass is important in diagnosis. (5)

Ebstein's anomaly is a congenital anomaly characterized by apical displacement of the tricuspid valve septal leaflet and may be associated with other congenital cardiac malformations. (6)

Although the association of non-compaction cardiomyopathy and Ebstein is a rare disease, there are cases described in the literature. We also planned to present this rare association in order to contribute to the literature.

2. Case Report

Our patient is a 23-year-old male patient with no known disease. He applied with the complaints of palpitation and fatigue, which lasted for 5-10 minutes and about 2-3 years, especially after exertion. In the cardiac examination of the patient, blood pressure was 120/70, and heart rate was 80 beats/min. A 2-3/6 systolic murmur was heard in the tricuspid valve focus. No significant additional pathology was detected in the physical examination. In the ECG of the patient, the rhythm was sinus, and QRS fragmentation was observed in lead D3. The ejection fraction was 55%, and mild global hypokinesia was observed in echocardiography. Increased trabecular structure in the LV and flow between these trabeculae with color Doppler were observed. In addition, it was noticed that the septal leaflet of the tricuspid valve was displaced apically, and the distance between the mitral and tricuspid annulus was measured as 18 mm. (Fig. 1). Cardiac MRI was requested from the patient with the preliminary diagnosis of non-compaction cardiomyopathy and Ebstein anomaly. Cardiac MRI showed a distinct trabecular appearance at the level of the apical and lateral walls of the left ventricle. The non-compact/compact ratio is approximately 2.3. The appearance was reported as compatible with light non-compaction. (Fig. 2) 100 mg of acetylsalicylic acid, 50 mg of metoprolol, and 1 mg of cilazapril were added to the patient's treatment. Our patient has been asymptomatic for about six months and can climb 3-4 flights of stairs. The patient is followed closely for possible complications.

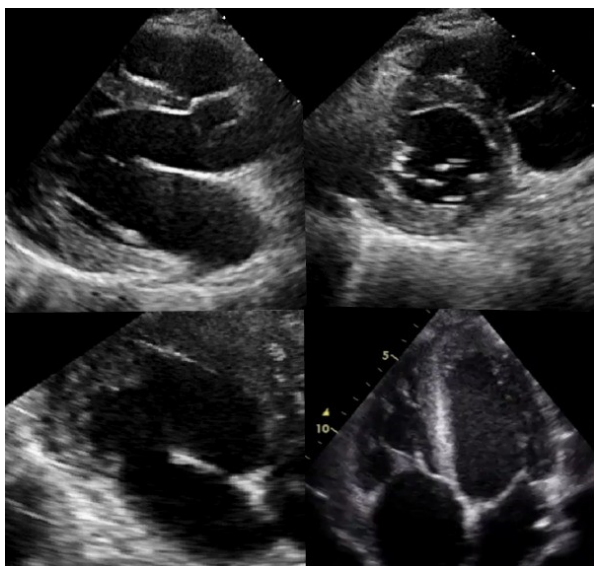


Fig. 1. Echocardiography images of the patient

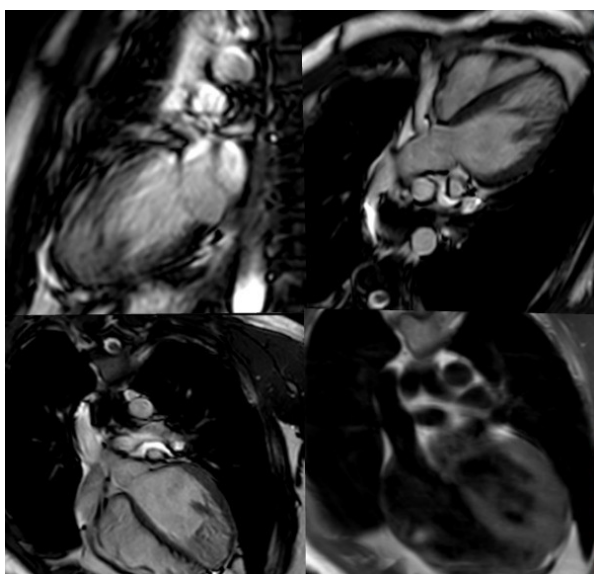


Fig. 2. Cardiac MR images of the patient, increased trabeculation structure in the LV apical

3. Discussion

This case is important because there are cases reported in the literature, even though there is a rare association with congenital heart disease. Both echocardiography and cardiac MRI are important in the association of Ebstein anomaly and left ventricular non-compaction cardiomyopathy. Cardiac MR imaging provides superior myocardial characterization and endocardial identification compared to echocardiography and is a more sensitive imaging modality in detecting left ventricular non-compaction. (7) Although current guidelines do not recommend routine cardiac MRI in cases where there is increased trabecular structure in the left ventricle, cardiac MRI scanning can be considered in this sense to exclude left ventricular non-compaction. MRI scanning may be considered in this context to rule out left ventricular non-compaction. In addition, this association is a condition that requires genetic screening. Both diseases may be alone or associated with other congenital heart diseases. Cases in which a mutation in the

sarcomere gene MYH7 was associated with the coexistence of non-compaction cardiomyopathy and Ebstein anomaly have been reported. (8-9-10) In another literature study, this association was also shown in the sarcomere gene TPM1 genetic mutation. (11) In this study, it is recommended to perform both MYH7 and TPM1 gene analysis. In the same study, family screening was also recommended, and these gene mutations were detected and diagnosed in other family members. This shows us that genetic transmission may occur when the diagnosis is made, and it is important to detect other family members for early diagnosis. However, genetic screening was not performed in our case.

Congenital heart diseases can be seen alone or together with other cardiac malformations, as seen in our case. Noncompaction cardiomyopathy is a vital disease ranging from severe left ventricular dysfunction and malignant arrhythmias to life-threatening thromboembolic events and even sudden death. When there are suspicious findings in a patient with Ebstein's anomaly, it may be associated with non-compaction cardiomyopathy, and scanning with echocardiographic and cardiac MRI should be considered. It should also be kept in mind that it is hereditary and screening of other family members.

Conflict of interest

The authors declared no conflict of interest.

Funding

No funding was used for the study.

Acknowledgments

None to declare.

Authors' contributions

Concept: A.C., O.G., Design: A.C., O.G., Data Collection or Processing: A.C., O.G., Analysis or Interpretation: A.C., O.G., Literature Search: A.C., O.G., Writing: A.C., O.G.

References

1. Murphy RT, Thaman R, Blanes JG et al. Natural history and familial characteristics of isolated left ventricular non-compaction. *Eur Heart J* 2005; 26:187-92.
2. Zuccarino F, Vollmer I, Sanchez G, Navallas M, Pugliese F, Gayete A. Left ventricular non-compaction: imaging findings and diagnostic criteria. *AJR Am J Roentgenol* 2015; 204: 519-30.
3. Gebhard C, Stähli BE, Greutmann M, Biaggi P, Jenni R, Tanner FC. Reduced left ventricular compacta thickness: a novel echocardiographic criterion for non-compaction cardiomyopathy. *J Am Soc Echocardiogr* 2012; 25:1050-7.
4. Petersen SE, Selvanayagam JB, Wiesmann F et al. Left ventricular non-compaction: Insights from cardiovascular magnetic resonance imaging. *J Am Coll Cardiol* 2005; 46: 101-5.
5. Jacquier A, Thuny F, Jop B et al. Measurement of trabeculated left ventricular mass using cardiac magnetic resonance imaging in the diagnosis of left ventricular non-compaction. *Eur Heart J* 2010; 31: 1098-104.
6. Scardi S, D'Agata B, Giansante C. Pratica clinica: l'anomalia di Ebstein. *G Ital Cardiol*. 2009. 10:509-15

7. Almeida AG, Fausto J Pinto, Heart 2013; 99:1535–1542. doi:10.1136/heartjnl-2012-302048
8. Van Engelen K, Postma AV, van de Meerakker JB et al. Ebstein's anomaly may be caused by mutation in the sarcomere protein gene MYH7. Neth Heart J. 2013 Mar;21(3):113-7. doi: 10.1007/s12471-011-0141-1.
9. A. V. Postma, K. van Engelen, J. van de Meerakker et al., "Mutations in the sarcomere gene MYH7 in Ebstein anomaly," *Circulation: Cardiovascular Genetics*, vol. 4, no. 1, pp. 43–50, 2011.
10. A. L. Bettinelli, T. J. Mulder, B. H. Funke, K. A. Lafferty, S. A. Longo, and D. M. Niyazov, "Familial ebstein anomaly, left ventricular hypertrabeculation, and ventricular septal defect associated with a MYH7 mutation," *American Journal of Medical Genetics A*, vol. 161, no. 12, pp. 3187–3190, 2013.
11. A. Nijak, M Alaerts, C. Kuiperi, et al. European Journal of Medical Genetics 61 (2018) 8–10