

### Kounis Syndrome or Adrenalin Side-Effect?

Oya Güven<sup>1</sup>, Meziyet Camuz<sup>2</sup>, Didar Elif Akgün<sup>3</sup>, Mert Avsever<sup>4</sup>

<sup>1</sup>Kırklareli University Medicine School, Emergency Department, Assistant Professor

<sup>2</sup>Kırklareli Training and Research Hospital, Emergency Department, General Practitioner

<sup>3</sup>Kırklareli Training and Research Hospital, Cardiology Department, Cardiologist

<sup>4</sup>Medifema Hospital, Emergency Room, General Practitioner

#### Introduction

Kounis syndrome, defined by the concurrence of allergic reaction and acute coronary syndrome, was identified by Kounis and Zavras in 1991<sup>1</sup>. The pathophysiology of the disease has been described as a complex process with mast cell-mediated progressive coronary vasospasm, intimal erosion or rupture. One study described, even an intact tunica intima may be damaged through this mechanism<sup>2</sup>. Although there are studies that have shown that arteries of various locations may be affected, coronary arteries (especially LAD) are impacted most<sup>3</sup>. In this article, we present a case of myocardial infarction following a bee sting, which we think was worsened by the anti-allergy treatment.

#### Case Report

A 66-year-old male, stung in the lower lip by a bee, was brought to our emergency room with sudden onset of vomiting, syncope, and hypotension. The diagnosis of anaphylaxis had been made and 0,5 mg of adrenaline was administered intramuscularly by the paramedics during the transfer. On examination in the ER, he was confused and had diffuse body erythema with lower lip and bilateral upper-eyelid angioedema. His vital signs were as follows: blood pressure, 90/60 mm Hg; pulse, 75 beats/minute; arterial oxygen saturation 96% on room air; and respiratory rate 12-15/minute. He was started on pheniramine 45.5 mg and methylprednisolone 80 mg intravenously. The ECG (electrocardiography) findings included (showed that) ST-segment depression in the anterior and lateral leads (D1-aVL-V1-V6), and ST-segment elevation in the inferior leads (D2-D3-aVF) (Figure 1). Based on these findings, acute ST-elevation myocardial infarction was diagnosed. The patient was given 300 mg of acetylsalicylic acid and 180 mg of ticagrelor orally, and 5000 IU heparin intravenously.

Following the improvement of the anaphylaxis symptoms, the patient underwent coronary angiography.

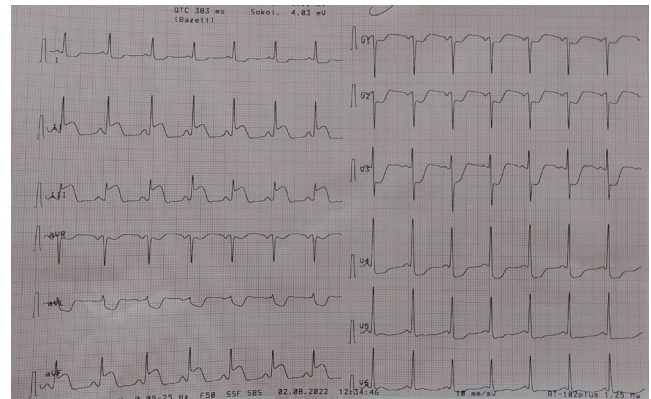
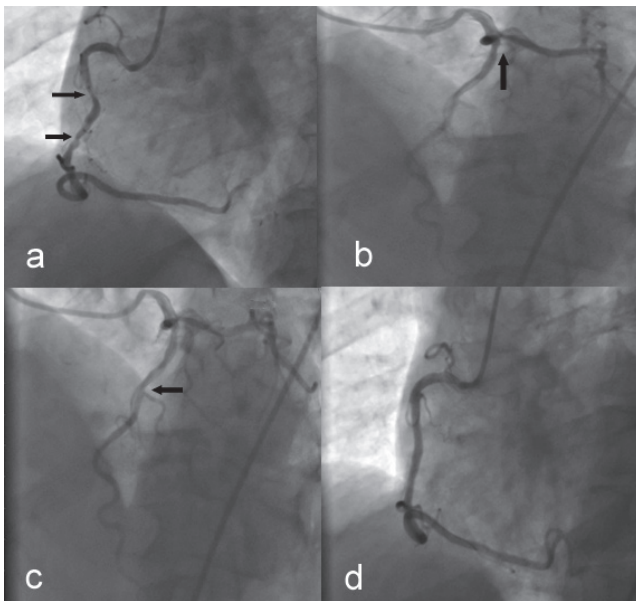


Figure 1: ECG showing inferior (STEMI) MI during allergic reaction.

While the 60-70% stenosis in the proximal left ascending artery (LAD) was planned to be electively evaluated through the fractional flow reserve (FFR) technique; stents were placed for the hazy lesion with an 80% stenosis in the proximal right coronary artery (RCA), and for another lesion with 90% stenosis in the later (distal) part of the RCA (Figure 2). ECG findings resolved upon the intervention (Figure 3). The ejection fraction was within normal limits on discharge from the hospital. Additionally, left ventricular hypertrophy and stage II diastolic dysfunction were noted. He was followed up in coronary intensive care unit for four days and was discharged on valsartan-hydrochlorothiazide, benidipine hydrochloride, atorvastatin calcium trihydrate, acetylsalicylic acid, clopidogrel and nebivolol.

#### Discussion

In the literature, three variants of Kounis syndrome have been described. While type 1 is seen in patients with no risk factors for ischemic heart disease, type 2 is mostly encountered in patients with the pre-existing atheromatous disease. Type 3, on the other hand, involves stent thrombosis following platelet activation. According to this classification,

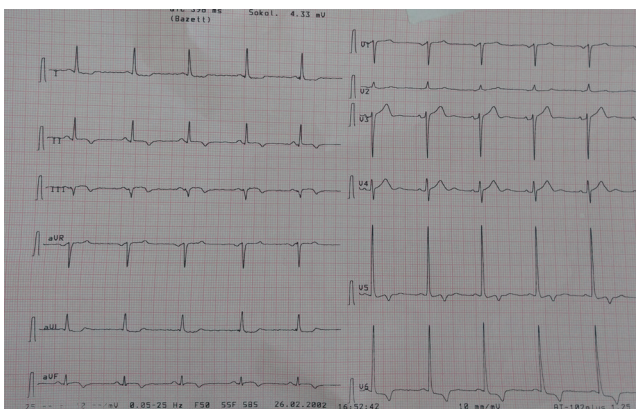


**Figure 2a:** 80 % and 90 % stenoses in the proximal RCA (dark arrows). **2b:** The lesion with 95% stenosis in the first diagonal branch of the LAD (dark arrow). **2c:** The lesion with %60 stenoses in the proximal LAD (dark arrow). **2d:** RCA is unobstructed after stent implantation.

the reaction our patient had corresponded to type 2, due to his predisposing risk factors for coronary artery disease.

Kounis syndrome may develop secondary to various allergens such as medications and insect poison. Atopic people are thought to be more vulnerable to the syndrome<sup>4</sup>. On further questioning, we have learnt our patient didn't have any known allergies, and it was his first time exposed to bee poison.

Adrenaline plays a vital role in the management of anaphylactic shock caused by Hymenoptera (insects' family) poisoning. The tryptase enzyme secreted by mast cells is shown to cause hypotension and plaque erosion<sup>5,6</sup>. Additionally, it can be extrapolated from the rise in



**Figure 3:** Normal ECG after angioplasty.

adrenaline levels in myocardial infarction that anti-allergy treatment may worsen an underlying coronary heart disease<sup>7</sup>. Likewise, we believe, adrenaline may have aggravated the ongoing myocardial infarction in our patient.

In light of the above, close cardiac monitoring is highly recommended in patients who develop severe allergic reactions, regardless of chest pain. It's worth noting that clinicians must pay even closer attention to patients with underlying cardiac comorbidities.

## Conclusion

In this study, we tried to explain the cardiac consequences of severe allergic reactions and anti-allergy treatment. It is not obvious which of these two plays a bigger part in the development of the acute coronary syndrome. However, given the high risk of dire outcomes, close cardiac monitoring and immediate intervention are instrumental in timely diagnosis.

## References

1. Kounis NG, Zavras GM. Histamine-induced coronary artery spasm: the concept of allergic angina. *The British journal of clinical practice*. 1991; 45(2), 121-128.
2. Constantinides P, Harkey M. Electron microscopic exploration of human endothelium in step-serial sections of early and advanced atherosclerotic lesions. *Annals of the New York Academy of Sciences*. 1990; 598, 113-124.
3. Gonzalez-de-Olano D, Alvarez-Twose I, Matito A, Sanchez-Munoz L, Kounis NG, Escribano L. Mast cell activation disorders presenting with cerebral vasospasm-related symptoms: a "Kounis-like" syndrome? *International journal of cardiology*. 2011; 150(2), 210-211.
4. Nikolaidis LA, Kounis NG, Gradman AH. Allergic angina and allergic myocardial infarction: a new twist on an old syndrome. *The Canadian journal of cardiology*. 2002; 18(5), 508-511.
5. Bonadonna P, Perbellini O, Passalacqua G, Caruso B, Colarossi S, Dal Fior D, et.al. Clonal mast cell disorders in patients with systemic reactions to Hymenoptera stings and increased serum tryptase levels. *Journal of allergy and clinical immunology*. 2009; 123(3), 680-686.
6. Mytas DZ, Stougiannos PN, Zairis MN, Tsiaousis GZ, Foussas SG, Hahalis GN, et.al. Acute anterior myocardial infarction after multiple bee stings. A case of Kounis syndrome. *International Journal of Cardiology*. 2009; 134(3), e129-e131.
7. Bertel O, Buhler FR, Baitsch G, Ritz R, Burkart F. Plasma adrenaline and noradrenaline in patients with acute myocardial infarction: relationship to ventricular arrhythmias of varying severity. *Chest*. 1982; 82(1), 64-68.