

Histopathological and Serum Biomarkers Analyses in MRONJ due to Periodontal Disease in Rats: Comparison of Zoledronic Acid and Denosumab

Ceren Damla Coskun¹ , Revan Birke Koca-Unsal² , Merva Soluk-Tekkesin³ , Faruk Celik⁴ , Hayriye Arzu Ergen⁴ , Umit Zeybek⁴ , Kivanc Bektas-Kayhan¹ , Meral Unur¹ 

¹Department of Oral and Maxillofacial Surgery, Faculty of Dentistry, Istanbul University, Istanbul, Turkiye

²Department of Periodontology, Faculty of Dentistry, University of Kyrenia, Kyrenia, Cyprus

³Department of Tumor Pathology, Institute of Oncology, Istanbul University, Istanbul, Turkiye

⁴Department of Molecular Medicine, Aziz Sançar Institute of Experimental Medicine, Istanbul University, Istanbul, Turkiye

ORCID ID: C.D.C. 0000-0003-4121-3777; R.B.K.Ü. 0000-0003-1540-983X; M.S.T. 0000-0002-7178-3335; F.Ç. 0000-0003-2433-0277; H.A.E. 0000-0001-5736-8453; Ü.Z. 0000-0001-8403-2939; K.B.K. 0000-0001-7149-9230; M.Ü. 0000-0003-4510-1668

Cite this article as: Coskun CD, Koca-Unsal RB, Soluk-Tekkesin M, Celik F, Ergen HA, Zeybek U, Bektas-Kayhan K, Unur M. Histopathological and serum biomarkers analyses in MRONJ due to periodontal disease in rats: Comparison of zoledronic acid and denosumab. *Experimed* 2023; 13(1): 8-14.

ABSTRACT

Objective: This study aimed to investigate the bisphosphonate and denosumab effects in medication-related osteonecrosis of the jaws (MRONJ) caused by periodontal disease with analyses of serum biomarkers and histopathology.

Materials and Methods: Forty Copenhagen rats were used in the study. A ligature wire was wrapped around the first molars to induce periodontal disease. The rats were divided into a zoledronic acid group (ZG) (n=12), a denosumab group (DG) (n=12), a saline group (SG) (n=10), and a control group (CG) (n=6). Prostate cancer was induced by injections for ZG, DG, and SG following the ligature application, and injections were repeated on the 14th and 21st days. While periodontal disease was evaluated clinically with gingival edema, swelling and redness, serum osteocalcin, osteopontin, parathormone and receptor activator of nuclear factor-kappa B ligand (RANKL) levels were evaluated using the LUMINEX technique. The Mann-Whitney U test was used for the comparison of parameters between groups (p<0.05).

Results: The osteocalcin levels were increased in CG, RANKL levels were decreased in DG, osteopontin levels were increased in ZG, and parathormone levels were increased in both ZG and CG.

Conclusion: Since the long-term use of bisphosphonates can cause osteonecrosis in the jaw bones, it should not be overlooked that this can also be caused by chronic inflammatory conditions such as periodontal disease.

Keywords: Bisphosphonates, denosumab, osteonecrosis, periodontal diseases, rats

INTRODUCTION

Periodontal disease is a common chronic inflammatory condition that affects about 20-50% of the global population (1). It is known that the etiological factor is bacteria, affecting the surrounding tissues of the teeth. The mildest form of periodontal disease is gingivitis, an infection only affecting the gingiva which is completely reversible with proper treatment. Bacterial dysbiosis increases when

gingivitis is not treated and turns into periodontitis, which is an irreversible infection characterized by the destruction of epithelial attachment and alveolar bone (2).

The relationship between periodontitis and systemic diseases is increasing with the reports published day by day. The periodontal disease which is a globally common disease is suspicious in medication-related osteonecrosis of the jaws (MRONJ) etiology. It is also regarded as a risk

Corresponding Author: Revan Birke Koca-Unsal **E-mail:** revanbirke.koca@kyrenia.edu.tr

Submitted: 18.10.2022 **Revision Requested:** 29.11.2022 **Last Revision Received:** 12.01.2023 **Accepted:** 17.01.2023 **Published Online:** 06.03.2023



Content of this journal is licensed under a Creative Commons Attribution-NonCommercial 4.0 International License.

factor for osteoradionecrosis of the jaws in the head and neck irradiated patients (3).

Prostate cancer is a well-known cancer type with a high rate of metastasis to the bone. The bone metastasis rate in prostate cancer is 74% (4). Bisphosphonates are used to reduce osteoclastic activity caused by androgen-deprivation therapy in bone metastasis of prostate cancer (5). Bisphosphonates are drugs that are frequently used to suppress the activity of bone metastasis and treat hypercalcemia which is a common complication of bone metastasis (6). Bisphosphonates which are pyrophosphate analogues have been used for a long time in the treatment of various diseases (5). Bisphosphonates bind with a high affinity to hydroxyapatites in the resorption areas of bones (7). Hence, they suppress osteoclast activity by reducing the development and aggregation of osteoclast progenitor cells (8).

As is well known, the use of bisphosphonates can lead to osteonecrosis of the jawbones (ONJ). This clinical condition was defined in 2003 and was named as Bisphosphonate-Induced Osteonecrosis of the Jaws (BRONJ) (9). Since then, a large number of patients showing serious consequences of these medication complications have been reported at a high growth rate (10). The American Association of Oral and Maxillofacial Surgeons (AAOMS) recommended a denomination from BRONJ to MRONJ in 2014 in order to accommodate the increasing number of ONJ cases in patients receiving other drugs such as Denosumab (Dmab), sunitinib, or rituximab (11, 12).

Dmab is a monoclonal human antibody (IgG₂) that is used in the treatment of bone metastasis (13). It affects osteoclastic activity by inhibiting osteoclast formation, reduces bone destruction by binding receptor activator of nuclear factor-kappa B ligand (RANKL) (14).

The etiopathology of osteonecrosis induced by bisphosphonates has been subjected to many studies in the past two decades (9). Dental invasive procedures and also infections such as periodontal diseases were the subjects of these studies, however, the reports on the occurrence of spontaneous osteonecrosis revealed another face of this question (15).

There are several proteins involved in bone metabolism, although some are more effective to monitor osteoblast activity and the activity of the drug used (16). These proteins are osteocalcin (OCN), which is synthesized by osteoblasts and is a marker of osteoblastic activity (17), osteopontin (OPN), which plays a role in binding osteoclasts to the mineralized bone matrix (18), and parathormone (PTH), which directly affects calcium metabolism and bone remodeling (19).

According to the literature, prostate cancer is one of the cancer types that most frequently causes bone metastasis (20), so a prostate cancer model in rats was created to examine the effect of periodontitis on MRONJ in oncology patients. This study aimed to investigate the effects of Dmab and bisphosphonate in MRONJ caused by periodontal disease with analyses of serum biomarkers and histopathology.

MATERIALS AND METHODS

This project has been reviewed and approved by the the Istanbul University Local Ethics Committee for Animal Experiments (2013/30). The study was carried out at Istanbul University, Aziz Sancar Institute of Experimental Medicine, Departments of Laboratory Animals Science and Molecular Medicine, and Istanbul University, Institute of Oncology, Department of Tumor Pathology.

Experimental Animals

Forty male Copenhagen rats, in the range of 270-300 gr body-weight, were obtained from Istanbul University, Aziz Sancar Institute of Experimental Medicine, Department of Laboratory Animals Science. They were accommodated in steel cages at an ambient temperature of 22±2 °C with 12 hours of light and dark cycles per day and had free access to fresh water and food ad libitum.

Experimental Procedure

General anesthesia was administered using 100 mg/kg ketamine HCl (50 mg/ml Ketalar®, Pfizer, United Kingdom) and Xylazine HCl (Rompun flakon, Bayer, Turkiye) injection. 0.25 mm-sized round retainer ligature wire was wrapped around the upper right first molars and fixed to the mesial of the tooth of all the rats to induce the experimental periodontal disease (Figure 1).

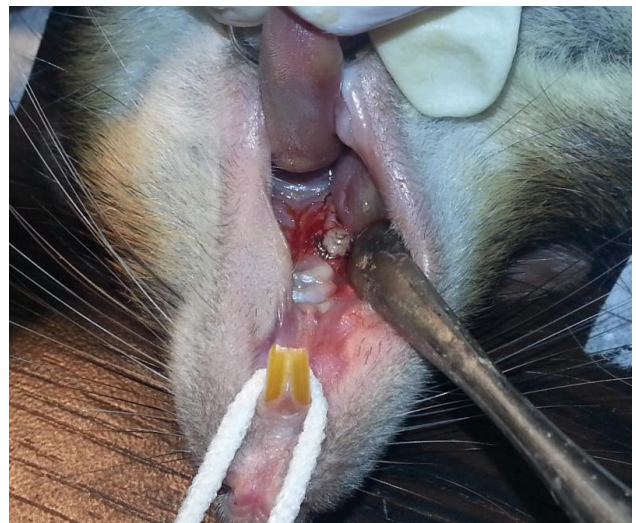


Figure 1. Placement of ligatures around 1st maxillary molar of rats.

Experimental Groups

Experimental animals were divided into four randomized groups: A zoledronic acid (ZA) group (ZG) (n=12), a Dmab group (DG) (n=12), a saline group (SG) (n = 10) and a control group (CG) (n=6).

Experimental Design

One week after the ligature application, prostate cancer was induced by the tumor cell line (R-3327MATLyLu) to the left

ventricle of the prostate of rats. Ten days after prostate cancer induction, the ZG received a weekly subcutaneous injection of 10 mg/kg ZA, the DG received a subcutaneous injection of 7.5 µg/kg of Dmab once a week, a weekly subcutaneous saline injection in the SG. All injections were repeated on days 7, 14 and 21 (21, 22). No intervention was made to the CG. All animals were clinically evaluated weekly regarding periodontal disease.

One week after the last injection, all animals were sacrificed with cervical dislocation. All tissues were dissected and evaluated before the histopathologic examination. For the periodontal disease examination, evaluation criterias were the presence of oedema, swelling and hyperemia at the gingiva. The maxilla and prostate of the experimental animals were then surgically removed for histopathological analysis. In addition, blood samples of 1 ml per animal from the cardiac tissue were collected and centrifuged at 1500 g for 10 min, and serum stored at -80°C until the immunoassays were conducted.

Histopathological Analysis

The samples were stained with the hematoxylin-eosin method and examined under a light microscope. The evaluation criteria under the light microscope (Olympus BX60 microscope, Tokyo, Japan) were determined as the presence of inflammation and necrosis in soft tissue and bone. Necrosis and foreign body reaction were graded as 0: no sign, +: existing. Inflammation was scored as 0 (absent), 1 (mild), 2 (moderate) and 3 (severe) (23). Prostate materials were stained with the hematoxylin-eosin method and examined under the light microscope to confirm tumor presence in each sample.

Immunoassay Method

Serum RANKL, OCN, OPN and PTH levels were determined using the LUMINEX technique according to the kits' instructions (MilliporeSigma, Merck KGaA, Darmstadt, Germany). 200 µl assay buffer was added to each well on the plate. The seal was placed on the plate and mixed with a plate shaker for 10 minutes. 25 µl of the appropriate matrix solution was added to the background, standard and control wells. The plate was sealed and covered with foil. It was incubated at 4°C for 16-18 hours in a plate shaker. The contents of the plate were poured out, the plate was washed 3 times. 50 µl detection antibody was added to each well. The plate was sealed and covered with

foil. It was incubated for 1 hour on the shaker. Streptavidin-Phycoerythrin (50 µl) was added to each well containing 50 µl detection antibody. The plate was sealed and covered with the foil. It was incubated in the shaker for 30 minutes. The contents of the plate were poured out and the plate was washed 3 times. 100 µl of Sheath Fluid was added to each well. The beads were resuspended in the plate shaker for 5 minutes. The plate was run with the appropriate device (Luminex Corporation, Texas, USA) and Luminex IS 100 Software.

Power Analysis

The power analysis of the study was calculated using the G*Power 3.1.9.2 program. In the study in which 4 parameters were examined in 4 experimental groups, the minimum sample value was 10, a total of 40 rats were found in each group with a two-way alternative hypothesis, a medium effect size of 0.25, a power of 80% and a margin of error of 5%. In order to increase the number of rats in the experimental groups, it was decided to have 12 rats each in the ZG and DG groups, and 6 rats each in the control and serum groups.

Statistical Analysis

Statistical analysis was performed with SPSS 25.0. The conformity of the data to the normal distribution was evaluated with the Kolmogorov-Smirnov test. While the homogeneity of variance was evaluated with the Levene test, the Welch ANOVA test was used to compare the inhomogeneous variance measurements between the groups, and the Dunnett's T3 test was used as the post hoc test for statistically significant measurements. In comparisons between groups, the level of serum RANKL, OCN, OPN and PTH levels were measured with the Mann-Whitney U test. The statistical significance limit was accepted as p<0.05.

RESULTS

LUMINEX Analysis

During the experiment, 6 animals from ZG, 6 animals from DG and 6 animals from SG were lost due to cancer. Serum RANKL, OCN, OPN, and PTH levels are shown in Table 1. In terms of OCN levels, the difference between the groups was not significant. RANKL levels were statistically lower in the DG compared to the CG (p=0.032). OPN levels were statistically increased in ZG

Table 1. Comparison of serum levels of RANKL, OCN, OPN and PTH in study groups.

Groups	RANKL (pg/ml)	OCN (pg/ml)	PTH (pg/ml)	OPN (pg/ml)
CG (n=6)	10.37±8.26*	4466.23±3043.62	32.74±28.07°	293.60±69.61†
SG (n=4)	4.56±2.07	6727.82±667.91	1.66±1.28 ^{β,°}	683.88±61.65
ZG (n=6)	9.97±6.04	6253.30±869.86	63.90±84.94 ^β	733.73±126.43 ^{†,α}
DG (n=6)	3.81±2.43*	5253.65±1023.82	15.83±11.82	321.91±237.35 ^α

*: p=0.032, °: p=0.019, °: p=0.013, ^β: p=0.010, †: p=0.04, RANKL: receptor activator of nuclear factor-kappa B ligand, OCN: osteocalcin, PTH: parathormone, OPN: osteopontin, CG: control group, SG: saline group, ZG: zoledronic acid group, DG: denosumab group, pg/ml: picograms per milliliters

compared to the DG ($p=0.013$), and CG ($p=0.04$). PTH levels were increased in both the ZG ($p=0.010$), and the CG ($p=0.019$) compared to the SG.

In the clinical examination, edema, swelling and hyperemia, which were the symptoms of the periodontal disease, were observed in all ligatured tissues.

Histopathological Results

In the histopathological evaluation, in one of the experimental animals in the ZG, resorption, and local necrosis, and dense colonies of microorganisms were observed in the alveolar bone (Figure 2). In the soft tissue, chronic inflammatory infiltration including mainly lymphoplasmacytic infiltration, and a slight increase in the number of cells in the basal layer of the surface epithelium was observed. Numerous lymphocyte infiltrations within the epithelium were also noted. Regarding this experimental animal, the inflammation score was 3 and the necrosis was labelled '+'. Sections taken from all other experimental animals showed similar histopathological characteristics that no necrosis was seen and scored as '0' and inflammation scored as '1'. In all these sections, alveolar bone generally preserved its natural structure. A mild chronic inflammatory infiltration (score 1) was observed in the

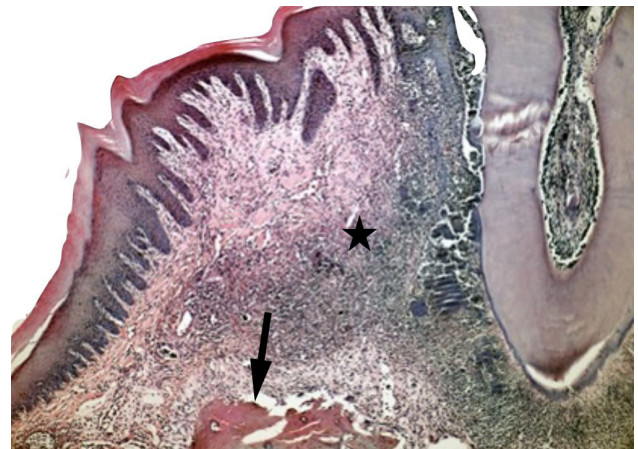


Figure 2. Severe chronic inflammatory infiltration (star) and alveolar bone loss (arrow) was observed under the surface mucosa demonstrating parakeratosis in the tissue sample obtained from the animal in ZG (H&E x 100).

gingival pocket through which the ligature passed (Figure 3). A well-differentiated carcinoma was observed in the prostate of all animals except for the control group confirmed with

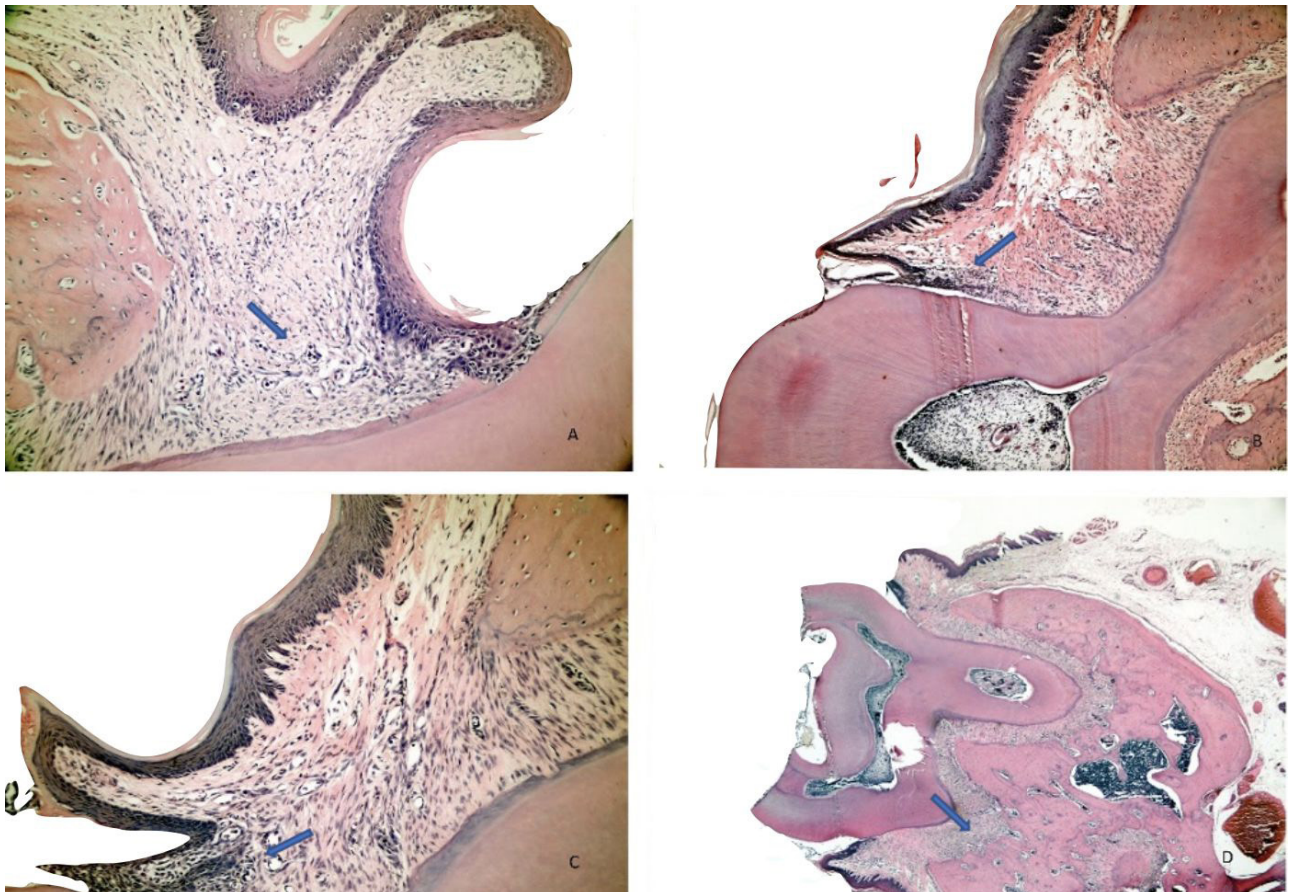


Figure 3. Representative histopathological images of the ZG (A), DG (B), SG (C), and CD (D) without any bone destruction, but with mild inflammation in the connective tissue (arrows).

histopathological examination. Also, distant organ metastasis developed in all animals except the control group. Metastases occurred most frequently in the lungs and the pancreas.

DISCUSSION

Prostate cancer is one of the most common malignancies among men, and bone metastases are the major cause of its morbidity and mortality. Rat models are frequently used in experimental studies on prostate biology, as the rat prostate has many common features with the human prostate and rats are one of the few species with spontaneous prostate adenocarcinoma (24). Male rats were used in the study to investigate the effects of ZA and Dmab hormone-independent, as estrogen secretion differentiates bone metabolism by affecting hormonal activity (25). Dunning R-3327 MATLyLu is an anaplastic, androgen-independent tumor cell line that can metastasize spontaneously, is an ideal drug for immunotherapeutic research in the treatment of metastatic prostate cancer (26). Therefore, Copenhagen male rats and Dunning R-3327MATLyLu tumor cell line were used in the study.

The tumor cell line can be injected into rats to induce prostate cancer by the subcutaneous, intravenous, intraosseous or orthotopic method (27). Since the survival time of the experimental animals in intravenous, intraosseous or subcutaneous applications of this cell line was reported as 15-20 days (28), the orthotopic method in which the cell line was directly injected into the prostate was used, and was reported as 30-35 days (29). Despite following a more conservative approach and daily subcutaneous saline injection, 18 rats were lost by the 28th day due to dehydration.

Since the characteristics of the molar teeth such as shallow gingival grooves and the attachment of the junction epithelium of rats are similar to those of humans, it is the most commonly used animal model to induce the experimental periodontal disease. Placing a ligature around the mandibular first molar tooth is a postulated, highly preferable model to induce experimental periodontal diseases in rats (29). Biofilm accumulation is increased around the ligature which was placed subgingivally and inflammation of periodontium is observed within an average of 21 days in this model (30).

Periodontal disease is a chronic inflammatory condition that develops as a result of host response, even though its etiological factor is bacteria. The diagnosis of periodontal disease, which is one of the most common chronic inflammatory diseases in the world affecting around 20-50% of the global population, can sometimes be overlooked even by dentists who focus on infection foci (1). Hence, the relationship between chronic periodontal inflammation and MRONJ, but not acute trauma such as tooth extraction, was evaluated in the study. There are several studies in the literature evaluating the relationship between periodontal disease and ZA, and more severe bone resorption was observed in the experimental group (31). However, there is no study evaluating the effect of Dmab on periodontal disease. The study is the first to examine the effect

of not only ZA but also Dmab on osteonecrosis in chronic periodontal inflammation by evaluating OPN, OCN, PTH and RANKL levels.

Periodontal disease is a complex and multifactorial chronic disease that is characterized by the destruction of periodontal tissues, and eventually results in the loss of the tooth. Since OCN is a marker that is synthesized by osteoblasts and indicates bone formation, a decrease in the serum level of this protein is considered a disorder in bone metabolism (32). Related to this, the resorption of alveolar bone in periodontal disease also causes a decrease in the serum OCN level. Similarly, studies are reporting that OCN levels increase with periodontal treatment (33).

Likewise, studies are reporting that the OPN level, which is one of the important markers in the alveolar bone resorption process, is associated with periodontal disease (34). Some studies have shown that the OPN level increased proportionally with the progression of the disease, and it was significantly reduced with the periodontal treatment (35).

PTH is both an anabolic and catabolic hormone that regulates the calcium and phosphate mechanism of bone (19). There are many studies in the literature regarding the therapeutic effect of PTH analogues (36). Intermittent or continuous administrations of PTH are similar to the anabolic and catabolic effects of endogenous PTH secretion (37). Since the number of osteoblasts increases with the anabolic effect of PTH, it is used as a therapeutic agent in periodontal treatment. In addition, the serum level of PTH decreases in periodontal diseases (38). Accordingly, the PTH level is one of the parameters to be evaluated in periodontal infections.

The OCN level is a parameter that indicates osteoblastic activity, and functions of osteoblasts. Although it was found at the highest level in CG induced by periodontal disease, which is chronic inflammation, its low levels in other groups (ZG, DG, SG) indicate that osteoblastic activity is suppressed in these groups. Although there are a few studies in the literature that are proportional to this result (17), there are also studies reporting that the relationship between OCN level, and bisphosphonate is dose-dependent (39).

Dmab inhibits osteoclast formation, function and bone remodeling by suppressing the RANK-RANKL interaction (40). The highest level of RANKL was found in the control group. This is an expected result because there is no agent to suppress RANKL activity in the environment. Statistically, it is lower in DG compared to CG. When the RANKL results were examined, although a decrease was seen in the ZG, it was not as effective as the substance Dmab.

OPN contributes to homeostasis, remodeling, biomineralization, and wound healing by stimulating osteoclasts to bind to the bone matrix. OPN level is significantly higher in ZG than in DG. The levels of the other groups relative to each other are not significant. The high level of OPN is strong evidence for

the resorptive activity of osteoclasts (41). OPN levels were determined as $CG < DG < SG < ZG$, respectively. Bone necrosis and resorption were observed only in ZG animals from our study groups. When we compared the ZG and DG groups in terms of OPN levels, a significant increase in ZG was found. While a few studies are showing that bisphosphonates increase OPN levels, there are also studies showing that they decrease OPN levels (17,42). This difference may be due to the dosage, the duration, and whether intravenous (IV) or oral bisphosphonates are used. We recommend that there may be an increase in OPN levels in ZG to suppress the necrotic formations seen in animals in this group.

PTH regulates bone calcium metabolism, and remodeling by affecting osteoblasts and osteoclasts (19). There are studies in which PTH is used in the treatment of various tumors (43), and osteoporosis (44). Likewise, in a study evaluating bone loss, it was found to be significantly lower in the study group in which ZA, and PTH were used together (45). Similarly, the PTH level was found to be significantly lower in ZG and CG compared to SG in our study.

The loss of about one-third of the rats due to metastases of prostate cancer, and osteonecrosis, and periodontal disease-dependent bone resorption were found in only one animal constitute the limitations of our study. For further studies, researchers should consider rat models with prostate cancer for short-termed clinical studies since life expectancy could be shorter than expected, and could affect the results of the study.

In this study, in which alveolar bone resorption was created with periodontal disease, and drugs that suppress bone resorption were used, 4 parameters showing different functions were examined. Parameters such as OCN and PTH, which inhibit bone resorption, decrease in periodontal disease, and increase with periodontal treatment, were compared with parameters such as RANKL and OPN, which have antagonist effects, and the effects of tumor (hence bone remodeling) inhibitory agents such as zoledronic acid, and Dmab on these parameters were shown. The effect mechanism of periodontal diseases, which can be seen frequently in the clinic, in patients using bisphosphonate and Dmab, has been demonstrated regarding biomarkers and histologically.

CONCLUSION

Increased PTH and OPN levels, and decreased OCN levels may indicate that patients who have been administered ZA are more susceptible to osteonecrosis, especially in chronic inflammatory conditions such as periodontal diseases. The investigation of zoledronic acid and Dmab in different dental conditions in randomized controlled trials will provide a better understanding of osteonecrosis.

Ethics Committee Approval: The experimental procedures were approved by the Istanbul University Local Ethics Committee for Animal Experiments (Decision No. 2013/30).

Peer-review: Externally peer-reviewed.

Author Contributions: Conception/Design of Study - C.D.C., K.B.K., H.A.E., M.S.T.; Data Acquisition - M.S.T., H.A.E., R.B.K.Ü.; Data Analysis/ Interpretation - M.S.T., H.A.E., F.Ç., Ü.Z., M.Ü.; Drafting Manuscript - R.B.K.Ü., K.B.K., M.S.T.; Critical Revision of Manuscript - R.B.K.Ü., K.B.K., Ü.Z.; Final Approval and Accountability - R.B.K.Ü., K.B.K.

Financial Disclosure: The study was supported by the Research Fund of Istanbul University (Project No: 35883).

REFERENCES

1. Nazir MA. Prevalence of periodontal disease, its association with systemic diseases and prevention. *Int J Health Sci (Qassim)* 2017; 11: 72-80.
2. Listgarten MA. Pathogenesis of periodontitis. *J Clin Periodontol* 1986; 13: 418-30. [CrossRef]
3. Sroussi HY, Epstein JB, Bensadoun RJ, Saunders DP, Lalla RJ, Migliorati CA et al. Common oral complications of head and neck cancer radiation therapy: mucositis, infections, saliva change, fibrosis, sensory dysfunctions, dental caries, periodontal disease, and osteoradionecrosis. *Cancer Med* 2017; 6: 2918-31. [CrossRef]
4. Kmetec A and Hajdinjak T. Evaluation of safety and analgesic consumption in patients with advanced cancer treated with zoledronic acid. *Radiol Oncol* 2013; 47: 289-95. [CrossRef]
5. Wu S, Dahut WL and Gulley JL. The use of bisphosphonates in cancer patients. *Acta Oncol* 2007; 46: 581-91. [CrossRef]
6. Mehrotra B. Bisphosphonates--role in cancer therapies. *J Oral Maxillofac Surg* 2009; 67: 19-26. [CrossRef]
7. Drake MT, Clarke BL, Khosla S. Bisphosphonates: mechanism of action and role in clinical practice. *Mayo Clin Proc* 2008; 83: 1032-45. [CrossRef]
8. Hughes DE, Wright KR, Uy HL, Sasaki A, Yoneda T, Roodman GD et al. Bisphosphonates promote apoptosis in murine osteoclasts in vitro and in vivo. *J Bone Miner Res* 1995; 10: 1478-87. [CrossRef]
9. Marx RE. Pamidronate (Aredia) and zoledronate (Zometa) induced avascular necrosis of the jaws: a growing epidemic. *J Oral Maxillofac Surg* 2003; 61: 1115-7. [CrossRef]
10. Rustemeyer J and Bremerich A. Bisphosphonate-associated osteonecrosis of the jaw: what do we currently know? A survey of knowledge given in the recent literature. *Clin Oral Investig* 2010; 14: 59-64. [CrossRef]
11. Sivoletta S, Lumachi F, Stellini E, Favero L. Denosumab and anti-angiogenic drug-related osteonecrosis of the jaw: an uncommon but potentially severe disease. *Anticancer Res* 2013; 33: 1793-7.
12. Ruggiero SL, Dodson TB, Fantasia J, Goodday R, Aghaloo T, Mehrotra B et al. American Association of Oral and Maxillofacial Surgeons position paper on medication-related osteonecrosis of the jaw--2014 update. *J Oral Maxillofac Surg* 2014; 72: 1938-56. [CrossRef]
13. Delmas PD. Clinical potential of RANKL inhibition for the management of postmenopausal osteoporosis and other metabolic bone diseases. *J Clin Densitom* 2008; 11: 325-38. [CrossRef]
14. Yee AJ and Raju NS. Denosumab, a RANK ligand inhibitor, for the management of bone loss in cancer patients. *Clin Interv Aging* 2012; 7: 331-8. [CrossRef]
15. Lorenzo-Pouso AI, Perez-Sayans M, Chamorro-Petronacci C, Gándara-Vila P, López-Jornet P, Carballo J et al. Association between periodontitis and medication-related osteonecrosis of the jaw: A systematic review and meta-analysis. *J Oral Pathol Med* 2020; 49: 190-200. [CrossRef]

16. Wei R, Wong JPC and Kwok HF. Osteopontin -- a promising biomarker for cancer therapy. *J Cancer* 2017; 8: 2173-83. [\[CrossRef\]](#)
17. Mergoni G, Vescovi P, Sala R, Merigo E, Passerini P, Maestri R et al. The effect of laser therapy on the expression of osteocalcin and osteopontin after tooth extraction in rats treated with zoledronate and dexamethasone. *Support Care Cancer* 2016; 24: 807-13. [\[CrossRef\]](#)
18. Zhao H, Chen Q, Alam A, Cui J, Suen KC, Soo AP et al. The role of osteopontin in the progression of solid organ tumour. *Cell Death Dis* 2018; 9: 356. [\[CrossRef\]](#)
19. Silva BC and Bilezikian JP. Parathyroid hormone: anabolic and catabolic actions on the skeleton. *Curr Opin Pharmacol* 2015; 22: 41-50. [\[CrossRef\]](#)
20. Wong SK, Mohamad NV, Giaze TR, Chin KY, Mohamed N, Ima-Nirwana S. Prostate cancer and bone metastases: The underlying mechanisms. *Int J Mol Sci* 2019; 20(10): 2587. [\[CrossRef\]](#)
21. Gerstenfeld LC, Sacks DJ, Pelis M, Mason ZD, Graves DT, Barrero M et al. Comparison of effects of the bisphosphonate alendronate versus the RANKL inhibitor denosumab on murine fracture healing. *J Bone Miner Res* 2009; 24(2): 196-208. [\[CrossRef\]](#)
22. Erdem MA, Cankaya AB, Isler SC, Demircan S, Soluk M, Kasapoglu C et al. Extraction socket healing in rats treated with bisphosphonate: animal model for bisphosphonate related osteonecrosis of jaws in multiple myeloma patients. *Med Oral Patol Oral Cir Bucal* 2011; 16(7): e879-e883. [\[CrossRef\]](#)
23. Özkahraman N, Balcioglu NB, Soluk Tekkesin M, Altundag Y, Yalcin S. Evaluation of the efficacy of mineralized dentin graft in the treatment of intraosseous defects: An experimental in vivo study. *Medicina (Kaunas)* 2022; 58(1): 103. [\[CrossRef\]](#)
24. Lamb DJ and Zhang L. Challenges in prostate cancer research: animal models for nutritional studies of chemoprevention and disease progression. *J Nutr* 2005; 135: 3009S-3015S. [\[CrossRef\]](#)
25. Macari S, Duffles LF, Queiroz-Junior CM, Madeira MFM, Dias GJ, Teixeira MM et al. Oestrogen regulates bone resorption and cytokine production in the maxillae of female mice. *Arch Oral Biol* 2015; 60: 333-41. [\[CrossRef\]](#)
26. Vieweg J, Rosenthal FM, Bannerji R, Heston WD, Fair WF, Gansbacher B, et al. Immunotherapy of prostate cancer in the Dunning rat model: Use of cytokine gene modified tumor vaccines. *Cancer Res* 1994; 54: 1760-5.
27. Halin S, Rudolfsson SH, Van Rooijen N, Bergh A. Extratumoral macrophages promote tumor and vascular growth in an orthotopic rat prostate tumor model. *Neoplasia* 2009; 11: 177-86. [\[CrossRef\]](#)
28. Liepe K, Geidel H, Haase M, Hakenberg OW, Runge R, Kotzerke J. New model for the induction of osteoblastic bone metastases in rat. *Anticancer Res* 2005; 25: 1067-73.
29. Oz HS and Puleo DA. Animal models for periodontal disease. *J Biomed Biotechnol* 2011; 2011: 754857. [\[CrossRef\]](#)
30. de Molon RS, Park CH, Jin Q, Sugai J, Cirelli JA. Characterization of ligature-induced experimental periodontitis. *Microsc Res Tech* 2018; 81: 1412-21. [\[CrossRef\]](#)
31. Messer JG, Mendieta Calle JL, Jiron JM, Castillo EJ, Poznak CV, Bhattacharyya N. et al. Zoledronic acid increases the prevalence of medication-related osteonecrosis of the jaw in a dose dependent manner in rice rats (*Oryzomys palustris*) with localized periodontitis. *Bone* 2018; 108: 79-88. [\[CrossRef\]](#)
32. Bhadracha H, Khatkhatay MI and Desai M. Development of an in house ELISA for human intact osteocalcin and its utility in diagnosis and management of osteoporosis. *Clin Chim Acta* 2019; 489: 117-23. [\[CrossRef\]](#)
33. Buduneli E, Buduneli N, Vardar-Sengul S, Kardesler L, Atilla G, Lappin D et al. Systemic low-dose doxycycline and alendronate administration and serum interleukin-1beta, osteocalcin, and C-reactive protein levels in rats. *J Periodontol* 2005; 76: 1927-33. [\[CrossRef\]](#)
34. Kido J, Nakamura T, Asahara Y, Sawa T, Kohri K, Nagata T. Osteopontin in gingival crevicular fluid. *J Periodontal Res* 2001; 36: 328-33. [\[CrossRef\]](#)
35. Nakashima K, Giannopoulou C, Andersen E, Roehrich N, Brochut P, Dubrez B et al. A longitudinal study of various crevicular fluid components as markers of periodontal disease activity. *J Clin Periodontol* 1996; 23: 832-38. [\[CrossRef\]](#)
36. Erten Taysi A, Cevher E, Sessevmez M, Olgac V, Taysi NM, Atalay B. The efficacy of sustained-release chitosan microspheres containing recombinant human parathyroid hormone on MRONJ. *Braz Oral Res* 2019; 33: e086. [\[CrossRef\]](#)
37. Jilka RL. Molecular and cellular mechanisms of the anabolic effect of intermittent PTH. *Bone* 2007; 40: 1434-46. [\[CrossRef\]](#)
38. Stutz C, Batool F, Petit C, Strub M, Buchler-Bopp S, Benkirane-Jessel N et al. Influence of parathyroid hormone on periodontal healing in animal models: A systematic review. *Arch Oral Biol* 2020; 120: 104932. [\[CrossRef\]](#)
39. Corrado A, Neve A, Maruotti N, Gaudio A, Marucci A, Cantatore FP. Dose-dependent metabolic effect of zoledronate on primary human osteoblastic cell cultures. *Clin Exp Rheumatol* 2010; 28: 873-9. [\[CrossRef\]](#)
40. De Castro J, Garcia R, Garrido P, Isla D, Massuti B, Blanca B et al. Therapeutic potential of denosumab in patients with lung cancer: Beyond prevention of skeletal complications. *Clin Lung Cancer* 2015; 16: 431-46. [\[CrossRef\]](#)
41. Altintas A, Saruhan-Direskeneli G, Benbir G, Demir M, Purisa S. The role of osteopontin: a shared pathway in the pathogenesis of multiple sclerosis and osteoporosis? *J Neurol Sci* 2009; 276: 41-4. [\[CrossRef\]](#)
42. Liu H, Cui J, Sun J, Du J, Feng W, Sun B et al. Histochemical evidence of zoledronate inhibiting c-src expression and interfering with CD44/OPN-mediated osteoclast adhesion in the tibiae of mice. *J Mol Histol* 2015; 46: 313-23. [\[CrossRef\]](#)
43. Ng PY, Ong AJ, Gale LS, Dass CR. Treatment of bone disorders with parathyroid hormone: success and pitfalls. *Pharmazie* 2016; 71: 427-33.
44. Leder BZ. Parathyroid hormone and parathyroid hormone-related protein analogs in osteoporosis therapy. *Curr Osteoporos Rep* 2017; 15: 110-9. [\[CrossRef\]](#)
45. Curtis RC, Custis JT, Ehrhart NP, Ehrhart EJ, Condon KW, Gookin SE et al. Combination therapy with zoledronic acid and parathyroid hormone improves bone architecture and strength following a clinically-relevant dose of stereotactic radiation therapy for the local treatment of canine osteosarcoma in athymic rats. *PLoS One* 2016; 11: e0158005. [\[CrossRef\]](#)