

Parvovirus-induced autoimmune hepatitis: First case in the literature

Arda YAVUZ¹ , Ayse Nur TOKSOZ YILDIRIM² , Feruze YILMAZ ENC¹ , Ilyas TUNCER¹ 

¹ Division of Gastroenterology, Department of Internal Medicine, School of Medicine, Istanbul Medeniyet University, Istanbul, Turkey.

² Department of Pathology, School of Medicine, Istanbul Medeniyet University, Istanbul, Turkey.

Corresponding Author: Feruze YILMAZ ENC

E-mail: feruzey@yahoo.com

Submitted: 12.05.2022

Accepted: 17.07.2022

ABSTRACT

Parvovirus B19 infection is usually self-limiting in immunocompetent individuals. Twenty-five percent of infected individuals are completely asymptomatic during infection, with 50% of them presenting flu-like symptoms and the remaining patients presenting erythema infectiosum, arthralgia, or arthritis. More rarely, transient aplastic crisis is seen in individuals with chronic haemolytic disorders. Chronic pure red cell aplasia and aplastic anaemia may also be observed in immunocompromised patients. There is sufficient evidence in the literature suggesting that B19 infections can also cause a spectrum of liver diseases, ranging from elevated transaminase levels to acute hepatitis, fulminant liver failure, and even chronic hepatitis. This case report discusses a patient with acute parvovirus infection and newly diagnosed autoimmune hepatitis (AIH) and the role of this viral infection in the disease.

Keywords: Parvovirus, autoimmune hepatitis, acute liver injury, pancytopenia

1. INTRODUCTION

Human parvo-virus B19 is a non-enveloped DNA virus that has tropism for erythroid progenitor cells of human beings. Patients infected with parvovirus are asymptomatic or have flu like symptoms mostly; arthralgia, arthritis and skin lesions can also be seen. Rarely red cell aplasia, bicytopenia or aplastic anemia have been reported. Parvo-virus B19 infections can also result in a spectrum of liver diseases, ranging from elevated transaminase levels to acute hepatitis, fulminant liver failure, and even chronic hepatitis [1].

Autoimmune hepatitis is an autoimmune liver disease mostly seen in middle-aged females with other autoimmune diseases. Presentation changes from asymptomatic cases, fulminant liver failure to cirrhosis and/or hepatocellular carcinoma. Autoimmune hepatitis can be seen either as primary autoimmune disease or secondary to other factors inducing autoimmunity: drugs, herbals or viral infections. Case reports of autoimmune hepatitis are reported related to Epstein-Barr virus, varicella-zoster virus, hepatitis A virus, hepatitis C virus or human herpesvirus.

Here, we present a case with acute parvo-virus infection and newly diagnosed autoimmune hepatitis related to this viral infection.

2. CASE REPORT

A 56-year-old immunocompetent Turkish female with a history of Sjogren's and Hashimoto's disease presented to the emergency department with a 2-week history of fatigue, nausea without emesis, and weight loss. On admission, she was afebrile, and physical examination revealed jaundice but no hepatomegaly, lymphadenopathy, or rash. She had no history of herbal product use, alcohol or mushroom consumption, or substance abuse or a family history of liver disease. Laboratory data showed the following: aspartate aminotransferase 827 U/L, alanine aminotransferase 959 U/L, total bilirubin 4.95 mg/dL, direct bilirubin 3.96 mg/dL, alkaline phosphatase 206 U/L, gamma-glutamyl transferase 388 U/L, lactic dehydrogenase 332 U/L,

How to cite this article: Yavuz A, Toksoz Yildirim AN, Yilmaz Enc F, Tuncer I. Parvovirus-induced autoimmune hepatitis: First case in the literature. *Marmara Med J* 2022; 3; 35(3):376-378. doi: 10.5472/marumj.1195421

INR 1.26, WBC $4.8 \times 10^9/\mu\text{L}$, Hgb 14 g/dL, and Plt $135 \times 10^9/\mu\text{L}$. Abdominal ultrasonography findings were unremarkable.

After admission, the patient underwent an extensive workup for acute hepatitis. Tests were negative for hepatitis A, B, C, and E; human immunodeficiency; Epstein-Barr; and cytomegalovirus. However, serological results were significantly positive for antinuclear antibodies (ANA) for 1/3200 and anti-smooth muscle antibodies for 1/100. Parvovirus IgM was also detected (first test: 44.8 IU/mL), and the patient had bicytopenia (WBC: $4 \times 10^9/\mu\text{L}$, Hgb: 11.3 g/dL, Plt: $86 \times 10^9/\mu\text{L}$). Liver biopsy was performed for suspected autoimmune hepatitis. On the third day, she developed pancytopenia, and the infection and haematology departments were consulted. Blastic cells were detected in the blood smear, and the patient's sister had a history of lymphoma; therefore, a bone marrow biopsy was performed. After the second positive test for parvovirus (second IgM test: 36.25 IU/mL with a positive parvovirus IgG test), the patient was treated with valacyclovir, which was administered for 7 days as suggested by the infection department. Liver histology revealed interface hepatitis lymphoplasmacytic infiltrate, lobular necroinflammatory activity, and hepatocyte rosette formation, which confirmed autoimmune hepatitis (Figures 1 and 2). After liver biopsy, 30 mg prednisolone with 50 mg azathioprine was initiated. Bone marrow histology revealed normocellular bone marrow with mild lymphoplasmacytic cell infiltration. On immunohistochemical examination, heterogeneous staining with CD3 and CD20 was observed, and mild interstitial lymphocytosis and mild plasmacytosis were detected and interpreted as reactive (Figure 3). Her hemogram parameters were normal after 4 weeks of treatment, and liver enzyme levels were normal after 6 weeks (Figure 4).

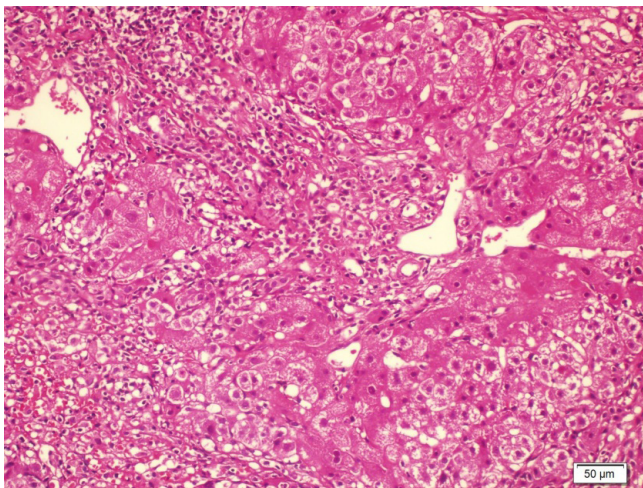


Figure 1. Interface hepatitis lymphoplasmacytic infiltrate, lobular necroinflammatory activity (haematoxylin and eosin 20x)

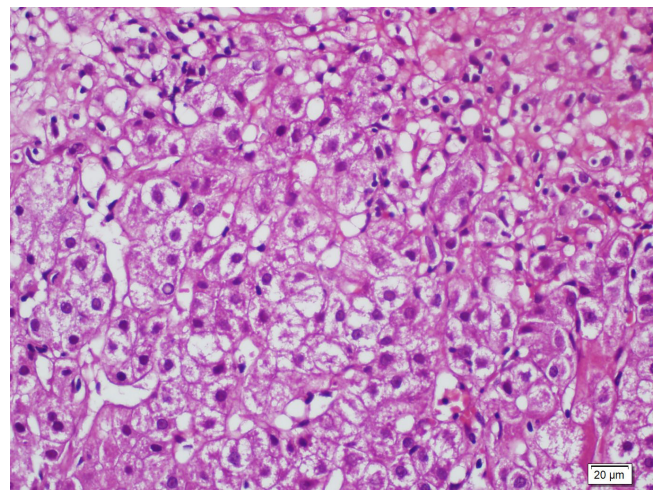


Figure 2. Hepatocyte rosettes (haematoxylin and eosin 40x)

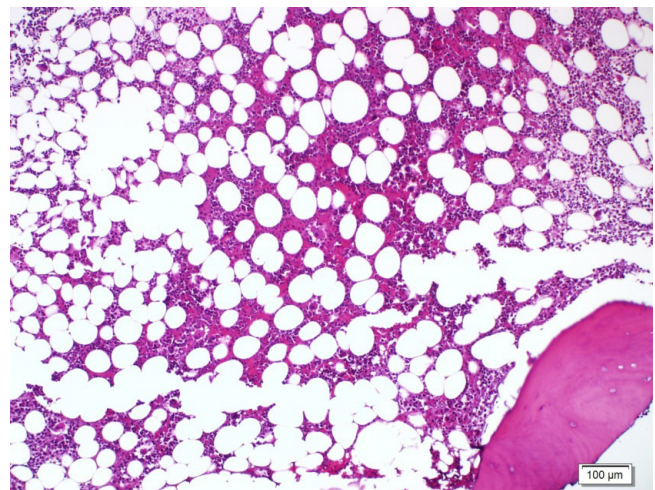


Figure 3. Normocellular bone marrow with mild lymphoplasmacytic cell infiltration

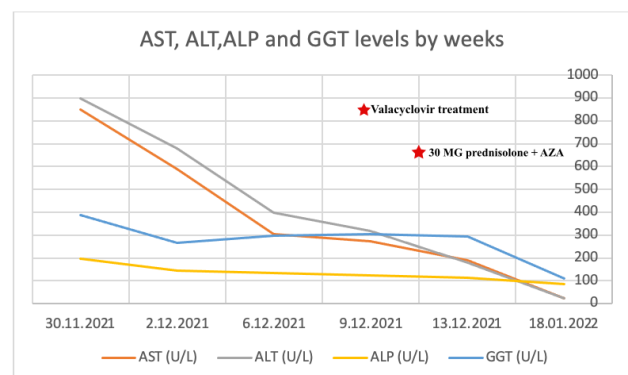


Figure 4. AST, ALT, ALP, and GGT levels after admission

3. DISCUSSION

Human parvovirus B19 is a non-enveloped, single-stranded DNA virus that codes for two major structural or capsid proteins, VP1 and VP2, and one non-structural protein, NS1. It exhibits tropism for erythroid progenitor cells, which possess the P-antigen. Most virus-related clinical symptoms result from cytolytic and apoptotic effects of NS1 on erythroid progenitor cells. Non-erythroid cells also express P-antigen, but to a lesser extent. VP1 also plays a role in infection and autoimmunity. Viral infections are a well-recognised prelude to autoantibody production, and many mechanisms may account for immune-mediated clinical consequences. The most probable explanation is molecular mimicry, in which specific antiviral responses cross-react with the host tissues. In addition, low-titre autoantibody production in symptomatic parvovirus B19 infections is common and may induce arthritis.

Parvoviruses may cause hepatitis, hepatitis-associated anaemia, and acute liver failure in infected patients [1]. These clinical manifestations have mainly been reported in children. Parvovirus-induced hepatitis is less common in adults than in children; however, it has a much less severe course with better patient outcomes. Most adult patients have complete and spontaneous remission, but one case required liver transplantation [2]. The mechanism underlying parvovirus-induced liver injury is debatable. The cytotoxic effect of the nonstructural (NS1) protein expression may induce immune-mediated injury by interferon-gamma due to T cells or a selective defect in patients with B19 infection. This mechanism may also cause hemophagocytic syndrome via interferon-gamma and tumour necrosis factor-alpha, leading to pancytopenia and hepatic dysfunction. The second effect of the virus is the induction of other antibodies, including anti-mitochondrial antibodies. Kerr and Boyd tested 53 patients with acute parvovirus B19 infection for antibodies, and seven of them were positive for ANA-2, rheumatoid factor-1, anti-reticulin antibody-2, anti-mitochondrial antibody-2, and anti-parietal cell antibody-1 [3].

In the present case, autoimmune hepatitis developed after a symptomatic parvovirus infection. Some cases have reported autoimmune hepatitis related to Epstein-Barr virus, varicella-zoster virus, hepatitis A virus, or human herpesvirus 6. To the best of our knowledge, this is the first report of parvovirus-induced autoimmune hepatitis. We believe that viral infections trigger autoimmune diseases in patients with certain risk factors or genetic predispositions, which should always be taken into consideration.

Compliance with Ethical Standards

This research was conducted ethically by following per under Helsinki World Medical Association Declaration.

Patient Consent: The patient gave her consent for images and other clinical information relating to her case to be reported in a medical publication.

Conflict of Interest Statement: The authors have no conflict of interest to declare.

Funding Sources: This research did not receive any specific grant from funding agencies in the public, commercial, or not-for-profit sectors.

Authors' Contributions: The authors confirm contribution to the paper as follows: AY and FYE: Study conception and design and draft article preparation, AY and ANTY: Data collection, IT and AY: Analysis and interpretation of results. All authors reviewed the results and approved the final version of the manuscript.

REFERENCES

- [1] Bihari C, Rastogi A, Saxena P *et al.* Parvovirus b19 associated hepatitis. *Hepat Res Treat* 2013;2013:472027.
- [2] Krygier DS, Steinbrecher UP, Petric M *et al.* Parvovirus B19 induced hepatic failure in an adult requiring liver transplantation. *World J Gastroenterol* 2009; 15(32): 4067-9.
- [3] Kerr JR, Boyd N. Autoantibodies following parvovirus B19 infection. *J Infect* 1996;32:41-7.