

A STUDY ON THE FEASIBILITY AND REPEATABILITY OF FETAL BASILAR ARTERY DOPPLER MEASUREMENTS BETWEEN 11 AND 13+6 WEEKS OF GESTATION

11-13+6 GEBELİK HAFTALARI ARASINDA FETAL BAZİLER ARTER DOPPLER ÖLÇÜMLERİNİN UYGULANABİLİRLİĞİ VE TEKRARLANABİLİRLİĞİ ÜZERİNE BİR ÇALIŞMA

Tuğba SARAÇ SİVRİKOZ¹ , Selen GÜRSOY ERZİNCAN² , Gürcan TÜRKİYILMAZ³ , Nihat DEMİRKOL¹ , Recep HAS¹ , İbrahim Halil KALELİOĞLU¹ 

¹Istanbul University, Istanbul Faculty of Medicine, Department of Obstetrics and Gynecology Istanbul, Türkiye

²Bakirkoy Dr Sadi Konuk Training and Research Hospital, Department of Obstetrics and Gynecology Istanbul, Türkiye

³Van Lokman Hekim Hospital, Department of Obstetrics and Gynecology, Van, Türkiye

ORCID ID: T.S.S. 0000-0001-5482-9429; S.G.E. 0000-0003-1764-0285; G.T. 0000-0002-5514-0233; N.D. 0000-0001-6605-8166; R.H. 0000-0002-1372-8506; İ.H.K. 0000-0003-1349-2561

Citation/Atf: Sarac Sivrikoz T, Gursoy Erzincan S, Turkyilmaz G, Demirkol N, Has R, Kalelioglu IH. A study on the feasibility and repeatability of fetal basilar artery Doppler measurements between 11 and 13+6 weeks of gestation. Journal of Advanced Research in Health Sciences 2023;6(1):10-16. <https://doi.org/10.26650/JARHS2023-1202942>

ABSTRACT

Objective: The fetal basilar artery Doppler (BA-D) measurements could be an easier alternative method to middle cerebral artery Doppler at the first trimester for the prediction of early fetal anemia. Our aim is to test its feasibility and construct reference ranges of BA-D at the first trimester

Materials and Methods: The study was analyzed retrospectively by using a transabdominal Doppler ultrasound which measured the fetuses at a crown-rump length (CRL) ranging from 45 to 81mm in 145 singleton pregnancies at the first trimester. The BA was imaged in the midsagittal plane, the pulse Doppler was placed just caudal to the anterior echogenic line of the brainstem, and the insonation angle was kept below 30°. The pulsatility index (PI) and peak systolic velocity (PSV) were also measured.

Results: A total of 138 out of the 145 fetuses were included. The mean CRL was 60.5±10.6 mm (range: 45-81mm). The mean nuchal translucency (NT) was 1.51±0.46 mm. The PI and PSV varied significantly, with the gestational age, CRL, NT, biparietal diameter ($p < 0.05$), and regression models being constructed for each variable. The 5th, 50th, and 95th percentiles for the BA PI and PSV Doppler measurements at each gestational week were determined. Intraclass correlation coefficient for the BA PI and PSV measurements were 0.792 (95% CI=0.661-0.876; $p < 0.01$) and 0.457 (95% CI=0.208-0.650; $p < 0.01$), respectively.

Conclusion: The BA PI and PSV values were determined during the first trimester sonography of healthy fetuses. Intraobserver reproducibility is acceptable for BA and should be supported by new studies for its use in the diagnosis of early fetal anemia.

Keywords: Basilar artery, Doppler ultrasound, first trimester ultrasound, peak systolic velocity, pulsatility index

ÖZ

Amaç: Fetal baziler arter Doppler (BA-D) ölçümleri, erken fetal anemi tahmini için ilk trimesterde orta serebral arter Doppleri'ne daha kolay bir alternatif olabilir. Amacımız, ilk trimesterde BA-D'nin fizibilitesini test etmek ve referans aralıklarını oluşturmaktır.

Gereç ve Yöntem: Çalışma retrospektif olarak planlanmış olup, ilk üç ayda trans abdominal Doppler ultrasonda baş-popo mesafesi (BPM) 45 ile 81 mm arasında ölçülen 145 tekil gebelik dahil edildi. BA midsagittal düzlemde görüntülenerek, puls Doppler beyin sapının ön ekojenik hattının hemen kaudaline yerleştirilmiş ve insonasyon açısı 30°'nin altında tutulmuştur. Pulsatilite indeksi (PI) ve pik sistolik hız (PSH) ölçüldü.

Bulgular: 138 fetüs kriterlere uygun idi. Ortalama BPM 60.5±10,6 mm (aralık:45-81 mm), ortalama ense saydamlığı (ES) 1.51±0.46 mm'di. PI ve PSH; gebelik yaşı, BPM, ES, biparietal çap ile değişiklik göstermiş, her gebelik için regresyon modelleri oluşturulmuştur ($p < 0.05$). Her gebelik haftasında BA PI ve PSH Doppler ölçümleri için 5.50. ve 95. persentiller belirlendi. BA PI ve PSH ölçümleri için korelasyon katsayısı sırasıyla 0.792 (%95 GA=0.661-0.876; $p < 0.01$) ve 0.457 (%95 GA=0.208-0.650; $p < 0.01$) idi.

Sonuç: BA PI ve PSV değerleri sağlıklı fetüsler birinci trimester sonografisi sırasında belirlenmiştir. Gözlemci içi tekrarlanabilirlik BA için kabul edilebilir olup erken fetal anemi tanısında kullanılması için yeni çalışmalarla desteklenmelidir.

Anahtar Kelimeler: Baziler arter, Doppler ultrason, ilk üçay sonografisi, pik sistolik hız, pulsatilite indeksi

Corresponding Author/Sorumlu Yazar: Tuğba SARAÇ SİVRİKOZ E-mail: tugbasrc@gmail.com

Submitted/Başvuru: 11.11.2022 • **Revision Requested/Revizyon Talebi:** 10.12.2022 • **Last Revision Received/Son Revizyon:** 13.12.2022

• **Accepted/Kabul:** 19.12.2022 • **Published Online/Online Yayın:** 28.02.2023



This work is licensed under Creative Commons Attribution-NonCommercial 4.0 International License

INTRODUCTION

Fetal anemia frequently occurs either secondary to Rh alloimmunization or parvovirus B19 infection and can be seen in early gestation, even if hydrops has not been developed yet (1-6). Especially in the history of Rh alloimmunization, if there is a pregnancy loss or hydrops due to fetal anemia before 20 weeks of gestation, there should be an earlier following up of the current pregnancy. Since a subsequent pregnancy will be at risk for anemia development, early screening would be appropriate and reasonable, starting approximately four to six weeks before the week of the previous pregnancy loss (7). Most studies address the evaluation of middle cerebral artery (MCA) by ultrasound to identify fetal anemia as a noninvasive screening tool (8-10). The measurement of peak systolic velocity (PSV) of MCA is currently necessary to diagnose fetal anemia. Therefore, nomograms of the MCA PSV and MCA pulsatility index (PI) for each week of gestational age starting from 11 weeks of gestation have been constructed (11-13).

In this respect, other cerebral arteries as internal carotid arteries (ICAs) and anterior cerebral artery (ACA) could also be used (6, 8, 9). While the examination of these arteries may be reasonable, the detection and measurement of each side can be more complicated and take more time due to fetal movement, size, and technical limitations. Moreover, the section and angle which are used to measure the MCA PSV or PI in the first trimester are not included in standard cranial ultrasonography plans. Sonographic evaluation of the fetal head in the midsagittal plane is an integral part of first trimester ultrasonography and is a familiar plan for sonographers. Hence, we suggest that the evaluation of the basilar artery (BA) may be an alternative path to MCA in the first trimester. Therefore, we aim to evaluate the feasibility and repeatability of the BA Doppler analysis of healthy fetuses and to establish normal reference values of BA Doppler indices at between 11 and 14 weeks of gestation.

MATERIALS and METHODS

The current study was performed between January 2019 and May 2020 in a private clinic. The BA Doppler flow measurements were performed on 145 consecutive patients admitted in a setting of first-trimester combined-screening tests for chromosomal abnormalities. The study was based on the principles of the Declaration of Helsinki. All patients gave informed consent to participate in the study prior to ultrasonographic examinations. This study was undertaken with the Institutional Review Board's approval (Number:1356719).

The inclusion criteria were singleton healthy pregnancies, crown-rump length (CRL) between 45 and 81mm, and the absence of fetal structural and chromosomal abnormalities at 11-13+6 weeks of gestation. Fetuses with any structural and/or chromosomal abnormalities, in utero fetal demise, those loss to follow-up, and abnormal fetal outcomes (such as intrauterine growth restriction) were excluded from the analysis. Ultrasonographic screenings and examinations for BA had been performed transabdominally using a 5-MHz curvilinear probe

(Voluson E8, General Electrics Healthcare Technologies, Zipf, Austria) by only one author (I.H.K.) in all cases.

The BA Doppler measurements were performed as a part of first trimester chromosomal screening and anomaly scan. All pregnancies were followed-up and the perinatal outcomes were made available. To obtain a BA trace, we used the technique described for intracranial translucency by Chaoui et al. (14). The exact midsagittal plane of the fetal face was obtained, and the image was magnified until the fetal head and upper thorax occupied the whole screen. Following the visualization of the lines of brainstem, a color Doppler ultrasound was used to obtain the BA waveform. During the first trimester ultrasound scan, at a slightly parasagittal and oblique plane, three main arteries can be demonstrated. Distal to the level of the maxilla, there are two main cerebral arteries – posteriorly, the BA and anteriorly, one of the ICAs. In proximal continuation of these two arteries, cranial to the level of the maxilla, ACA can be detected. The ICA runs vertically upwards towards the base of the skull and travels closer to the maxilla, whereas the BA rises up from the groove just in front of the pons and travels closer and perpendicular to the echogenic lines of the brainstem, running towards the back of the fetal head. Therefore, in a slightly oblique plane, distal to the level of the maxilla, both arteries-anteriorly, ICA and posteriorly, BA – can be visualized. However, for the Doppler analysis of BA, we have avoided this oblique plane, and obtained the correct midsagittal plane. Only the BA and a portion of the ACA were identified in the correct midsagittal plane, and a gate of pulse Doppler was placed just caudal to the anterior echogenic line of brainstem using a color Doppler ultrasound (Figure 1). Figure 2c shows the incorrect,

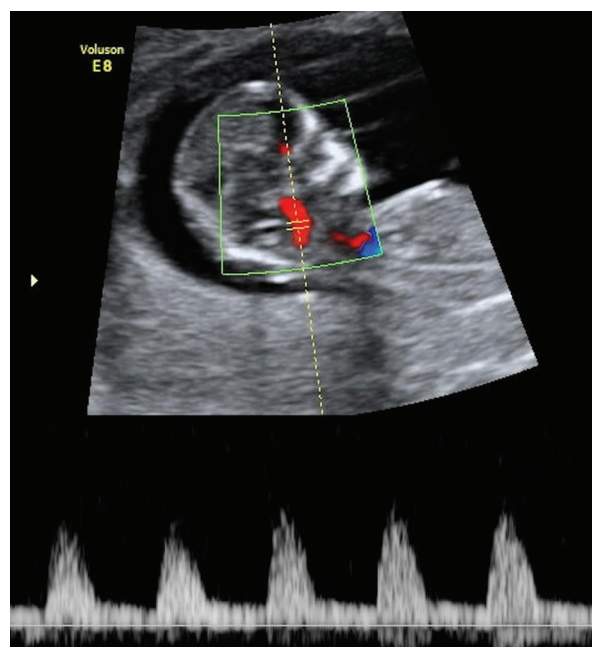


Figure 1: Transabdominal insonation of the basilar artery (BA) at the first trimester. The BA was identified along the sagittal plane anterior to the brainstem using color Doppler ultrasound.

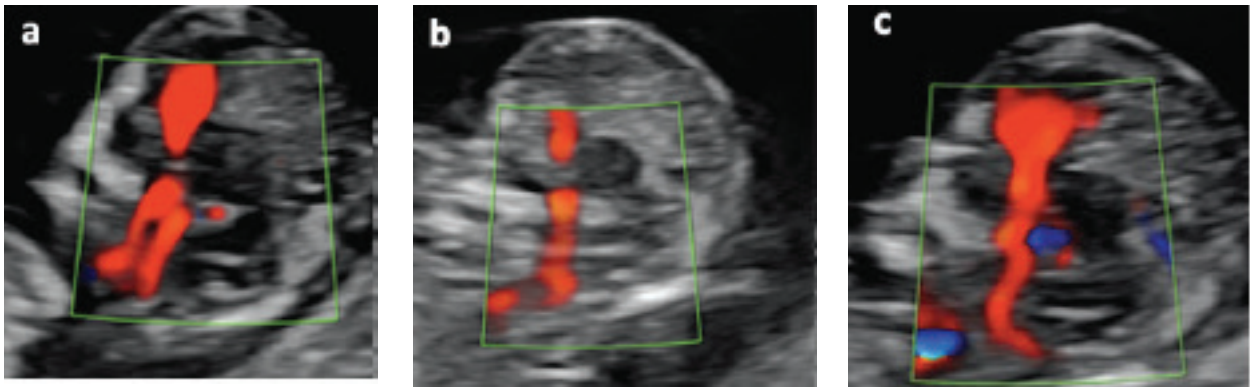


Figure 2: Approach to imaging of the basilar artery (BA) on color Doppler **a)** Incorrect plane; the internal carotid artery (ICA) is also seen in this plane anterior to the BA. Proximally, the anterior cerebral artery (ACA) is also seen, **b)** Suboptimal plane which shows the course of BA and a part of ACA. This plane is suboptimal because the borders of brainstem are not clear, **c)** The ideal plane which shows the BA, ACA, and the anterior and posterior borders of the brainstem. The BA was identified optimally in this correct midsagittal plane where ICA was not visualized. Measurements were obtained at the anterior line of the brainstem

suboptimal, and optimal planes to image the BA on a color Doppler ultrasound.

While measuring the BA PI and BA PSV, the insonation angle was kept between 0-30°. The pulse repetition frequency values were kept between 7 and 18 kHz. Mechanic and thermal indices below 1 were maintained, minimizing the examination time with color and the pulse wave Doppler to less than two minutes (15-17). All Doppler measurements were performed in the absence of fetal movements while the fetus was facing up, with the neck in neutral position, neither hyperextended nor hyperflexed. In order to calculate intraobserver repeatability, the measurements were performed two times in the first 50 consecutive fetuses.

The maternal characteristics as age (years), body mass index (BMI) (kg/m²), number of pregnancies, parity, gestational age (GA) at ultrasound examination, CRL, biparietal diameter (BPD), and nuchal translucency (NT) were expressed by mean±standard deviation (SD) and ranges. The intraobserver repeatability was expressed as the intraclass correlation coefficient (ICC). The sample size was calculated according to the study conducted by Bellera et al. for uniform gestational age distribution to produce a 90% confidence interval for the 95% BA PI or PSV reference limit, with a relative margin of error of 17% when compared with the 95% reference range (the alpha error was taken as 0.1 instead of 0.05) (18).

RESULTS

This study included 145 singleton pregnancies. BA waveforms were technically non-acceptable in five cases; and in two cases, fetal structural anomalies were detected during follow-up. One of these cases had agenesis of corpus callosum, the other case had a congenital diaphragmatic hernia; both of them went to termination of the pregnancy. Therefore, seven cases were

excluded and a total of 138 fetuses were included in the final analysis. The visualization and evaluation of the BA Doppler indices were available in 96.5% (140/145) of cases at the time of NT measurement. The distribution of pregnancies in each GA was as following: 11-11+6 weeks:44, 12-12+6 weeks:44, and 13-13+6 weeks:50.

The mean ± SD and ranges of age (years), BMI (kg/m²), number of pregnancies, parity, GA at ultrasound scan (weeks), CRL (mm), BPD (mm), and NT (mm) were: 31.67±4.98 (20-39), 24.18±3.45 (17.01 -35.12), 2±1 (1-8), 0.5±0.7 (0-3), 60.54±10.66 (45-81), 19.67±2.73 (15-25), and 1.51±0.46 (0.8-2.9), respectively. The average GA at delivery was 37.8±2.71 weeks and the average birth weight was (±SD) was 3076±550g. The BA PI and PSV varied significantly with gestational age, CRL, and biparietal diameter (p<0.05) (Table 1).

Linear regression analyses were the best fit curves as follows: BA PI measurement = 2.8-0.106×GA (weeks) (R²=0.274), and for BA PSV measurement=4.785+0.991×GA (weeks) (R²=0.205). The BA PI decreased significantly with GA, CRL, BPD, and NT (p<0.05), whereas the BA PSV was found to increase significantly with GA, CRL, BPD, and NT (p<0.05). Table 2 shows the 5th, 50th, and 95th percentiles for the BA PI and PSV measurements at each GA. Figure 3 shows the scatterplot for the BA PI measurement as a function of GA (weeks). Figure 4 shows the scatterplot for the BA PSV measurement as a function of GA (weeks). Figures 5 and 6 show the distribution of the percentiles of the BA PI and PSV values according to GA, respectively. The ICC for the BA PI and PSV measurements were 0.792 (95% CI=0.661-0.876; p<0.01) and 0.457 (95% CI=0.208-0.650; p<0.01), respectively. The intraobserver repeatability was found to be acceptable for BA PI and PSV measurements.

Table 1: Evaluation of the relationship between maternal age, crown-rump length (CRL in millimeters), biparietal diameter (BPD in millimeters), nuchal translucency (NT in millimeters) measurements, and fetal basilar artery pulsatility index (PI) and peak systolic velocity (PSV) measurements

	Basilar Artery PI		Basilar Artery PSV	
	r	p	r	p
Maternal age (years)	-0.053 ^a	0.537	0.087 ^a	0.312
Gestational age	-0.501 ^b	0.001**	0.409 ^b	0.001**
CRL (mm)	-0.498 ^b	0.001**	0.406 ^b	0.001**
BPD (mm)	-0.481 ^b	0.001**	0.398 ^b	0.001**

^a: Pearson correlation coefficient, ^b: Spearman's correlation coefficient, *p<0.05, **p<0.01

Table 2: Nomogram of the Basilar Artery (BA) pulsatility index (PI) and peak systolic velocity (PSV) values at the 5th, 50th, and 95th percentile for each gestational age

		Basilar Artery PI					
		n	Min-Max	Mean±SD	Per 5%	Per 50%	Per 95%
Gestational age (weeks+ days)	11-11 w 6 d	44	1.25-1.89	1.59±0.16	1.33	1.60	1.85
	12-12 w 6 d	44	1.17-1.79	1.48±0.16	1.24	1.47	1.77
	13-13 w 6 d	50	1.16-1.64	1.40±0.13	1.17	1.39	1.59
		Basilar Artery PSV					
		n	Min-Max	Mean±SD	Per 5%	Per 50%	Per 95%
Gestational age (weeks+ days)	11-11 w 6 d	44	13.20- 19.80	15.99±1.80	13.24	16.11	19.12
	12-12 w 6 d	44	13.96-20.44	17.1±1.57	15.00	17.43	20.10
	13-13 w 6 d	50	14.80-20.64	17.86±1.64	15.30	17.59	20.44

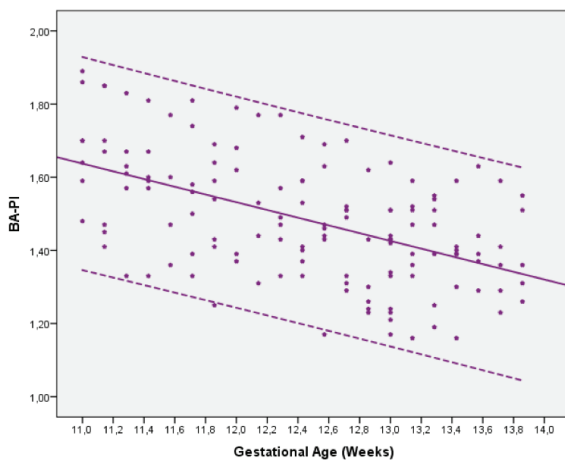


Figure 3: Reference values for the pulsatility index (PI) of basilar artery (BA) in first-trimester healthy fetuses (mean, 5th, and 95th percentiles)

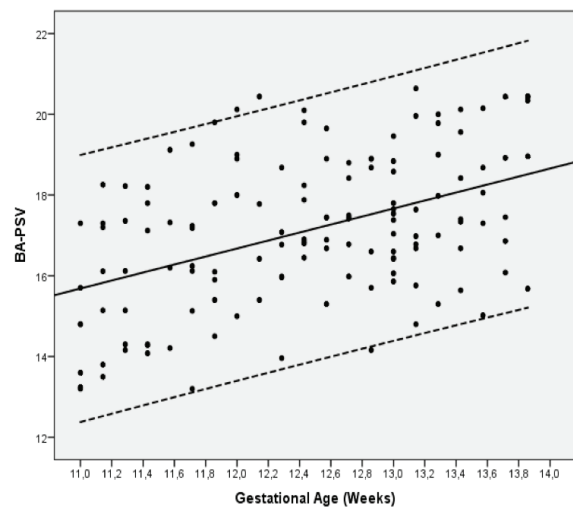


Figure 4: Reference values for the peak systolic velocity (PSV) of the basilar artery (BA) in first-trimester healthy fetuses (mean, 5th, and 95th percentiles)

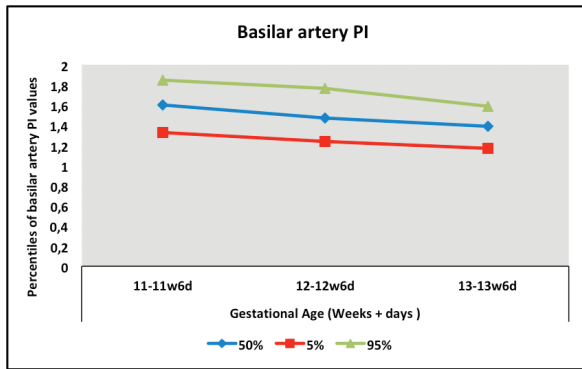


Figure 5: The distribution of the percentiles of the basilar artery (BA) pulsatility index (PI) values according to gestational age

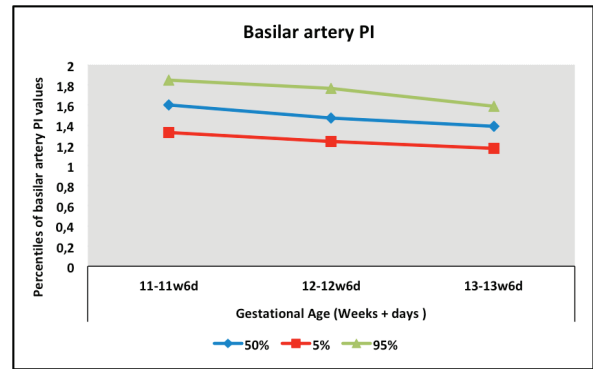


Figure 6: The distribution of the percentiles of basilar artery (BA) peak systolic velocity (PSV) values according to gestational age

DISCUSSION

Although the vertebrobasilar circulation is known to be developed by nine weeks of gestation, the literature regarding the posterior cerebral circulation is very limited, especially in the first trimester (19-20). In 1996, Pooh and Aono used a transvaginal approach to demonstrate the fetal brain by using power Doppler technique (19). Their study showed clear images of fetal vertebral arteries, the BA, and posterior cerebral arteries in the coronal plane at 12 weeks of gestation. In another study, Danon et al. evaluated fetal cerebral vasculature by using a high-definition Doppler with three-dimensional ultrasound volume data sets in 25 patients between 12.3 and 36.3 weeks of gestation (20). However, in this study, only two patients were evaluated in the first trimester, whereas the rest were in the second or third trimester. Although their study did not provide a detailed information about patients' characteristics in whom BA was identified, it was reported that the visualization rate of BA at midsagittal plane was approximately 88%. In the current study, the visualization and evaluation of the BA indices were feasible in 96.5% of cases, despite being in the first trimester. The mean value of maternal BMI in our study group was in the normal weight range (24.18 kg/m²), therefore we could not find any impact of maternal BMI on BA Doppler indices' measurement.

In the current study, we established the reference values for BA PI and PSV Doppler measurements between 11 and 13+6 weeks of gestation. It was found that the BA PSV increases as the weeks progressed. This finding is similar to the previous study conducted by Qureshi (21). They demonstrated the feasibility of visualizing and measuring the flow velocities of BA in 18 fetuses with a GA ranging from 19 weeks to 38 weeks and an increase in BA PSV according to GA. The fact that the study groups are quite small and heterogeneous, as well as the fact that they and cover the second and third trimesters, constitutes important differences from our study. However, the results of both studies indicate that the BA PSV appears to increase slightly within weeks of the first trimester

and continues to increase at a higher rate as pregnancy progresses.

It is known that MCA Doppler indices have a major effect on the early non-invasive assessment of fetuses at risk for fetal anemia after 15 weeks of gestation (22). An evaluation of the MCA Doppler indices should be obtained in the axial view of the fetal head and measured with an insonation angle close to zero in order to obtain 100% accuracy. It is also suggested that MCA PSV may accurately predict fetal anemia in the first half of the pregnancy (11-13). However, in the first trimester, it may be difficult to keep the angle close to zero technically, especially before 14 weeks of gestation. With the experience of the NT measurement, in the same sonographic plane, our findings support that BA Doppler evaluation appears to be easier and more practical compare to first-trimester MCA Doppler assessment. In addition, Tongsong et al. presented the distribution of MCA PSV measurement in the first half of pregnancy by weeks in their study (12). In this study, intraobserver variability was found to be 6.1% between 11-22 weeks of gestation, but it was not mentioned whether this result differed between the first trimester and early second trimester, nor how many of the patients were between 11-14 weeks. According to our results, the ICC for BA PI and PSV measurements were found to be 0.792 and 0.457, respectively, and their repeatability were found acceptable. We believe that BA Doppler evaluation may be an alternative method to discover fetal anemia before 14 weeks of gestation and needs further investigation to demonstrate its importance in terms of anemia prediction.

A small sample size and performance of BA Doppler indices' measurements by the same author are the main limitations' of the current study. Therefore, the interobserver variability and reproducibility were not assessed completely. The sample size was calculated relative to produce a 90% confidence interval (alpha error was taken as 0.1 instead of 0.05), as a pilot study was designed. Our study was designed in a prospective manner in a larger population compared to previous studies, which were involved BA insonation

in the first-trimester sonography (19-21). Nevertheless, the current results demonstrated an acceptable intraobserver repeatability for BA PI and PSV. The current study's design is clear and distinct compared to the methodologies of previous prenatal studies regarding the BA Doppler, where the evaluations are unclear.

In conclusion, the nomogram of the BA Doppler indices during first-trimester scanning was constructed in the current study. So far, this is the only study in which fetal BA Doppler evaluation and measurements on healthy fetuses were presented in first trimester sonography. These results should be confirmed with more studies. In addition, the reproducibility of the BA Doppler indices' at the first trimester to detect early fetal anemia should be established before using this method in clinical practice.

Ethics Committee Approval: This study was approved by Istanbul Faculty of Medicine Clinical Research Ethics Committee (Date: 21.10.2022, No: 19).

Peer Review: Externally peer-reviewed.

Author Contributions: Conception/Design of Study- T.S.S., İ.H.K.; Data Acquisition- İ.H.K., S.G.E, G.T., N.D.; Data Analysis/Interpretation- İ.H.K., R.H.; Drafting Manuscript- T.S.S., İ.H.K., S.G.E., G.T., N.D.; Critical Revision of Manuscript- İ.H.K., R.H.; Final Approval and Accountability- T.S.S., İ.H.K., R.H., S.G.E.; Material and Technical Support- G.T., N.D.; Supervision- İ.H.K., R.H.

Conflict of Interest: The authors have no conflict of interest to declare.

Financial Disclosure: The authors declared that this study has received no financial support.

REFERENCES

1. Figueroa-Diesel H, Hernández-Andrade E, Acosta-Rojas R, Cabero L, Gratacos E. Doppler changes in the main fetal brain arteries at different stages of hemodynamic adaptation in severe intrauterine growth restriction. *Ultrasound Obstet Gynecol* 2007;30(3):297-302.
2. Vollgraff Heidweiller-Schreurs CA, De Boer MA, Heymans MW, Schoonmade L, Bossuyt PMM, Mol BWJ, et al. Prognostic accuracy of cerebroplacental ratio and middle cerebral artery Doppler for adverse perinatal outcome: systematic review and meta-analysis. *Ultrasound Obstet Gynecol* 2018;51(3):313-22.
3. Baschat AA, Gembruch U, Reiss I, Gortner L, Weiner CP, Harman CR. Relationship between arterial and venous Doppler and perinatal outcome in fetal growth restriction. *Ultrasound Obstet Gynecol* 2000;16(5):407-13.
4. Prefumo F, Fichera A, Fratelli N, Sartori E. Fetal anemia: Diagnosis and management. *Best Pract Res Clin Obstet Gynaecol* 2019;58:2-14.
5. Abbasi N, Johnson JA, Ryan G. Fetal anemia. *Ultrasound Obstet Gynecol* 2017;50(2):145-53.
6. Dubiel M, Gunnarsson GO, Gudmundsson S. Blood redistribution in the fetal brain during chronic hypoxia. *Ultrasound Obstet Gynecol* 2002;20(2):117-21.
7. Kempe A, Rösing B, Berg C, Kamil D, Heep A, Gembruch U, et al. First-trimester treatment of fetal anemia secondary to parvovirus B19 infection. *Ultrasound Obstet Gynecol* 2007;29(2):226-8.
8. Benavides-Serralde JA, Hernández-Andrade E, Figueroa-Diesel H, Oros D, Feria LA, Scheier M, et al. Reference values for Doppler parameters of anterior cerebral artery throughout gestation. *Gynecol Obstet Invest* 2010;69(1):33-9.
9. Benavides-Serralde JA, Hernández-Andrade E, Cruz-Martinez R, Cruz-Lemini M, Scheier M, Figueras F, et al. Doppler evaluation of the posterior cerebral artery in normally grown and growth-restricted fetuses. *Prenat Diagn* 2014;34(2):115-20.
10. Ciobanu A, Wright A, Syngelaki A, Wright D, Akolekar R, Nicolaides KH. Fetal Medicine Foundation reference ranges for umbilical artery and middle cerebral artery pulsatility index and cerebroplacental ratio. *Ultrasound Obstet Gynecol* 2019;53(4):465-72.
11. Abu-Rustum RS, Ziade MF, Ghosn I, Helou N. Normogram of middle cerebral artery Doppler indexes and cerebroplacental ratio at 12 to 14 weeks in an unselected pregnancy population. *Am J Perinatol* 2019;36(2):155-60.
12. Tongsong T, Wanapirak C, Sirichotiyakul S, Tongprasert F, Srisupundit K. Middle cerebral artery peak systolic velocity of healthy fetuses in the first half of pregnancy. *J Ultrasound Med* 2007;26(8):1013-7.
13. Rujiwetpongstorn J, Phupong V. Doppler waveform indices of middle cerebral artery of normal fetuses in the first half of pregnancy in the Thai population. *Arch Gynecol Obstet* 2007;276(4):351-4.
14. Chaoui R, Benoit B, Mitkowska-Wozniak H, Heling KS, Nicolaides KH. Assessment of intracranial translucency (IT) in the detection of spina bifida at 11-13 week scan. *Ultrasound Obstet Gynecol* 2009;34(3):249-52.
15. Official Statement AIUM. As Low As Reasonably Achievable (ALARA) Principle. Approved 3/16/2008; Reapproved 4/2/2014. Available at: <http://www.aium.org/officialStatements/39>. Accessed June 5, 2018.
16. Official Statement AIUM. Statement on the Safe Use of Doppler Ultrasound During 11-14 week scans (or earlier in pregnancy). Approved 4/18/2011; Revised 3/21/2016, 10/30/2016. Available at: <http://www.aium.org/officialStatements/42>. Accessed June 5, 2018.
17. Salvesen K, Lees C, Abramowicz J, Brezinka C, Ter Haar G, Maršál K. ISUOG statement on the safe use of Doppler in the 11 to 13+6-week fetal ultrasound examination. *Ultrasound Obstet Gynecol* 2011;37(6):628.
18. Bellera CA, Hanley JA. A method is presented to plan the required sample size when estimating regression-based reference limits. *J Clin Epidemiol* 2007;60(6):610-5.
19. Pooh RK, Aono T. Transvaginal power Doppler angiography of the fetal brain. *Ultrasound Obstet Gynecol* 1996;8(6):417-21.
20. Danon E, Weisz B, Achiron R, Pretorius DH, Weissmann-Brenner A, Gindes L. Three-dimensional ultrasonographic depiction of fetal brain blood vessels. *Prenat Diagn* 2016;36(5):407-17.
21. Qureshi AI, Miran MS, Degenhardt J, Axt-Flidner R, Kohl T.

Transabdominal insonation of fetal basilar artery: a feasibility study. J Neuroimaging 2016;26(2):180-3.

22. Mari G, Adrignolo A, Abuhamad AZ, Pirhonen J, Jones DC,

Ludomirsky A, et al. Diagnosis of fetal anemia with Doppler ultrasound in the pregnancy complicated by maternal blood group immunization. Ultrasound Obstet Gynecol 1995;5(6):400-5.