



Cystic Echinococcosis in Children: Ten Years of Experience and Which Laboratory Results are Significant in the Evaluation of Ruptured Cases?

Çocuklarda Kistik Ekinokokkoz: On Yıllık Tecrübe ve Rüptüre Olguları Değerlendirmede Hangi Laboratuvar Sonuçları Önemlidir?

Hakan Salman¹, Zeliha Salman², Yeliz Kart³, Mustafa Akçam¹

¹ Suleyman Demirel University, School of Medicine, Department of Pediatrics, Division of Pediatric Gastroenterology, Hepatology and Nutrition, Isparta, Turkey

² Sanayi Family Health Center, Isparta, Turkey

³ Suleyman Demirel University, School of Medicine, Department of Pediatric Surgery, Isparta Turkey

Abstract

Aim: Hydatid disease (Echinococcosis) is a common zoonosis in countries that are involved in livestock such as our country. Our study aims to evaluate pediatric cases with hydatid disease over the last decade in our region and to determine the significance of initial clinical and laboratory findings in distinguishing ruptured hydatid cyst cases.

Material and Method: A retrospective analysis was made on demographic characteristics, presenting symptoms, physical examination, laboratory and radiological findings, and treatments of children with hydatid disease who were treated in our hospital and followed up regularly between January 2011 and December 2020.

Results: Of the 42 cases included in the study, 19 were female (45.2%) and the median age of cases was 125.5 (34-209) months. The most common symptom was abdominal pain (50%), and the most common physical examination finding was decreased breath sounds (23.8%). Thirty-five (83.3%) patients had single organ involvement and 7 (16.7%) patients had multiple organ involvement. Cysts were detected in the right lobe of the liver in 24 (75%) of hepatic hydatid cysts and the left lobe in 7 (58.3%) of pulmonary hydatid cysts. The median size of the cysts was 57.5 (12-140) mm. The initial IHA titer, eosinophil count, eosinophil percentage, and sedimentation value were statistically significantly higher in patients with ruptured cysts than in those without rupture ($p=0.002$, $p=0.003$, $p=0.003$, $p=0.02$, respectively).

Conclusion: Initial pathological examination findings and at initial laboratory findings such as high IHA titer, eosinophil count, eosinophil percentage, sedimentation value can be used to distinguish rupture cases.

Keywords: Cyst, echinococcus, liver, lung, pediatrics

Öz

Amaç: Kist hidatik hastalığı (Echinococcosis) Türkiye gibi hayvancılıkla uğraşan ülkelerde yaygın olan bir zoonozdur. Çalışmanın amacı bölgemizde son 10 yılda görülen çocuk kist hidatik olgularını değerlendirip, rüptüre kist hidatik olgularını ayırt etmede başlangıç klinik ve laboratuvar bulgularının önemini belirlemektir.

Gereç ve Yöntem: Ocak 2011-Aralık 2020 tarihleri arasında hastanemizde tedavi edilen ve düzenli olarak takiplere gelen kist hidatikli çocukların demografik özellikleri, başvuru şikayeti, fizik muayene, laboratuvar, radyolojik bulguları ve tedavileri geriye dönük incelendi.

Bulgular: Çalışmaya dahil edilen 42 olgunun 19'u kız (%45,2), ortanca yaşları 125,5 (34-209) aydı. En yaygın belirti %50 ile karın ağrısı, en yaygın fizik muayene bulgusu ise %23,8 ile solunum seslerinde azalmaydı. Hastaların 35'inde de (%83,3) tek organ, 7'sinde (%16,7) çoklu organ tutulumu vardı. Karaciğer kist hidatiklerinin 24'ünde (%75) kist karaciğerin sağ lobunda, akciğer kist hidatiklerinin ise 7'si (%58,3) sol lobunda tespit edildi. Kistlerin ortanca boyu 57,5 mm (12-140 mm) idi. Rüptüre kisti olan hastalarda başlangıç İHA titresi, eozinofil sayısı, eozinofil yüzdesi ve sedimantasyon değeri rüptür olmayan hastalara göre istatistiksel olarak anlamlı yüksekti (sırasıyla $p=0,002$, $p=0,003$, $p=0,003$, $p=0,02$).

Sonuç: İlk başvuruda patolojik muayene bulgusu ve yüksek İHA titresi, eozinofil sayısı, eozinofil yüzdesi ve sedimantasyon değeri rüptür olgularını ayırt etmek için kullanılabilir.

Anahtar Kelimeler: Akciğer, ekinokok, karaciğer, kist, pediatri,



INTRODUCTION

Hydatid disease is a zoonosis caused by the larvae of *Echinococcus*, a ~2–7 mm long tapeworm, which is common in countries engaged in agriculture and livestock.^[1] Dogs are the definitive host of the disease, while goats, sheep, camels, and cattle are intermediate hosts and humans are accidental hosts.^[2] Humans become infected by ingesting the eggs in contaminated food, water, and soil, or via contact with dogs. While it can occur in all age groups, it is often acquired in childhood in endemic regions.^[3] It is common in countries with poor preventive medicine. The endemic regions include the Middle East, South America, New Zealand, South Africa, Asia, China, and the Mediterranean countries such as Turkey. In endemic areas, the incidence of cystic echinococcosis are 50 per 100,000 person-years. Prevalence are 5-10% in Argentina, Peru, East Africa, Central Asia, and parts of China. Worldwide, there may be in excess of 1 million people living with these diseases at any one time. The 2015 WHO Foodborne Disease Burden Epidemiology Reference Group estimated echinococcosis to be the cause of 19 300 deaths and around 871 000 disability-adjusted life-years (DALYs) globally each year. The annual cost associated with echinococcosis in the livestock industry is estimated at US\$ 3 billion.^[4]

Clinical signs vary with the organ involved, the size of the cyst, and the interaction between the enlarged cyst and adjacent organs. Most of the cysts are asymptomatic and may regress spontaneously. The most commonly involved organ is the liver in adults and the lungs in children. Rarely, it can also affect such organs as the spleen, pancreas, heart, brain, kidney, muscles, and bones.^[5] The diagnosis is established by clinical signs, radiological imaging techniques, and serological tests. Treatment may be medical, surgical, or puncture-aspiration-injection-reaspiration (PAIR).^[6]

Our study aimed to evaluate the demographic characteristics, clinical symptoms, radiological images, laboratory findings, and treatment methods of children diagnosed with hydatid disease in our region. We aimed to determine the significance of initial clinical and laboratory findings in distinguishing ruptured hydatid cyst cases and to contribute to the literature.

MATERIAL AND METHOD

The medical records of patients with hydatid disease who were treated and followed up regularly at the Departments of Pediatrics and Pediatric Surgery of Suleyman Demirel University Faculty of Medicine between January 2011 and December 2020 were retrospectively reviewed. The study was carried out in the province of Isparta with a population of 445,678 located in the central Mediterranean region of Turkey.

Diagnosis

Hydatid disease was diagnosed by clinical, radiological, and serological tests. Demographic characteristics of the patients, presenting symptoms, initial physical examination and

radiological findings, initial laboratory values (echinococcal indirect hemagglutination (IHA), complete blood count, transaminase levels, sedimentation, C-reactive protein (CRP), and total Ig E), the localization, number and size (largest diameter) of the cyst, duration of treatment, duration of follow-up, medical treatment, PAIR and surgical method, complications, and post-treatment echinococcal IHA results were evaluated. Before the treatment, patients underwent chest radiography, abdominal ultrasonography (US), thoracic or cranial computerized tomography (CT), cranial magnetic resonance imaging, and echocardiography according to indications. In asymptomatic patients, hydatid disease was diagnosed incidentally after US or other radiological examinations for other reasons. *Echinococcus* IHA titers of $\geq 1/320$ were considered positive.

Treatment

All patients were administered albendazole 15 mg/kg/day (in two divided doses, maximum 800 mg/day) as medical treatment in cycles of 28 days with a drug-free interval of 14 days between the cycles. Medical treatment was administered by monitoring complete blood count and transaminase levels. Eligible patients with hepatic hydatid cysts were treated with the PAIR technique. This technique was performed under US guidance; the cystic content was aspirated first and then 20% hypertonic saline was injected into the cyst, followed by reaspiration. Patients ineligible for PAIR and with indications for surgery underwent surgical techniques (cystectomy, cystotomy and capitonnage). Patients scheduled for surgery were initiated on andazole treatment 1-4 weeks before the operation according to the World Health Organization's recommendations, and the treatment was continued for at least one more month after the operation.^[7]

Assessment

Response to treatment was evaluated together with clinical, radiological, and serological tests. Along with the improvement of clinical signs, complete disappearance of the cyst or reduction in size, the collapse of the cyst, calcification of the cyst, and progressive increase in the echogenicity and density of the cystic fluid were considered an improvement. The formation of new cysts in the same or another organ, recurrence of the cyst, and increase or no change in the size of the cyst were considered non-response to treatment.

Approval for the study was granted by the Local Ethics Committee for Research (decision no: 83, date: 10/03/2022). Written consent was obtained from the families for publication. The study protocol conforms to the ethical guidelines of the 1975 Declaration of Helsinki as reflected in a prior approval by the institution's human research committee

Statistical analysis

Statistical analysis was performed using the Statistical Package for the Social Sciences for Windows (SPSS) version 26.0 (SPSS Inc. Chicago, IL, USA). Continuous variables were expressed as median (range) and categorical variables

as frequency (percentage). The normality of continuous data was analyzed by the Kolmogorov-Smirnov test. The significance value was considered <0.05 . For non-parametric data, continuous variables were compared using the Chi-square and Mann-Whitney U tests. A p-value of <0.05 was considered statistically significant for all tests.

RESULTS

Epidemiological profiles

The study included 42 patients, who were treated for hydatid disease in our clinics, followed up regularly, and had accessible information. The patients consisted of 19 (45.2%) girls and 23 (54.8%) boys. The median age was 125.5 (min-max: 34-209) months. Of the patients, 61.9% presented between 2013 and 2016. Thirteen (33.3%) patients had a history of contact with dogs and 28 (66.7%) were living in rural areas.

Clinical features

At the time of first admission, 34 (81%) of the patients had complaints related to hydatid cyst and 22 (52.4%) had pathological findings on physical examination. Eight (19%) patients were asymptomatic and diagnosed incidentally during investigations for other reasons. Three of the eight patients had a history of trauma and were diagnosed by imaging requested for this purpose. The most common symptoms were abdominal pain in 21 (50%), fever in 9 (21.4%), and cough in 8 (19%). The most common presenting symptom was abdominal pain (63.8%) in patients with hepatic involvement and cough (58.3%) in those with pulmonary involvement. The most common physical examination findings were decreased breath sounds in 10 (23.8%), abdominal distention in 6 (14.3%), and hepatomegaly in 5 (11.9%). The presenting symptoms and physical examination findings of the patients are presented in **Tables 1** and **2**.

Table 1. Patients' complaints at presentation

Symptoms	n	%
Stomach ache	21	50
High fever	9	21.4
Cough	8	19
Vomiting	7	16.7
Shortness of breath	6	14.3
Anorexia	5	11.8
Weakness	4	9.5
Skin rash and pruritus	3	7.1
Chest pain	2	4.8
Jaundice	2	4.8
Spitting up salty liquid	1	2.4

Table 2. Physical examination findings of the patients

Results	n	%
Decreased breath sounds	10	23.8
Abdominal distention	6	14.3
Hepatomegaly	5	11.9
Urticaria	2	4.8
Icterus	2	4.8

Thirty-five (83.3%) patients had single organ involvement and 7 (16.7%) patients had multiple organ involvement. Of 35 cases with single organ involvement, the liver was involved in 26 (74.2%), the lungs in 7 (20%), and the spleen in 2 (5.7%) patients. Of 7 cases with multiple organ involvement, both the liver and lungs were involved in 4 (57.1%), both the liver and spleen in 2 (28.6%), and both the lungs and pancreas in 1. Concerning the localization of the cysts, 32 (76.2%) were in the liver, 12 (28.6%) were in the lung, 4 (9.5%) were in the spleen, and 1 (2.4%) was in the pancreas. Radiological imaging of a patient with pulmonary hydatid cysts is presented in **Figure 1**. Cysts were detected in the right lobe of the liver in 24 (75%), in the left lobe in 6 (18.8%), in both lobes in 2 (6.2%) of hepatic hydatid cysts, while the cysts were in the right lobe in 5 (41.7%) and the left lobe in 7 (58.3%) of pulmonary hydatid cysts.

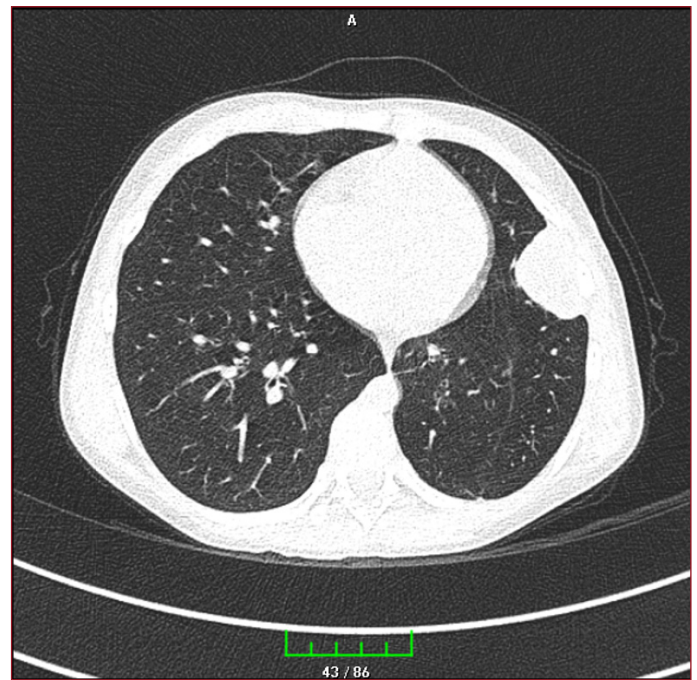


Figure 1. Radiological image of one patient. Tomography image of the cyst in the left lung periphery

The median size of overall cysts was 57.5 (min-max=12-140) mm. The cysts were small (≤ 50 mm) in 17 (40.5%) patients, 50-100 mm in 17 (40.5%) patients, and giant (>100 mm) in 8 (19%) patients. The mean cysts diameter was 57.09 ± 29.28 mm (12-120) in the liver and 72.16 ± 32.68 mm (23-140) in the lungs. Thirteen patients had multiple cysts in the same organ.

Laboratory findings

The echinococcus IHA was positive in 18 (42.9%) patients. The IHA was positive in 36.4% of hepatic hydatid cysts and 75% of pulmonary hydatid cysts. When the patients were classified according to the IHA results, the titer was 1/10240 in 4 (9.5%) patients, 1/5120 in 1 (2.4%) patient, 1/2560 in 2 (4.8%) patients, 1/1280 in 5 (11.9%) patients, 1/640 in 2 (4.8%) patients, and 1/320 in 5 (11.9%) patients. After the treatment,

echinococcus IHA titers were decreased in 9 (21.4%) patients and the results became negative in 4 (9.5%) patients. The median eosinophil count at diagnosis was $0.2 \times 10^9/L$ (0-3 10^9) and the median percentage was 3.15% (0-19.7). Ten (23.8%) patients had eosinophilia ($>0.5 \times 10^9/L$). The median leukocyte count was $7.9 \times 10^9/L$ (4.1-32.9 10^9), the median neutrophil count was $4.3 \times 10^9/L$ (1.5-31.6 10^9), and the median lymphocyte count was $2.25 \times 10^9/L$ (0.3-5.3 10^9).

Complications

When the patients were evaluated for hydatid cyst complications, there were 10 (23.8%) patients with complications and 8 (19%) with cyst rupture. The cysts were ruptured into the bronchus in five cases and into the biliary system in three cases. These three cases were followed up and treated with clinical signs of cholangitis. Pleural effusion was detected in 4 (9.5%) of the cases. The initial IHA titer, eosinophil count, eosinophil percentage, and sedimentation value were statistically significantly higher in patients with ruptured cysts than in those without rupture ($p=0.002$, $p=0.003$, $p=0.003$, $p=0.02$, respectively). Moreover, the initial physical examination findings were pathological at a statistically significantly higher rate in the rupture group than in the non-rupture group ($p=0.003$). There was no difference in age, gender, symptoms such as abdominal pain, cough, fever, and respiratory distress at diagnosis between the two groups. The comparison of patient characteristics is provided in **Table 3**.

	With rupture, n=8	Without rupture, n=34	P
Age (month)	148.62	117.64	0.091
Cyst size (mm)	83.12	59.67	0.069
IHA titer	4280	771.76	0.002
Leukocytes /L	11.87×10^9	9.28×10^9	0.251
Eosinophil/L	1.18×10^9	0.36×10^9	0.003
Eosinophil percent	10.67	4.09	0.003
ALT (IU/L)	38.74	23.23	0.339
AST (IU/L)	39.87	33.47	0.575
Neutrophil/L	7.46×10^9	5.72×10^9	0.432
Lymphocyte/L	2×10^9	2.48×10^9	0.356
CRP (nmol/L)	330.28	203.90	0.386
Sedimentation (mm/h)	45.42	20.1	0.020

Treatments

All patients received albendazole as medical treatment, 17 (40.5%) underwent surgical treatment, and 11 (26.2%) underwent PAIR. Sixteen (38.1%) patients received only albendazole treatment, nine (21.4%) patients both albendazole and PAIR, 15 patients both albendazole and surgery, and two (4.8%) patients received triple treatment with albendazole, PAIR, and surgery. Considering the treatment methods according to organ involvement, all patients with pulmonary hydatid cysts received both albendazole and surgical treatments. Of the patients with hepatic hydatid cysts, albendazole treatment alone was administered to 15

(46.9%), PAIR and albendazole treatment to 8 (25%), surgery and albendazole treatment to 7 (21.9%), and triple treatment to 2 (6.2%). One patient had elevated transaminase levels during the albendazole treatment, the transaminase elevation persisted at follow-up and the patient was diagnosed with autoimmune hepatitis based on tests and liver biopsy. In addition, one patient had transient transaminase elevation, which spontaneously regressed when albendazole treatment was discontinued. There were no other side effects related to albendazole treatment. After the treatment, the patients were evaluated by clinical and radiological examinations. There was no mortality. Recurrence of cysts occurred in 9 (21.4%) patients. The mean number of treatment cycles was 5.78 ± 2.03 (1-12) and the mean follow-up was 39.11 ± 21.55 (9-91) months.

DISCUSSION

Hydatid disease remains a serious health problem in Turkey, where livestock and agriculture are common sources of income. New echinococcal infections continue to occur throughout life. The prevalence of hepatic and pulmonary hydatid cysts increases with age. Despite the lack of definite data, the reported prevalence in Turkey is around 50 per 100000 and the incidence is around 2-6 per 100000.^[8] In our country, hydatid disease most frequently occurs in the Central Anatolia, Eastern Anatolia, and Southeastern Anatolia. A study from Uruguay reported the overall prevalence as 5.6%. The prevalence was shown to increase from 1% in patients aged 4-6 years to 11% in patients over 60 years of age.^[9] Living in rural areas ($p=0.003$), especially residing in rural areas for the first 5 years of life ($p=0.000$), always drinking water from natural sources ($p=0.007$), and living in the current address for more than 20 years were indicated as risk factors for the development of cystic echinococcosis.^[10]

According to the reports in the literature, hydatid cysts are more common in men (53.6-54.2%). This can be attributed to the behavioral characteristics of men, such as spending more time outdoors, and more contact with animals. In addition, the median age of children with hydatid disease was reported to range from 123 to 134 months.^[11-13] In a study, it was stated that children aged 7-11 years were most affected. Also, of the 94.4% children had single organ involvement and 5.6% had multiple organ involvement.^[14] In our study, male predominance was evident, which was consistent with the literature, and the median age was 125.5 months.

Since most cysts progress slowly, they can remain asymptomatic for years, usually until they reach 50 mm. Some cysts can also regress spontaneously. Abdominal pain was reported 28.6-55.4%, vomiting 15.3-25%, jaundice 2-5.3%, cough 39.3-50%, fever 35.7-42.9%, shortness of breath 14.2-17.9%, chest pain 10.7-28.6%, fatigue 15-17.9%, rock water vomiting 2-3.6%, and hemoptysis 7.1-14.3%. Due to the high elasticity of the lung parenchyma and weak immune response, children are asymptomatic and may be diagnosed late. Physical examination was reported to reveal decreased

breath sounds in 37.5%-39.3%, hepatomegaly in 7.1-8.9%, hepatosplenomegaly in 2-3.6%, and urticaria 2-3.6% of cases.^[12-15] In our study, the most common symptoms were abdominal pain in 50%, fever in 21.4%, and cough in 19%. The most common physical examination findings were decreased breath sounds in 23.8%, abdominal distention in 14.3%, and hepatomegaly in 11.9%.

Hydatid disease can affect any part of the body, more often the lungs and liver. Single organ involvement was reported in 67.8-90% of cases in previous studies.^[16,17] In our study, the rate of single organ involvement was 83.3%. Two studies from Greece and Turkey reported the rate of pulmonary involvement to be 51.3-54%,^[18,19] while another studies from Bulgaria and Turkey reported a rate of 51.4-71.5%.^[13,20] In our study, the rate of hepatic involvement was 76.2%. The most affected areas reported in children are the right lobe of the liver and the right lung.^[13,21] In a study evaluating the cases with multiple organ involvement, it was reported that the liver, lung and spleen (38.5%) were affected most frequently.^[22] In our study, the most involved areas were the right lobe of the liver (75%) and the left lung (58.3%). Cysts <50 mm in size are called small cysts and >100 mm are "giant cysts".^[23] In our study, 19% of the patients had giant cysts.

The IHA, a serological test, has low reliability because it cross-reacts with other parasitic infections, a negative serology test result does not rule out the diagnosis of hydatid disease, its positivity does not give a definitive diagnosis, but only supports it, and can remain positive even if many years pass since treatment.^[24] IHA test positivity in combination with abdominal ultrasonography is useful in diagnosing liver hydatid cyst, but thoracic CT is usually required to diagnose hydatid cyst of the lung.^[25] In our study, echinococcus IHA was positive in 42.9% of the children.

Eosinophilia was reported in 20-34% of hydatid cyst cases.^[13] Leukocyte and eosinophil counts were shown to be higher in cases with ruptured cysts.^[26] The study by Özyurtkan et al. found statistically significantly elevated sedimentation in rupture cases, while the elevation in leukocytes and eosinophils was insignificant.^[27] In our study, the initial IHA titer, eosinophil count, eosinophil percentage, and sedimentation value were statistically significantly higher in patients with ruptured cysts than in those without rupture. These findings suggest that the initial IHA titer, eosinophil count, eosinophil percentage, and sedimentation value are significant in evaluating ruptured cysts. Skin rashes, biliary peritonitis, and severe anaphylactic reaction may develop after hydatid cyst rupture. Since rupture of hydatid cysts has vital consequences, early diagnosis of rupture is important.

There is no standard choice of treatment for echinococcosis and treatment is planned on a patient basis. Treatment may vary with the patient's age, the localization, number, and structure of the cyst, and the presence of complications. Surgery is the main treatment for pulmonary hydatid cysts. In children, parenchyma-preserving surgery, such as cystotomy

and capitonnage, is more often preferred. In a study, it was concluded that cystotomy and capitonnage method reduced the occurrence of emphysema, pneumothorax, and the long-term retention of residual cavity statistically significantly compared to cystotomy method alone.^[28] Lobectomy and pneumonectomy cause loss of parenchyma and thus are recommended especially in endemic regions with a high risk of recurrence.^[29] It has been reported that benzimidazoles used in medical treatment are also effective in hydatid cysts with pulmonary involvement by softening the cysts, reducing the intracystic pressure, and allowing the removal of the cyst. These agents are not recommended in large cysts because they have a role in weakening the cyst wall and therefore increase the risk of cyst rupture.^[30,31]

The US-guided PAIR technique allows the treatment of simple and accessible cysts, especially in the liver. This technique is contraindicated for superficial, calcified cysts with biliary communication.^[32] In our study, all patients received albendazole as medical treatment, 40.5% underwent surgical treatment, and 26.2% underwent PAIR. Hydatid disease usually has a good prognosis in children. Depending on the location of the cyst and the treatment of choice, the recurrence rate varies between 8,8% and 25%.^[33,34] In our study, the rate of hydatid cyst recurrence was 21.4%. In a study, the frequency of cyst rupture was higher in the male sex ($p=0.023$), in those who complained of dyspnea ($p=0.001$) and in cases with rock water vomiting ($p=0.005$).^[34] In our study, 23.8% of the cases had complications and 19% had cyst rupture.

The limitations of our study are the single-center and retrospective design, and the lack of laboratory comparison because other serological methods used in the diagnosis were not examined.

CONCLUSION

Our study suggest that the presence of pathological examination findings, high initial IHA titer, high eosinophil count and eosinophil percentage, and high sedimentation value in children with hydatid disease are likely to indicate a ruptured cyst. We believe that it is important to pay attention to the abovementioned signs and to manage the patient. Periodic deworming of dogs with praziquantel (at least 4 times per year), improved hygiene in the slaughtering of livestock and public education campaigns are necessary for prevention of cyst hidatid.

ETHICAL DECLARATIONS

Ethics Committee Approval: The study was carried out with the permission of Süleyman Demirel University Local Ethics Committee (Date: 10/03/2002, Decision No: 83)

Informed Consent: Written consent was obtained from the families for publication.

Referee Evaluation Process: Externally peer-reviewed.

Conflict of Interest Statement: The authors have no conflicts of interest to declare.

Financial Disclosure: The authors declared that this study has received no financial support.

Author Contributions: All of the authors declare that they have all participated in the design, execution, and analysis of the paper, and that they have approved the final version.

REFERENCES

- Eckert J, Deplazes P. Biological, epidemiological, and clinical aspects of echinococcosis, a zoonosis of increasing concern. *Clin Microbiol Rev* 2004;17:107
- Petropoulos AS, Chatzoulis GA. Echinococcus granulosus in childhood: a retrospective study of 187 cases and newer data. *Clin Pediatr (Phila)* 2019;58:864-88
- Bhutani N, Kajal P. Hepatic echinococcosis: a review. *Ann Med Surg (Lond)* 2018;36:99-105
- World Health Organization. Echinococcosis. 17 May 2021 <http://www.who.int/echinococcosis/en/> (Accessed on April 1, 2022)
- Shams M, Khazaei S, Naserifar R, Shariatzadeh SA, Anvari D, Montazeri F, et al. Global distribution of Echinococcus granulosus genotypes in domestic and wild canids: a systematic review and meta-analysis. *Parasitology*. 2022;149(9):1147-59.
- Ben Brahim M, Nouri A, Ksia A et al. Management of multiple echinococcosis in childhood with albendazole and surgery. *J Pediatr Surg* 2008;43:2024-30
- Brunetti E, Kern P, Vuitton DA. Writing panel for the WHO-IWGE. Expert consensus for the diagnosis and treatment of cystic and alveolar echinococcosis in humans. *Acta Trop* 2010;114:1-16
- Uysal A, Gürüz Y, Köktürk O et al. Türk Toraks Derneği Paraziter Akciğer Hastalıkları Tanı ve Tedavi Uzlaşma Raporu. *Turkish Thoracic Journal* 2009;10;Suppl B (in Turkish)
- Cohen H, Paolillo E, Bonifacio R et al. Human cystic echinococcosis in a Uruguayan community: a sonographic, serologic, and epidemiologic study. *Am J Trop Med Hyg* 1998;59(4):620-7.
- Uchiumi L, Mujica G, Araya D, et al. Prevalence of human cystic echinococcosis in the towns of Ñorquinco and Ramos Mexia in Rio Negro Province, Argentina, and direct risk factors for infection. *Parasit Vectors* 2021;14(1):262.
- Aslanabadi S, Zarrintan S, Abdoli-Oskouei S et al. Hydatid cyst in children: a 10-year experience from Iran. *Afr J Paediatr Surg* 2013;10:140-4
- Aygün D, Yıldırım T, Başoğlu Öner Ö, Kuzdan Ö. Hydatid Disease in Childhood: A Single Center Experience. *J Pediatr Inf* 2020;14(2):80-86
- Tural-Kara T, Özdemir H, Karbuş A, Kocabaş BA. Clinical characteristics of childhood hydatid disease: a single tertiary centre experience from Turkey. *HK J Paediatr (new series)* 2018;23:162-8
- Amahmid O, El Guamri Y, Zenjari K, et al. The pattern of cystic echinococcosis in children in an endemic area in Morocco. *J Parasit Dis*. 2019;43(2):209-214.
- Dopchiz MC, Elissondo MC, Andresniuk MV et al. Pediatric hydatidosis in the south-east of the Buenos Aires province, Argentina. *Rev Argent Microbiol* 2009;41:105-1
- Bhutani N, Kajal P. Hepatic echinococcosis: a review. *Ann Med Surg (Lond)* 2018;36:99-105
- Escola-Verge L, Salvador F, Sanchez-Montalva A et al. Retrospective study of cystic echinococcosis in a recent cohort of a referral center for liver surgery. *J Gastrointest Surg* 2019;23:1148-56
- Petropoulos AS, Chatzoulis GA. Echinococcus granulosus in childhood: a retrospective study of 187 cases and newer data. *Clin Pediatr (Phila)* 2019;58:864-88
- Çakır D, Çelebi S, Gürpınar A, Ağın M, Bozdemir E. Evaluation of cases with hydatid diseases. *J Pediatr Inf* 2009;3:104-8
- Jordanova DP, Harizanov RN, Kaftandjiev IT, Rainova IG, Kantardjiev TV. Cystic echinococcosis in Bulgaria 1996-2013, with emphasis on childhood infections. *Eur J Clin Microbiol Infect Dis* 2015;34:1423-8
- Morar R, Feldman C. Pulmonary echinococcosis. *Eur Respir J* 2003;21:1069-77
- Çay Ü, Alabaz D, Gündeşlioglu Ö, Tutuş K, Çil M, Pehlivan UA. Multi-organ/disseminated echinococcosis in children: Case series and review of the literature. *J Paediatr Child Health* 2022;58(7):1193-200.
- Djuricic SM, Grebeldinger S, Kafka DI, Djan I, Vukadin M, Vasiljevic ZV. Cystic echinococcosis in children—the seventeen-year experience of two large medical centers in Serbia. *Parasitol Int* 2010;59:257-61
- Tamarozzi F, Silva R, Fittipaldo VA, Buonfrate D, Gottstein B, Siles-Lucas M. Serology for the diagnosis of human hepatic cystic echinococcosis and its relation with cyst staging: A systematic review of the literature with meta-analysis. *PLoS Negl Trop Dis*. 2021;15(4):e0009370.
- Kaman A, Tanır G, Çakmakçı E, Demir P, Öz FN, Teke TA, et al. Characteristics, diagnosis, and treatment modality of pediatric patients with cystic echinococcosis: a single centre experience. *Turk J Pediatr*. 2019;61(5):704-13.
- Sarkar M, Pathania R, Jhobda A, Thakur B, Chopra R. Cytic pulmonary hydatidosis. *Lung India* 2016;33:179-91
- Ozyurtkan MO, Balci AE. Surgical treatment of intrathoracic hydatid disease: a 5-year experience in an endemic region. *Surg Today* 2010;40(1):31-7.
- Ksia A, Fredj MB, Zouaoui A, Kechiche N, Belhassen S, Mosbahi S, et al. Capitonage seems better in childhood pulmonary hydatid cyst surgery. *J Pediatr Surg* 2020;55(4):752-5.
- Onal O, Demir OF. Is anatomic lung resection necessary in surgical treatment of giant lung hydatid cysts in childhood? *Ann Thorac Cardiovasc Surg* 2017;23:286-90
- Oral A, Yigiter M, Yildiz A, Yalcin O et al. Diagnosis and management of hydatid liver disease in children: a report of 156 patients with hydatid disease. *Journal of Pediatric Surgery* 2012;47:528-34
- Doğru D, Kiper N, Özçelik U, Yalçın E, Göçmen A. Medical treatment of pulmonary hydatid disease: for which child? *Parasitol Int* 2005;54:135-8
- Brunetti E, Junghanss T. Update on cystic hydatid disease. *Curr Opin Infect Dis* 2009;22:497-502
- Bozkurt B, Soran A, Karabeyoğlu M, Unal B, Coşkun F, Cengiz O. Follow-up problems and changes in obliteration of the residual cystic cavity after treatment for hepatic hydatidosis. *J Hepatobiliary Pancreat Surg* 2003;10:441-5
- Tüz AE, Ekemen Keleş Y, Şahin A, et al. Hydatid Disease in Children from Diagnosis to Treatment: A 10-year Single Center Experience. *Turkiye Parazitol Derg* 2022;46(3):189-94.