

# Analgesic efficacy and safety of epidural and paravertebral blocks in thoracotomy surgery

Tuğba Onur<sup>1</sup>, Asiye Demirel<sup>1</sup>, Anıl Onur<sup>1</sup>, Şeyda Efsun Özgünay<sup>1</sup>, Ümran Karaca<sup>1</sup>, Mesut Engin<sup>2</sup>

<sup>1</sup>Department of Anesthesiology and Reanimation, University of Health Sciences, Bursa Yüksek İhtisas Training and Research Hospital, Bursa, Turkey; <sup>2</sup>Department of Cardiovascular Surgery, University of Health Sciences, Bursa Yüksek İhtisas Training and Research Hospital, Bursa, Turkey

## ABSTRACT

**Objectives:** Epidural anesthesia, once considered a gold standard, has significant complications: hypotension, urinary retention, and catastrophic neurological damage in rare cases. While paravertebral analgesia can provide similar analgesic effectiveness to epidural analgesia, it is associated with fewer side effects. To compare the perioperative and postoperative effects of epidural (ED) and ultrasound-guided paravertebral block (PVB) applications in thoracotomy surgeries.

**Methods:** Fifty-two patients underwent elective thoracotomy; Group 1 (ED, n = 23) and Group 2 (PVB, n = 29) were evaluated. A comparison of hemodynamic parameters and complications preoperatively and postoperatively, postoperative analgesia requirements, visual analog scale (VAS) pain scores within 24 hours at specified times, the amount of analgesic used, the time to mobilize, the time to discharge, and the VAS values measured at three months was made.

**Results:** There was no difference between the study groups regarding demographic and ASA values, most comorbid chronic diseases, obesity, and smoking. The number of attempts, the postoperative 2<sup>nd</sup> hour VAS score, and the doses of paracetamol and tramadol used was significantly higher in Group 1 than in Group 2 ( $p = 0.002$ ,  $p = 0.002$ ,  $p = 0.012$ , and  $p = 0.022$ , respectively). There was no statistical difference between the groups in terms of postoperative 6, 12, 24 hours, and 3 months VAS scores, first mobilization and discharge, time to remove the thorax tube, intensive care (PACU) need, and perioperative and postoperative complications ( $p > 0.05$ ).

**Conclusions:** Ultrasound-guided PVB can be considered a safe and effective alternative to ED in thoracotomy surgery.

**Keywords:** Epidural block, paravertebral block, postoperative pain, chronic pain

Thoracotomy pain is one of the most severe complications associated with surgery. The pain is caused by damage to the pleura, muscles, intercostal nerves, and costovertebral joints. It can also result in

adverse outcomes such as respiratory complications, prolonged hospital stays, poor quality of life, and chronic pain syndrome [1]. Pain after thoracotomy may vary between 25% and 91%; it shows heterogene-

Received: December 12, 2022; Accepted: February 2, 2023; Published Online: February 21, 2023



e-ISSN: 2149-3189

**How to cite this article:** Onur T, Demirel A, Onur A, Özgünay ŞE, Karaca Ü, Engin M. Analgesic efficacy and safety of epidural and paravertebral blocks in thoracotomy surgery. Eur Res J 2023;9(2):391-397. DOI: 10.18621/eurj.1217756

**Address for correspondence:** Tuğba Onur, MD., University of Health Sciences, Bursa Yüksek İhtisas Training and Research Hospital, Department of Anesthesiology and Reanimation, Mimarşinan Mah., Emniyet Cad., 16310 Yıldırım, Bursa, Turkey. E-mail: doktor-t@hotmail.com, Phone: +90 224 295 50 00



©Copyright © 2023 by Prusa Medical Publishing  
Available at <http://dergipark.org.tr/eurj>

ity depending on the underlying pathophysiology, type of injury, pain classification methods, and clinical evaluation. Acute pain intensity is also associated with chronic pain [2].

A goal to minimize the complications that may accompany anesthesia and to prevent acute and chronic pain has led to the search for an ideal anesthetic method. For patients with postoperative pain, a multimodal approach combining systemic and regional anesthesia is most effective in enhancing analgesia [3]. Generally, thoracic epidural blocks (ED) are preferred as analgesia methods in thoracic surgery: it is usually considered the most appropriate pain management technique following cardiothoracic surgery. There is, however, a contraindication to its use in patients with coagulopathy. Additionally, it may cause some adverse effects, such as hypotension and nerve damage. The PVB, on the other hand, can prevent respiratory side effects (atelectasis, infection, pulmonary failure) and hypotension caused by respiratory muscle weakness [4].

With this study, we aimed to evaluate and compare the perioperative and postoperative effects of multimodal ED and ultrasound-guided PVB techniques in thoracotomy surgeries in our clinic.

## METHODS

A total of 52 thoracotomy surgery patients who underwent USG-guided PVB and EP were included. Permission of local ethics committee date and numbered 2011- KAEK-25 2022/10-06, and the written consent was obtained.

Inclusion criteria were unilateral elective pulmonary surgery, age  $\geq 16$ , and agreeing to cooperate with physicians for a postoperative analgesic regimen. Patients who did not agree to participate in the study, who were allergic to anesthetic drugs in the past, who currently have psychological problems, or who have a local infection at the surgery site were excluded. Patients were excluded from the analysis if they were on mechanical ventilator support 4 hours after the operation, need for reoperation and if pain scores could not be reached by phone after 3 months postoperatively (Fig. 1). The demographic characteristics (age, gender, body mass index [BMI], ASA values), comorbidities (Diabetes Mellitus [DM], Hypertension [HT], Chronic

obstructive lung disease [COPD], coronary artery disease [CAD], Obesity [BMI  $> 30$  kg/m<sup>2</sup>]), smoking were recorded. Patients were divided into two groups: those who underwent thoracic epidural catheterization before anesthesia (Group 1) and who underwent ultrasound-guided thoracic PVB in the surgically appropriate lateral position after induction of general anesthesia (Group 2).

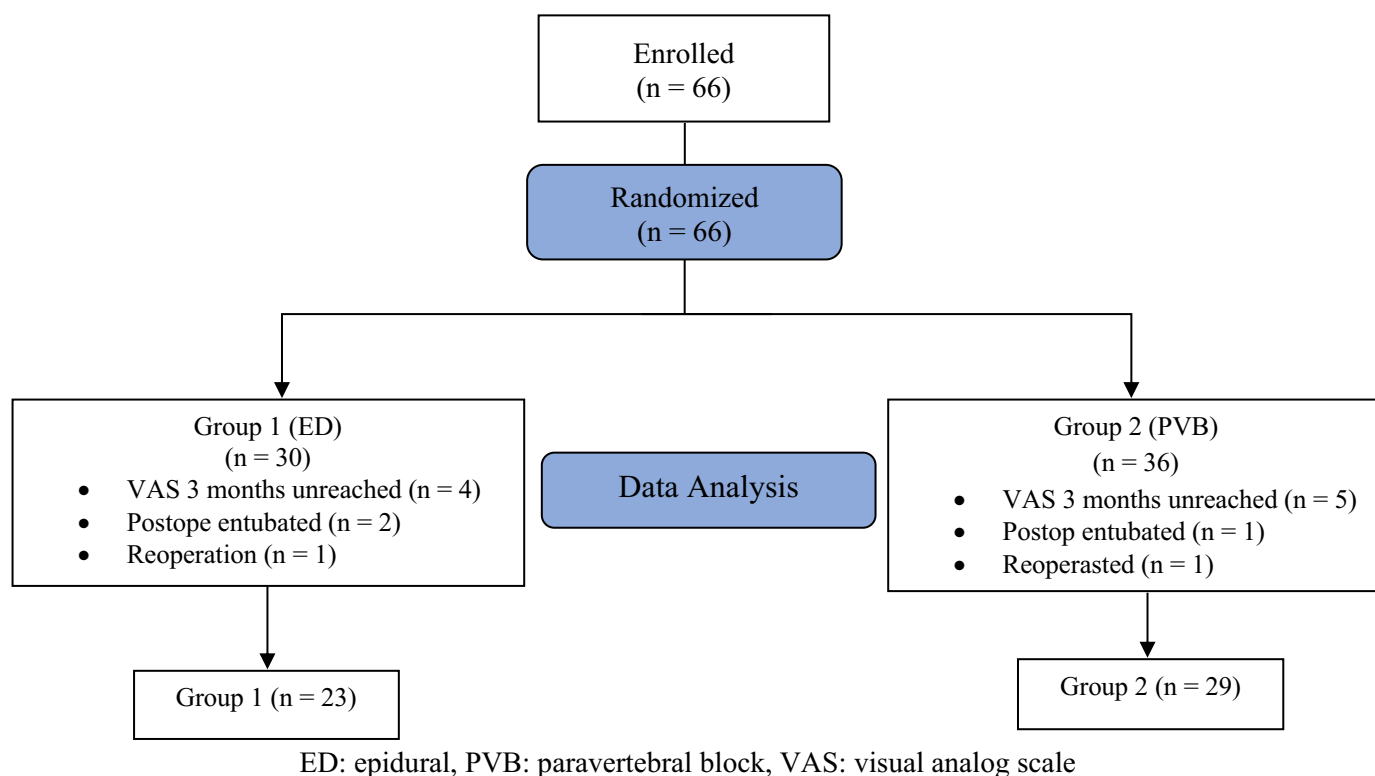
The number of attempts, hemodynamic data at preoperatively determined times, minor intraoperative complications (desaturation [SpO<sub>2</sub>  $< 90\%$ ], hypotension [20% decrease in MAP compared to baseline], hypertension, arrhythmia), and major complications (atelectasis, respiratory distress, bleeding) and postoperative complications, pain scores (between 0 and 10 points) recorded with Visual Analogue Scale (VAS) at postoperative 2, 6, 12, 24 hours, need for postoperative intensive care unit (PICU), first mobilization time and discharge times, used analgesic amounts were observed retrospectively from patient files. Three months after the operation, patients were contacted by phone to determine their VAS scores. Blind anesthesiologists made the blocks prospectively. Tramadol 1 mg/kg iv was given to patients with VAS  $> 4$  as routine rescue analgesia in the surgical service, and paracetamol 1 gr iv was given to patients with VAS  $> 2$ .

## Thoracic Epidural Block

Following routine monitoring, 2 mg midazolam was administered intravenously to patients, and 1 mL of 2% prilocaine was injected with a needle at the T5-6 vertebra level subcutaneously and in a sitting position. A Tuohy needle was used to enter the epidural space using either the hanging drop technique or the loss of resistance technique. The catheter was fixed at an appropriate level after aspiration. 8 mL of 0.5% bupivacaine was injected with 100  $\mu$ g of fentanyl and 10 cc of SF through a 15 mL catheter.

## Paravertebral Block

A high-frequency linear USG probe (5-13 MHz; GE Healthcare Logiq P5, USA) was placed longitudinally in the lateral decubitus position. At the level of T5-6 vertebrae, a transverse process (TP) and hyperechoic pleura were found 2-2.5 cm lateral to the spinous processes, and 1 mL of 2% prilocaine was injected into the subcutaneous tissue. We used a 22-gauge, 50 mm scale peripheral block needle (Stimuplex A<sup>®</sup>; B Braun,



**Fig. 1. Flow Chart of Procedure. ED = epidural, PVB = paravertebral block, VAS = visual analog scale**

Melsungen, Germany) to make all the blocks. The needle's plane technique advanced the selected paravertebral area by passing through the trapezius, rhomboids, erector spina muscles, and superior costotransverse ligament. A total of 15 mL of 0.5% bupivacaine, 5 mL of 2% lidocaine and 10 cc SF solution was injected bilaterally after negative aspiration. The parietal pleura shifted downward in each procedure.

**Primary and Secondary Outcomes**

Analgesic doses in 24 hours and VAS values at postoperative 24 hours and three months were the primary outcomes. Secondary outcomes included perioperative hemodynamics, side effects, complications, mobilization, thoracic tube removal, and intensive care requirement.

**Statistical Analysis**

Descriptive data are presented as numbers and percentages, and measurement data are presented as mean + standard deviation and median (minimum-maximum). The assumption of normal distribution was tested using the Shapiro-Wilk test and histograms. The Chi-square test was used to compare categorical

data. The Mann-Whitney U test was used to compare normally distributed measurements, and the Spearman Correlation test was used to correlate two variables. *P* < 0.05 was accepted as statistically significant. SPSS 20 was used for all analyses.

**RESULTS**

A comparison of 52 patients showed no statistically significant differences in age, ASA, DM, HT, COPD, obesity, or smoking. Group 2 had a statistically significant higher CAD rate than Group 1 (*p* = 0.048) (Table 1).

There were no statistically significant differences between the groups regarding MAP, HR, and SpO<sub>2</sub> at the measurement times determined during surgery (Table 2). Three patients in both groups experienced desaturation, responsive to increasing oxygen flow rate.

The number of interventions was higher in Group 1 (*p* = 0.002). Group 1 had significantly higher postoperative 2 hour VAS scores (*p* = 0.002) (Table 3). There was no statistical difference between the groups

**Table 1. The demographic data of the patients**

	Group 1 (n = 23)	Group 2 (n = 29)	<i>p</i> value
Gender (Female/male)	11/12	14/15	0.974
Age (years) (mean ± SD)	57.35 ± 7.36	60.29 ± 7.91	0.178
ASA II/III	18/5	18/11	0.209
HT, n (%)	12 (52.1)	12 (41.3)	0.438
DM, n (%)	9 (39.1)	12 (41.3)	0.870
CAD, n (%)	5 (21.7)	14 (48.2)	<b>0.048*</b>
Obesity, n (%)	2 (8.6)	6 (20.6)	0.234
Smoking, n (%)	12 (52.1)	12 (41.3)	0.438
COPD, n (%)	5 (21.7)	9 (31.03)	0.453

ASA = American Society of Anesthesiologists, HT = Hypertension, DM = Diabetes Mellitus, CAD = Coronary Artery Disease, COPD = Chronic Obstructive Pulmonary Disease, SD = standard deviation

*p* < 0.05, Mann-Whitney U test

regarding VAS 6, 12, 24 hours, and 3-month VAS scores.

There was no statistical difference between the groups regarding the first mobilization and discharge time, thorax tube removal time, and need in PICU (*p* > 0.05) (Table 3).

Postoperative paracetamol and tramadol doses were significantly higher in Group 1 (*p* = 0.012 and *p* = 0.022, respectively) (Table 3).

Correlation between VAS 24th hour and thoracic tube removal and discharge time showed no significant difference between the groups (*r*: 0.102, *p* = 0.473 and *r*: 0.097, *p* = 0.494, respectively).

A patient in Group 1 developed hypotension, and three patients in Group 2 suffered arrhythmia and hypertension as postoperative complications.

## DISCUSSION

In our study comparing ED with PVB for multimodal analgesia in thoracotomy surgeries, the postoperative second-hour VAS, the number of attempts, and paracetamol and tramadol doses were higher in the ED group. All other hemodynamic parameters, postoperative VAS values at 6, 12, 24 hours, and 3 months, initial mobilization, time to discharge, time to remove thoracic tubes, PICU need, and complications were similar between the groups.

As part of the multimodal approach to analgesia for thoracic surgery, regional techniques may reduce the likelihood of developing postoperative complications and chronic pain. The use of both ED and PVB in the management of thoracic surgery has been deemed appropriate in systematic reviews and meta-analyses over the past 20 years [5-7]. Evidence suggests that the effects of ED versus thoracic PVB for postoperative analgesia are comparable. PVB is associated with fewer side effects when used for unilateral or bilateral thoracic surgery and video-assisted thoracoscopy. Furthermore, there is evidence that thoracic PVB is an appropriate and safer alternative to thoracic epidural placement when anticoagulation is a contraindication [5]. Meta-analysis of 10 randomized studies comparing epidural and paravertebral block analgesia after thoracotomy demonstrated adequate and similar analgesia and pain scores [8]. Our study observed a similar relationship between analgesic effects and VAS scores, except for the postoperative 2<sup>nd</sup> hour VAS score. There is a possibility that this may be explained by the fact that the local anesthetic absorption from the epidural veins is higher in ED patients due to the central block, as well as the higher dose of paracetamol and tramadol used since the analgesic efficacy passes more quickly in these patients.

Both interventions are believed to affect hemodynamics during and after surgery based on their mechanisms of action. In meta-analyses comparing thoracic

**Table 2. Measurements of perioperative hemodynamics and saturation**

	Group 1	Group 2	p value
MAP1	88.13 ± 11.25	87.38 ± 11.91	0.818
MAP2	78.48 ± 7.74	76.48 ± 9.93	0.433
MAP3	70.65 ± 6.30	70.86 ± 7.48	0.915
MAP4	69 ± 5.02	68.72 ± 6.75	0.871
MAP5	67.09 ± 5.11	67.07 ± 5.15	0.990
MAP6	65.74 ± 4.63	66.66 ± 4.93	0.498
HR1	82.26 ± 10.45	81.24 ± 10.54	0.730
HR2	76.21 ± 7.82	75.68 ± 9.38	0.830
HR3	75.48 ± 6.59	74.83 ± 7.71	0.749
HR4	74.87 ± 7.40	74.03 ± 7.18	0.683
HR5	74.83 ± 6.90	73.86 ± 6.46	0.607
HR6	74 ± 6.57	73.55 ± 6.22	0.802
SPO2-1	95.17 ± 0.93	95.31 ± 0.92	0.603
SPO2-2	93.78 ± 1.75	92.82 ± 2.53	0.131
SPO2-3	88.21 ± 1.78	88.27 ± 2.71	0.929
SPO2-4	92.47 ± 2.06	92.37 ± 2.51	0.880
SPO2-5	94.52 ± 1.59	94.48 ± 2.27	0.945
SPO2-6	95.21 ± 0.95	95.06 ± 1.33	0.655

Data are shown as mean ± standard deviation. MAP = Mean Arterial Pressure, HR = Heart Rate, SpO<sub>2</sub> = Oxygen Saturation

**Table 3. Results of postoperative VAS scoring, number of interventions, hospital stay time, PICU requirements, and analgesia dosage**

	Group 1	Group 2	p value
VAS1 median (min-max)	2.82 (2-5)	2.13 (1-4)	<b>0.002*</b>
VAS2 median (min-max)	3.08 (1-6)	2.58 (1-4)	0.123
VAS3 median (min-max)	3.82 (2-6)	3.27 (2-6)	0.064
VAS4 median (min-max)	3.82 (3-6)	3.48 (2-5)	0.160
VAS5 median (min-max)	2.69 (1-5)	2.62 (1-4)	0.782
Attempt number (min-max)	1.73(1-3)	1.20(1-2)	<b>0.002*</b>
Mobilization time (h)	17.65 ± 3.60	16.79 ± 4.13	0.435
Discharge time (h)	97.73 ± 13.31	96.72 ± 16.53	0.812
TT withdrawal (h)	24.95 ± 7.74	24.72 ± 7.46	0.913
PACU, n (%)	9 (39.1)	11 (37.9)	0.930
Paracetamol dose (mg)	230.43 ± 76.48	186.20 ± 44.11	<b>0.012*</b>
Tramadol dose (mg)	134.78 ± 126.52	68.96 ± 71.23	<b>0.022*</b>

Data are shown as mean ± standard deviation or median (minimum-maximum) or n (%). VAS = Visual Analog Scale, VAS1 = Postoperative 2<sup>nd</sup> hour VAS, VAS2: Postoperative 6<sup>th</sup> hour VAS, VAS3: Postoperative 12<sup>th</sup> hour VAS, VAS4: Postoperative 24<sup>th</sup> hour VAS, VAS5: Postoperative 3<sup>rd</sup> month VAS, TT = Thorax tube, PACU = Postoperative anesthetic care unit

\*p < 0.05 Mann-Whitney U test

PVB and ED analgesia for pain relief after thoracotomy, short-term and transient hypotension was defined in the ED group [9, 10]. Since local anesthetics were administered unilaterally close to the somatic roots, the paravertebral block was found to have a lower incidence of hypotension. Paravertebral anesthesia has a minor effect on blood pressure and heart rate, making it safe for patients with cardiovascular comorbidities. Furthermore, the paravertebral block provides greater perioperative hemodynamic stability, requiring a smaller amount of intravenous colloid and less vasopressor than the ED [11, 12]. A similar hemodynamic profile was observed between the groups during the surgery in our study. However, PVB was preferred, especially in patients with coronary artery disease with an expected risk of hemodynamic instability and hypotension, resulting in heterogeneity in the comparison of groups.

In recent years, enhanced recovery after surgery (ERAS) has also gained popularity in thoracic surgery. The ERAS protocol is designed to provide an immediate termination. It aims to reduce complications by using less invasive surgical techniques and providing effective analgesia [13, 14]. Likewise, the chest tube facilitates rapid recovery following thoracic surgery. Many studies have focused on the postoperative chest tube approach in thoracic surgery [15]. According to these studies, long-term chest tube use can prolong hospital stays and increase complications. The timing of chest tube removal is under debate, but commonly it is decided based on volume plus exit thresholds. According to some surgeons, higher daily volume outputs (450-500 cc) are acceptable thresholds for removing chest tubes [16]. In most cases, patients are discharged the same day after chest tube removal. However, some may need to remain in the hospital for longer.

Furthermore, chronic co-morbidities, obesity, and smoking history contribute to chest tube lengthening. Shortening the discharge time by early removing the chest tube; it may be an appropriate approach to a center-based situation [15]. Operation time, pain scores, and postoperative respiratory movements were evaluated as factors affecting chest tube withdrawal time and discharge time. Our study found no significant difference in groups between 24<sup>th</sup> hour VAS scores and the time of discharge or removal of thoracic tubes. Low VAS scores in the postoperative period indicate

that effective analgesia was provided. The complications caused by pain were reduced since almost all patients received effective analgesia. In our study length of hospital stay after thoracic tube removal exceeded 24 hours, which we attribute to clinic procedures rather than complications.

In a study comparing PVB and ED in thoracotomy cases, including upper gastrointestinal surgery, PVB showed a lower risk of minor complications. Perioperative complications were similar between the two groups in our study. Three patients in both groups experienced desaturation during one-lung ventilation responsive to an increase in oxygen flow rate. PVB was as effective as thoracic ED for the control of acute pain. There was no difference in 30-day mortality, major complications, or length of hospital stay [1, 17]. Similarly, in our study, there were no differences in postoperative complications or length of hospital stay between the groups.

ICD-11 defines post-surgical chronic pain as pain that persists beyond the healing process, at least 3 months after surgery or a tissue injury [18]. Chronic pain can develop following any surgery but is more likely to occur following an amputation, thoracotomy, or mastectomy. A low-quality evidence study suggests that preventive epidural analgesia before thoracotomy incision reduces acute pain intensity and chronic pain incidence after thoracotomy [7]. In the present study, postoperative VAS values in the 3rd month postoperatively were similar between the two groups and compatible with acute pain scores.

## CONCLUSION

Our study demonstrated that both block applications were sufficient and adequate for postoperative analgesia in thoracotomy patients, did not impair perioperative hemodynamics, and had low complications. We consider ultrasound-guided PVB a safe, effective alternative to ED for managing acute and chronic pain in thoracotomy procedures.

### *Authors' Contribution*

Study Conception: TO, AO; Study Design: TO; Supervision: ŞEÖ; Funding: ŞEÖ; Materials: AD, ŞEÖ; Data Collection and/or Processing: AO, TO; Sta-

tistical Analysis and/or Data Interpretation: AO, ME; Literature Review: AD, ÜK; Manuscript Preparation: TO, ÜK and Critical Review: ÜK, ME.

### Conflict of interest

The authors disclosed no conflict of interest during the preparation or publication of this manuscript.

### Financing

The authors disclosed that they did not receive any grant during conduction or writing of this study.

## REFERENCES

1. Yeung JH, Gates S, Naidu BV, Wilson MJ, Smith FG. Paravertebral block versus thoracic epidural for patients undergoing thoracotomy. *Cochrane Database Syst Rev* 2016;2:CD009121.
2. Arends S, Böhmer AB, Poels M, Schieren M, Koryllos A, Wappler F, et al. Post-thoracotomy pain syndrome: seldom severe, often neuropathic, treated unspecific, and insufficient. *Pain Rep* 2020;5:e810.
3. Marshall K, McLaughlin K. Pain management in thoracic surgery. *Thorac Surg Clin* 2020; 30:339-46.
4. Scarci M, Joshi A, Attia R. In patients undergoing thoracic surgery is paravertebral block as effective as epidural analgesia for pain management? *Interact Cardiovasc Thorac Surg* 2010; 10:92-6.
5. D'Ercole F, Arora H, Kumar PA. Paravertebral block for thoracic surgery. *J Cardiothorac Vasc Anesth* 2018;32:915-27.
6. Feray S, Lubach J, Joshi GP, Bonnet F, Van de Velde M;PROSPECT Working Group \*of the European Society of Regional Anaesthesia and Pain Therapy. PROSPECT guidelines for video-assisted thoracoscopic surgery: a systematic review and procedure-specific postoperative pain management recommendations. *Anaesthesia* 2022;77:311-25.
7. Park SK, Yoon S, Kim BR, Choe SH, Bahk JH, Seo JH. Pre-emptive epidural analgesia for acute and chronic post-thoracotomy pain in adults: a systematic review and meta-analysis. *Reg Anesth Pain Med* 2020;45:1006-16.
8. Davies RG, PS Myles, Graham J. A comparison of the analgesic efficacy and side-effects of paravertebral vs epidural blockade for thoracotomy -- a systematic review and meta-analysis of randomized trials. *BJA: Br J Anaesth* 2006;96:418-26.
9. Mohta M, Ophrii EL, Sethi AK, Agarwal D, Jain BK. Continuous paravertebral infusion of ropivacaine with or without fentanyl for pain relief in unilateral multiple fractured ribs. *Indian J Anaesth* 2013;57:555-61.
10. Grider JS, Mullet TW, Saha SP, Harned ME, Sloan PA. A randomized, double-blind trial comparing continuous thoracic epidural bupivacaine with and without opioid in contrast to a continuous paravertebral infusion of bupivacaine for post-thoracotomy pain. *J Cardiothorac Vasc Anesth* 2012;26:83-9.
11. Baidya DK, Khanna P, Maitra S. Analgesic efficacy and safety of thoracic paravertebral and epidural analgesia for thoracic surgery: a systematic review and meta-analysis. *Interact Cardiovasc Thorac Surg* 2014;18:626-35.
12. Ng A Swanevelder J. Pain relief after thoracotomy: is epidural analgesia the optimal technique? *Br J Anaesth* 2007;98:159-62.
13. Markham T, Wegner R, Hernandez N, Lee JW, Choi W, Eltzschig HK, et al. Assessment of a multimodal analgesia protocol to allow the implementation of enhanced recovery after cardiac surgery: retrospective analysis of patient outcomes. *J Clin Anesth* 2019;54:76-80.
14. Batchelor TJ, Rasburn NJ, Abdelnour-Berchtold E, Brunelli A, Cerfolio RJ, Gonzalez M, et al. Guidelines for enhanced recovery after lung surgery: recommendations of the Enhanced Recovery After Surgery (ERAS®) Society and the European Society of Thoracic Surgeons (ESTS). *Eur J Cardiothorac Surg* 2019;55:91-115.
15. Asban A, Xie R, Abraham P, Kirklin JK, Donahue J, Wei B. Reasons for extended length of stay following chest tube removal in general thoracic surgical patients. *J Thorac Dis* 2020; 12:5700-8.
16. Cerfolio RJ, Bryant AS, Skylizard L and Minnich DJ. Optimal technique for the removal of chest tubes after pulmonary resection. *J Thorac Cardiovasc Surg* 2013;145:1535-9.
17. Terkawi AS, Tsang S, Sessler DI, Terkawi RS, Nunemaker MS, Durieux ME, et al. Improving analgesic efficacy and safety of thoracic paravertebral block for breast surgery: a mixed-effects meta-analysis. *Pain Physician* 2015;18:E757-80.
18. Scholz J, Finnerup NB, Attal N, Aziz Q, Baron R, Bennett MI, et al. The IASP classification of chronic pain for ICD-11: chronic neuropathic pain. *Pain* 2019;160:53-9.



This is an open access article distributed under the terms of [Creative Commons Attribution-NonCommercial-NoDerivatives 4.0 International License](https://creativecommons.org/licenses/by-nc-nd/4.0/).