

A Rare Cause of Facial Nerve Paralysis: Hemangioma Located in the Tympanic Portion of the Facial Nerve

Deniz Baklaci¹ , Mustafa Dalgıç¹ , Filiz Kutlu² , Banu Alicioğlu³ 

¹Bülent Ecevit University, Faculty of Medicine, Department of Otolaryngology, Zonguldak, Türkiye

²Bülent Ecevit University, Faculty of Medicine, Department of Pathology, Zonguldak, Türkiye

³Bülent Ecevit University, Faculty of Medicine, Department of Radiology, Zonguldak, Türkiye

ORCID ID: D.B. 0000-0001-8449-4965; M.D. 0000-0003-1886-8994; F.K. 0000-0003-1743-457X; B.A. 0000-0002-6334-7445

Citation: Baklaci D, Dalgic M, Kutlu F, Alicioglu B. A rare cause of facial nerve paralysis: Hemangioma located in the tympanic portion of the facial nerve. Tr-ENT 2023;33(1):19-22. <https://doi.org/10.26650/Tr-ENT.2023.1227009>

ABSTRACT

Facial nerve hemangiomas are rare tumors and benign lesions. These tumors may involve all segments of the facial nerve. The most common location of these tumors are geniculate fossa of the facial nerve. The tympanic portion of the facial nerve is rarely involved. To our knowledge, two cases are reported in the literature. These tumors may cause symptoms due to the compression of adjacent structures, such as facial nerve paralysis and hearing loss. Computed tomography imaging and magnetic resonance imaging are useful tools for diagnosis and viewing the extent of the tumor. Surgical excision is the primary treatment for these tumors. In this study, we report the third case of facial nerve hemangioma located in the tympanic portion of the facial nerve in the literature. The tumor was located in the tympanic segment and presented with total facial nerve paralysis.

Keywords: Facial nerve, hemangioma, tumor

INTRODUCTION

Facial nerve (FN) tumors are uncommon tumors. Facial nerve hemangiomas (FNH) are rare entities and benign lesions. These tumors have a slow growth pattern and account for 18% of all facial nerve tumors (1). FNH may involve all segments of the facial nerve. Pulec reported the first case of hemangioma involving geniculate ganglion of the facial nerve (2). FNH stem from the venous plexus around the FN and not from the FN itself. The term 'hemangioma' is commonly accepted to describe these tumors, but there are clinical findings suggesting that they are vascular malformations and not vascular tumors. The most common location of the FNH is the geniculate fossa. Other location sites are internal auditory canal (IAC) and the second genu of the facial nerve (1). They may cause symptoms due to the compression of adjacent structures, such as facial nerve paralysis and hearing loss. First line treatment for these tumors is surgical excision, and the type and extent of surgery is related to tumor location, tumor site, and preoperative hearing level (2).

In this study, we report the third case of FNH in the literature. The tumor was located in the tympanic segment and presented with total facial nerve paralysis.

CASE REPORT

A 61-year-old patient presented to the Zonguldak Bulent Ecevit University Department of Otolaryngology clinic with progressive left facial weakness during the previous six-month history and a one-month history of left total facial paralysis (House-Brackmann grading score VI). Steroid therapy had been given previously, and the patient was referred to our clinic for further investigation due to progressive facial nerve paralysis despite steroid therapy. He had no hearing changes, tinnitus, or vertigo. An otoscopy showed intact and normal tympanic membranes. Audiometry revealed normal hearing. A physical examination revealed total left facial paralysis with no muscle movement.

Computed tomography (CT) showed a round-shaped soft-tissue density lesion in the middle ear, close to the mastoid portion of

Corresponding Author: Mustafa Dalgıç E-mail: dalgic_816@hotmail.com

Submitted: 30.12.2022 • **Revision Requested:** 03.01.2023 • **Last Revision Received:** 06.01.2023 • **Accepted:** 17.03.2023 • **Published Online:** 29.03.2023



This work is licensed under Creative Commons Attribution-NonCommercial 4.0 International License.

the FN (Figure 1). With magnetic resonance imaging (MRI), an expansive lesion with irregular contours, involving the tympanic segment of the left facial nerve and posteriorly, in its transition to the mastoid segment, was noted. Slight enhancement of contrast agent was suggestive of facial nerve schwannoma (Figure 2). Facial electromyography revealed severe total axonal degeneration findings in the facial nerve. Surgery was planned for the patient. Posterior tympanotomy with the left retroauricular transmastoid approach was performed. The tumor was located in the tympanic portion extending between the geniculate ganglion and the second genu of the FN. The incus was removed to provide more exposure. Once the tumor was reached, it is noted that the tumor was interspersed with the FN; therefore, it was impossible to dissect the tumor from the FN. To provide complete tumor excision, we decided to perform the segmental excision of the FN including the lesion, as well as end-to-end interposition grafting with the left greater auricular nerve. The lesion was excised with the facial nerve tympanic segment and second genu. Then, the greater auricular nerve graft material was placed between the two ends of the tympanic portion of the facial nerve, and fibrine glue was applied to stabilize the grafting material in place. The incus was replaced between the malleus and stapes and stabilized with bone cement. Lastly, left lateral tarsorrhaphy was performed in order to minimize orbital complaints. For histologic

examination, hematoxylin-eosin staining was performed, and it revealed vascular structures with a single layer endothelium on surface with loose connective tissue (Figure 3). The diagnosis was made as FNH. There was no change in the facial function of the patient, and no tumor recurrence was observed during the six-months follow-up period.

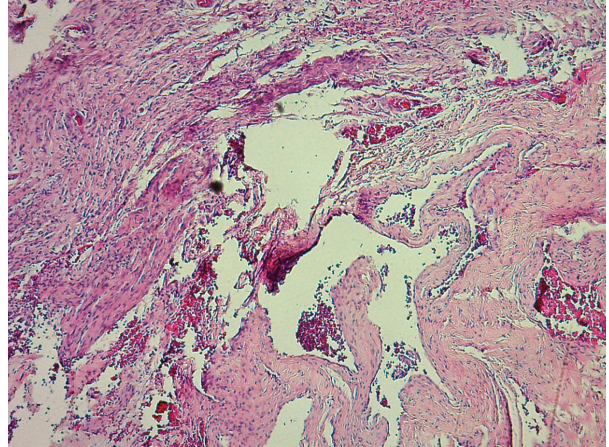


Figure 3: Hematoxylin-eosin staining revealed multiple vascular structures with a single layer endothelium on surface with loose connective tissue.

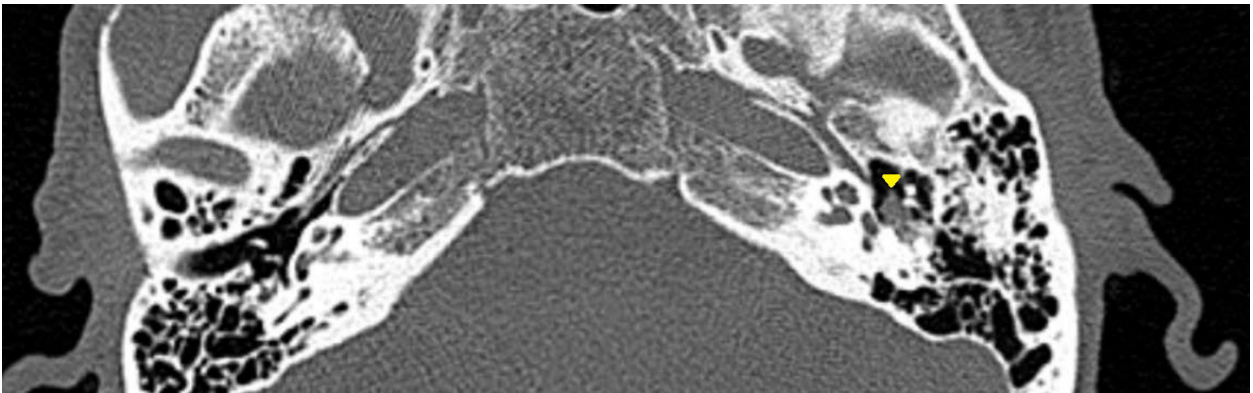


Figure 1: CT of the patient with hemangioma of the tympanic segment. Note the soft tissue attenuated mass centered in the tympanic segment of the facial canal.

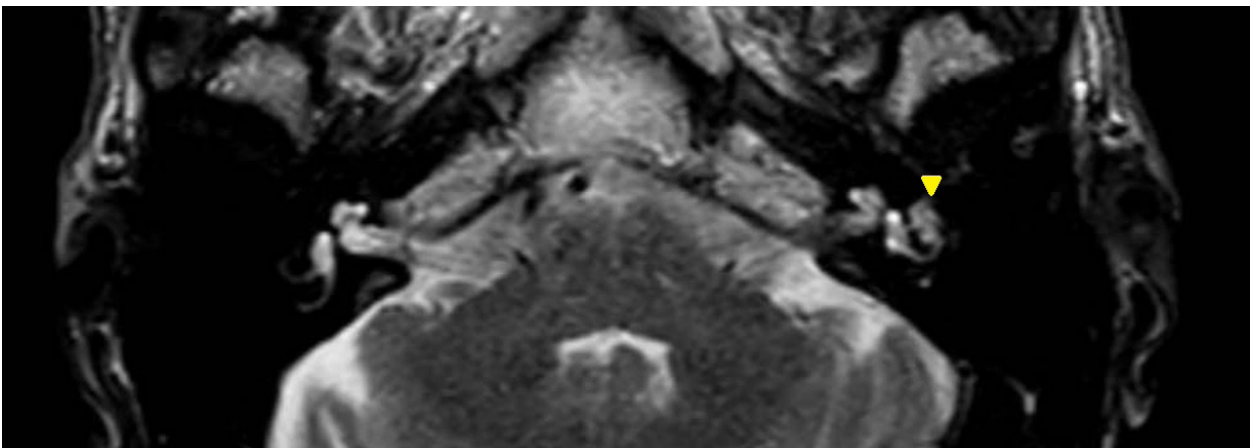


Figure 2: Axial T2-weighted image demonstrating an ill-defined mass lesion in the left tympanic cavity.

DISCUSSION

FNH are benign lesions but their underlying pathogenesis is unclear. They most commonly involve the geniculate ganglion of the FN (3). Also, the underlying mechanism for the reason of hemangioma preference for the geniculate ganglion is not completely understood. Balkany et al. suggested in their study that the presence of high perineural capillary density in the geniculate portion of the FN in comparison with its other segments may be the reason for tendency of FNH (3). In our knowledge, four cases of FNH involving the mastoid segment of the FN are reported in the literature. Hopkins et al., Piccirillo et al and Eby et al. reported a total of four patients with facial nerve hemangiomas involving the mastoid segment of the facial nerve (4-6). The hemangiomas involved in the tympanic portion of the facial nerve are relatively uncommon, with only a few cases having been reported in the literature. Friedman et al. reported in their study that two cases of hemangioma involved geniculate ganglion and tympanic portions of the FN (7). Saliba and Fayad reported in their study a facial nerve hemangioma case located in the second genu of the FN (8). Santos et al. reported the second case in the literature of FNH involving the tympanic portion of the FN. To our knowledge, this is the third FNH located in the tympanic portion of the FN in the literature (9).

Facial nerve hemangiomas may compress or invade adjacent structures and may cause severe symptoms (10). Some possible symptoms in patients with facial nerve hemangioma are recurrent or persistent unilateral facial paralysis, tinnitus, and ear fullness. Occasionally, hemangioma involves the IAC and unilateral sensorineural hearing loss or vertigo may also occur (11). The clinical presentation of patients with tympanic portion facial nerve hemangiomas has not yet been well described because this condition is rare (11). In our case, the patient had left grade 6 facial nerve paralysis, and an audiometry test revealed normal hearing.

Diagnosis of the FNH is based on imaging. In a CT scan, hemangioma may contain calcified intra-tumoral spicules resembling honeycomb may be noticed. A tumor may also cause the irregular expansion of the surrounding bone. Hemangiomas are hypointense on T1-weighted MRI and hyperintense on T2-weighted images, and they show contrast enhancement with gadolinium (11,12). Differentiation of the other facial nerve tumors in the same region, such as schwannomas, tend to have a similar appearance in imaging. Although considered pathognomonic, the honeycomb appearance of facial nerve hemangiomas in a CT scan is present in approximately 50% of cases, and unfortunately, this pattern may not be reliable (13). In the absence of this finding, differential diagnosis from schwannomas or other rarer facial nerve neoplasms, such as meningioma, may be difficult (14).

The first line treatment for FNH is surgical excision, but FNH in the tympanic segment of the FN are very rare vascular tumors, and therefore there is no consensus on their management (2). Propranolol, surgical excision, and close follow ups are

possible treatment options for hemangiomas in the tympanic portion of the FN. For patients with normal facial function, close follow ups without excision may be appropriate (15). The type and extent of surgical approach depends on tumor location, tumor size, and preoperative hearing level. Since the tumor is extraneural, it is possible to remove it while preserving the FN in some cases. However, in some cases, it is not possible to preserve the FN because of direct nerve infiltration.

Small hemangiomas result in less compression of the nerve, making it possible to surgically remove the tumor while preserving nerve function (16). Large hemangiomas are usually interspersed with the FN, therefore it is difficult to excise the tumor from the nerve, and it is often necessary to remove the involved portion of the facial nerve and repair it with end-to-end primary anastomosis or interposition with a graft. In our case, we performed FN partial excision and repaired it using end-to-end interposition grafting with greater auricular nerve. We used fibrine glue to stabilize the grafting material in place. There are some conflicting reports on the management of these injuries, with the timing of surgery being one of the most controversial subjects. The recurrence of FNH is rare after complete or partial excision (17).

CONCLUSION

Facial nerve hemangiomas should be considered as a possible cause of facial paralysis in the differential diagnosis of middle ear tumors.

Informed Consent: Written informed consent was obtained.

Peer Review: Externally peer-reviewed.

Author Contributions: Conception/Design of Study- D.B., M.D.; Data Acquisition- M.D.; Data Analysis/Interpretation- D.B., M.D.; Drafting Manuscript- D.B.; Critical Revision of Manuscript- D.B.; Final Approval and Accountability- D.B.; Material or Technical Support- F.K., B.A.; Supervision- D.B.

Conflict of Interest: The authors have no conflict of interest to declare.

Financial Disclosure: The authors declared that this study has received no financial support.

REFERENCES

1. Mangham CA, Carberry JN, Brackmann DE. Management of intratemporal vascular facial nerve tumors. *Laryngoscope* 1981;91:863-7.
2. Pulec JL. Facial nerve tumors. *Ann Otol Rhinol Laryngol* 1969;78:962-82.
3. Balkany T, Fradis M, Jafek BW, Rucker NC. Hemangioma of the facial nerve: role of the geniculate capillary plexus. *Skull Base Surg* 1991;1(1):59-63.
4. Hopkins B, Aygun N, Eisen M. Hemangioma of the vertical segment of the facial nerve. *Otol Neurotol* 2007;28(4):570-1.
5. Eby T, Fisch U, Makek MS. Facial nerve management in temporal bone hemangiomas. *Am J Otol* 1992;13(3):223-32.

6. Piccirillo E, Agarwal M, Rohit, Khrais T, Sanna M. Management of temporal bone hemangiomas. *Ann Otol Rhinol Laryngol* 2004;113(6):431-7.
7. Friedman O, Neff BA, Willcox TO, et al. Temporal bone hemangiomas involving the facial nerve. *Otol Neurotol* 2002;23(5):760-6.
8. Saliba I, Fayad JN. Facial nerve hemangioma of the middle ear. *Ear Nose Throat J* 2009;88(3):822-3.
9. Costa LEM, Castro RF, Costa FMM, Santos MAO. Facial nerve hemangioma in the middle ear. *Einstein (Sao Paulo)* 2018;16(4):eRC4509.
10. Miyashita T, Hoshikawa H, Kagawa M, Mori N. A case report of facial nerve hemangioma. *Auris Nasus Larynx* 2007;34(4):519-22.
11. Hopkins B, Aygun N, Eisen MD. Hemangioma of the vertical segment of the facial nerve. *Otol Neurotol* 2007;28(4):570-1.
12. Achilli V, Mignosi S. Facial nerve hemangioma. *Otol Neurotol* 2002;23(6):1003-4.
13. Escada P, Capucho C, Silva JM, Ruah CB, Vital JP, Penha RS. Cavernous haemangioma of the facial nerve. *J Laryngol Otol* 1997;111(9):858-61 .
14. Burton L, Burton EM, Welling DB, Marks SD, Binet EF. Hemangioma of the temporal bone in a patient presumed to have Ménière's syndrome. *South Med J* 1997;90(7):736-9 .
15. Tokyol C, Yilmaz MD. Middle ear hemangioma: a case report. *Am J Otolaryngol* 2003;24(6):405-7.
16. Sataloff RT, Frattali MA, Myers DL. Intracranial facial neuromas: total tumor removal with facial nerve preservation: a new surgical technique. *Ear Nose Throat J* 1995;74:248-56.
17. Maroun T, Semaan, William H. Slattery, and Derald E. Brackmann. Geniculate Ganglion Hemangiomas: Clinical Results and Long-Term Follow-Up. *Otol Neurotol* 2010;31(4):665-70.