

A Hybrid Ameloblastoma in Posterior Mandible: A Case Report

Posterior Mandibulada Bir Hibrit Ameloblastoma: Olgu Sunumu

Büşra KARASU^a(ORCID-0000-0002-8267-6965), Öznur ÖZALP^a(ORCID-0000-0003-4350-1975), Gülay ÖZBİLİM^b(ORCID-0000-0002-9850-5976),

Alper SİNDEL^c(ORCID-0000-0001-8760-5958), Büşra ALTUNAY^b(ORCID-0000-0001-6534-6078)

^aAkdeniz Üniversitesi, Diş Hekimliği Fakültesi, Ağız Diş ve Çene Cerrahisi AD, Antalya, Türkiye

^aAkdeniz University, Faculty of Dentistry, Department of Oral and Maxillofacial Surgery, Antalya, Türkiye

^bAkdeniz Üniversitesi, Tıp Fakültesi, Cerrahi Tıp Bilimleri Bölümü, Tıbbi Patoloji AD, Antalya, Türkiye

^bAkdeniz University, Faculty Of Medicine, Department Of Surgical Medical Sciences, Department Of Medical Pathology, Antalya, Türkiye

ABSTRACT

Objective: Hybrid ameloblastoma refers to the tumors that contain two or more different histologic types of ameloblastoma. Till date, only 49 cases of hybrid ameloblastoma with different combinations have been reported. Here we present a case of hybrid ameloblastoma containing follicular, plexiform, and acanthomatous types.

Case Report: A 24-year-old male patient referred to our clinic with a slow-growing asymptomatic swelling on the right side of the mandible. Radiographic assessment revealed a well-defined radiolucent lesion associated with an impacted third molar. Following incisional biopsy, which was compatible with ameloblastoma, total excision of the lesion along with Carnoy fixation was performed. Final histopathologic assessment revealed a hybrid ameloblastic lesion which contained follicular, plexiform, and acanthomatous types.

Conclusion: Hybrid ameloblastoma has variable clinical, radiological, and histopathological presentation. As a rare entity, the biological behavior of the lesion still needs to be analyzed extensively with further clinical research.

Keywords: Carnoy, Enucleation, Hybrid ameloblastoma.

ÖZ

Amaç: Hibrit ameloblastoma, iki veya daha fazla farklı histolojik ameloblastoma alt tipini içeren tümörleri ifade eder. Bugüne kadar, farklı kombinasyonlara sahip sadece 49 hibrit ameloblastoma vakası bildirilmiştir. Burada foliküler, pleksiform ve akantomatöz alt tipler içeren bir hibrit ameloblastoma vakası sunulmaktadır.

Olgu Sunumu: 24 yaşında erkek hasta, kliniğimize mandibulanın sağ tarafında yavaş büyüyen, ağrı ve pü akışının eşlik ettiği, sert şişlik şikâyeti ile başvurdu. Radyografik değerlendirmede, gömülü üçüncü molar diş ile ilişkili iyi sınırlı bir radyolüsent lezyon saptandı. Ameloblastoma ile uyumlu insizyonel biyopsi sonrası lezyonun total eksizyonu ve Carnoy solüsyonu ile kimyasal fiksasyon uygulandı. Nihai histopatolojik değerlendirme, foliküler, pleksiform ve akantomatöz alt tipleri içeren bir hibrit ameloblastik lezyonu ortaya çıkardı.

Sonuç: Hibrit ameloblastoma değişken klinik, radyolojik ve histopatolojik prezentasyona sahiptir. Nadir bir antite olarak, lezyonun biyolojik davranışının daha ileri klinik araştırmalarla kapsamlı bir şekilde analiz edilmesi gerekmektedir.

Anahtar Kelimeler: Carnoy, Enükleasyon, Hibrit ameloblastoma

Introduction

Ameloblastoma is a benign but locally aggressive tumor accounting for around 18% of all odontogenic neoplasms¹. Till date, various classifications of ameloblastoma were suggested based on their clinical, radiological, and histological features. Most recently, WHO 2017 classification divided ameloblastoma into four categories: conventional, extrasosseous or peripheral, unicystic, and metastasizing ameloblastoma².

The unicystic ameloblastoma has three histological subtypes including luminal, intraluminal, and mural types. As well, many microscopic subtypes of conventional ameloblastoma have been identified including follicular, plexiform, acanthomatous, granular cell, desmoplastic and basal cell types. The desmoplastic type was previously speculated to be more aggressive and classified as a different type, however, in the latest update, it has been moved to a histologic subtype without biological significance.

In 1987, Waldron and el-Mofty suggested the term 'hybrid ameloblastoma' for ameloblastic tumors that contain two or more different histologic subtypes³. To best of our knowledge, < 50 cases of hybrid ameloblastoma have been published so far.¹ The aim of this report was to report a case of hybrid ameloblastoma containing follicular, plexiform, and acanthomatous types in an attempt to contribute current knowledge of this rare entity which could be a challenge in diagnosis and management due to its unusual histopathological presentation.

Case Report

A 24-year-old male patient applied to our clinic with the complaint of a firm swelling in the right mandibular molar region, which has been growing for a while, accompanied by pain and pus flow (Figure 1).

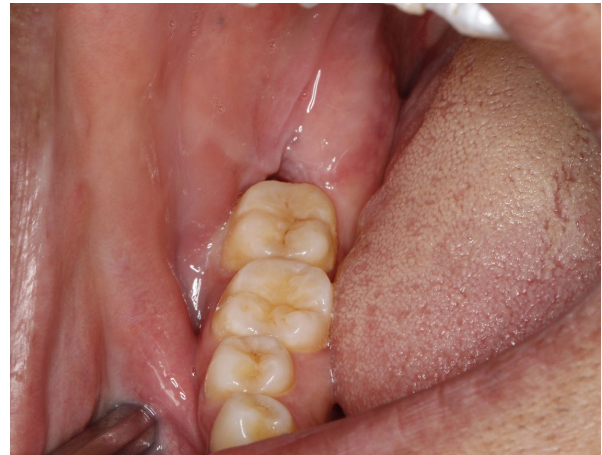

Figure 1. Preoperative intraoral view showing the swelling and fistula.

Gönderilme Tarihi/Received: 17 Ocak, 2023

Kabul Tarihi/Accepted: 22 Ağustos, 2023

Yayınlanma Tarihi/Published: 26 Nisan, 2024

Atıf Bilgisi/Cite this article as: Karasu B, Özalp Ö, Özbilim G, Sindel A, Altunay B. A Hybrid Ameloblastoma in Posterior Mandible: A Case Report. Selcuk Dent J 2024;11(1): 55-58 Doi: 10.15311/ selcukdentj.1237397

Sorumlu yazar/Corresponding Author: Büşra KARASU

E-mail: busrakarasu395@gmail.com

Doi: 10.15311/ selcukdentj.1237397

Radiographic examination revealed a unilocular radiolucency with a well-defined border involving the molar-ramus region extending to the lower border of the right mandible (Figure 2).

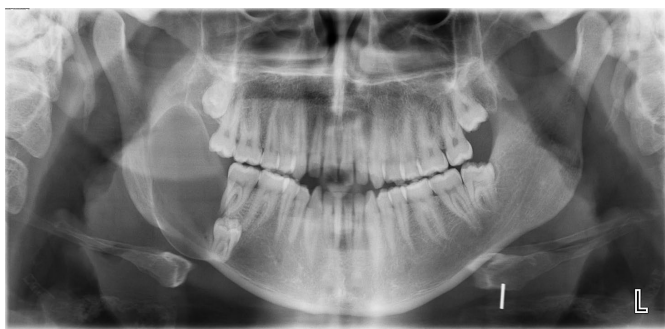

Figure 2. Preoperative OPG. Note that no displacement or root resorption was present in adjacent tooth.

The lesion was associated with impacted third molar, however, no resorption or displacement in adjacent teeth was present. Although expansion was observed in the buccal and lingual cortex of the mandible on computed tomography, no perforation was observed (Figure 3).

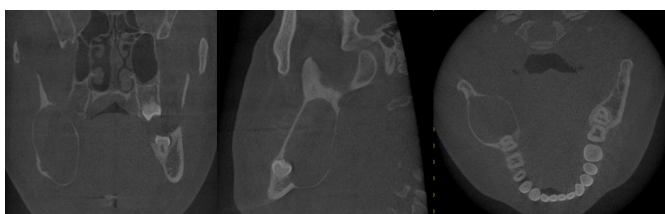

Figure 3. Preoperative CBCT. Expansion of the buccal and lingual cortices.

The patient was informed about the treatment planning and gave his written consent for clinical and radiological data acquisition as well as for surgical procedures. Following incisional biopsy, which was referring to an ameloblastoma, considering the age of the patient, final surgery was performed by enucleation, curettage, and chemical fixation with Carnoy's solution under general anesthesia (Figure 4).

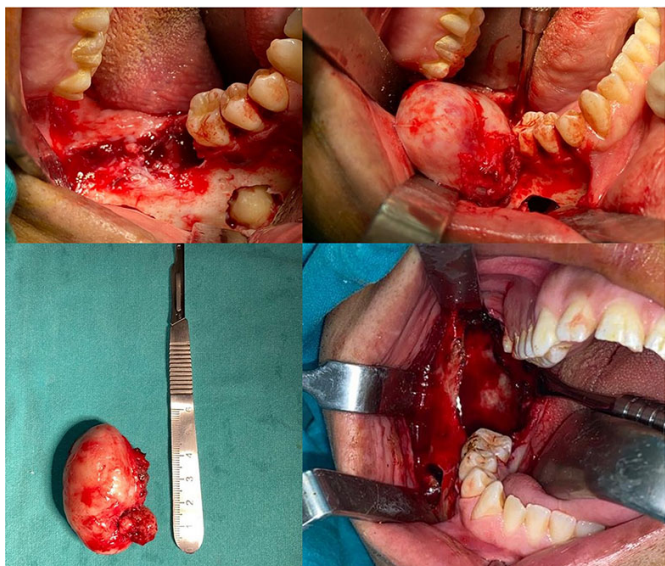


Figure 4. Final surgery was performed by enucleation, curettage, and chemical fixation with Carnoy's solution.

Histopathology of the total lesion revealed that the lesion was a hybrid ameloblastoma containing follicular, plexiform, and acanthomatous types. (Figure 5,6)

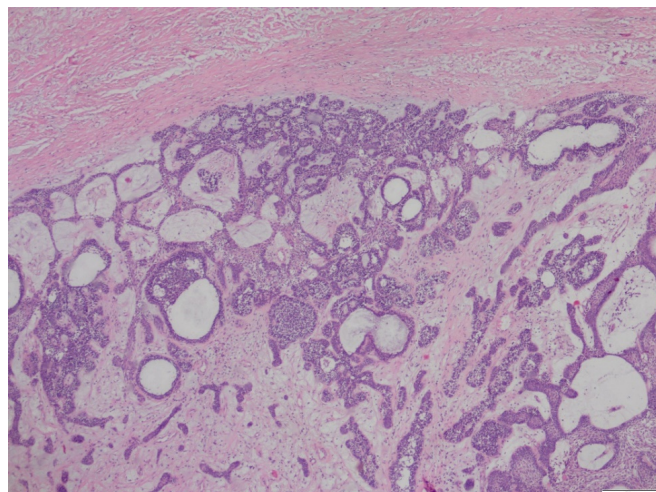


Figure 5. Hematoxylin-eosin staining at 4x magnification, tumoral tissue with basophilic palisatation around the well-demarcated halo is observed.

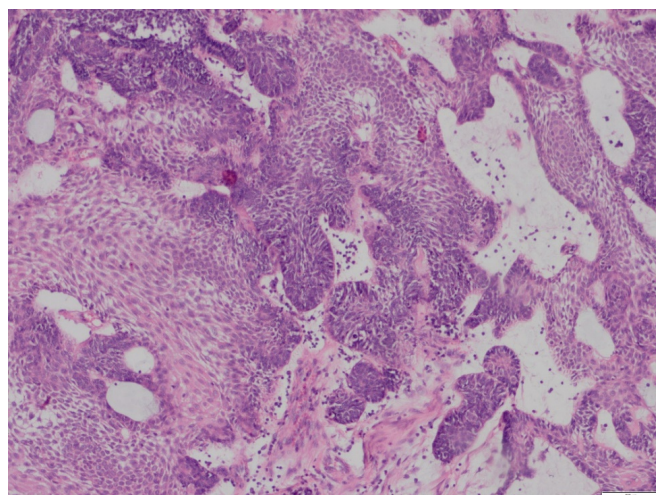


Figure 6. Hematoxylin-eosin staining at 10x magnification, ameloblastoma with follicular, acanthomatous, plexiform areas.

Post-operative period of the patient was uneventful and radiographic examination revealed evidence of proper bone remodeling at 1 year of follow-up (Figure 7,8). The patient has still been followed up for recurrence or further complications.

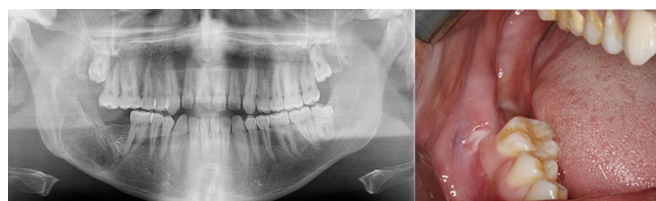

Figure 7. 1 year follow-up examination revealed proper ongoing bone healing and uneventful mucosal healing.

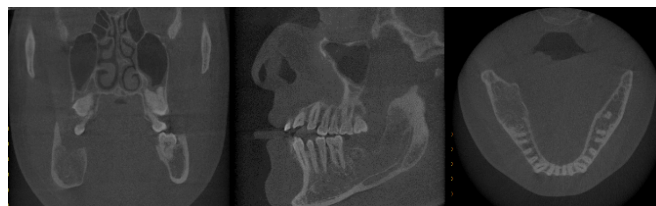

Figure 8. Postoperative 1-year follow-up ongoing bone healing on CBCT.

Discussion

Since the first description by Waldron and el-Mofty, only few cases of hybrid ameloblastomas have been reported globally.^{1,4} Similar to the presented case, the most common site of involvement for hybrid ameloblastoma is the mandible at a ratio of 5:3 when compared with the maxilla.⁵

The case presented contained follicular, plexiform, and acanthomatous subtypes. Follicular and plexiform ameloblastomas alone have been reported to be the most common histological variants and accounted for 32.5% and 28.2%, respectively, followed by the acanthomatous subtype with 12.1%.⁶ The hybrid variant has commonly been reported to appear as mixed radiolucent and radiopaque lesions with irregular borders, however, few cases exhibit a radiolucent pattern, as observed in our patient.^{7,8}

There is no general agreement regarding the surgical management of hybrid ameloblastoma since the biologic behavior of this rare entity has not been established yet.⁴ Several reports have described treatment algorithms for ameloblastoma. Many surgeons prefer a radical surgical approach in the form of resection as management of all types of ameloblastoma as it is a formidable tumor due to its local aggressive nature and its tendency to recur.^{5,9} However, Escande et al. suggested that unilocular ameloblastomas less than 5 cm in diameter that contain several medium-sized "soap bubbles" should be treated in a conservative manner in performing enucleation and curettage.¹⁰

Carnoy solution is used as a chemical curettage agent in the treatment of benign lesions of the jaws, particularly keratocysts, due to its cauterization, penetration, and fixation properties.¹¹ As well, it has been reported in several studies that adjunctive use of Carnoy's solution following enucleation or curettage of aggressive lesions such as ameloblastoma could provide some benefits. In a retrospective study by Lee et al., it was reported decreased recurrence rate when Carnoy solution was applied for 3 minutes after enucleation of unicystic ameloblastomas with 93% mural invasion.¹² According to Lau and Samman, the recurrence rate was 3.6% at resection, 30.5% in enucleation alone, and 16% in Carnoy application after enucleation.¹³ From the findings of the available studies, it can be assumed that after enucleation of the ameloblastoma it is likely to fix residual ameloblastoma tissue and reduce the risk of recurrence, but it is based on the two studies mentioned.^{12,13}

In the presented case, we therefore preferred enucleation, curettage, and chemical fixation with Carnoy's solution opted for preservation of the inferior alveolar nerve and maintaining the quality of life by focusing on aesthetics and function, and the proposed technique achieved successful outcomes.

Conclusion

The biological behaviour and prognosis of hybrid ameloblastoma has not been clearly established. Further clinical, radiological, and histopathological data are required to clearly demonstrate this rare pathologic entity.

Değerlendirme / Peer-Review

İki Dış Hakem / Çift Taraflı Körleme

Etik Beyan / Ethical statement

Bu makale, Türk Oral Maksillofasial Cerrahi Derneği 29. Uluslararası Bilimsel Kongresi'nde sözlü olarak sunulan ancak tam metni yayımlanmayan "A HYBRID AMELOBLASTOMA IN POSTERIOR MANDIBLE: A CASE REPORT" adlı tebliğin içeriği geliştirilerek ve kısmen değiştirilerek üretilmiş hâlidir.

Bu çalışmanın hazırlanma sürecinde bilimsel ve etik ilkelere uyulduğu ve yararlanılan tüm çalışmaların kaynakçada belirtildiği beyan olunur.

This article is a version of the paper titled "A HYBRID AMELOBLASTOMA IN POSTERIOR MANDIBLE: A CASE REPORT", which was presented orally at the 29th International Scientific Congress of the Turkish Oral Maxillofacial Surgery Association, but whose full text was not published, by improving and partially changing the content.

It is declared that scientific and ethical principles were followed during the preparation of this study and that all studies used are stated in the bibliography.

Benzerlik Taraması / Similarity scan

Yapıldı - ithenticate

Etik Bildirim / Ethical statement

ethic.selcukdentaljournal@hotmail.com

Telif Hakkı & Lisans / Copyright & License

Yazarlar dergide yayınlanan çalışmalarının telif hakkına sahiptirler ve çalışmalarını CC BY-NC 4.0 lisansı altında yayımlanmaktadır.

Finansman / Grant Support

Yazarlar bu çalışma için finansal destek almadığını beyan etmiştir. | The authors declared that this study has received no financial support.

Çıkar Çatışması / Conflict of Interest

Yazarlar çıkar çatışması bildirmemiştir. | The authors have no conflict of interest to declare.

Yazar Katkıları / Author Contributions

Çalışmanın Tasarlanması | Design of Study: AS (%50), ÖÖ (%30), BK (%20)

Veri Toplanması | Data Acquisition: BK (%50), GÖ (%30) BA (%20)

Veri Analizi | Data Analysis: AS (%50), ÖÖ (%30), BK (%20)

Makalenin Yazımı | Writing up: BK (%40), ÖÖ (%30), AS (%20), GÖ (%10)

Makale Gönderimi ve Revizyonu | Submission and Revision: BK (%50), ÖÖ (%40), BA (%10)

REFERENCES

1. Rai S, Misra D, Prabhat M, Jain A, Jain P. Hybrid ameloblastoma of anterior maxilla: A rare and puzzling pathologic entity-Case report with systematic review. *Contemporary Clinical Dentistry*. 2019;10(1):147.
2. Wright JM, Tekkesin MS. Odontogenic tumors: where are we in 2017? *Journal of Istanbul University Faculty of Dentistry*. 2017;51(3 Suppl 1):S10.
3. Waldron CA, El-Mofty SK. A histopathologic study of 116 ameloblastomas with special reference to the desmoplastic variant. *Oral surgery, oral medicine, oral pathology*. 1987;63(4):441-51.
4. Chaitanya B, Chhapparwal Y, Pai KM, Kudva A, Cariappa K, Acharya S. Hybrid ameloblastoma: An amalgam of rare and conventional ameloblastoma. *Contemporary Clinical Dentistry*. 2016;7(1):90.
5. Torres-Lagares D, Infante-Cossío P, Hernández-Guisado JM, Gutiérrez-Pérez JL. Mandibular ameloblastoma. A review of the literature and presentation of six cases. *Medicina oral, patología oral y cirugía bucal*. 2005;10(3):231-8.
6. Grandis E-NACJ, WHO JTTSP. WHO classification of head and neck tumours. IARC. Lyon; 2017.
7. Santos JNd, De Souza VF, Azevêdo RA, Sarmiento VA, Souza LB. "Hybrid" lesion of desmoplastic and conventional ameloblastoma: immunohistochemical aspects. *Revista Brasileira de Otorrinolaringologia*. 2006;72:709-13.
8. Yamazaki M, Maruyama S, Abé T, Babkair H, Fujita H, Takagi R, et al. Hybrid ameloblastoma and adenomatoid odontogenic tumor: report of a case and review of hybrid variations in the literature. *Oral surgery, oral medicine, oral pathology and oral radiology*. 2014;118(1):e12-e8.
9. Mladick RA, Robinson L, Martinez M. Unicystic ameloblastoma, a prognostically distinct entity. *Plastic and Reconstructive Surgery*. 1978;62(3):493.
10. Escande C, Chaine A, Menard P, Ernenwein D, Ghoul S, Bouattour A, et al. A treatment algorithm for adult ameloblastomas according to the Pitié-Salpêtrière Hospital experience. *Journal of Cranio-Maxillofacial Surgery*. 2009;37(7):363-9.
11. Kalaskar R, Unawane AS, Kalaskar AR, Pandilwar P. Conservative management of unicystic ameloblastoma in a young child: Report of two cases. *Contemporary Clinical Dentistry*. 2011;2(4):359-63.
12. Lee P, Samman N, Ng I. Unicystic ameloblastoma—use of Carnoy's solution after enucleation. *International journal of oral and maxillofacial surgery*. 2004;33(3):263-7.
13. Lau S, Samman N. Recurrence related to treatment modalities of unicystic ameloblastoma: a systematic review. *International journal of oral and maxillofacial surgery*. 2006;35(8):681-90.