

# Prognostic role of preoperative neoadjuvant chemotherapy in patients with tongue cancer

İ Süleyman Cebeci<sup>1</sup>, İ Emirhan Akyol<sup>1</sup>, İ Utku Aydil<sup>1</sup>, İ Alper Dilci<sup>2</sup>, İ Aytuğ Üner<sup>3</sup>

Department of Otorhinolaryngology, Head and Neck Surgery, Faculty of Medicine, Gazi University, Ankara, Turkey

Department of Otorhinolaryngology, Head and Neck Surgery, Faculty of Medicine, Uşak University, Uşak, Turkey

Department of Medical Oncology, Faculty of Medicine, Gazi University, Ankara, Turkey

**Cite this article as:** Cebeci S, Akyol E, Aydil U, Dilci A, Üner A. Prognostic role of preoperative neoadjuvant chemotherapy in patients with tongue cancer. J Med Palliat Care 2023; 4(2): 106-111.

## ABSTRACT

**Aim:** This study aimed to investigate the relationship between preoperative neoadjuvant chemotherapy (NAC) and overall survival in patients with tongue cancer who underwent glossectomy.

**Material and Method:** The study included 35 tongue cancer patients who underwent glossectomy. Twenty patients did not receive any treatment before surgery (control group). Fifteen patients received two cycles of cisplatin-containing NAC prior to surgery. Five-year overall survival findings were compared between the groups.

**Results:** Median pathological depth of invasion was lower in the NAC group compared to the control group (7 vs. 9 mm,  $p=0.037$ ). The mortality rate was lower in the NAC group (26.7% vs. 50.0%,  $p=0.008$ ). Increased depth of invasion was independently associated with increased risk of mortality, while receiving NAC was independently associated with decreased risk of mortality. The risk of mortality was 6.25-fold lower (1/0.16) in the NAC group compared to the control group (HR: 0.16, 95% CI: 0.004-0.72,  $p=0.017$ ).

**Conclusion:** Patients who underwent NAC plus surgery were associated with a higher probability of 5-year overall survival compared to patients who underwent surgery alone. These findings may be inspiring for the role of NAC prior to surgery in the prognosis of patients with tongue cancer.

**Keywords:** Depth of invasion, neoadjuvant chemotherapy, prognosis, tongue cancer

## INTRODUCTION

Tongue cancer, which is the most common form of malignancy in the head and neck area, has significant morbidity and mortality rates (1). The primary treatment for tongue cancer is surgery, which is followed by radiation therapy and chemotherapy. Despite new treatment strategies, the 5-year overall survival rate has not changed significantly (2). Treatment success and overall survival depend on tumor location, stage, depth of invasion, resection margin, and pathological TNM stage (3).

Preoperative neoadjuvant chemotherapy (NAC) is a therapeutic strategy applied to preserve functions and reduce mortality risk (4). NAC can reduce tumor burden, prevent micrometastatic disease, improve surgical outcomes, and potentially play a prognostic role (5). However, studies to date report conflicting results regarding the efficacy of NAC (4-6). In previous meta-analysis studies involving head and neck cancer patients, NAC did not significantly improve overall survival, while a combination regimen of NAC with 5-fluorouracil (5-

FU) and cisplatin increased overall survival compared to single-agent NAC (7, 8), some studies have reported that the combination of NAC including docetaxel offers better overall survival (9-11). However, these studies included various head and neck cancer subtypes and the frequency of tongue cancer patients was low. Therefore, more evidence is needed on the prognostic role of NAC in tongue cancer patients.

This study aimed to investigate the relationship between preoperative NAC and overall survival in patients with tongue cancer who underwent glossectomy.

## MATERIAL AND METHOD

This retrospective study was carried out in the Gazi University Faculty of Medicine's Department of Otorhinolaryngology. The study was performed in accordance with the Declaration of Helsinki and approved by the Gazi University Faculty of Medicine Clinical Researches Ethics Committee (Date: 04/2011, Decision No: 92).

### Study Population

A total of 75 patients (≥18 years old) who had tongue cancer and underwent glossectomy between January 2006 and January 2012 were evaluated retrospectively. Among these patients, those with pathology other than squamous cell carcinoma, those with a previous history of malignancy, and those with missing data were excluded. Finally, 35 patients were included in the analysis. The decision of NAC was at the discretion of the senior surgeon. Twenty patients did not receive any treatment before surgery (control group). Fifteen patients received two cycles of cisplatin-containing NAC prior to surgery.

Demographic, clinical and 5-year overall survival data of the patients were obtained from the hospital database and pathology and radiology archives. While clinical stages were determined according to examination notes and radiological images of the patients, pathological findings were determined according to pathology reports.

### Statistical Analysis

The normality of numerical data was evaluated with the Kolmogorov-Smirnov test. Data were presented as mean±standard deviation or median (min-max) according to normal distribution. Categorical variables were expressed as numbers and percentages. Cox regression analyses were conducted to establish any possible factors independently associated with mortality. Overall survival plots were made with Kaplan-Meier analysis. Values of  $p < 0.05$  were taken to be statistically significant. All data were analyzed using IBM SPSS Statistics for Windows 20.0 (IBM Corp., Armonk, NY, USA) and MedCalc 11.4.2 (MedCalc Software, Mariakerke, Belgium).

### RESULTS

The median age of the patients who had tongue cancer and underwent glossectomy was 58 years (range: 24-77 years) and the majority of them were male (68.6%). The rates of pathological T2 (51.4%) and pathological N0 (65.7%) stages were higher. Median pathological depth of invasion was 9 mm (range: 2-18 mm) and median tumor size was 2 cm (range: 0.3-5.7 cm). Surgical margins were positive in 5.7% of the cases. Perineural invasion was observed in 3 patients, lymphovascular invasion in 3 patients, and lymph node metastasis in 13 patients (Table 1).

Median pathological depth of invasion was lower in the NAC group compared to the control group (7 vs. 9 mm,  $p=0.037$ ). Other demographic and clinical characteristics did not differ significantly between the NAC group and control group. The mortality rate was lower in the NAC

group compared to the control group (26.7% vs. 50.0%,  $p=0.008$ ) (Table 1).

**Table 1. Patients' characteristics and clinical findings**

Variables	All population n=35	NAC		P
		Yes n=15	No n=20	
Age, years	58 (24-77)	55 (24-74)	60 (28-77)	0.074
Male gender, n (%)	24 (68.6)	9 (60.0)	15 (75.0)	0.563
cT, n (%)				0.215
T1	6 (17.1)	1 (6.7)	5 (25.0)	
T2	21 (60.0)	9 (60.0)	12 (60.0)	
T3	8 (22.9)	5 (33.3)	3 (15.0)	
cN, n (%)				0.818
N0	18 (51.4)	7 (46.7)	11 (55.0)	
N1	10 (28.6)	4 (26.7)	6 (30.0)	
N2	7 (20.0)	4 (26.7)	3 (15.0)	
pT, n (%)				0.810
T1	8 (22.9)	4 (26.7)	4 (20.0)	
T2	18 (51.4)	8 (53.3)	10 (50.0)	
T3	9 (25.7)	3 (20.0)	6 (30.0)	
pN, n (%)				0.792
N0	23 (65.7)	9 (60.0)	14 (70.0)	
N1	6 (17.1)	3 (20.0)	3 (15.0)	
N2	6 (17.1)	3 (20.0)	3 (15.0)	
Tumor size, cm	2 (0.3-5.7)	1.5 (0.3-5.7)	2.1 (1.1-5.0)	0.501
Difference, n (%)				0.644
Well	24 (68.6)	9 (60.0)	15 (75.0)	
Moderate	8 (22.9)	4 (26.7)	4 (20.0)	
Poor	3 (8.6)	2 (13.3)	1 (5.0)	
Depth of invasion, mm	9 (2-18)	7 (2-11)	9 (3-18)	0.037
Surgical margins, n (%)				0.496
Negative	33 (94.3)	15 (100.0)	18 (90.0)	
Positive	2 (5.7)	0	2 (10.0)	
Lymphovascular invasion, n (%)	3 (8.6)	1 (6.7)	2 (10.0)	0.999
Perineural invasion, n (%)	3 (8.6)	1 (6.7)	2 (10.0)	0.999
Extracapsular extension, n (%)	0	0	0	-
Lymph node metastasis, n (%)	13 (37.1)	6 (40.0)	7 (35.0)	0.999
Mortality, n (%)	14 (40.0)	4 (26.7)	10 (50.0)	0.008

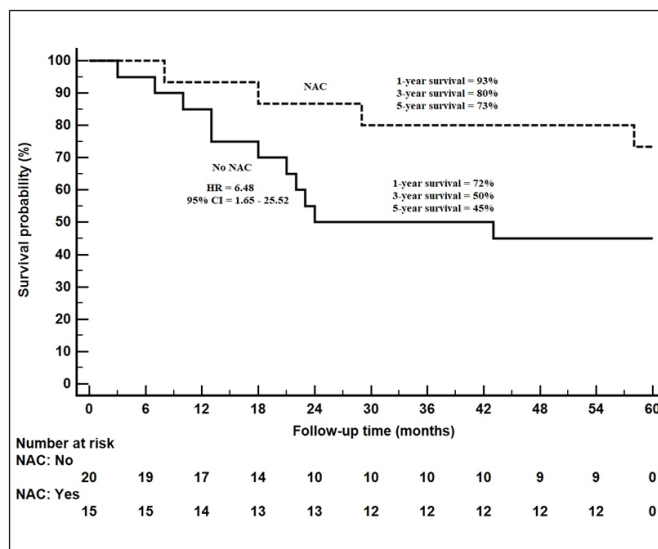
Data are shown as median and min - max or number and percentage (%).  
Abbreviations: cT, clinical T stage; cN, clinical N stage; pT, pathological T stage; pN, pathological N stage.

Mean follow-up time was 40.0±4.1 months. Findings associated with 5-year overall survival are presented in Table 2. Increased age, NAC administration and increased depth of invasion were found to be factors associated with 5-year overall survival. Multivariable regression analysis showed that increased depth of invasion was independently associated with increased risk of mortality, while receiving NAC was independently associated with decreased risk of mortality. The risk of mortality was 6.25-fold lower (1/0.16) in the NAC group compared to the control group (HR: 0.16, 95% CI: 0.004-

0.72, p=0.017). A 1-mm increase in depth of invasion increased the risk of mortality by 1.3-fold (HR: 1.38, 95% CI: 1.05-2.00, p=0.030) (Table 3).

The 1-year overall survival probability was 93% and the 5-year overall survival probability was 73% in the NAC group. The 1-year overall survival probability was 72% and the 5-year overall survival probability was 45% in the control group (Figure 1).

Variables	Multivariable Cox Regression		
	HR	95% CI	p
Age, years	1.03	0.98-1.08	0.177
Neoadjuvant chemotherapy, n (%)	0.16	0.04-0.72	0.017
Depth of invasion, mm	1.38	1.05-2.00	0.030
-2Log Likelihood=11.76, p<0.001			
Abbreviations: CI, confidence interval; HR, hazard ratio			



Variables	Overall Survival		Univariable Cox Regression		
	Alive n=21	Exitus n=14	HR	95% CI	p
Age, years	55 (24-74)	65 (36-77)	1.04	1.00-1.09	0.043
Male gender, n (%)	12 (57.1)	12 (85.7)	3.38	0.76-15.07	0.111
Neoadjuvant chemotherapy, n (%)	11 (52.4)	4 (28.6)	0.15	0.04-0.61	0.008
cT, n (%)					
1	5 (23.8)	1 (7.1)	ref		
2	10 (47.6)	11 (78.6)	2.84	0.37-22.03	0.319
3	6 (28.6)	2 (14.3)	1.68	0.17-16.21	0.653
cN, n (%)					
0	13 (61.9)	5 (35.7)	ref		
1	5 (23.8)	5 (35.7)	2.56	0.78-8.40	0.122
2	3 (14.3)	4 (28.6)	2.08	0.55-7.83	0.277
pT, n (%)					
1	6 (28.6)	2 (14.3)	ref		
2	10 (47.6)	8 (57.1)	1.28	0.27-6.10	0.753
3	5 (23.8)	4 (28.6)	2.11	0.41-10.95	0.375
pN, n (%)					
0	14 (66.7)	9 (64.3)	ref		
1	5 (23.8)	1 (7.1)	1.01	0.22-4.68	0.992
2	2 (9.5)	4 (28.6)	1.87	0.57-6.12	0.301
Tumor size, cm	2 (0.3-5.7)	2.1 (1-3.5)	0.93	0.58-1.50	0.759
Difference, n (%)					
Well	15 (71.4)	9 (64.3)	ref		
Moderate	4 (19.0)	4 (28.6)	0.86	0.26-2.88	0.810
Poor	2 (9.5)	1 (7.1)	1.57	0.33-7.48	0.569
Depth of invasion, mm	8 (2-13)	13 (9-18)	1.36	1.03-1.80	0.030
Surgical margins, n (%)					
Negative	19 (90.5)	14 (100.0)	ref		
Positive	2 (9.5)	0	2.46	0.31-19.81	0.397
Lymphovascular invasion, n (%)	1 (4.8)	2 (14.3)	1.48	0.33-6.65	0.607
Perineural invasion, n (%)	2 (9.5)	1 (7.1)	0.90	0.12-6.96	0.922
Lymph node metastasis, n (%)	8 (38.1)	5 (35.7)	1.37	0.49-3.87	0.552

Data are shown as median and min - max or number and percentage (%).  
Abbreviations: cT, clinical T stage; cN, clinical N stage; pT, pathological T stage; pN, pathological N stage.

## DISCUSSION

In this study, NAC was found to improve 5-year overall survival. The depth of invasion was lower in the NAC group. Increased depth of invasion was an independently associated with increased risk of mortality. These associations were independent of the pathological stage of the disease.

NAC is cited as a therapeutic strategy for functional preservation, relapse control, and reduction of mortality risk (4). It has been suggested that NAC is associated with a high response rate in untreated patients with head and neck cancers (2). Assessment of tumor response to NAC includes histopathologic evaluation of tumor regression in resected specimens (12). In our study, pathological depth of invasion was lower in the NAC group and tumor size was relatively smaller. These findings support the potential role of NAC in reducing tumor burden. Tumor size reduction following NAC can reduce the extent of surgery, provide better preservation of function, and improve quality of life (13). On the other hand, preoperative NAC may also play a prognostic role in reducing surgical margins (5). This was consistent with the finding of negative surgical margins in all patients who received NAC. However, it still remains unclear whether NAC can reduce the rates of distant metastasis or locoregional relapse (3). The rates of lymphovascular invasion, perineural invasion, and lymph node metastasis were not significantly different in the NAC group compared to the control group in the present study. In an experimental study of a mouse model of oral squamous cell carcinoma, mice were divided into surgery, preoperative NAC plus surgery, surgery plus postoperative NAC, and untreated groups. After 28 days of follow-up, cervical lymph node metastasis rates were lower in the preoperative NAC plus surgery group than the other groups (14). DNA microarray studies have shown that the gene expression profiles of metastatic tumors, including lymph node metastasis, are different compared to primary tumors (15, 16). Thus, gene differences in metastatic tumors may result in differences in the response to NAC. This may explain the similar lymph node metastasis rates of the NAC group and the control group.

Previous studies have reported that depth of invasion is an independent predictor of metastatic tumors (17, 18). In the 8th edition of the American Joint Committee on Cancer's staging manual, the depth of tumor invasion was accepted as a prognostic factor in tumor staging (19). In our study, NAC was associated with lower depths of invasion. Since NAC targets control of local disease and systemic micrometastasis, the characteristics and response of the primary tumor may be more closely related to prognosis (12). It is known that there is a

high correlation between radiological depth of invasion and pathological depth of invasion (20, 21). Therefore, changes in the radiological depth of invasion and tumor size may be important for the evaluation of the response of the tumor to NAC. However, a standard method for determining radiological depth of invasion in the preoperative period has not been established yet.

The 5-year overall survival rates of tongue cancer patients range from 32% to 55% (22, 23). In our study, those who received NAC had an approximately 6-fold lower risk of mortality and NAC was an independently associated with decreased risk of mortality. The probability of both 1-year and 5-year overall survival was higher in the NAC group. A prospective study of 198 patients with resectable oral cavity cancer compared the 10-year overall survival rates of patients who underwent only surgery and those who received preoperative NAC (24). There was no significant difference in 10-year overall survival between the groups. However, the probability of overall survival at the 10-year follow-up was 76% for patients with a pathological complete response to NAC compared to 41% for patients who did not respond to NAC (24). A previous study involving patients with hypopharyngeal carcinoma reported that preoperative NAC improved overall survival (25). In contrast, a meta-analysis study showed that NAC did not confer a significant advantage in terms of disease-free survival or overall survival at the 2-year follow-up (23). Similarly, another head and neck cancer meta-analysis including 87 studies showed no increase in overall survival following NAC (8). However, the patients with tongue cancer in these studies constituted only small fractions of the total populations.

Different NAC regimens can cause significant differences in overall survival. Combination regimens containing 5-FU, cisplatin, or taxane offer greater advantages in improving overall survival compared to single-agent regimens (8). Moreover, previous studies have reported that the triple regimen containing taxane increases the probability of overall survival compared to the double regimen containing cisplatin plus 5-FU (26). In our study, the NAC regimen consisted of 2 cycles of cisplatin. The use of single-regimen NAC was associated with the clinical approach of the physicians planning treatments in the years in which patients were included. Considering the conflicting findings for NAC regarding overall survival, prospective studies with larger patient populations are needed, especially studies containing both single regimens and combination regimens.

The strengths of this study are the assessment of long-term prognosis in patients with tongue cancer and its inspiring findings between prognosis and preoperative

NAC. However, this study has some important limitations. The main limitation was the single-center retrospective design together with a small sample. Secondly, the response status to NAC could not be evaluated. Thirdly, due to the retrospective design, patients' relapse data was missing and therefore could not be evaluated. Fourthly, the effect of chemotherapy on the depth of tumor invasion could not be evaluated, since data on the pre-treatment values of tumor invasion depth could not be reached. The importance of overall survival was limited due to the lack of data on locoregional recurrence and disease-free survival, which are the main prognostic parameters, and the inability to show that the cause of death was disease-related. Finally, data on the toxicity status of patients following NAC were not available. That may play an important role in the overall survival of patients (26, 27).

## CONCLUSION

Patients who underwent NAC plus surgery were associated with a higher probability of 5-year overall survival compared to patients who underwent surgery alone. However, NAC was associated with lower depths of invasion. These findings may be inspiring for the role of NAC prior to surgery in the prognosis of patients with tongue cancer.

## ETHICAL DECLARATIONS

**Ethics Committee Approval:** The study was carried out with the permission of Gazi University Medicine Faculty Clinical Researches Ethics Committee (Date: 04/2011, Decision No: 92).

**Informed Consent:** Because the study was designed retrospectively, no written informed consent form was obtained from patients.

**Referee Evaluation Process:** Externally peer-reviewed.

**Conflict of Interest Statement:** The authors have no conflicts of interest to declare.

**Financial Disclosure:** The authors declared that this study has received no financial support.

**Author Contributions:** All of the authors declare that they have all participated in the design, execution, and analysis of the paper, and that they have approved the final version.

## REFERENCES

- Rusthoven KE, Raben D, Song JI, Kane M, Altoos TA, Chen C. Survival and patterns of relapse in patients with oral tongue cancer. *J Oral Maxillofac Surg* 2010; 68: 584-9.
- Liu SA, Wong YK, Wang CP, et al. Surgical site infection after preoperative neoadjuvant chemotherapy in patients with locally advanced oral squamous cell carcinoma. *Head Neck* 2011; 33: 954-8.
- Olasz L, Szalma J, Orsi E, Tornoczky T, Marko T, Nyarady Z. Neoadjuvant chemotherapy: does it have benefits for the surgeon in the treatment of advanced squamous cell cancer of the oral cavity? *Pathol Oncol Res* 2010; 16: 207-12.
- Hirakawa H, Hanai N, Suzuki H, et al. Prognostic importance of pathological response to neoadjuvant chemotherapy followed by definitive surgery in advanced oral squamous cell carcinoma. *Jpn J Clin Oncol* 2017; 47: 1038-46.
- Vishak S, Rangarajan B, Kekatpure VD. Neoadjuvant chemotherapy in oral cancers: Selecting the right patients. *Indian J Med Paediatr Oncol* 2015; 36: 148-53.
- Sturgis EM, Moore BA, Glisson BS, Kies MS, Shin DM, Byers RM. Neoadjuvant chemotherapy for squamous cell carcinoma of the oral tongue in young adults: a case series. *Head Neck* 2005; 27: 748-56.
- Pignon JP, Bourhis J, Domenge C, Designe L. Chemotherapy added to locoregional treatment for head and neck squamous-cell carcinoma: three meta-analyses of updated individual data. MACH-NC Collaborative Group. Meta-Analysis of Chemotherapy on Head and Neck Cancer. *Lancet* 2000; 355: 949-55.
- Pignon JP, le Maitre A, Maillard E, Bourhis J, Group M-NC. Meta-analysis of chemotherapy in head and neck cancer (MACH-NC): an update on 93 randomised trials and 17,346 patients. *Radiother Oncol* 2009; 92: 4-14.
- Posner MR, Hershock DM, Blajman CR, et al. Cisplatin and fluorouracil alone or with docetaxel in head and neck cancer. *N Engl J Med* 2007; 357: 1705-15.
- Vermorken JB, Remenar E, van Herpen C, et al. Cisplatin, fluorouracil, and docetaxel in unresectable head and neck cancer. *N Engl J Med* 2007; 357: 1695-704.
- Lorch JH, Goloubeva O, Haddad RI, et al. Induction chemotherapy with cisplatin and fluorouracil alone or in combination with docetaxel in locally advanced squamous-cell cancer of the head and neck: long-term results of the TAX 324 randomised phase 3 trial. *Lancet Oncol* 2011; 12: 153-9.
- Miyata H, Yoshioka A, Yamasaki M, et al. Tumor budding in tumor invasive front predicts prognosis and survival of patients with esophageal squamous cell carcinomas receiving neoadjuvant chemotherapy. *Cancer* 2009; 115: 3324-34.
- Patil VM, Noronha V, Joshi A, Banavali SD, Muddu V, Prabhaskar K. Preoperative Chemotherapy and Metronomic Scheduling of Chemotherapy in Locally Advanced Oral Cancers. *Oncology* 2016; 91 Suppl 1: 35-40.
- Kawashiri S, Noguchi N, Tanaka A, Nakaya H, Kato K, Yamamoto E. Inhibitory effect of neoadjuvant chemotherapy on metastasis of oral squamous cell carcinoma in a mouse model. *Oral Oncol* 2009; 45: 794-7.
- Stoecklein NH, Hosch SB, Bezler M, et al. Direct genetic analysis of single disseminated cancer cells for prediction of outcome and therapy selection in esophageal cancer. *Cancer Cell* 2008; 13: 441-53.
- Lahdesmaki H, Hao X, Sun B, et al. Distinguishing key biological pathways between primary breast cancers and their lymph node metastases by gene function-based clustering analysis. *Int J Oncol* 2004; 24: 1589-96.
- Faisal M, Abu Bakar M, Sarwar A, et al. Depth of invasion (DOI) as a predictor of cervical nodal metastasis and local recurrence in early stage squamous cell carcinoma of oral tongue (ESSCOT). *PLoS One* 2018; 13: e0202632.
- Aaboubout Y, van der Toom QM, de Ridder MAJ, et al. Is the Depth of Invasion a Marker for Elective Neck Dissection in Early Oral Squamous Cell Carcinoma? *Front Oncol* 2021; 11: 628320.
- Lydiatt WM, Patel SG, O'Sullivan B, et al. Head and Neck cancers-major changes in the American Joint Committee on cancer eighth edition cancer staging manual. *CA Cancer J Clin* 2017; 67: 122-37.

20. Mair M, Raj L, Mahmood S, et al. Diagnostic accuracy of magnetic resonance imaging in detecting depth of invasion of tongue cancers. *Br J Oral Maxillofac Surg* 2021; 59: 1275-9.
21. Mao MH, Wang S, Feng ZE, et al. Accuracy of magnetic resonance imaging in evaluating the depth of invasion of tongue cancer. A prospective cohort study. *Oral Oncol* 2019; 91: 79-84.
22. Sungwalee W, Vatanasapt P, Suwanrungruang K, Promthet S. Comparing Survival of Oral Cancer Patients Before and After Launching of the Universal Coverage Scheme in Thailand. *Asian Pac J Cancer Prev* 2016; 17: 3541-4.
23. Marta GN, Riera R, Bossi P, et al. Induction chemotherapy prior to surgery with or without postoperative radiotherapy for oral cavity cancer patients: Systematic review and meta-analysis. *Eur J Cancer* 2015; 51: 2596-603.
24. Bossi P, Lo Vullo S, Guzzo M, et al. Preoperative chemotherapy in advanced resectable OCSCC: long-term results of a randomized phase III trial. *Ann Oncol* 2014; 25: 462-6.
25. Beauvillain C, Mahe M, Bourdin S, et al. Final results of a randomized trial comparing chemotherapy plus radiotherapy with chemotherapy plus surgery plus radiotherapy in locally advanced resectable hypopharyngeal carcinomas. *Laryngoscope* 1997; 107: 648-53.
26. Blanchard P, Bourhis J, Lacas B, et al. Taxane-cisplatin-fluorouracil as induction chemotherapy in locally advanced head and neck cancers: an individual patient data meta-analysis of the meta-analysis of chemotherapy in head and neck cancer group. *J Clin Oncol* 2013; 31: 2854-60.
27. Chaukar D, Prabash K, Rane P, et al. Prospective Phase II Open-Label Randomized Controlled Trial to Compare Mandibular Preservation in Upfront Surgery With Neoadjuvant Chemotherapy Followed by Surgery in Operable Oral Cavity Cancer. *J Clin Oncol* 2022; 40: 272-81.