

To Cite: Yıldız Dalginli, K., Ozturkler, M., Beseren-Havadar, H., Adali, Y. & Atakisi, O. (2023). Evaluation of Oxidative/Nitrosative Stress Parameters And Histopathological, Immunohistochemical Effects on Cisplatin-Induced Lung Toxicity in Rats. *Journal of the Institute of Science and Technology*, 13(4), 2495-2504.

Ratlarda Sisplatin Kaynaklı Akciğer Toksikitesi Üzerine Oksidatif/Nitrozatif Stres Parametrelerinin ve Histopatolojik, İmmünohistokimyasal Etkilerin Değerlendirilmesi

Kezban YILDIZ-DALGINLI^{1*}, Melek OZTURKLER¹, Hatice BESEREN-HAVADAR³, Yasemen ADALI⁴, Onur ATAKISI²

Öne Çıkanlar:

- Sisplatin kaynaklı akciğer toksisitesi üzerine antioksidan/nitrozatif stres, histopatolojik ve immünohistokimyasal etkiler araştırıldı.
- Sisplatin uygulamasının sıçanların akciğer dokusunda NO düzeylerini arttırdığı saptanmıştır.
- p53, CD3, CD20, Bcl-2 ve Ki67'nin sisplatin kaynaklı akciğer toksisitesinin mekanizması üzerindeki etkileri belirlendi.

Anahtar Kelimeler:

- Sisplatin,
- oksidatif/nitrozatif stres,
- histopatoloji,
- immünohistokimya,
- rat

ÖZET:

Bu çalışmanın ana odak noktası, sisplatin kaynaklı akciğer toksisitesinde oksidatif/nitrozatif stres ve antioksidan etkiler ile immünohistokimyasal etkileri araştırmaktır. Çalışmada 2 aylık 12 Sprague Dawley erkek rat kontrol (n=6) ve sisplatin (n=6) olmak üzere iki gruba ayrıldı. Kontrol grubuna izotonik solüsyon, sisplatin grubuna sisplatin 10 mg/kg tek doz intraperitoneal uygulandı. Alınan akciğer dokularında redukte glutasyon (GSH), malondialdehit (MDA) ve nitrik oksit (NO) seviyeleri spektrofotometrik yöntemle belirlendi. Akciğer dokularından parafin bloklar yapıldı ve hematoxilen-eozin (HE) boyama ile boyandı. İmmünohistokimyasal olarak p53, CD3, CD20, Bcl-2 ve Ki67 değerlendirildi. Sıçanların akciğer dokusunda tek başına sisplatin uygulamasının MDA ve GSH değerleri üzerine etkisinin olmadığı, NO düzeylerinin anlamlı olarak arttığı bulundu (P<0.005). Akciğer dokusunun histopatolojik değerlendirmesinde HE boyama ile konjesyon-kanama bulguları, yoğun inflamasyon alanları, bronş ve bronşiyol çevresinde lenfoid foliküller görüldü. Alveoller arasında düşük yoğunluklu ödem ile hava yollarında kan-fibrin ve enflamatuvar hücreler ve fibroblastlardan oluşan konsantrik fibröz ve fibrinöz tıkaçlar gözlemlendi. Reaktif pan B hücre belirteçleri CD20, interstisyel bileşende T-hücre belirteci CD3 ve subepitelyal hücrelerde desmin immünohistokimyasal boyama ile pozitif boyanırken, bronşiyoller ve alveolar kanallara uygulanan reaktif germinal merkezler Bcl-2 ve p53 immünohistokimyasal olarak negatif boyandı. Ayrıca Ki67 immünohistokimyasal boyama ile düşük yoğunluklu nükleer boyanma saptandı. Sonuç olarak NO düzeyinde anlamlı artış ve immünohistokimyasal olarak yoğun inflamasyon, lenfoid foliküller, fibröz ve fibrinöz tıkaçlar sisplatin kaynaklı akciğer hasarı başlangıcının bir ifadesidir.

Evaluation of Oxidative/Nitrosative Stress Parameters and Histopathological, Immunohistochemical Effects on Cisplatin-Induced Lung Toxicity in Rats

Highlights:

- Antioxidative/nitrosative stress, histopathological and immunohistochemical effects were investigated on cisplatin induced lung toxicity.
- It was found that cisplatin administration in the lung tissue of rats NO levels were increased.
- The effects of p53, CD3, CD20, Bcl-2 and Ki67 on the mechanism of cisplatin-induced lung toxicity were determined.

Keywords:

- Cisplatin,
- oxidative/nitrosative stress,
- histopathology,
- immunohistochem,
- rat

ABSTRACT:

The main focus of this study is to investigate oxidative/nitrosative stress and antioxidant effects and immunohistochemical effects in cisplatin-induced lung toxicity. In the study, 12 male Sprague Dawley rats, 2 months old, were divided into two groups: control (n=6) and cisplatin (n=6). Isotonic solution was administered to control and cisplatin 10 mg/kg single dose intraperitoneal to cisplatin group. Reducte glutathione (GSH), malondialdehyde (MDA) and nitric oxide (NO) levels were determined by spectrophotometric method in the lung tissues taken. Paraffin blocks were made from lung tissues and stained with hematoxylin-eosin (HE) staining. Immunohistochemically, p53, CD3, CD20, Bcl-2 ve Ki67 were evaluated. It was found that cisplatin administration alone had no effect on MDA and GSH values in the lung tissue of rats, and NO levels were significantly increased (P<0.005). In the histopathological evaluation of the lung tissue, congestion-bleeding findings, intense inflammation areas, lymphoid follicles around the bronchi and bronchioles were seen with HE staining. Concentric fibrous and fibrinous plugs consisting of blood-fibrin and inflammatory cells and fibroblasts in the airways were observed, with low-density edema between the alveoli. Reactive pan B cell markers CD20, T-cell marker CD3 in the interstitial component and desmin in sub-epithelial cells were stained positively by immunohistochemical staining, while reactive germinal centers Bcl-2 and p53 applied to the bronchioles and alveolar ducts were immunohistochemically stained negative. In addition, low-intensity nuclear staining was found with Ki67 immunohistochemical staining. In conclusion, significant increase in NO level and immunohistochemically intense inflammation, lymphoid follicles, fibrous and fibrinous plugs are an expression of the onset of cisplatin-induced lung injury.

¹Kezban YILDIZ-DALGINLI (Orcid ID: 0000-0002-1483-348X), Melek OZTURKLER (Orcid ID: 0000-0002-2917-6371), Kafkas University, Department of Chemistry and Chemical Processing Technologies, Kars Vocational High School Kafkas University, Kars, Türkiye

²Onur ATAKISI (Orcid ID: 0000-0003-1183-6076), Kafkas University Department of Chemistry, Faculty Science and Letter, Kars, Türkiye

³Hatice BESEREN-HAVADAR (Orcid ID: 0000-0002-4780-540X), Kafkas University Department of Pathology Faculty of Medicine, Kars, Türkiye

⁴Yasemen ADALI (Orcid ID: 0000-0002-8004-7364), Izmir University of Economics, Department of Pathology, Faculty of Medicine, Izmir, Türkiye

*Sorumlu Yazar/Corresponding Author: Kezban YILDIZ-DALGINLI, e-mail: kezbandalginli@gmail.com

Etik Kurul Onayı / Ethics Committee Approval: The required permission for the study was obtained by the Local Ethics Committee of Kafkas University Animal Experiments (Approval No: KAU-HADYEK/2019-155).

INTRODUCTION

Cisplatin (cis-dichloro diammine platinum II), a platinum derivative, is a broad-spectrum antineoplastic drug used in the treatment of different types of cancer, including lung cancer (Rabik and Dolan, 2007; Waissbluth et al., 2017). Discovered by Michele Peyrone in 1845 and its chemical structure elucidated by Alfred Werner in 1893, cisplatin is one of the first metal-based chemotherapeutic drugs (Dasari and Tchounwou 2014). In the 1960s, Barnett Rosenberg reported that cisplatin could be used in cancer chemotherapy with his studies (Rosenberg et al., 1965). It has been reported that cisplatin causes serious side effects depending on the dose increase in its anticancer activity (Khan et al., 2012). Cisplatin causes oxidative stress by affecting the lungs, other tissues and organs. Side effects include renal toxicity, nausea, vomiting, as well as fibrosis, interstitial inflammation, structural pulmonary damage, and other serious complications (Leo et al., 2010; Iwasaki et al., 2005; Kosmas et al., 2001). The cis diammineaquachloroplatinum II metabolite is responsible for the toxic effects of cisplatin on the body (Kopke et al., 1997). Studies have suggested that cisplatin produces reactive oxygen species (ROS) and causes tissue damage by reacting with biological macromolecules (Weijl et al., 1997; Halliwell and Chirico, 1993). It has been stated that the antioxidant defense mechanism of cisplatin against oxidative damage is weak by causing a decrease in plasma antioxidant levels in chemotherapy applications. This is due to the consumption of antioxidants caused by oxidative stress in chemotherapy (Weijl et al., 1998).

It has been stated in studies that the use of cisplatin causes many toxic damages such as ototoxicity, nephrotoxicity, neurotoxicity, cardiotoxicity. However, studies investigating its effects on the lungs are limited. In this context, our study was planned to investigate the effects of cisplatin, which is used as an antineoplastic agent, on oxidative/nitrosative stress due to fibrosis in the lungs.

MATERIALS AND METHODS

Chemicals

The cisplatin was purchased from Kocak Farma (50mg/100mL CAS-No. 1923852, Istanbul, Turkey) and other chemicals used in the study were of analytical purity and were purchased from Sigma-Aldrich Co. (St. Louis, MO, USA).

Animals

The required permission for the study was obtained by the Local Ethics Committee of Kafkas University Animal Experiments (Approval No: KAU-HADYK/2019-155). Housing, maintenance, and experimental procedures were carried out at Kafkas University Experimental Animals Production and Experimental Research Center. The animals were kept in conventional rooms with controlled photoperiod (12:12 light:dark, lights on at 06:00 h, approximately 470 lx at 1 m above the floor), temperature (23 ± 2 °C), relative humidity (50-70%) and ventilation (18 air changes h⁻¹). The rats were housed per strain in groups of two animals in wire topped Macrolon type LF-3H cages (800 cm², Kobay Experimental Animals Laboratory, Ankara, Turkey) provided with sawdust bedding ((Tapvei 2H (2x2x1mm) Kobay Experimental Animals Laboratory, Ankara, Turkey), (low dust content in order not to harm the respiratory system of animals easy to remove from cages and it provide a large surface area that is absorbent and capable of taking up and binding both urine and faecal moisture for hygienic reasons)). Tap water and food-pellets (Bayramoglu Feed and Flour Industry and Trade Inc., Erzurum, Turkey) were provided ad libitum. The physical and chemical properties of feed are collectively presented in Table 1. The location of the objects remained the same throughout the experimental period without any contact between the groups. The tissues were renewed with daily cage cleaning.

Five days before the start of a test the mice were brought in their cages to the test room to acclimatise. The same conditions were applied to all groups during the experiment.

Table 1. Feed content

| Feed content | |
|-----------------|------------------|
| Humidity | 12.80 % |
| Crude protein | 23.00 % |
| Crude cellulose | 3.70 % |
| Crude ash | 8.30 % |
| Crude oil | 1.70 % |
| Sodium | 0.50 % |
| Manganese | 96.00 mg/kg |
| Iron | 31.00 mg/kg |
| Zinc | 95.00 mg/kg |
| Cobalt | 0.50 mg/kg |
| Selenium | 0.30 mg/kg |
| Iodine | 2.28 mg/kg |
| Vitamin A | 12.000.000 IU/kg |

Food-pellets (Bayramoglu Feed and Flour Industry and Trade Inc., Erzurum, Turkey) Experimental Design

Experimental Design

Twelve Sprague Dawley male 2 months old rats were used in the study. Subjects were randomly distributed to two groups and rats were weighed for dose calculations. The rats were as follows: Control (n=6) and Cisplatin (n=6) groups. During the experiment, saline was administered intraperitoneally (i.p) to the control group. Cisplatin group was given single dose cisplatin (10 mg/kg i.p). Twenty-four hours after the end of the study period, animals were decapitated under anesthesia with xylazine-ketamine combination (15mg / kg-50mg / kg) i.p was applied to rats and cervical dislocation was applied and the anterior abdominal door was opened with an incision and lung tissues were taken. One of the lungs were washed in cold physiological solution and then stored at -45 °C (deep-freeze) for biochemical analysis. The other lung tissues were taken into 10% buffered formaldehyde for immunohistochemical and pathological examinations.

Reduced glutathione (GSH), malondialdehyde (MDA) and nitric oxide (NO) were determined by spectrophotometric method in the tissues taken (Bio-Tek Eon Winooski, VT, USA). In addition, paraffin blocks were made from lung tissues and stained with hematoxylin-eosin staining. Immunohistochemically, p53 CD3, CD20, Bcl-2 and Ki67 were evaluated.

Preparation of Tissue Homogenates

Fresh tissues were rinsed with ice-cold saline and immediately stored at -45 °C. The tissue specimens were weighed and then homogenized in a phosphate-buffered saline (PBS). Homogenized lung samples were then centrifuged at 10.000 rpm at +4 °C over 15 min to isolate the supernatant for subsequent analysis.

Biochemical Analysis

Determination of Reduced Glutathione Level

Lung tissue levels of GSH were evaluated by using spectrophotometric technique according to the method described by (Beutler et al., 1963). The method established on the reduction of 5, 5 dithiobis (2-nitrobenzoic acid) with GSH to yield a yellow compound. The reduced chromogen directly proportional to GSH concentration and its absorption was measured at 412 nm.

Determination of Malondialdehyde Level

Lipid peroxidation was determined by quantifying MDA content in the tissue supernatants. Thiobarbituric acid (TBA) was added in the reaction mixture after vortexing the contents of the tube. The tubes were kept in a boiling water bath for 1 h. MDA level was determined with the absorption coefficient of MDA–TBA complex at 532 nm using spectrophotometer (Yoshoiko et al., 1979).

Determination of Nitric Oxide Level

Nitric oxide concentrations in lung tissue were determined using a spectrophotometer by the method of (Miranda et al., 2001). The samples were de-proteinized with 10% zinc sulphate. Total NO (nitrate and nitrite) concentrations were measured colorimetrically by acidic Griess reaction via reaction involving reduction of nitrate to nitrite by vanadium (III) chloride.

Determination of Total Protein

Lung total protein concentration was determined by the Bradford method using bovine serum albumin (BSA) as the standard at 595 nm (Bradford, 1976).

Histopathological Analyses

Lung tissues taken for histopathological evaluation were kept in 10% formalin solution for 12 hours and then the tissue was followed up. Tissue follow-up was performed with a closed system Leica ASP300 S (Fully Enclosed Tissue Processor, US) device, and the standard tissue follow-up procedure was followed and embedded in paraffin blocks. Sections of 4 micron thickness were taken from each block with the microtome (Leica RM2255 Fully Automated Rotary Microtome, US). Hematoxylin-Eosin (HE) staining was performed on the sections taken. Sections were examined using a light microscope (Olympus BX46F, Tokyo, Japan).

Immunohistochemical Analysis

For immunohistochemical staining, sections were cut into 3-micron adhesive slides and kept in an oven at 56 °C for 1 night. Then the sections were deparaffinized and the avidin-biotinperoxidase method was used as an immunohistochemical method. Sections to be stained were kept in 3% hydrogen peroxide solution for 15 minutes to prevent endogenous peroxide activity after deparaffinization and dehydration. All tissues used in the study were processed in a microwave oven for 10 minutes in order to reveal antigen structures. After the sections were washed with phosphate buffer solution (PBS), the tissues were soaked in appropriate antibodies of p53, CD3, CD20, Bcl-2 and Ki67 for 2 hours. The sections were then incubated with biotin for 10 minutes at room temperature. All sections were washed with PBS and then incubated with peroxidase-conjugated streptavidin for 10 minutes. As the color revealing substrate, 3,3'-diaminobenzidine tetrahydrochloride (DAB) solution prepared at a ratio of 1/1 was applied to the sections for 5 minutes. Sections were stained with Harris Haematoxylin and washed for 5 minutes. It was then covered with entellan and examined under a light microscope.

Statistical Analysis

Statistical analysis of the data obtained from the study was done using SPSS Windows 16.0 package program (SPSS Inc.). Mean values between groups were determined by one-way analysis of variance (ANOVA) and differences between groups by Duncan test. Data are expressed as mean±SD values.

RESULTS AND DISCUSSION

Biochemical Findings

It was determined that there was a significant increase in NO levels in the lung tissue of rats with a single dose of cisplatin ($P < 0.005$), and there was no significant difference in MDA and GSH levels (Table 2).

Table 2. Effects of control and cisplatin groups on MDA, GSH and NO levels in lung tissues

| Parameters | Control | Cisplatin | P |
|-----------------------|---------------------------|---------------------------|-------|
| NO (nmol/mg protein) | 301.62±12.11 ^b | 427.82±33.65 ^a | 0.005 |
| MDA (nmol/mg protein) | 4.52±0.18 | 4.04±0.25 | Ns |
| GSH (µg/mg protein) | 25.54±0.14 | 25.20±0.25 | Ns |

*: a, b: Significant differences in values between cisplatin and control groups are indicated by different superscript letters, Ns: Not significant.

Histopathological Findings

In the histopathological evaluation of the lung tissue, histological structure was observed in morphological limits with HE staining. In addition, the structure of bronchi and bronchioles, vascular structures and air spaces, inflammation, edema and congestion were evaluated. Statistical analysis was not performed because there was no histopathologically abnormal finding in the lung tissue of rats with a single dose of cisplatin administration (Figure. 1a). When the histopathological sections of the lung tissue of 12 animals given cisplatin were examined under light microscopy; signs of congestion-bleeding were observed intensely (Figure. 1b). When evaluated in terms of inflammation; intense areas of inflammation are present and lymphoid follicle formations are noted. Numerous lymphoid follicles containing reactive germinal centers were seen around the bronchi and bronchioles. The hyperplastic follicular is often located between the arteries and the bronchi/bronchioles, and mild compressions of the bronchiole lumen have been observed in some sections. Lymphocytes often show intense permeation in the adjacent bronchi and bronchiole epithelium. In addition, low-intensity edema secondary to inflammation was noted in the sections. Edema was usually seen in the lumens and sometimes between the alveoli (Figure. 1c). The presence of blood-fibrin and inflammatory cells in the edematous areas was noted. In addition, concentric fibrous and fibrinous plugs consisting of fibroblasts embedded in a loose myxoid matrix were observed in the airways (Figure. 1d).

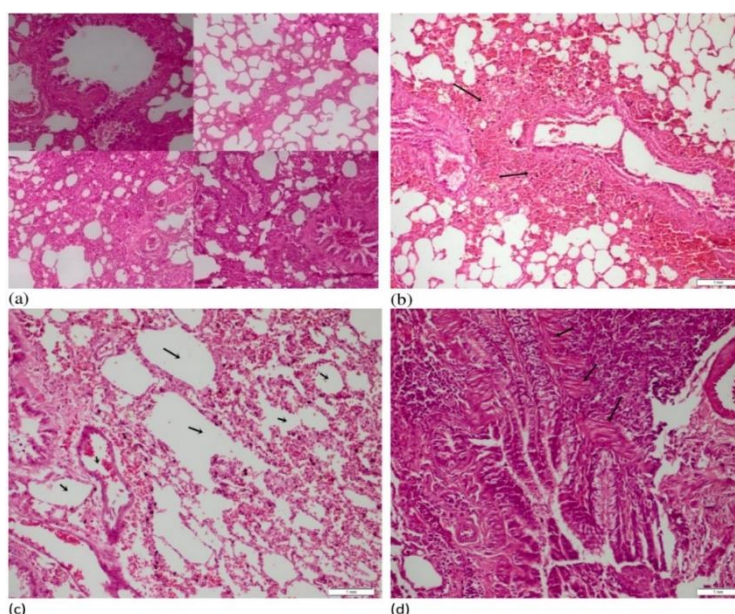


Figure 1. Bronchi and bronchioles, vascular structures and structure of air spaces and signs of inflammation, edema and congestion (HEX40) (a); In the area indicated by the black arrow, the area of intense (3+) bleeding-congestion (HEX400)(b); Intense blood-fibrin formations (black arrows) in areas of edema (HEX200)(c); Fibroblastic plug formation extending into the bronchiolar lumen secondary to intense inflammation (HEX200)(d)

Immunohistochemical Findings

When immunohistochemical data are evaluated; reactive pan B-cell markers CD20 showed positive staining (Figure. 2a). The T-cell marker CD3 in the interstitial component was stained positive by immunohistochemical staining. Reactive germinal centers were stained negatively by Bcl-2 immunohistochemical staining (Figure 2b). Extralobar sequestration areas were noted, and uniform dilated bronchioles and alveolar ducts were noted. The p53 immunohistochemical staining applied to these areas was negative (Figure. 2c, 2d). In p53 immunohistochemistry, stainings below 1% were considered negative, and stainings of 2% and above were considered positive. Evaluations were made in 10 selected high-magnification fields across the entire tissue. Desmin immunohistochemical staining applied to the proliferating areas showed positive staining in the cells under the epithelium (Figure. 2c,d-Figure 3a,b). In addition, low-intensity nuclear staining with Ki67 immunohistochemical staining and cytoplasmic staining in general attracted attention (Figure. 3c).

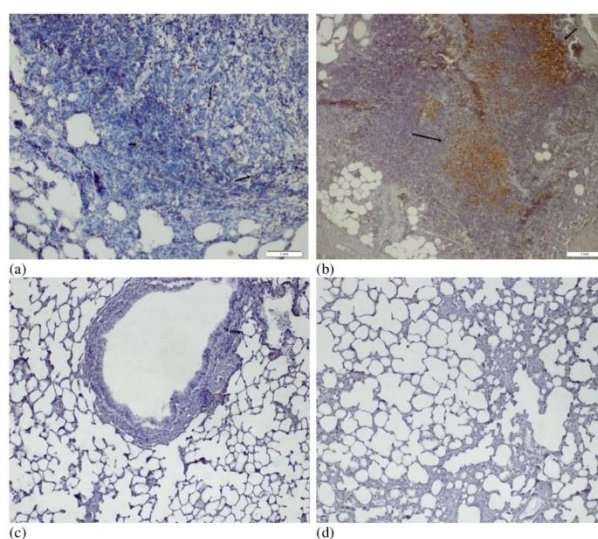


Figure 2. Positive staining of B-lymphocytes by CD20 immunohistochemical staining (black arrows)(CD20X400) (a); It showed a moderate positive reaction especially around the lymphoid formation with CD3 immunohistochemical staining (black arrows) (CD3X200) (b); P53 immunohistochemical negative staining findings (p53X40) (c, d).

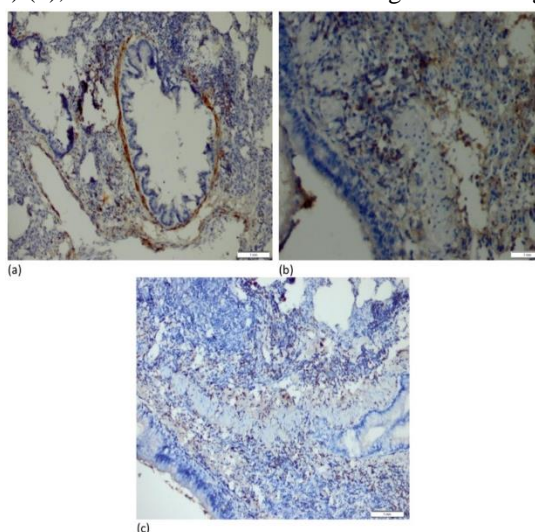


Figure 3. Desmin positive cells under the epithelium (Desminx400)(a); Desmin positive cells under the epithelium (Desminx400)(b); Ki67 immunohistochemical staining of proliferating areas (Ki67X200) (c).

In this study, we reported that cisplatin causes oxidative stress as a result of increasing the NO level of the lung and disrupting the nitrosative balance, and that it causes lung cell damage as a result

of intense inflammation and secondary lymphoid formations. In addition, we demonstrated that the immunohistochemically reactive pan B-cell markers CD20 positive staining, p53, desmin and Ki67 staining, and intense inflammatory cells suppressed neoplastic formation by activating the defense mechanism of the chemical.

It has been proven that various agents increase oxidative/nitrosative levels by showing toxic effects in the cell (Atakisi et al., 2022; Yildiz Dalginli et al., 2022; Gulmez et al., 2020; Kart et al., 2016). Cisplatin, an important cytotoxic agent, triggers oxidative stress and causes damage to the lungs and other tissues and organs (Leo et al., 2010). It is reported that when cisplatin enters the cell, it leads to ROS production through DNA cross-linking, overproduction of oxidases, depletion of endogenous antioxidant systems such as glutathione, and dysfunction of cytoplasmic organelles (Yang et al., 2018). However, it has been shown that cisplatin administration causes local redox imbalance, increases the number of ROS and worsens oxidative stress in the lungs (Han et al., 2021). Studies are continuing on the production of less toxic and more effective analogues of cisplatin. In particular, Pt-based and non-toxic derivatives such as carboplatin are being studied (Ali and Al Moundhri, 2006; Hosseinian et al., 2016).

In previous studies, it was stated that administration of approximately similar doses (7 and 7.5 mg/kg) of cisplatin significantly increased the levels of various oxidative stress MDA, NO and hydrogen peroxide (H₂O₂) markers in the lung tissue, decreased the levels of antioxidant enzymes (superoxide dismutase (SOD), catalase (CAT), peroxidase (POD), quinone reductase (QR), glutathione peroxidase (GPx), γ -glutamyl transpeptidase (γ -GT), glutathione reductase (GR), glutathione-S-transferase (GST), and decreased glutathione (GSH)) and caused severe tissue damage (Afsar et al., 2018; Geyikoglu et al., 2017). It has been stated that free radicals play an important role in cisplatin-induced pulmonary toxicity. Cisplatin administration has also been reported to cause severe degenerations histopathologically, including inflammatory cell infiltrates, changes in the alveolar septum, disruption of connective tissue and elastic fibers, blood vessel occlusion, pulmonary edema, irregular inner epithelium of alveolar bronchioles, fibroblast aggregations, and interstitial hemorrhages (Afsar et al., 2018). In present study, it can be said that the potential of a single dose of cisplatin to affect lung tissue oxidative stress parameters is low. However, a significant increase in NO level is an expression of the onset of cisplatin-induced damage to the lung. Moreover, positive staining of cells under the epithelium was observed with desmin immunohistochemical staining applied to the proliferating areas. Low-intensity nuclear staining with Ki67 immunohistochemical staining, and cytoplasmic staining in general was noted. In addition, lymphoid formations that were formed secondary to intense inflammation, which were warning to chronic antigen, were observed.

Recently, cisplatin-induced lung injury was investigated in rats given 2.5 mg/kg cisplatin for 14 days. It has been reported that cisplatin increases the levels of MDA, myeloperoxidase (MPO) and 8-hydroxy-2 deoxyguanosine (8-OHdG), which are markers of oxidative DNA damage, and decreases the amount of total glutathione (tGSH) in the lung tissue. It was stated that in the cisplatin group, infiltration of polymorphic nuclear leukocytes and hemorrhagic foci, as well as severe alveolar damage such as edema and diffuse alveolar septal fibrosis occurred (Unver et al., 2019). Similarly, the presence of edema and fibrosis supports our study. Unlike our study, this change in oxidant and antioxidant parameters can be associated with the duration and dose of the experiment. In another study, tissue lipid peroxidation, protein carbonyl modification and pathohistological and biochemical changes in xanthine oxidase, caspase-3 and DNAase activities in lung tissues were investigated in rats administered 10 mg/kg cisplatin. In his histopathological examination, it was reported that he was edematous and there were significant deteriorations in the alveolar epithelium. In addition to oxidative

stress parameters, it has been stated that there is a significant increase in the activity of enzymes related to apoptosis (Ristić, et al., 2020). Edema was observed similarly in the histopathological examination of our study. Edema was generally seen in the lumens and sometimes between the alveoli. The presence of blood-fibrin and inflammatory cells in edematous areas and lymphoid follicle formations in areas of intense inflammation were recorded.

Faid (2020) injected rats with 5 mg/kg cisplatin intraperitoneally every 2 days for a total of 8 days. As a result, it was seen that cisplatin administration increased the lung MDA level and decrease the GSH content significantly. At the same time, histopathological examinations observed widespread severe alveolar damage in the lungs of the cisplatin group with diffuse alveolar edema and alveolar septal fibrosis, infiltration of polymorphic nuclear leukocytes, and hemorrhagic foci (Faid, 2020).

CONCLUSION

In the current study, it can be said that the potential of a single dose of cisplatin to affect lung tissue oxidative stress parameters is low. However, a significant increase in NO level is an expression of the onset of cisplatin-induced damage to the lung. It shows that cisplatin induces lung cell damage of blood-fibrin and inflammatory cells and lung lymphoid follicles in areas with edema, and these results may be useful in determining lung damage. Moreover, positive staining of cells under the epithelium was observed with desmin immunohistochemical staining applied to the proliferating areas. In addition, lymphoid formations that were formed secondary to intense inflammation, which were warning to chronic antigen, were observed. This information may be useful for understanding the mechanism of cisplatin toxicity. The presence of dense inflammatory cells suggests that the chemical activates the defense mechanism and suppresses neoplastic formation, and it should be strengthened by further histopathological studies.

Conflict of Interest

The article authors declare that there is no conflict of interest between them.

Author's Contributions

The authors declare that they have contributed equally to the article.

REFERENCES

- Afsar, T., Razak, S., Almajwal, A., & Khan, M.R., (2018). Acacia hydasypica R. Parker ameliorates cisplatin induced oxidative stress, DNA damage and morphological alterations in rat pulmonary tissue. *BMC Complement. Altern. Med.*, 18(1): 49. [https://doi: 10.1186/s12906-018-2113-0](https://doi.org/10.1186/s12906-018-2113-0)
- Ali, B.H., & Al Moundhri, M.S., (2006). Agents ameliorating or augmenting the nephrotoxicity of cisplatin and other platinum compounds: a review of some recent research. *Food Chem. Toxicol.*, 44(8): 1173-1183. [https://doi: 10.1016/j.fct.2006.01.013](https://doi.org/10.1016/j.fct.2006.01.013).
- Atakisi, O., Dalginli, K. Y., Gulmez, C., Kalacay, D., Atakisi, E., Zhumabaeva, T. T., Aşkar, T. K., & Demirdogen, R. E. (2022). The role of reduced glutathione on the activity of adenosine deaminase, antioxidative system, and aluminum and zinc levels in experimental aluminum toxicity. *Biological trace element research*, 10.1007/s12011-022-03503-0. Advance online publication. <https://doi.org/10.1007/s12011-022-03503-0>.
- Beutler, E., Duron, O., & Kelly, B.M., (1963). Improved method for the determination of blood glutathione. *J. Lab. Clin. Med.*, 61: 882-888.
- Bradford, M.M., (1976). A rapid and sensitive method for the quantitation of microgram quantities of protein utilizing the principle of protein-dye binding. *Anal. Biochem.*, 72: 248-254. [https://doi: 10.1006/abio.1976.9999](https://doi.org/10.1006/abio.1976.9999)

- Dasari, S., & Tchounwou, P.B., (2014). Cisplatin in cancer therapy: molecular mechanisms of action. *Eur. J. Pharmacol.*, 5(740): 364-378. [https://doi: 10.1016/j.ejphar.2014.07.025](https://doi.org/10.1016/j.ejphar.2014.07.025).
- Faid, S.M., (2020). Potential protective role of *Melilotus officinalis* extract against Cisplatin-induced cardiac and pulmonary toxicities in rats. *African J. Biol. Sci.*, 16(1): 233-244.
- Geyikoglu, F., Isikgoz, H., Onalan, H., Colak, S., Cerig, S., Bakir, M., Hosseinigouzdagani, M., Koc, K., Erol, H.S., Saglam, Y.S., & Yildirim, S., (2017). Impact of high-dose oleuropein on cisplatin-induced oxidative stress, genotoxicity and pathological changes in rat stomach and lung. *J. Asian Nat. Prod.Res.*, 19(12): 1214–1231. [https://doi: 10.1080/10286020.2017.1317751](https://doi.org/10.1080/10286020.2017.1317751)
- Gulmez, C., Dalginli, K.Y., Atakisi, E., & Atakisi, O., (2020). the protective effect of lactoferrin on adenosine deaminase, nitric oxide and liver enzymes in lipopolysaccharide-induced experimental endotoxemia model in rats. *Kafkas Univ. Vet. Fak. Derg.*, 26(6): 801-806. doi:10.9775/kvfd.2020.24504
- Halliwell, B., & Chirico, S., (1993). Lipid peroxidation: its mechanism, measurement, and significance. *Am. J. Clin. Nutr.*, 57(5): 715S-725S. <https://doi.org/10.1093/ajcn/57.5.715S>
- Han, Y.K., Kim, J.S., Jang, G.B., & Park, K.M., (2021). Cisplatin induces lung cell cilia disruption and lung damage via oxidative stress. *Free Radic. Biol. Med.*, 177:270-277. [https://doi: 10.1016/j.freeradbiomed.2021.10.032](https://doi.org/10.1016/j.freeradbiomed.2021.10.032)
- Hosseinian, S., Rad, A.K., Mousa-Al-RezaHadjzadeh, N.M., Roshan, S.H., & Shafiee, S., (2016). The protective effect of *nigella sativa* against cisplatin-induced nephrotoxicity in rats. *Avicenna J. Phytomed.*, 6(1): 44.
- Iwasaki, Y., Nagata, K., Nakanishi, M., Natuhara, A., Kubota, Y., Ueda, M., Arimoto, T., & Hara, H., (2005). Double-cycle, high-dose ifosfamide, carboplatin, and etoposide followed by peripheral blood stem-cell transplantation for small cell lung cancer. *Chest.*, 128(4): 2268-2273.
- Kart, A., Koc, E., Dalginli, KY., Gulmez, C., Sertcelik, M., & Atakisi, O., (2016). The therapeutic role of glutathione in oxidative stress and oxidative DNA damage caused by hexavalent chromium. *Biol. Trace Elem. Res.*, 174(2): 387-391. [https://doi: 10.1007/s12011-016-0733-0](https://doi.org/10.1007/s12011-016-0733-0)
- Khan, R., Khan, A.Q., Qamar, W., Lateef, A., Ali, F., Rehman, MU., Tahir, M., Sharma, S., & Sultana, S., (2012). Chrysin abrogates cisplatin-induced oxidative stress, p53 expression, goblet cell disintegration and apoptotic responses in the jejunum of Wistar rats. *Br. J. Nutr.*, 108(9): 1574-1585. [https://doi: 10.1017/S0007114511007239](https://doi.org/10.1017/S0007114511007239)
- Kopke, R.D., Liu, W., Gabaizadeh, R., Jacono, A., Feghali, J., Spray, D., Garcia, P., Steinman, H., Malgrange, B., Ruben, R. J., Rybak, L., & Van de Water, T.R., (1997). Use of organotypic cultures of Corti's organ to study the protective effects of antioxidant molecules on cisplatin-induced damage of auditory hair cells. *Am. J. Otol.*, 18(5): 559-571.
- Kosmas, C., Tsavaris, N.B., Malamos, N.A., Vadiaka, M., & Koufos, C., (2001). Phase II study of paclitaxel, ifosfamide, and cisplatin as second-line treatment in relapsed small-cell lung cancer. *J. Clin. Oncol.*, 19(1): 119-126. [https://doi: 10.1200/JCO.2001.19.1.119](https://doi.org/10.1200/JCO.2001.19.1.119)
- Leo, F., Pelosi, G., Sonzogni, A., Chilosi, M., Bonomo, G., & Spaggiari, L., (2010). Structural lung damage after chemotherapy: fact or fiction? *Lung Cancer*, 67(3): 306-310. [https://doi: 10.1016/j.lungcan.2009.04.013](https://doi.org/10.1016/j.lungcan.2009.04.013)
- Miranda, K.M., Espey, M.G., & Wink, D.A., (2001). A rapid, simple spectrophotometric method for simultaneous detection of nitrate and nitrite. *Nitric Oxide*, 5:62-71. [https://doi: 10.1006/niox.2000.0319](https://doi.org/10.1006/niox.2000.0319)
- Rabik, C.A., & Dolan, M.E., (2007). Molecular mechanisms of resistance and toxicity associated with platinating agents. *Cancer Treat. Rev.*, 33(1): 9-23. [https://doi: 10.1016/j.ctrv.2006.09.006](https://doi.org/10.1016/j.ctrv.2006.09.006)
- Ristić, L., Rančić, M., Radović, M., Krtinić, D., Pavlović, M., Ilić, B., Milojković, M., Živković, N., Turković, K., & Sokolović, D., (2020). Melatonin inhibits apoptosis and oxidative tissue damage in cisplatin-induced pulmonary toxicity in rats. *Arch. Med. Sci.*, <https://doi.org/10.5114/aoms.2020.95952>
- Rosenberg, B., Vancamp, L., & Krigas, T., (1965). Inhibition of cell division in *Escherichia coli* by electrolysis products from a platinum electrode. *Nature*, 205: 698-699. [https://doi: 10.1038/205698a0](https://doi.org/10.1038/205698a0)

- Unver, E., Tosun, M., Olmez, H., Kuzucu, M., Cimen, F. K., & Suleyman, Z., (2019). The effect of taxifolin on cisplatin-induced pulmonary damage in rats: a biochemical and histopathological evaluation. *Mediators Inflamm.*, 3740867. [https://doi: 10.1155/2019/3740867](https://doi.org/10.1155/2019/3740867). eCollection 2019
- Waissbluth, S., Peleva, E., & Daniel, S.J., (2017). Platinum-induced ototoxicity: a review of prevailing ototoxicity criteria. *Eur. Arch. Otorhinolaryngol.*, 274(3): 1187-1196. [https://doi: 10.1007/s00405-016-4117-z](https://doi.org/10.1007/s00405-016-4117-z)
- Weijl, N.I., Cleton, F.J., & Osanto, S., (1997). Free radicals and antioxidants in chemotherapy-induced toxicity. *Cancer Treat Rev.*, 23:209-240. [https://doi: 10.1016/s0305-7372\(97\)90012-8](https://doi.org/10.1016/s0305-7372(97)90012-8)
- Weijl, N.I., Hopman, G.D., Wipkink-Bakker, A., Lentjes, E.G., Berger, H.M., Cleton, F.J., & Osanto, S., (1998). Cisplatin combination chemotherapy induces a fall in plasma antioxidants of cancer patients, *Ann. Oncol.*, 9(12): 1331-1337. [https://doi: 10.1023/a:1008407014084](https://doi.org/10.1023/a:1008407014084)
- Yang, Q. Sun. G., Yin, H., Li H., Cao, Z., Wang, J., Zhou M., Wang, H., & Li J., (2018). PINK1 protects auditory hair cells and spiral ganglion neurons from cisplatin-induced ototoxicity via inducing autophagy and inhibiting JNK signaling pathway. *Free Radic. Biol. Med.*, 120:342-355, <https://doi.org/10.1016/j.freeradbiomed.2018.02.025>
- Yildiz Dalginli K., Gulmez, C., Atakisi, E., & Atakisi, O., (2022). Lactoferrin modulates increased liver DNA damage by reducing serum cytokine, hepcidin and iron levels in lipopolysaccharide-induced endotoxemia in rats. *Studia Univ. Babeş-Bolyai. Chemia.*, 67(1): 165-176.
- Yoshoiko, T., Kawada, K., Shimada, T., & Mori, M., (1979). Lipid peroxidation in maternal and cord blood and protective mechanism against active oxygen toxicity in the blood. *Am. J. Obstet. Gynecol.*, 135: 372-376. [https://doi: 10.1016/0002-9378\(79\)90708-7](https://doi.org/10.1016/0002-9378(79)90708-7).