


# Morphological and Biochemical Investigation of the Protective Effects of *Panax ginseng* on Methotrexate-Induced Testicular Damage

Fatma Bedia Karakaya-Cimen<sup>1,2,3</sup>,  Caglar Macit<sup>4</sup>,  Guzin Goksun Sivas<sup>5</sup>,   
Tugba Tunali Akbay<sup>5</sup>,  Goksel Sener<sup>6</sup>,  Feriha Ercan<sup>2</sup> 

<sup>1</sup>Marmara University, Institute of Health Sciences, Department of Histology and Embryology, Istanbul, Turkiye

<sup>2</sup>Marmara University, School of Medicine, Department of Histology and Embryology, Istanbul, Turkiye

<sup>3</sup>Bezmialem Vakif University, School of Medicine, Department of Histology and Embryology, Istanbul, Turkiye

<sup>4</sup>Istanbul Medipol University, School of Pharmacy, Department of Pharmacology, Istanbul, Turkiye

<sup>5</sup>Marmara University, Faculty of Dentistry, Basic Medical Sciences, Department of Basic Health Sciences, Istanbul, Turkiye

<sup>6</sup>Fenerbahce University, School of Pharmacy, Department of Pharmacology, Istanbul, Turkiye

## ABSTRACT

**Objective:** Methotrexate (MTX) is a chemotherapeutic agent that causes testicular toxicity used in the cure of various types of cancer. The anti-oxidant and anti-cancer effects of *Panax ginseng* (PxG) have been reported in both experimental and clinical studies. This study aims to examine the healing effect of PxG on testicular damage induced by MTX.

**Materials and Methods:** Sprague Dawley male rats (8-week-olds) were used in the study. A single dose of MTX dissolved in saline (20 mg/kg) was given to MTX and MTX+PxG groups by intraperitoneal injection. PxG dissolved in saline (100 mg/kg) was given by orogastric gavage once a day for 5 days to the MTX+PxG group. Saline was given to the control and MTX groups orally during the experiments. After decapitation, the testis samples were obtained. Seminiferous tubules and basement membrane were evaluated histopathologically. Seminiferous tubule diameter and germinal epithelium thickness were measured. Furthermore, oxidative stress parameters such as malondialdehyde, glutathione, superoxide dismutase, and glutathione-S-transferase were measured.

**Results:** MTX treatment caused seminiferous tubule degeneration with a decrease in Johnsen's score, the seminiferous tubule's diameter, and the germinal epithelium's thickness. Parallel with the histopathological results increased testicular oxidative stress with an increase in malondialdehyde level and a decrease of endogenous anti-oxidant activity with a decrease in glutathione level and glutathione-S-transferase and superoxide dismutase activities. PxG treatment improved these histological and biochemical parameters in MTX-induced testis cytotoxicity.

**Conclusion:** MTX treatment causes testicular damage via the oxidative processes. PxG treatment ameliorates MTX-induced testicular damage by inhibiting oxidative stress.

**Keywords:** Methotrexate, *Panax ginseng*, testis, oxidative stress

## INTRODUCTION

Methotrexate (MTX) is a folate antagonist often used in various types of cancer such as osteosarcoma, acute lymphoblastic leukemia, head and neck tumors, and inflammatory processes such as rheumatoid arthritis, psoriatic arthritis, and systemic lupus erythematosus.<sup>1–4</sup> It has been shown to have toxic effects on the bone marrow, liver, lung, kidney, intestine, central nervous system, and gonads, and also cause drug toxicity leading to chronic testicular damage.<sup>1–7</sup> Therefore, numerous studies have been conducted on the prevention of testicular damage caused by MTX. It has been shown that MTX reduces testicular sperm

count and motility, causes DNA damage in sperm, atrophy in seminiferous tubules, and apoptosis in spermatocytes, these damages are related to an increase of reactive oxygen species (ROS).<sup>3–4</sup> Therefore, anti-oxidant-containing compounds may help the protection of testis against the harmful effects of MTX-induced oxidative stress.<sup>3–8</sup>

In recent studies, various antioxidants have been used to decrease the side effects associated with MTX application.<sup>2,4,6–10</sup> *Panax ginseng* (PxG) a powerful anti-oxidant belonging to the Araliaceae family, is a medicinal herb, widely used especially in Southeast Asia.<sup>9</sup> PxG contains ginsenosides, saponins, non-

**Corresponding Author:** Feriha Ercan E-mail: eferiha@hotmail.com; fercan@marmara.edu.tr

Submitted: 27.01.2023 • Revision Requested: 11.05.2023 • Last Revision Received: 22.05.2023 • Accepted: 24.05.2023



This article is licensed under a Creative Commons Attribution-NonCommercial 4.0 International License (CC BY-NC 4.0)

saponins, oils, phytosterols, polysaccharides, vitamins, minerals, enzymes, and organic acids.<sup>11-12</sup> The pharmacological effects of PxG have been demonstrated in the cardiovascular, immune, endocrine, and central nervous systems.<sup>13</sup> PxG and its components have also shown anti-diabetic, anti-hypertensive, anti-inflammatory, anti-tumor, anti-apoptotic, anti-stress, and anti-aging properties.<sup>13-15</sup> In addition, Ginseng extract protects the testicular and erectile function.<sup>16-17</sup> It has been shown to stimulate spermatogenesis, increase sperm survival rate, motility, and quality, and prevent erectile dysfunction in animal models.<sup>17</sup> It has been also noted that anti-oxidant, anti-apoptotic effects of PxG on cisplatin-induced testicular toxicity.<sup>18</sup>

It aimed to investigate the anti-oxidant effects of PxG extract on MTX-induced testicular damage in rats in this study. Testicular histopathological damage was evaluated using histopathological Johnsen's score. Testicular oxidative damage was evaluated by estimating malondialdehyde (MDA) and glutathione (GSH) levels and glutathione *S* transferase (GST), and superoxide dismutase (SOD) activities using biochemical methods.

## MATERIALS AND METHODS

### Experimental Animals

Sprague Dawley male rats (8-week-olds, 250-300 gr) were obtained from the İstanbul Medeniyet University, Science and Advanced Technologies Research Center (BİLTAM), Laboratory Animal Care Unit. During the study, they were kept in a laboratory environment with ventilation (air exchange 18 h/h), 12 h light/dark cycle, humidity (50-60%), and temperature (23-25°C). The rats accessed food and water *ad libitum*. This study was confirmed by The Animal Care and Ethical Committee for Experimental Animals at Marmara University (37.2022.mar).

### Experimental Groups

Animals were randomly divided into three groups (n=8 in each group) as control, MTX, and MTX+PxG. A single dose of MTX dissolved in saline (20 mg/kg) was applied to MTX<sup>19</sup> and MTX+PxG groups by intraperitoneal injection. PxG dissolved in saline (100 mg/kg) was given orally once a day for 5 days to the MTX+PxG group.<sup>20,21</sup> Saline was given by orogastric gavage to the control and MTX groups during the experiment. PxG was purchased from "Naturel Kimya" by Casel İlaç Sanayi and kindly donated to us. Animals were decapitated under light ether anesthesia, and testes were obtained at the end of the experiment for histological and biochemical investigations.

### Light Microscopic Preparation

Testis samples were fixed with 10% formalin and processed for the routine paraffin embedding method. Paraffin sections

(4  $\mu$ m in thickness) were stained with hematoxylin and eosin (H&E) for histopathological investigation, and periodic acid Schiff (PAS) reaction for investigation of basement membrane and examined under an Olympus BX51 (Tokyo, Japan) photomicroscope. In each H&E-stained section, the diameter of seminiferous tubules and thickness of germinal epithelium were measured using Image J (NIH-USA) program in 20 seminiferous tubules. Also, these tubules were evaluated histopathologically using Johnsen's scoring criteria as follows: 10: Full spermatogenesis; 9: Slightly disturbed spermatogenesis and many spermatozoa; 8: A few spermatozoa; 6: A few spermatids; 5: Many spermatocytes, but the absence of spermatozoa or spermatids; 4: A few spermatocytes; 3: Only spermatogonia; 2: Only Sertoli cells and absence of germinal cells; 1: Absence of germinal epithelium.<sup>22,23</sup> According to these criteria, using a scale ranging seminiferous tubules was scored from ten (complete full spermatogenesis) to one (absence of germinal epithelium). In PAS-stained sections, PAS-positive staining intensity of basement membrane was scored semiquantitatively as follows: 3: strong; 2: moderate; 1: weak, and 0: absence.

### Measurement of MDA and GSH Levels, GST, and SOD Activities

Testis tissue homogenates in physiological saline were prepared using a glass homogenizer. The cooling process during homogenization was done by immersing a glass homogenizer into a beaker containing ice. Tissue homogenates were then centrifuged at 3000xg for 10 min. The supernatant samples were used for the measurement of MDA and GSH levels, and GST and SOD activities.<sup>24-27</sup>

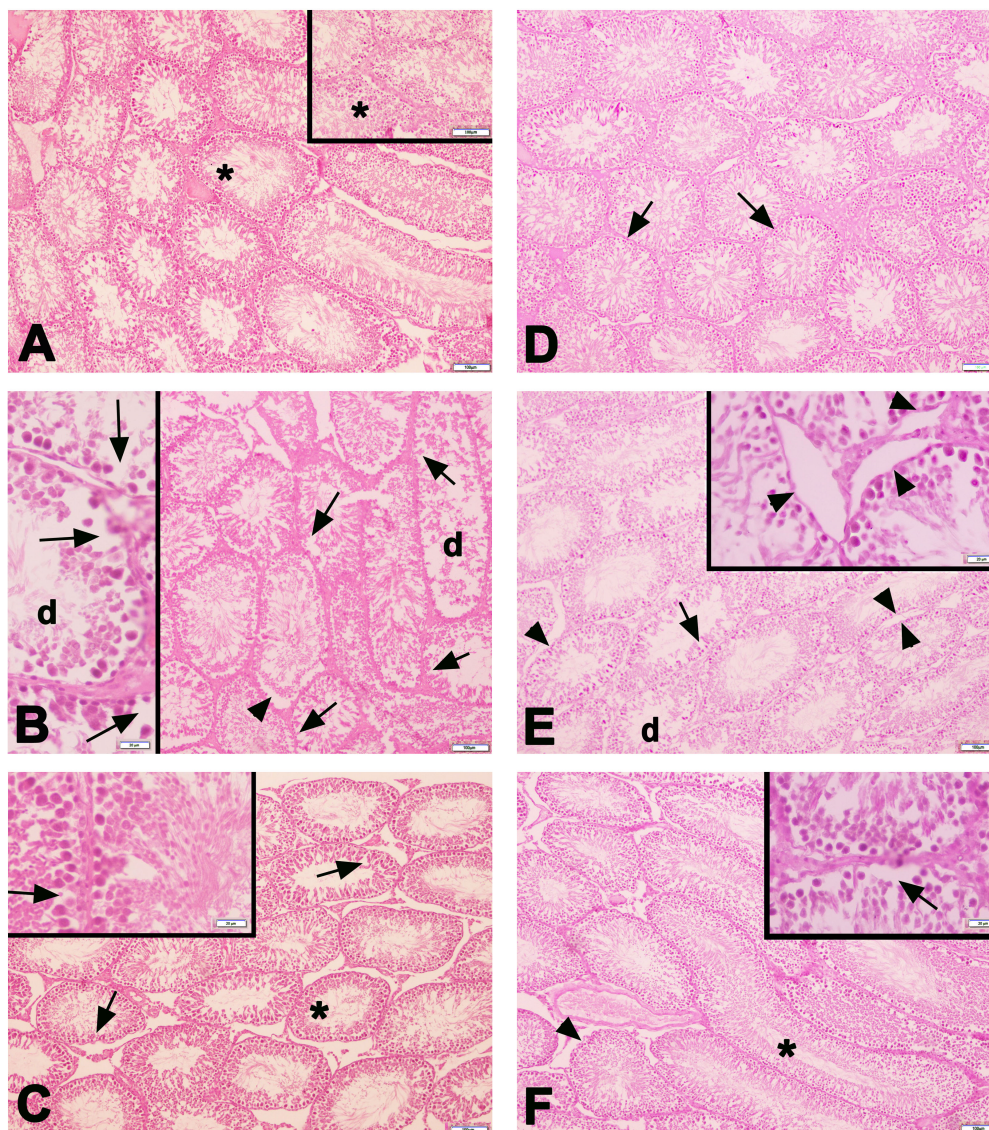
### Statistical Analysis

The histological and biochemical analyses were done by the researchers who were blinded to the experimental groups. One-way analysis of variance was used for analysis of the data and Tukey's multiple comparisons test was used to determine the differences between groups. The results were expressed as mean  $\pm$  standard deviation (SD). Analysis was estimated by Graph Pad Prism Version 8.0 (Graph Pad Software, San Diego, USA). A p<0.05 level was considered significant.

## RESULTS

### Histopathological Results

In the control group, basement membrane contours and germinal epithelial arrangement of the seminiferous tubules were normal, and a large number of sperm were seen in the seminiferous tubule lumen. In the MTX group, dilatations in the tubule epithelium, a decrease in the germinal cell line, basement membrane irregularity, and extensive dilatations between



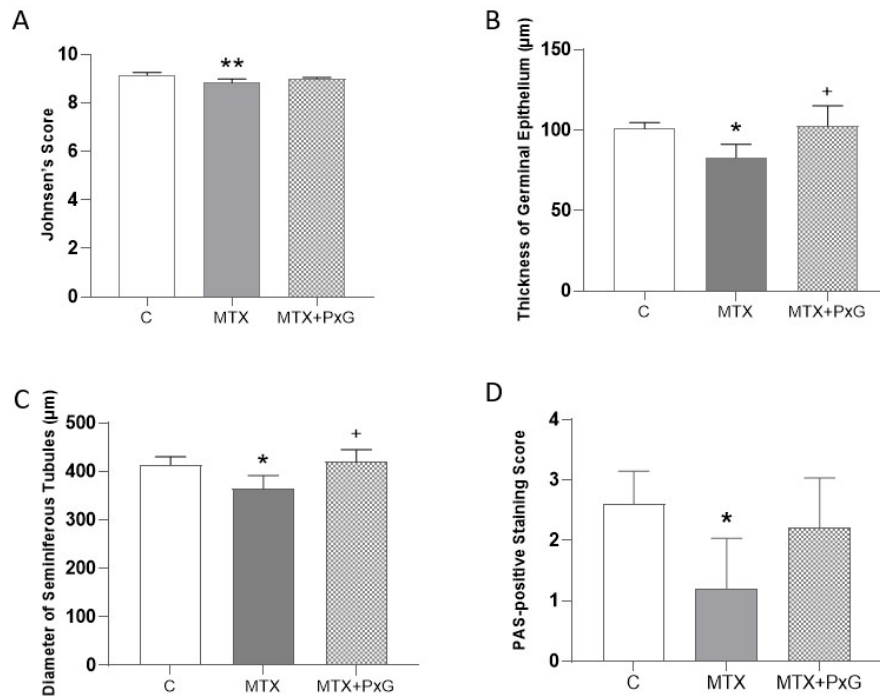
**Figure 1.** Representative light micrographs of testis samples are seen in the experimental groups. Normal seminiferous tubules morphology (\*) with regular PAS-positive basement membrane (arrow) is seen in the control group (A, D). Dilatations (arrow) among the germinal epithelial cells, degenerated tubules (d), and PAS-positive stained irregular basement membrane (arrowhead) are observed in the MTX group (B, E). Numerous quite regular seminiferous tubules morphology (\*) and some degenerated seminiferous tubules with germinal epithelial dilatation (arrow) and PAS-positive stained irregular basement membrane (arrowhead), are seen in the MTX+PxG group (C, F). A-C: H&E staining, D-F: PAS staining. Scale bar: 100  $\mu$ m, insets: 20  $\mu$ m.

the seminiferous tubules and degenerated tubule structures were observed. Although dilatations in the seminiferous tubules and irregularities in the germinal epithelium were detected in some places, numerous quite regular seminiferous tubules were seen in the MTX+PxG group (Figure 1). Histopathological Johnsen's score ( $p < 0.01$ ), the thickness of germinal epithelium ( $p < 0.05$ ), the diameter of seminiferous tubules ( $p < 0.05$ ), and PAS-positive staining intensity score of basement membrane ( $p < 0.05$ ) were decreased in the MTX group compared to the control group. Thickness of germinal epithelium ( $p < 0.05$ ), and diameter of seminiferous tubules ( $p < 0.05$ ) were increased in the MTX+PxG group compared to the MTX group. Although

the histopathological Johnsen's score and PAS-positive staining intensity of the basement membrane tended to increase, no statistical significance was found between these groups (Figure 2).

#### MDA and GSH Levels and GST and SOD Activities Results

Testis MDA level ( $p < 0.001$ ) increased, and GSH level ( $p < 0.01$ ) and GST ( $p < 0.001$ ) and SOD ( $p < 0.001$ ) activities reduced in the MTX group in comparison with the control group. The administration of PxG to the MTX group significantly reduced testis



**Figure 2.** Johnsen's histopathological score (A), the thickness of germinal epithelium (B), the diameter of seminiferous tubules (C), and the PAS-positive staining intensity score of basement membrane (D) are seen in the experimental groups. \*  $p < 0.05$  and \*\* $p < 0.01$  compared to control group. +  $p < 0.05$  compared to the MTX group.

MDA level ( $p < 0.001$ ) while increasing GSH level ( $p < 0.05$ ), and GST ( $p < 0.001$ ) and SOD ( $p < 0.01$ ) activities (Figure 3).

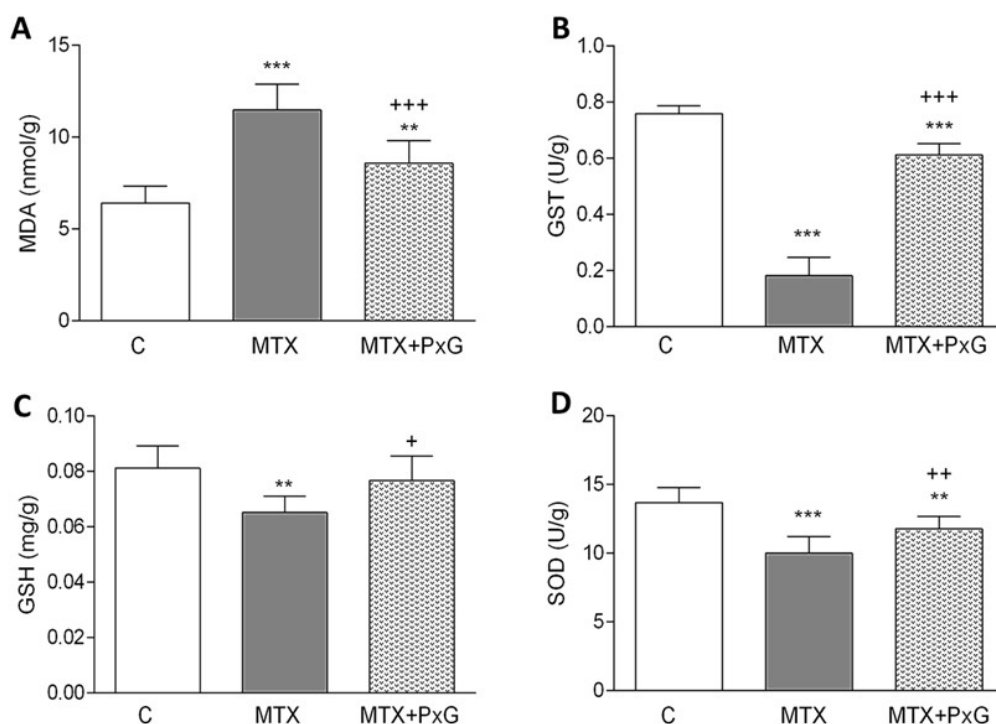
## DISCUSSION

In this study, attenuating effects of PxG on MTX-induced testicular injury were shown by histological and biochemical techniques. The findings of this study showed that MTX treatment led to seminiferous tubule degeneration with a decrease in seminiferous tubule diameter, germinal epithelial thickness, PAS-positive staining intensity of basement membrane, and histopathological Johnsen's score. Parallel with the histopathological results, it was determined that the testicular oxidative stress increased with the increase in MDA level and the endogenous anti-oxidant activity decreased with the decrease in the GSH level and GST and SOD activities.

Free radicals and lipid peroxidation are the two leading factors in MTX-induced testicular pathology.<sup>28</sup> Intensive production of free radicals results in increased lipid peroxidation. Lipid peroxidation also leads to the oxidation of polyunsaturated fatty acids.<sup>29</sup> Testicular toxicity is a serious side effect of MTX.<sup>6-8</sup> The testis, in particular, is highly sensitive to oxidative injury because of containing high polyunsaturated fatty acids. Oxidative stress is a major pathogenic factor of MTX-induced testicular damage. MTX is not capable of redox but

indirectly contributes to the generation of oxidative stress. The oxidation/anti-oxidant balance is inhibited by external stimuli, thus increasing the level of ROS.<sup>4</sup> The increase in ROS disrupts the functioning of the male genital system, leading to infertility. For this reason, antioxidants are needed to preserve the body from oxidative stress injury.<sup>30</sup> Vardi et al<sup>7</sup> revealed that MTX reduces the effectiveness of the anti-oxidant enzyme system and causes destructive changes in the testicles by making cells vulnerable to the harmful effects of ROS. In this study, PxG extract administration ameliorated the MTX-induced testis damage. It is thought that the reason for this improvement is the increase in the anti-oxidant capacity of the testicular tissue with the application of PxG extract and the decrease in oxidative damage in the testicular tissue, which is also reflected in the histological results.

In recent years, PxG's anti-oxidant and anti-cancer effects, as well as its effects on improving immunity, energy, and sexuality and fighting cardiovascular diseases, diabetes, and neurological diseases have been investigated in both experimental and clinical studies.<sup>13,15</sup> The positive effects of the use of PxG on testicular morphology, sperm parameters, reproductive functions, and libido have been demonstrated in various damages.<sup>31,32</sup> Several modern medicines originate from traditional medicines.<sup>33</sup> Ginseng is used in clinical settings all over the world<sup>34</sup> and holds promise for the development of new therapeutic agents.<sup>35</sup> For



**Figure 3.** Testicular MDA (A), GST (B), GSH (C), and SOD (D) levels are seen in the experimental groups. \*\* $p < 0.01$  and \*\*\*  $p < 0.001$  compared to control group. +  $p < 0.05$ , ++  $p < 0.01$  and +++  $p < 0.001$  compared to MTX group.

this reason, in this study, the therapeutic effects of PxG against testicular damage caused by MTX application were examined histologically and biochemically.

MTX causes cellular and mitochondrial glutathione depletion by altering the redox properties of the cell resulting in a dose-dependent increase in peroxide levels, which confers immunosuppressive properties to MTX.<sup>36</sup> Oxidative stress injury results from an imbalance between oxidants and antioxidants and leads to many cytopathological alterations. MTX toxicity causes free radical formation and lipid peroxidation resulting from oxidative cellular damage.<sup>37</sup> It also suppresses antioxidants and increases oxidant levels in various tissues.<sup>38</sup> It has been reported that MTX administration causes severe degeneration of seminiferous tubules with epithelial vacuolization, desquamation, decrease in spermatogenic cells, increase number of apoptotic cells, and separation of germinal epithelium from the basement membrane and alteration in sperm parameters.<sup>6</sup> In the pilocarpine-induced temporal lobe epilepsy model, ginseng application improved seminiferous tubule morphological disorders and decrease sperm count that occurs with epilepsy.<sup>9</sup> It was reported that PxG treatment ameliorated cisplatin-induced testicular damage via inhibiting oxidative stress formation.<sup>18</sup> In another study investigating the effect of ginseng on testicular damage caused by aging, it was reported that ginseng application improved the morphological deteriorations that occur with aging.<sup>39</sup> Parallel with these find-

ings, degenerated seminiferous tubules with dilatation in the germinal epithelium, decrease in germ cell number and germinal epithelium thickness, basement membrane irregularity with decrease of PAS-positive staining intensity were observed in the MTX group. PxG application improved these histopathological damages thanks to its anti-oxidant properties.

## CONCLUSION

Based on the histological and biochemical findings of this study, MTX administration caused degeneration in seminiferous tubules with dilatation among the germinal epithelial cells and irregular basement membrane and decrease of PAS-positive staining intensity, germinal epithelium thickness, Johnsen's score, decreased endogenous GSH level, GST and SOD activities and increased MDA level in rat testis. PxG treatment ameliorated MTX-induced testicular damage by inhibiting oxidative stress through its anti-oxidant properties.

**Ethics Committee Approval:** This study was approved by The Animal Care and Ethical Committee for Experimental Animals at Marmara University (37.2022.mar).

**Informed Consent:** Written consent was obtained from the participants.

**Author Contributions:** Conception/Design of Study- C.M., G.S., F.E.; Data Acquisition- F.B.K.C., C.M., G.G.S., T.T.A.,

G.S., F.E.; Data Analysis/Interpretation- F.B.K.C., C.M., G.G.S., T.T.A., G.S., F.E.; Drafting Manuscript- F.B.K., F.E.; Critical Revision of Manuscript- F.B.K.C., T.T.A., G.S., F.E.; Final Approval and Accountability- F.B.K.C., C.M., G.G.S., T.T.A., G.S., F.E.

**Conflict of Interest:** Authors declared no conflict of interest.

**Financial Disclosure:** This study was financially supported by Marmara University, Scientific Research Project Committee (TDK-2020-10047).

#### ORCID IDs of the authors

Fatma Bedia Karakaya-Cimen	0000-0001-6054-0752
Caglar Macit	0000-0002-5532-2395
Guzin Goksun Sivas	0000-0001-7347-490X
Tugba Tunali Akbay	0000-0002-2091-9298
Goksel Sener	0000-0001-7444-6193
Feriha Ercan	0000-0003-2339-5669

#### REFERENCES

- Hamed KM, Dighriri IM, Baomar AF, et al. Overview of Methotrexate Toxicity: A Comprehensive Literature Review. *Cureus*. 2022;14(9):e29518. doi:10.7759/cureus.29518
- Bleyer WA. Methotrexate: clinical pharmacology, current status and therapeutic guidelines. *Cancer Treat Rev*. 1977;4(2):87-101.
- Pinar N, Cakirca G, Ozgur T, Kaplan M. The protective effects of alpha lipoic acid on methotrexate induced testis injury in rats. *Biomed Pharmacother*. 2018;97:1486-1492.
- Wang Y, Zhao TT, Zhao HY, Wang H. Melatonin protects methotrexate-induced testicular injury in rats. *Eur Rev Med Pharmacol Sci*. 2018;22(21):7517-7525.
- Abdelhameed RFA, Fattah SA, Mehanna ET, et al. Zygo-Albuside A: New Saponin from *Zygophyllum album* L. with significant antioxidant, anti-inflammatory and antiapoptotic effects against methotrexate-induced testicular damage. *Int J Mol Sci*. 2022;23(18):10799. doi:10.3390/ijms231810799
- Kanpalta F, Ozbeyli D, Sen A, Cevik O, Sener G, Ercan F. Bitter melon (*Momordica charantia*) fruit extract ameliorates methotrexate-induced reproductive toxicity in male rats. *Marmara Med J*. 2021;34(3):222-228.
- Vardi N, Parlakpinar H, Ates B, Cetin A, Otlu A. Antiapoptotic and antioxidant effects of beta-carotene against methotrexate-induced testicular injury. *Fertil Steril*. 2009;92(6):2028-2033.
- Armagan A, Uzar E, Uz E, et al. Caffeic acid phenethyl ester modulates methotrexate-induced oxidative stress in testes of rat. *Hum Exp Toxicol*. 2008;27(7):547-552.
- Ganjkhani M, Nourozi S, Bigonah R, Rostami A, Shokri S. Ameliorating impacts of ginseng on the apoptosis of spermatogenic cells and sperm quality in temporal lobe epilepsy rat model treated with valproate. *Andrologia*. 2019;51(9):e13348. doi: 10.1111/and.13348.
- Padmanabhan S, Tripathi DN, Vikram A, Ramarao P, Jena GB. Methotrexate-induced cytotoxicity and genotoxicity in germ cells of mice: intervention of folic and folinic acid. *Mutat Res*. 2009;673(1):43-52.
- Ernst E. Panax ginseng: an overview of the clinical evidence. *J Ginseng Res*. 2010;34(4):259-263.
- Ratan ZA, Haidere MF, Hong YH, et al. Pharmacological potential of ginseng and its major component ginsenosides. *J Ginseng Res*. 2021;45(2):199-210.
- Liu CX, Xiao PG. Recent advances on ginseng research in China. *J Ethnopharmacol*. 1992;36(1):27-38.
- Lu J-M, Yao Q, Chen C. Ginseng compounds: an update on their molecular mechanisms and medical applications. *Curr Vasc Pharmacol*. 2009;7(3):293-302.
- Yue PY, Mak NK, Cheng YK, et al. Pharmacogenomics and the Yin/Yang actions of ginseng: anti-tumor, angiomodulating and steroid-like activities of ginsenosides. *Chin Med*. 2007;2:6. doi: 10.1186/1749-8546-2-6.
- Kim W, Hwang S, Lee H, Song H, Kim S. Panax ginseng protects the testis against 2,3,7, 8-tetrachlorodibenzo-p-dioxin induced testicular damage in guinea pigs. *BJU Int*. 1999;83(7):842-849.
- Wanderley MI, Saraiva KL, Cesar Vieira JS, Peixoto CA, Udrisar DP. Foetal exposure to Panax ginseng extract reverts the effects of prenatal dexamethasone in the synthesis of testosterone by Leydig cells of the adult rat. *Int J Exp Pathol*. 2013;94(3):230-240.
- Aslan E, Kumalar K, Güzel H, Demirel HH, Çelik S, Pektaş MB. Effects of Panax ginseng on cisplatin-induced testicular damage of rats. *Ant J Bot*. 2021;5(1):37-43.
- Uzar E, Sahin O, Koyuncuoglu HR, et al. The activity of adenosine deaminase and the level of nitric oxide in spinal cord of methotrexate administered rats: protective effect of caffeic acid phenethyl ester. *Toxicology*. 2006;218(2-3):125-133.
- Qiao C, Den R, Kudo K, et al. Ginseng enhances contextual fear conditioning and neurogenesis in rats. *Neurosci Res*. 2005;51(1):31-38.
- Koşmaz K, Durhan A, Şenlikçi A, et al. Evaluation of the protective effect of Red Ginseng on lipid profile, endothelial and oxidative damage after splenectomy in rats. *Arch Clin Exp Med*. 2021;6(2):43-49.
- Johnsen SG. Testicular biopsy score count—a method for registration of spermatogenesis in human testes: normal values and results in 335 hypogonadal males. *Hormones*. 1970;1(1):2-25.
- Elmas MA, Ozakpinar OB, Kolgazi M, Sener G, Arbak S, Ercan F. Exercise improves testicular morphology and oxidative stress parameters in rats with testicular damage induced by a high-fat diet. *Andrologia*. 2022;54(11):e14600. doi:10.1111/and.14600.
- Fujii S, Dale GL, Beutler E. Glutathione-dependent protection against oxidative damage of the human red cell membrane. *Blood*. 1984;63(5):1096-1101.
- Habig WH, Jakoby WB. Assays for differentiation of glutathione S-Transferases. *Methods Enzymol*. 1981;77:398-405.
- Ledwozyw A, Michalak J, Stepień A, Kadziółka A. The relationship between plasma triglycerides, cholesterol, total lipids and lipid peroxidation products during human atherosclerosis. *Clin Chim Acta*. 1986;155(3):275-283.
- Mylroie AA, Collins H, Umbles C, Kyle J. Erythrocyte superoxide dismutase activity and other parameters of copper status in rats ingesting lead acetate. *Toxicol Appl Pharmacol*. 1986;82(3):512-520.
- Tracey WR, Linden J, Peach MJ, Johns RA. Comparison of spectrophotometric and biological assays for nitric oxide (NO) and endothelium-derived relaxing factor (EDRF): nonspecificity of the diazotization reaction for NO and failure to detect EDRF. *J Pharmacol Exp Ther*. 1990;252(3):922-928.
- Rikans LE, Hornbrook KR. Lipid peroxidation, antioxidant pro-

- tection and aging. *Biochim Biophys Acta*. 1997;1362(2-3):116-127.
30. Koroglu KM, Cevik O, Sener G, Ercan F. Apocynin alleviates cisplatin-induced testicular cytotoxicity by regulating oxidative stress and apoptosis in rats. *Andrologia*. 2019;51(4):e13227. doi:10.1111/and.13227.
  31. Leung KW, Wong AS. Ginseng and male reproductive function. *Spermatogenesis*. 2013;3(3):e26391. doi:10.4161/spmg.26391.
  32. Sanad NH, Abbas HR, Yaseen AA, Habeeb IA, Alsalm HA. Hormonal, histological, and comparative study of the effect of pure ginseng on testicular function in the breeding/non-breeding season of rams in Basrah. *Arch Razi Inst*. 2021;76(5):1519-1535.
  33. Thomford NE, Senthebane DA, Rowe A, et al. Natural products for drug discovery in the 21st century: Innovations for novel drug discovery. *Int J Mol Sci*. 2018;19(6):1578.
  34. He Y, Yang J, Lv Y, et al. A Review of Ginseng Clinical Trials Registered in the WHO international clinical trials registry platform. *Biomed Res Int*. 2018;2018:1843142. doi:10.1155/2018/1843142.
  35. Wee JJ, Mee Park K, Chung AS. Biological activities of Ginseng and its application to human health. In: Benzie IFF, Wachtel-Galor S, eds. *Herbal Medicine: Biomolecular and Clinical Aspects*. 2nd ed. 2011.
  36. Phillips DC, Woollard KJ, Griffiths HR. The anti-inflammatory actions of methotrexate are critically dependent upon the production of reactive oxygen species. *Br J Pharmacol*. 2003;138(3):501-511.
  37. Helal MG, Said E. Tranilast attenuates methotrexate-induced renal and hepatic toxicities: Role of apoptosis-induced tissue proliferation. *J Biochem Mol Toxicol*. 2020;34(5):e22466. doi:10.1002/jbt.22466.
  38. Montasser AOS, Saleh H, Ahmed-Farid OA, Saad A, Marie MS. Protective effects of *Balanites aegyptiaca* extract, melatonin and ursodeoxycholic acid against hepatotoxicity induced by methotrexate in male rats. *Asian Pac J Trop Med*. 2017;10(6):557-565.
  39. Won YJ, Kim BK, Shin YK, et al. Pectinase-treated *Panax ginseng* extract (GINST) rescues testicular dysfunction in aged rats via redox-modulating proteins. *Exp Gerontol*. 2014;53:57-66.

### How cite this article

Karakaya-Cimen FB, Macit C, Goksun Sivas G, Tunali Akbay T, Sener G, Ercan F. Morphological and Biochemical Investigation of the Protective Effects of *Panax ginseng* on Methotrexate-Induced Testicular Damage. *Eur J Biol* 2023;82(1): 31-37. DOI: 10.26650/EurJBiol.2023.1271825