

# The possible effect of light exposure reduction via eye patches after the examination for retinopathy in premature infants? An observational study in preterm neonates

Gaffari Tunç<sup>1</sup>, Duygu Yalınbaş Yeter<sup>2</sup>, Feyzanur Karagöz<sup>3</sup>, Emine Erva Tecer<sup>3</sup>, Senem Akkan<sup>3</sup>, Fatih Kılıçbay<sup>4</sup>

<sup>1</sup>Department of Pediatrics Division of Neonatology, University of Health Sciences, Bursa Yüksek İhtisas Training and Research Hospital, Bursa, Turkey; <sup>2</sup>Department of Ophthalmology, Sivas Cumhuriyet University Faculty of Medicine, Sivas, Turkey; <sup>3</sup>Medical Student, Sivas Cumhuriyet University Faculty of Medicine, Sivas, Turkey; <sup>4</sup>Department of Pediatrics, Division of Neonatology, Sivas Cumhuriyet University Faculty of Medicine, Sivas, Turkey

## ABSTRACT

**Objectives:** This study aimed to examine whether infants with and without eye patches differ in terms of vital signs and clinical status after retinopathy of prematurity examination.

**Methods:** Premature infants hospitalized in study center between June 2021-April 2022 were included. Group 1 is consisted of infants whose eyes were not closed after retinopathy of prematurity examination. Those infants whose eyes were closed eye-patches consisted of group 2. Vital signs were followed for 24 hours following the examination. Demographic, medical and follow-up data were all recorded prospectively. Vital signs were evaluated in accordance with birth week and weight. Pain score was evaluated by Neonatal Pain, Agitation, and Sedation Scale.

**Results:** Pain scores were found to be lower in group 2 ( $p < 0.020$ ). Although the systolic blood pressure, diastolic blood pressure, and mean blood pressure values of group 2 were found to be lower than group 1, they were within normal limits (all  $p < 0.05$ ). Vomiting was not observed at all in Group 1 ( $p = 0.036$ ). There was no significant difference between the groups in terms of fever, respiratory rate, heart rate, SpO<sub>2</sub>, and blood glucose values.

**Conclusions:** This study showed that using an eye patch in infants after an eye examination reduces pain and increases comfort of infants. Although their pain scores are lower, taking necessary precautions are recommended for these patients in terms of vomiting. Thus, eye patches can be suggested as a non-pharmacological pain-reducing method after get advanced stagnation by the support of more studies with a larger number of participants.

**Keywords:** Newborn, eye patch, light exposure, retinopathy of prematurity, non-pharmacological method



e-ISSN: 2149-3189

Received: March 30, 2023; Accepted: June 22, 2023; Published Online: August 5, 2023

**How to cite this article:** Tunç G, Yalınbaş Yeter D, Karagöz F, Tecer EE, Akkan S, Kılıçbay F. The possible effect of light exposure reduction via eye patches after the examination for retinopathy in premature infants? An observational study in preterm neonates. Eur Res J 2023;9(5):977-983. DOI: 10.18621/eurj.1273038

**Address for correspondence:** Gaffari Tunç, MD., Assistant Professor, University of Health Sciences, Bursa Yüksek İhtisas Training and Research Hospital, Department of Pediatrics, Division of Neonatology, Yıldırım, Bursa, Turkey. E-mail: dr.gaffaritunc@gmail.com, Phone: +90 224 295 50 00



©Copyright © 2023 by Prusa Medical Publishing  
Available at <http://dergipark.org.tr/eurj>  
[info@prusamp.com](mailto:info@prusamp.com)

**R**etinopathy of prematurity (ROP) is a disorder of retinal vascular development of preterm infants [1]. The blood supply to the anterior segment of the eye is provided by the hyaloid artery from the 6<sup>th</sup> week of pregnancy. The hyaloid artery, which originates from the optic nerve, runs along the vitreous and supplies blood supply to the lens and iris surface. The retina is the last organ of the fetus to be vascularized and there is no vascularization before 16 weeks of gestation. Retinal vascularization occurs from the optic disc to the periphery by two mechanisms: vasculogenesis (new capillary formation from endothelial cells) and angiogenesis (new capillary formation as a result of activation, migration and proliferation of endothelial cells from existing venules). The nasal region of the retina is completely vascularized at 36 weeks and the temporal retina at 40 weeks of gestation. [2]. While ROP is predominantly the problem of preterms who are born below 28 weeks in developed countries, severe ROP was reported up to 34 weeks in developing countries [3]. In a multicenter study conducted by the Turkish Neonatal Society in 2014, the frequency of ROP in very low birth weight (BW) preterm infants was found to be 42%, and the frequency of advanced ROP was 8.2%. According to this data advanced stage ROP requiring treatment can be needed for more mature infants with higher GW and BW in our country compared to developed countries [4]. Although the pathogenesis of ROP is not elucidated exactly yet, it is thought to be developed in a two-stage process. Retinal vascularization that started in the intrauterine environment can be paused by any damaging effect in a premature infant. Factors such as prolonged hyperoxia, asphyxia, hypothermia, acidosis, and vitamin E deficiency are possible causes of initial injury. In the early stage of ROP (Phase I), suppression of vascular endothelial growth factor (VEGF) and erythropoietin due to hyperoxia, absence of insulin-like growth factor 1 (IGF-1), poor postnatal growth inhibits normal vascular development [3, 5]. The retina continues to develop, but due to the impaired vascularization, retinal oxygen demand cannot be met resulting in relative hypoxia of retina. Hypoxia encountered by the retina initiates phase II. With the trigger of hypoxia, the levels of mediators such as VEGF, erythropoietin and IGF-I increase and new vessel formation begins. New vessels appear at the vascular-avascular retinal border. Newly formed vessels cluster in the retina and can

form a rapidly thickening ridge tissue. New vascularization can lead to leakage and edema formation ending in vision loss, and even retinal detachment [5, 6].

Early detection of ROP can enhance long-term visual acuity [7]. Thus, routine ROP examinations are carried out at certain times which are determined depending on various studies. According to the 2013 recommendations of the American Academy of Pediatrics and the American Academy of Ophthalmology, ROP screening is recommended for all infants who are born with a BW of  $\leq 1500$  g and/or a GW of  $\leq 30$  weeks, and infants with a GW above 30 weeks, with a BW of 1500-2000 grams, who required cardiopulmonary support [8]. In the light of national studies, Turkish Neonatal Society guidelines recommended screening all infants born at  $\leq 32$  weeks, as in the 2006 recommendations of the American Academy of Pediatrics and the American Academy of Ophthalmology [9]. Retinal examination is recommended within 4-6 weeks after babies are born [3]. Physiological changes such as tachycardia, bradycardia, oxygen desaturation, hypertension, and an increase in the frequency of apneic episodes can be seen either during the procedure, and in the following hours in infants undergoing ROP examination [10].

Increased sensitivity of the infant to light due to the dilated pupils before the eye examination, is thought to be effective on the clinical status of the infant. Therefore, the aim of this study is to examine the clinical effects of decreasing the light exposure of infants using eye patches after retinopathy screening in preterm infants.

## METHODS

Premature infants hospitalized in Sivas Cumhuriyet University Neonatal Intensive Care Unit between June 2021 and April 2022 were included in this study. Informed consent was obtained from the parents of the patients included in the study, in accordance with the requirements of the Helsinki Declaration of ethical issues. The Ethics Committee of Sivas Cumhuriyet University approved the study (Date: 16.04.2021, Decision No: 2021-04/08). After retinopathy examination, clinical differences were evaluated comparatively between the infants who were exposed to light (Group 1) and infants who were not exposed to light

by using eye patches (Group 2). All patients were followed up for 24 hours after the examination due to the half-life of the drugs used for procedure. No analgesic agents or non-pharmacological methods except swaddling were used in both groups during the follow-up. After the instillation of 0.5% tropicamide and 2.5% phenylephrine drops to bilateral eyes with a 15-minute interval approximately 1-2 hours before the infant's examination, a speculum is used to open the palpebral fissure, and the retina was examined using scleral depression to visualize the periphery. The first examinations of the infants were made by the same ophthalmologist at 31 weeks for infants who were born before 27 weeks and at the postnatal 28<sup>th</sup> day for infants who were born after 27 weeks. Demographic characteristics (gender, birth weight, gestational week) of the patients were recorded prospectively. The vital signs of the patients included in the study in the first 24 hours after the eye examination were recorded. Vital signs and clinical follow-up data of all infants including body temperature, oxygen saturation, heart rate, blood pressure, blood glucose, pain, respiratory rate, apnea, abdominal distension, vomiting, and resuscitation were all recorded prospectively. The blood pressure values of the patients were evaluated in accordance with the GW and BW according to the guide published by the Turkish Neonatal Society [11]. Pain values were calculated according to the Neonatal Pain, Agitation, and Sedation Scale (N-PASS). N-PASS is a tool used to measure pain in term and preterm infants who experience pain during procedures performed in neonatal intensive care units. The tool uses five physiological and behavioral cues (crying irritability, behavioral state, facial expression, extremities tone, vital signs) with relative validity for measurement [12]. Bradycardia was defined as a heart rate below 100. According to the guidelines of the Turkish Neonatology Association; desaturation was evaluated as SpO<sub>2</sub> below 90. Apnea was defined as the cessation of breathing for 20 seconds or bradycardia with desaturation lasting longer than 10 seconds. Data were obtained by observing all cases 24 hours after retinopathy examination.

### Study Population

Infants who were born under 32 weeks and weighed less than 1500 g at birth were included in the study. The infants over 32 weeks, infants whose BW

was over 1500 g, those with the genetic disease, heart disease, metabolic disease, lung anomalies, ocular malformations, and infants with conditions that may affect the response to stress were excluded from the study.

### Statistical Analysis

The obtained data were evaluated by using the IBM-SPSS (Version 22.0) statistical package program. The percentage, median, and interquartile range 25-75 (IQR 25-75) values were used for descriptive statistics. The Chi-square test was used to compare categorical data, and the Shapiro-Wilk test was used to compare continuous data. Mann-Whitney U test was used for comparisons with categorical groups as it did not show the normal distribution as a result of the normality test.  $P < 0.05$  was accepted for statistical significance.

## RESULTS

A total of 88 newborn infants were included in this study. While 31.5% (n = 28) of the study group were girls, the median birth weight of the individuals was 860 (780-1250). The median week of delivery of the patients was 27 (25-29), the median APGAR score at 1<sup>st</sup> and 5<sup>th</sup> minutes were 5 (4.0-6.0) and 7 (6.0-8.0), respectively (Table 1).

Group 1 included 45 infants, and 43 of them were in Group 2. No correlation was found between the

**Table 1. Gender, birth weight, week of birth and APGAR scores of the patients**

Gender n (%)	Female	28 (31.8)
	Male	60 (68.2)
Birth weight (g), median (IQR25-75)		860 (780.0-1250.0)
Gestational age (week), median (IQR25-75)		27 (25.0-29.0)
1 <sup>st</sup> . min. APGAR score, median (IQR25-75)		5 (4.0-6.0)
5 <sup>th</sup> . min. APGAR score, median (IQR25-75)		7 (6.0-8.0)

APGAR = Activity- Pulse - Grimace - Appearance - Respiration

**Table 2. Comparison of the complications according to the eye closure status of the study groups**

Complication		Group 1		Group 2		p value
		n	%	n	%	
Apnea	No	45	100.0	42	97.7	0.304
	Yes	0	0.0	1	2.3	
Bradycardia	No	45	100.0	42	97.7	0.304
	Yes	0	0.0	1	2.3	
Tachycardia	No	22	48.9	18	41.9	0.508
	Yes	23	51.1	25	58.1	
Abdominal distention	No	40	88.9	40	93.0	0.500
	Yes	5	11.1	3	7.0	
Vomiting	No	45	100.0	39	90.7	0.036
	Yes	0	0.0	4	9.3	
Resuscitation	No	37	82.2	34	79.1	0.078
	Yes	8	17.8	9	20.9	

presence of apnea, bradycardia, tachycardia, abdominal distension, and resuscitation and eye closure. Vomiting was found to be in a significantly higher frequency in Group 2 ( $p = 0.036$ ). Vomiting was observed in 4 (0.09%) of 43 patients (Table 2).

Systolic blood pressure ( $p < 0.001$ ), diastolic blood pressure ( $p < 0.017$ ), and mean blood pressure ( $p < 0.002$ ) values were found to be lower in Group 2 compared to Group 1 although they were within the normal limits. Pain values were found to be significantly lower in group 2 ( $p < 0.020$ ). There was no difference between the groups in terms of fever,

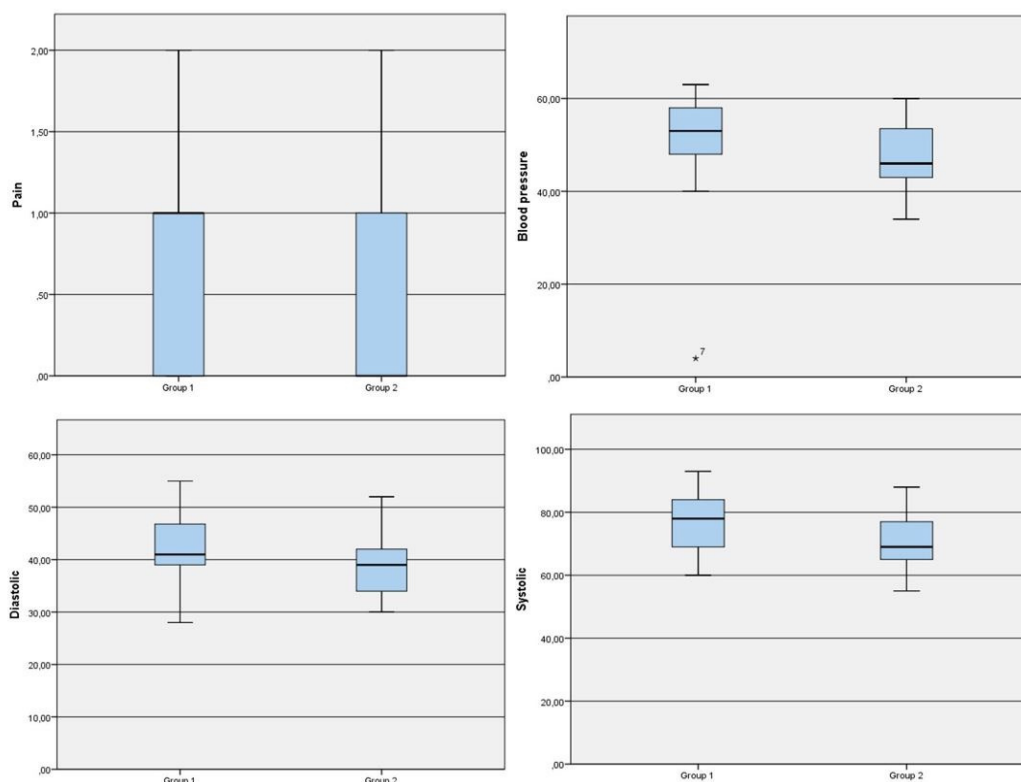
respiratory rate, heart rate, SpO<sub>2</sub>, and blood glucose values. The clinical symptoms and findings according to the eye closure status of the study group are given in Table 3. The systolic, diastolic, mean blood pressure and pain characteristics of the two groups are also shown in the Fig. 1.

### DISCUSSION

This study revealed that decreasing the light exposure of infants by using eye patches following the ROP ex-

**Table 3. Comparison of clinical and symptoms according to eye closure status of study groups.**

Clinical symptoms and findings	Group 1			Group 2			p value
	Median	IQR 25	IQR 75	Median	IQR 25	IQR 75	
Fever (°C)	37.00	37.00	37.30	37.10	37.00	37.20	0.446
Respiratory rate (min)	60.00	58.00	62.00	59.00	58.00	60.00	0.226
Heart rate (min)	155.00	148.00	164.00	158.00	154.00	165.00	0.150
SpO <sub>2</sub>	94.00	94.00	97.00	95.00	94.00	96.00	0.980
Systolic blood pressure (mmHg)	78.00	69.00	84.00	69.00	65.00	77.00	0.001
Diastolic blood pressure (mmHg)	41.00	39.00	46.80	39.00	33.00	43.00	0.017
Mean blood pressure (mmHg)	53.00	48.00	58.00	46.00	43.00	54.00	0.002
Pain score	1.00	0.00	1.00	0.00	0.00	1.00	0.020
Blood glucose (mg/dL)	80.00	71.00	90.00	80.00	74.00	87.00	0.864



**Fig. 1.** Comparison of systolic blood pressure, diastolic blood pressure, mean blood pressure, and pain status of the study groups. In group 2, systolic blood pressure ( $p < 0.001$ ), diastolic blood pressure ( $p < 0.017$ ), mean blood pressure ( $p < 0.002$ ) values were found to be lower than those whose eyes were closed. Pain values were found to be lower in the infants with eye patches ( $p < 0.020$ ).

amination, can reduce the pain due to the procedure. Physiological changes such as tachycardia, bradycardia, desaturation, hypertension, and an increase in apneic episodes can be observed during the ROP examination and in the following hours in infants who are examined for retinopathy [10]. In a study examining the effects of light intensity on the physiological parameters of premature infants, an increase in the intensity of light resulted in elevated heart rate and respiratory rate accordingly followed by an increase in oxygen demand [13]. In this study, we did not detect a significant difference between Group 1 and Group 2 in terms of respiratory rate, heart rate, and SpO<sub>2</sub> values after the examination. In a small randomized clinical study, Szgiato *et al.* [1] showed that in addition to the stress caused by the examination itself, additional stress due to the extreme light sensitivity by mydriasis can be reduced by using eye patches. Since the unequal distribution of infants receiving ventilator support affected the accuracy of the findings, they stated that more comprehensive and prospective studies are

needed to increase the reliability of the results [1]. Belda *et al.* [14] found no significant changes in blood pressure and pulse rate in 27 preterm infants after ophthalmological examination, while they detected vomiting in 4%, reflux in 22%, and apnea in 41% of these cases. Similarly, in this study, although systolic blood pressure, diastolic blood pressure, and mean blood pressure values were found to be higher in Group 1 compared to Group 2, blood pressure values were found to be within the normal range. Although no vomiting was seen in Group 1, it was observed in 4 of 43 patients in group 2. This finding could be associated with the relatively small number of participants of this study. However, a clarification can be provided by more comprehensive studies in the future.

The infants who wore eye patches after retinopathy examination had lower pain scores in Group 2 compared to group 1. Since the complications in regard to pain-related stressful events can be common, those infants should be closely monitored for the first 24-48 hours following the ROP examination. Pain re-



duction by using eye patches after ROP examination was found to be useful in a recent study [15]. Likewise, this study revealed that the pain scores of infants who wore eye patches were lower than the ones in group 1. On account of premature infants are more sensitive to painful stimuli, the pain due to the ROP examination was shown to be more severely felt, and its effect was longer [16]. While negative stress increases the oxygen demand of the tissues in infants exposed to pain when the respiratory system cannot meet this need, it can lead to apnea, cardiovascular problems, overloading and bleeding in weak and immature vessels with increased blood pressure, and changes in the level of consciousness. Reducing pain is an important entity for newborn infants. Therefore, the use of an eye patch can be valuable either in preventing intraventricular hemorrhage by reducing the pain. Thus, this can be used as a non-pharmacological method after retinopathy examination. Infants examined with wide-field digital retinal imaging (WFDR) for ROP screening showed to be more painful and stressed compared with a Binocular Indirect Ophthalmoscope (BIO) [17]. In this study, all infants were examined with BIO, and the patients without eye patches were found to have more pain than the infants whose eyes were closed after the examination. Many pharmacological and non-pharmacological methods are used in infants to reduce pain [18]. Based on this study, using the eye patches can be suggested as a non-pharmacological pain relief method.

### Limitations

The limitations of the study can be mentioned as follows. Although the infants are similar in terms of clinical and demographic status, the medications used for infants, treatment modalities, and the genetic factors of the population can not be completely similar between the groups. Besides, vital signs of the infants can be affected by many environmental conditions which can not be recognized. Therefore, we suggest that multidisciplinary studies with larger number of cases are needed to overcome those limitations.

### CONCLUSION

This study revealed that using an eye patch in infants after eye examination reduces pain and improves the

comfort of infants. However, necessary precautions should be taken for these patients in terms of vomiting. Based on the findings of this study, the use of eye patches can be suggested as a non-pharmacological pain-reducing method after retinopathy examination, however more studies with larger number of participants are required for a better understanding for its action of mechanism.

### Authors' Contribution

Study Conception: FK, GT, FK; Study Design: GT, FK, DYY, FK; Supervision: DYY, FK, GT; Funding: SA, EET, FK, GT, ÖŞ; Materials: FK, SA, EET; Data Collection and/or Processing: FK, SA, EET, GT; Statistical Analysis and/or Data Interpretation: DYY, SA, FK; Literature Review: EET, GT, FK, SA; Manuscript Preparation: GT, FK, DYY and Critical Review: DYY, GT, FK, FK.

### Conflict of interest

The authors disclosed no conflict of interest during the preparation or publication of this manuscript.

### Financing

The authors disclosed that they did not receive any grant during conduction or writing of this study.

### REFERENCES

1. Szigiato AA, Speckert M, Zielonka J, Hollamby K, Altomare F, Ng E, et al. Effect of eye masks on neonatal stress following dilated retinal examination: The MASK-ROP randomized clinical trial. *JAMA Ophthalmol* 2019;137:1265-72.
2. Uslu S, Bülbül A. Retinopathy of prematurity via neonatology perspective. *Şişli Etfal Hastanesi Tıp Bülteni* 2011;45:142-52. [Article in Turkish]
3. Koç E, Yağmur Baş A, Özdek Ş, Ovalı F, Başmak H. Turkish Neonatal and Turkish Ophthalmology Societies consensus guideline on the retinopathy of prematurity. *Turk Pediatr Ars* 2018;53:151-60.
4. Bas AY, Koc E, Dilmen U, ROP neonatal Study Group. Incidence and severity of retinopathy of prematurity in Turkey. *Br J Ophthalmol* 2015;99:1311-4.
5. Löfqvist C, Andersson E, Sigurdsson J, Engström E, Hard AL, Niklasson A, et al. Longitudinal postnatal weight and insulin-like growth factor I measurements in the prediction of retinopathy of prematurity. *Arch Ophthalmol* 2006;124:1711-8.
6. Hellström A, Carlsson B, Niklasson A, Segnestam K, Boguszewski M, de Lacerda L, et al. IGF-I is critical for normal vascularization of the human retina. *J Clin Endocrinol Metab* 2002;87:3413-6.

7. Early Treatment For Retinopathy of Prematurity Cooperative Group. Revised indications for the treatment of retinopathy of prematurity: results of the early treatment for retinopathy of prematurity randomized trial. *Arch Ophthalmol* 2003;121:1684-94.
8. Fierson WM; American Academy of Pediatrics Section on Ophthalmology; American Academy of Ophthalmology; American Association for Pediatric Ophthalmology and Strabismus; American Association of Certified Orthoptists. Screening examination of premature infants for retinopathy of prematurity. *Pediatrics* 2013;131:189-95.
9. Fierson WM; American Academy of Pediatrics Section on Ophthalmology; American Academy of Ophthalmology; American Association for Pediatric Ophthalmology and Strabismus; American Association of Certified Orthoptists. Screening examination of premature infants for retinopathy of prematurity. *Pediatrics* 2018;142:e20183061.
10. Mitchell AJ, Green A, Jeffs DA, Roberson PK. Physiologic effects of retinopathy of prematurity screening examinations. *Adv Neonatal Care* 2011;11:291-7.
11. Dilli D, Soylyu H, Tekin N. Neonatal hemodynamics and management of hypotension in newborns. *Turk Pediatri Ars* 2018;53(Suppl 1):65-75.
12. Benbrook K, Manworren RCB, Zuravel R, Entler A, Riendeau K, Myler C, et al. Agreement of the neonatal pain, agitation, and sedation scale (N-PASS) with NICU nurses' assessments. *Adv Neonatal Care* 2023;23:173-81.
13. Marlier L, Gaugler C, Astruc D, Messer J. The olfactory sensitivity of the premature newborn. *Arch Pediatr* 2007;14:45-53.
14. Belda S, Pallás CR, De la Cruz J, Tejada P. Screening for retinopathy of prematurity: is it painful? *Biol Neonate* 2004;86:195-200.
15. Espino-torres E, Malloy M, Geary C. Eye patches reduce the pain and distress in infants undergoing pupillary dilation for the screening of retinopathy of prematurity. Poster presented at: 2012 Texas Pediatric Society Electronic Poster Contest 2012.
16. Johnston CC, Fernandes AM, Campbell-Yeo M. Pain in neonates is different. *Pain* 2011;152(3 Suppl):65-73.
17. Moral-Pumarega MT, Caserío-Carbonero S, De-La-Cruz-Bértolo J, Tejada-Palacios P, Lora-Pablos D, Pallás-Alonso CR. Pain and stress assessment after retinopathy of prematurity screening examination: indirect ophthalmoscopy versus digital retinal imaging. *BMC Pediatr* 2012;12:132.
18. Yiğit Ş, Ecevit A, Koroğlu ÖA. Turkish Neonatal Society guideline on the neonatal pain and its management. *Turk Pediatri Ars* 2018;53(Suppl 1):161-71.



This is an open access article distributed under the terms of [Creative Commons Attribution-NonCommercial-NoDerivatives 4.0 International License](https://creativecommons.org/licenses/by-nc-nd/4.0/).