

■ Original Article

Effect of montelukast on hepatic and renal ischemia/reperfusion injury

Montelukastın karaciğer ve böbrekteki iskemi/reperfüzyon hasarına olan etkisi

Ali Baran BUDAK¹, Kemal KORKMAZ¹, Hikmet Selçuk GEDİK¹, Gökhan LAFÇI², Ertuğrul KAYA³, Handan ANKARALI⁴, Serdar GÜNAYDIN^{1a}

¹Department of Cardiovascular Surgery, Numune Training and Research Hospital, Ankara,

²Department of Cardiovascular Surgery, Yüksek İhtisas Hospital, Ankara,

³Department of Pharmacology, Medical Faculty, Düzce University, Konuralp, Düzce,

⁴Department of Biostatistics, Medical Faculty, Düzce University, Konuralp, Düzce, TURKEY

ABSTRACT

Aim: The thoracoabdominal aortic aneurysm surgery may cause splanchnic ischemia and may result in severe postoperative complications caused by liver and/or kidney injury. This study investigated the effect of temporary occlusion of the aorta on the development of I/R injury of liver and kidney and the protective effect of montelukast, a selective reverse CysLT1 receptor antagonist.

Material and Methods: Twenty-one male Sprague-Dawley rats were randomly assigned to three groups (n=7 per group) as G1 (no aortic occlusion and montelukast administration), G2 (45 min. aortic occlusion; no montelukast administration) and G3 (45 min. aortic occlusion, 10 mg/kg montelukast administration). At the 48th hour of reperfusion, kidney and liver samples were dissected for histopathological evaluation and immunohistochemical staining for HSP70, interleukin-6 and myeloperoxidase (MPO).

Results: Tissue samples taken from the kidney showed significant intergroup differences in terms of tubular cell degeneration, cytoplasmic vacuole formation, hemorrhage and tubular dilatation (P = 0.001, P = 0.017, P = 0.001, P = 0.001 respectively). There was a significant difference with regards to HSP-70 stain (P = 0.01) in favor of G1 and G3 with respect to G2. Hepatocyte degeneration in the liver samples of G3 was significantly lower than that of G1 and G2 (P = 0.027).

Conclusion: The findings of the current study demonstrated that montelukast has protective effects on both kidney and liver; and were confirmed histopathologically and immunohistochemically. The protective effects of montelukast can be attributed to its potential of anti-oxidative and anti-inflammatory actions.

Keywords: Ischemia-reperfusion injury, montelukast, kidney, liver

Corresponding Author[®]: Serdar Gunaydin, MD. Department of Cardiovascular Surgery, Numune Training & Research Hospital, Ankara, TURKEY

Phone: +90-536-3896521

e-mail: sgunaydin@isnet.net.tr

Received 24.06.2016, accepted 23.08.2016

Doi: 10.18663/tjcl.304530

ÖZ

Amaç: Torakoabdominal aort anevrizması cerrahisinin sebep olabildiği splanknik iskemi, karaciğer ve/veya böbrek hasarının neden olduğu ciddi postoperatif komplikasyonlarla sonuçlanabilir. Bu çalışmada seçici tersinir bir CysLT1 reseptör antagonisti olan montelukastın, aortanın geçici oklüzyonuyla yaratılan böbrek ve karaciğer iskemi-reperfüzyon (I/R) hasarı üzerindeki koruyucu etkisini incelemek için tasarlandı.

Gereç ve Yöntemler: Yirmi bir erkek Sprague-Dawley tipi sıçan, rasgele üç gruba (her grupta n=7) ayrıldı; G1 (aort oklüzyonu ve montelukast uygulaması yok), G2 (45 dakika aort oklüzyonu; montelukast uygulaması yok) ve G3 (45 dakika aort oklüzyonu, 10 mg/kg montelukast uygulaması). Reperfüzyonun 48. saatinde böbrek ve karaciğerden alınan doku örneklerinden histopatolojik değerlendirme ve HSP 70, interlökin-6 ve miyeloperoksidaz (MPO) ile immünohistokimyasal boyama yapıldı.

Bulgular: Böbrekten alınan doku örnekleri tübüler hücre dejenerasyonu, sitoplazmik vakuol formasyonu, hemoraji ve tübüler dilatasyon açısından incelendi ve gruplar arasında istatistiksel olarak anlamlı fark bulundu ($P = 0.001$, $P = 0.017$, $P = 0.001$). G1 ve G3 gruplarında HSP-70 ile boyanmada G2'ye göre anlamlı fark saptandı ($P = 0.001$). G3 karaciğer örneklerinde hepatosit dejenerasyonu G1 ve G2'den anlamlı olarak düşüktü ($P = 0.027$).

Sonuçlar: Yapılan çalışmanın bulguları, montelukastın böbrek ve karaciğer üzerinde koruyucu etkileri olduğunu histopatolojik ve immünohistokimyasal olarak göstermiştir. Montelukastın koruyucu etkileri, ilacın antioksidan ve antiinflamatuvar etkilerine bağlanabilir.

Anahtar Kelimeler: İskemi-reperfüzyon injurisi, montelukast, böbrek, karaciğer

Introduction

Thoraco-abdominal aortic surgery (TAAS) can cause ischemia/reperfusion (I/R) injury in visceral organs [1]. A temporary discontinuation in splanchnic, renal and spinal cord blood flow is inevitable during the aortic cross-clamping. Although the ischemic insult of visceral organs can recover after oxygen supply and blood elements are restored, the process of reperfusion associated with a huge systemic proinflammatory response can cause remote organ injury [2-4].

Oxidative stress due to the reperfusion recruit polymorphonuclear leukocytes to the tissue and exaggerate the inflammatory reaction by immune cell infiltration, release of pro-inflammatory cytokines, chemokines, proteolytic enzymes, adhesion molecules and free oxygen radicals (FORs) [2].

Interleukin-6 (IL-6) is a pleiotropic cytokine engaged in the differentiation of B lymphocytes and an important mediator of the inflammatory response in ischemia. It is generally considered as a non-specific marker of inflammation that is released in response to infection, burns, trauma and neoplasia [5].

Myeloperoxidase (MPO) is one of the distinct indicators for the tissue infiltration of neutrophilic granulocytes. MPO activity increases in response to the I/R injury [6].

Heat shock proteins (HSPs) are cellular stress proteins which have been shown to have an important role for the survival of cells under stress conditions [7]. It has been showed that overexpression of HSP70 attenuates the release of inflammatory factors and interferes with the process of apoptotic cell death [8-11].

Cysteinyleukotriens (CysLTs), namely leukotriene (LT) C₄, LTD₄ and LTE₄, which are the 5-lipoxygenase (5-LO) metabolites of arachidonic acid, are potent mediators of inflammation that are associated with I/R injury [12,13]. Montelukast, is a selective reversible CysLT1 receptor antagonist. It is clinically used for the treatment of asthma by reducing the eosinophilic inflammation in the airways [14,15].

The present study was designed to investigate the protective effects of montelukast on liver and kidney I/R injury in an experimental model.

Material and Methods

Animal Care

This study was approved by the Ethics Committee for Experimental Research of Düzce University School of Medicine. All rats received humane care in compliance with the European Convention on Animal Care.

21 male Sprague-Dawley rats weighing 250 to 350 g were housed in cages and maintained on a 12-hour light/dark cycle with free access to food and water. The animals were kept within the same unit at a room temperature between 18°C and 21°C. The animals were followed for 15 days before the procedure. None of the animals had any neurological abnormality before anesthesia and surgery.

Anesthesia and Monitoring

Rats were fasting within 8 hours before anesthesia. Anesthesia was induced with intramuscular administration of ketamine (50 mg/kg) and xylazine (5 mg/kg). 0.01 mg heparin was given intraperitoneally. Anesthesia was maintained by intermittent



delivery of ketamine (25 mg/kg) (0.6 mg/kg/h). Animals were allowed to breathe spontaneously without mechanical ventilation and core temperature was maintained between 36,5-37,5°C by means of a heating lamp. The animals received oxygen at 200 mL/minute via a pediatric face mask throughout the procedure. Each operation was performed in the same operating room at ambient temperature. Ensuring adequate depth of anesthesia, a 24G catheter was surgically inserted into the left jugular vein to provide intravenous administration of fluid and medications. (0.9% isotonic saline solution, 1 mL/kg/h). An arterial 24G catheter was inserted into the left carotid artery for monitoring the arterial blood pressure. The core temperature above 36°C was followed with a rectal probe. The animals received prophylactic antibiotics (procaine penicillin, 200,000 units administered intramuscularly twice a day) for 2 days in the immediate postoperative period. 400 IU/kg of heparin was administered to all animals immediately before the procedure. Postoperative analgesia was maintained by subcutaneous injection of tramadol.

Study Groups

Twenty-one male Sprague-Dawley rats weighing between 250-350 g were enrolled in the study. Intraperitoneal heparin was administered immediately before the procedure to animals in the study groups. The animals were divided into three groups. Group G1 (Vehicle-treated Sham-operation group) (n=7): The operation was performed in the same fashion, but without aortic occlusion and montelukast administration. Group G2 (Vehicle-treated ischemia group): Aorta was cross-clamped for 45 minutes. No montelukast administration. Group G3 (Montelukast treated group): Aorta was cross-clamped for 45 minutes and continuous infusion of montelukast solution (20 mg/kg/h) was administered for 30 minutes-started after the midline incision and continued during the ischemic period-Montelukast sodium parenteral preparation method.

We did not have a commercial parenteral form of montelukast. For this reason, the parenteral form was prepared from oral tablets. Ten tablets of montelukast (Onceair®; Merck & Co. Inc., Whitehouse Station, NJ, USA) 10 mg was dissolved in 10 milliliters of ethanol. The solution was centrifuged for 5 minutes at 5000 rpm to precipitate ethanol-insoluble excipients and the resultant supernatant was filtered using a filter with pores of 0.2µm. The filtered solution was concentrated using an evaporation method and reduced to a volume of 3 ml. In this solution, there was approximately 30 mg/mL concentration of montelukast sodium. 100 µL of this solution was injected into the semi-preparative high-performance liquid chromatography (HPLC) system and fractioned according to time of extracting from chromatogram. We use a method in the HPLC device which was previously validated [16].

The peak of montelukast sodium was at the 12.115th minute in HPLC chromatogram. Fraction was collected from the initiation till the termination of the peak. The same process was repeated until the collected amount of montelukast sodium reached to a desired concentration in the fraction (approximately 20 times). All fractions were collected together. The concentration of drug obtained from the fraction was measured by analytical HPLC. 1 tablet dissolved in 10 ml of ethanol and stock solution was obtained. Diluting this stock solution, three different calibration standards were constituted. The proportion of the peak areas of montelukast sodium was used to obtain a calibration curve. 5 µL from this fraction was injected into the analytical system. A mixture of water-acetonitrile (ratio 5:95) was used as mobile phase at a rate of 1 mL/min. The RP Semi-preparative(ACE) column, which was filled with 4.6x250 mm C18 (5 mm particle diameter), was used. Measurements were taken with a 225 nm wavelength UV detector.

As a result of this analysis, the purity and concentration of montelukast sodium that was obtained by fractioning method were confirmed. The amount of montelukast sodium was determined by placing the peak area of obtained fraction in HPLC into calibration curve.

The liquid phase of the fraction evaporated. The remaining solid part was substantially diluted with distilled water to obtain a 10 mg/mL of solution. The purity ratio was calculated to be 97.874% respectively.

Surgical procedure

Animals were placed in supine position. After sterile preparation, a standard midline laparotomy incision was made, and the infrarenal abdominal aorta was exposed via a transperitoneal approach with the abdominal contents reflected to the right. The aorta was isolated from the left renal artery down to the aortic bifurcation. Heparin was not reversed at the end of the procedure in the study groups. The aorta was cross-clamped with mini-aneurysm clamps at 2 sites: just distal to the left renal artery and proximal to the aortic bifurcation. Loss of aortic pulse was confirmed by palpation. The duration of the ischemic insult was 45 minutes. Following removal of the cross-clamp, distal perfusion was observed visually. Upon completion of the procedure, the abdominal wall was closed in a double-layer fashion with 4-0 polypropylene suture. After anesthesia was discontinued, the rats were separated from each other to allow optimal recovery from anesthesia.

Tissue Preparation

All animals were killed at 48 hours postoperatively by a lethal cardiac injection of sodium pentobarbital (100 mg/kg). The liver and kidneys were dissected totally and fixed in buffered

formalin for 7 days. The experimental model was carried out according to the experimental studies in the literature that investigate the spinal cord and visceral organ damage after cross-clamping the aorta [17-20].

Immunohistochemistry Examination

Blood samples from each rat were obtained at the end of 48h immediately before sacrifice. The chest wall was cleansed with chlorohexidine in spirit, and a sterile 10ml syringe was then used to obtain a blood sample by direct cardiac puncture. Blood samples for cytokine assay were collected into heparinized (20 unit/ml blood) sterile tubes and immediately transferred on ice to be centrifuged at 2000 rpm (at 4°C) for 10 minutes. They were stored at -70°C until the time of assay for IL-6, MPO and HSP-70.

Analysis of HSP70: Paraffin sections (4 µm thick) were prepared. Tissue sections were de-paraffinized and hydrated in xylenes and graded alcohol. The sections were incubated with primary anti-HSP70 (clone BRM.22, dilution 1/80, Biogenex, San Ramon, California) diluted in buffer. PBS was used as negative control.

Analysis of IL-6: The polyclonal anti-human IL-6 receptor antibody C-20 (Santa Cruz Biotechnologies, Santa Cruz, CA, USA) was used for the detection of IL-6 receptor. This antibody was diluted 1: 20. IL-6 receptor immunostaining was also performed according to a streptavidin-biotin-peroxidase protocol. The secondary anti-rabbit antibody was diluted 1: 500. Negative controls were performed via omitting the first antibody.

Analysis of MPO: The liver and kidney MPO activities were evaluated using an anti-MPO kit according to the manufacturer's protocol. Briefly, samples on polylysine-coated slides were deparaffinized and rehydrated. Then, the microwave antigen retrieval procedure was performed, and the samples were incubated in a 3% H₂O₂ solution to inhibit endogenous peroxidase. To block nonspecific background staining, the sections were incubated with a blocking solution. Then the sections were incubated with primary anti-MPO antibody, followed by incubation with biotinylated goat anti-mouse antibody. After incubating with the chromogenic substrate (DAB), the sections were counterstained with HE. The staining of cytoplasmic MPO in the neutrophils was evaluated, and the results were expressed as the percentage of neutrophils cytoplasmically stained positive for MPO.

Tissues with no evidence of staining, or only rare scattered positive cells, less than 3%, were recorded as negative. The results were evaluated for intensity and frequency of staining. The intensity of staining was graded as 0 (negative), 1 (weak), 2 (moderate), and 3 (strong). The frequency was graded from 0 to 4 by the percentage of positive cells as follows: grade

0, <3%; grade 1, 3-25%; grade 2, 25-50%; grade 3, 50-75%; grade 4, more than 75%. The index score was the product of multiplication of the intensity and frequency grades, which was then classified into a 4-point scale: index score 0 = product of 0, index score 1 = products 1 and 2, index score 2 = products 3 and 4, index score 3 = products 6 through 12.

Histopathologic Evaluation

For light microscopic investigations, a midline laparotomy was performed to all animals immediately following blood sampling and liver and kidney tissue specimens were fixed in 10% formaldehyde, dehydrated in alcohol series, cleared in toluene and embedded in paraffin. 5µ thick sections were placed on polylysine-coated slides and stained with hematoxyline and eosin (H&E).

The stained kidney samples were observed to identify tubular cell degeneration, cytoplasmic vacuole formation, tubular dilatation and infiltration of inflammatory cells.

The stained liver samples were observed to identify hepatocyte degeneration, single cell necrosis, steatosis and infiltration of inflammatory cells.

The tissues were observed and evaluated under a light microscope (Olympus BX51; Olympus Corp., Tokyo, Japan) at 400 x magnification.

Histopathological investigation was carried out by two pathologists blinded to the group assignments.

Statistical Analysis

Statistical analysis and calculations were performed by using SPSS 15 for Windows (Chicago, IL). Results were expressed as the mean (standard error mean). Kruskal-Wallis analysis of variance and Likelihood chi-square test was used to detect differences between groups. Statistical comparisons were made using the Mann-Whitney U test. A p value of < .05 was considered statistically significant.

Results

There was no significant difference in terms of body temperature, mean arterial pressure, heart rate and body temperature among the groups.

As depicted in Table 1, histopathological evaluation of the tissue samples taken from the kidney showed significant intergroup differences in terms of tubular cell degeneration, cytoplasmic vacuole formation, hemorrhage and tubular dilatation (P=0.001, P=0.017, P=0.001, P=0.001 respectively).



Table 1. Histopathologic results of the kidney tissue

Kidney	Grade	G1 (SHAM)		G2 (ischemia)		G3 (Montelukast)		P value
		Number	%	Number	%	Number	%	
Tubular cell degeneration	0	6	85.7%	0	0.0%	6	85.7%	0.001
	1	1	14.3%	7	100%	1	14.3%	
Cytoplasmic vacole formation	0	5	71.4%	0	0.0%	5	71.4%	0.017
	1	2	28.6%	7	100%	2	28.6%	
Hemorrhage	0	4	57.1%	0	0.0%	7	100%	0.001
	1	3	42.9%	7	100%	3	42.9%	
Tubular dilatation	0	7	100%	0	0.0%	7	100%	0.001
	1	0	0.0%	2	28.6%	1	14.3%	
	2	0	0.0%	5	71.4%	0	0.0%	

Tubular cell degeneration was identified in all animals in the G2 group; whereas only one animal in G1 and G3 (P = 0.001).

Cytoplasmic vacuole formation in the kidney specimens of G3 and G1 was significantly lower than that of G2 (P = 0.017).

There was no hemorrhage in the kidney specimens of G3 according to histopathologic evaluation. Hemorrhage was worst in G2 followed by G1 (P = 0.001).

There was no tubular dilatation in the kidney specimens of G1 and only one animal in G3 showed a moderate tubular dilatation. On the other hand, moderate tubular dilatation was observed in 2 animals and severe tubular dilatation was observed in 5 animals in G2 (P = 0.001).

Immunohistochemical markers as, MPO, HSP-70 and IL-6, were studied from the kidney tissue samples (Table 2).

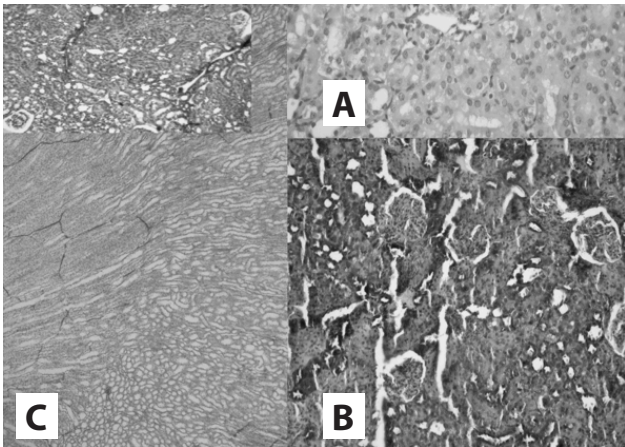
Table 2. Immunohistochemical results of the kidney tissue

Kidney	Grade	G1 (SHAM)		G2 (ischemia)		G3 (Montelukast)		P value
		Number	%	Number	%	Number	%	
MPO	0	4	57.1%	0	0.0%	4	57.1%	0.115
	1	3	42.9%	3	42.9%	2	28.6%	
	2	0	0.0%	2	28.6%	1	14.3%	
	3	0	0.0%	2	28.6%	0	0.0%	
IL-6	0	3	42.9%	6	85.7%	3	42.9%	0.112
	1	4	57.1%	0	0.0%	4	57.1%	
	2	0	0.0%	1	14.3%	2	28.6%	
HSP-70	0	3	71.4%	0	0.0%	3	71.4%	0.01
	1	0	0.0%	1	14.3%	1	14.3%	
	2	2	28.6%	1	14.3%	3	42.9%	
	3	0	0.0%	5	71.4%	0	0.0%	

Grade 1, 2 and 3 staining with MPO was stronger in the G2 group but it did not reach to a statistical significance (p=0.115). There was no statistically significant difference found among the groups in terms of IL-6 staining (P = 0.112), but there was a significant difference with regards to HSP-70 stain (P = 0.01).

The lowest HSP-70 level was measured in the G1 (sham) group, while 5 of 7 animals in G2 were strongly stained, evaluated as grade 3.

The histopathologic examples of kidney specimens are shown in Figure 1.



A: Grade 3 HSP-70 staining in G2 group; B: Grade 2 staining in G3 group; C: Tubular dilatation in an animal that belongs to G2 (x200).

Figure 1. Examples of kidney specimens

As depicted in table 3, histopathological evaluation of the liver samples showed significant intergroup differences in terms of hepatocyte degeneration and steatosis ($P = 0.027$ and $P = 0.017$, respectively) but we could not find a statistically significant difference among the groups with regards to single cell necrosis and infiltration of inflammatory cells ($P = 0.112$ and $P = 0.558$ respectively).

Table 3. Histopathological results of the liver tissue.

Liver	Grade	G1 (SHAM)		G2 (ischemia)		G3 (Montelukast)		P value
		Number	%	Number	%	Number	%	
Hepatocyte Degeneration	1	0	0.0%	2	28.6%	5	71.4%	0.027
	2	5	71.4%	5	71.4%	2	28.6%	
	3	2	28.6%	0	0.0%	0	0.0%	
Single Cell Necrosis	0	5	71.4%	2	28.6%	5	71.4%	0.112
	1	2	28.6%	2	28.6%	2	28.6%	
	2	0	0.0%	3	42.9%	0	0.0%	
Inflammatory Cell Infiltration	0	3	42.9%	2	28.6%	4	57.1%	0.558
	1	4	57.1%	5	71.4%	3	42.9%	

Hepatocyte degeneration in the liver samples of G3 was significantly lower than that of G1 and G2 ($P = 0.027$). There was no hepatocyte steatosis in G1 animals. Hepatocyte steatosis was found in 2 animals in G3 and 5 animals in G2, this

difference was statistically significant ($P = 0.017$).

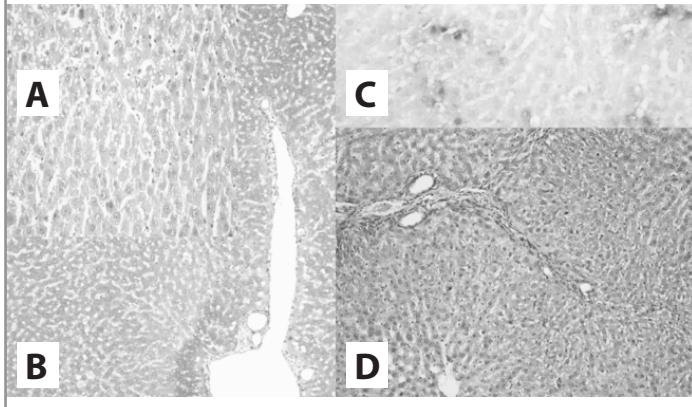
Immunohistochemical markers as, MPO, HSP-70 and IL-6, were studied from the liver tissue samples (Table 4).

Table 4. Immunohistochemical results of the liver tissue.

Liver	Grade	G1 (SHAM)		G2 (ischemia)		G3 (Montelukast)		P value
		Number	%	Number	%	Number	%	
MPO	0	4	57.1%	3	42.9%	6	85.7%	0.233
	1	1	14.3%	4	57.1%	1	14.3%	
	2	1	14.3%	0	0.0%	0	0.0%	
	3	1	14.3%	0	0.0%	0	0.0%	
HSP-70	0	3	42.9%	4	57.1%	2	28.6%	0.462
	1	1	14.3%	3	42.9%	2	28.6%	
	2	1	14.3%	0	0.0%	2	28.6%	
	3	2	28.6%	0	0.0%	1	14.3%	
IL-6	0	0	0.0%	0	0.0%	4	57.1%	0.022
	1	5	71.4%	2	28.6%	2	28.6%	
	2	2	28.6%	3	42.9%	0	0.0%	
	3	0	0.0%	2	28.6%	1	14.3%	

Grade 1, 2 and 3 staining with IL-6 was stronger in G2 than G3 ($P = 0.022$). There was no statistically significant difference found among the groups in terms of MPO staining ($P = 0.233$) and HSP-70 staining ($P = 0.462$).

The histopathologic examples of liver specimens are shown in Figure 2.



A: Grade 3 staining with IL-6; B: Grade 1 staining with IL-6; C: Necrosis; D: Hepatocyte degeneration (x200)

Figure 2. Examples of liver specimen

Discussion

This study investigated the effect of temporary occlusion of the aorta on the development of I/R injury of liver and kidney and the protective effect of montelukast.

Despite recent advances in operative techniques, anesthetic management and postoperative care, TAAS is still associated with significant mortality and morbidity. Harward and colleagues studied 29 patients who had undergone TAAS, and pointed out the rate of multiple organ dysfunction as 34.5% [21]. A temporary discontinuation in splanchnic, renal and spinal cord blood flow is inevitable during the aortic cross-clamping. This ischemia phase lead to the disability of energy metabolism resulting in the abnormality of intracellular ion homeostasis, especially calcium, and cell necrosis [22,23]. I/R injury of the tissue has been connected with lipid peroxidation. Lipid peroxidation breaks down the membrane integrity and inactivates the critical membrane bound enzyme systems. The over-expression and release of inflammatory mediators, cytokines, activation of phospholipase A2 and complement system, effects of adhesion molecules, activation of arachidonic acid system make I/R injury very complicated and difficult to understand [2,24,25].

LTs, which are metabolites of arachidonate, are products of the 5-LO pathway. They are potent chemotactic factors involved in recruitment of cells at the inflammation site, and increase vascular permeability [26]. CysLTs are secreted mainly by eosinophils, mast cells, monocytes and macrophages. The

previous studies reported that, increased generation of 5-LO products, LTs, in post-ischemic organs play an important role in I/R injury [13,27,28].

Montelukast is a selective antagonist of CysLT1 receptor which is used in the treatment of bronchial asthma [29]. It causes a significant dose-related inhibition of superoxide by interfering with the activation of NADPH oxidase. Anderson et al. pointed out that besides its primary mechanism of therapeutic activity, antagonism of CysLT1 receptors, it causes an increase in basal cAMP and cGMP suggesting a non-specific PDE -targeted anti-inflammatory activity [30]. We unfortunately could not measure CysLT1 receptor inhibitor receptor expression in the sample tissues in our study.

Acute renal failure is one of the most frequent complications of thoraco-abdominal aortic surgery [31] and the incidence was reported in literature in a range between 3-34.5% [21,31,32]. Svensson and colleagues claimed that, the renal flow pattern changes against the cortical nephrons even if the aorta being cross-clamped infrarenally [33]. It is a known fact that I/R induces potent tissue injury related to change in microvascular environment. Decrement of renal perfusion and the release of FORs result in vasoconstriction, redistribution of the flow pattern and an increment in vascular permeability [2]. The activated neutrophils release proteases, cytokines, FORs, MPO and other enzymes [34]. In our study, Montelukast treatment significantly ameliorated post-ischemic acute tubular necrosis and considerably limited the structural damage of kidney. Histologically, montelukast treatment reduced tubular cell degeneration, cytoplasmic vacuole formation, hemorrhage and tubular dilatation.

Acute phase proteins, MPO and IL-6 increase with inflammation [35,36]. MPO is the index of leukocyte infiltration into the kidney [36,37]. HSPs comprise a family of stress proteins and provide cellular protection against factors causing cellular injury, including I/R injury. HSP-70 is present in the cytoplasm and nucleus and involved in the early phase of protein maturation, completion of protein translocation into organelles, protein synthesis, and the stabilization of synthesized proteins [38]. HSP-70 is defined as a molecular chaperone which inhibits misfolding of synthesized proteins triggered by I/R, regulates cell growth and maintains cellular integrity [39]. In the present study, the lowest HSP-70 level was measured in the G1 (sham) group then the montelukast group. MPO level was low in sham and montelukast group in kidney tissue. This result showed that the inflammation and injury was significantly lower with this treatment. The decrease in HSP-70 in these groups also was an indirect proof of lower tissue injury and better cellular protection. I/R injury of the liver includes oxidative stress mediated by Kupffer cells, activation of neutrophils, secretion of proteases like MPO, elastase, collagenase and FORs [40]. Dawson and colleagues pointed out that the most important source of

FORs is mitochondria and also showed that the activation of neutrophils by FORs results in cell death [41]. Furthermore, numerous studies have shown that renal injury affects additional organs including liver [42-44]. The microcirculatory destruction that diminishes the liver perfusion occurs especially at the end of 48 hr of reperfusion [2]. We took the liver biopsies at the 48th hour of reperfusion and found out that montelukast treated animals showed less hepatocyte degeneration and steatosis than untreated animals. Also we found out that Grade 1, 2 and 3 staining with IL-6 was stronger in untreated ischemia group.

As a limitation of our study, we did not measure the blood levels of urea, creatinine, alanine aminotransferase, aspartate aminotransferase, lactate dehydrogenase and gamma-glutamyltranspeptidase which probably would have strengthened our results. The study was designed as a histopathological and immunohistochemical investigation. Therefore, the main limitation of our study was that we did not quantify how clinically significant the ischemia/reperfusion injury was. Another proxy for this would be a TUNEL assay to assess for apoptosis which is commonly performed by those studying I/R and may have also been considered

In conclusion, multiple organ dysfunction is a hazardous complication of visceral I/R injury after TAAA repair and requires a multimodal management. Recent developments in operative techniques, anesthetic management and monitoring, pharmacological medications and postoperative care have decreased the risk of TAAA repair but obviously further investigation is necessary. The findings of the current study demonstrated that montelukast has protective effects on both kidney and liver; and it was proved histopathologically and immunohistochemically. The protective effects of montelukast can be attributed to its potential of anti-oxidative and anti-inflammatory actions.

Declaration of conflicting interests

The authors declared no conflicts of interest with respect to the authorship and/or publication of this article.

Funding

The authors received no financial support for the research and/or authorship of this article.

References

1. Welborn MB, Oldenburg HS, Hess PJ, et al. The relationship between visceral ischemia, proinflammatory cytokines, and organ injury in patients undergoing thoracoabdominal aortic aneurysm repair. *Crit Care Med* 2000; 28: 3191-7.
2. Budak B, Seren M, Turan NN, Sakaogullari Z, Ulus AT. The protective effects of resveratrol and L-NAME on visceral organs following aortic clamping. *Ann Vasc Surg* 2009; 23: 675-85.
3. Walker PM. Ischemia/reperfusion injury in skeletal muscle. *Ann Vasc Surg* 1991; 5: 399-402.
4. Bown MJ, Nicholson ML, Bell PR, Sayers RD. Cytokines and inflammatory pathways in the pathogenesis of multiple organ failure following abdominal aortic aneurysm repair. *Eur J Vasc Endovasc Surg* 2001; 22: 485-95.
5. Seekamp A, Warren JS, Remick DG, Till GO, Ward PA. Requirements for tumor necrosis factor-alpha and interleukin-1 in limb ischemia/reperfusion injury and associated lung injury. *The American journal of pathology* 1993; 143: 453-63.
6. Bao XQ, Liu GT. Bicyclol: a novel antihepatitis drug with hepatic heat shock protein 27/70-inducing activity and cytoprotective effects in mice. *Cell Stress Chaperones* 2008; 13: 347-55.
7. Zhang K, Zhao T, Huang X, et al. Preinduction of HSP70 promotes hypoxic tolerance and facilitates acclimatization to acute hypobaric hypoxia in mouse brain. *Cell Stress Chaperones* 2009; 14: 407-15.
8. Latchman DS. Heat shock proteins and cardiac protection. *Cardiovasc Res* 2001; 51: 637-46.
9. DDMosser, A W Caron, L Bourget, C Denis-Larose, B Massie. Role of the human heat shock protein hsp70 in protection against stress-induced apoptosis. *Mol Cell Biol* 1997; 17: 5317-27.
10. Fujibayashi T, Hashimoto N, Jijiwa M, Hasegawa Y, Kojima T, Ishiguro N. Protective effect of geranylgeranylacetone, an inducer of heat shock protein 70, against drug-induced lung injury/fibrosis in an animal model. *BMC Pulm Med* 2009; 9: 45.
11. Choudhury S, Bae S, Ke Q, Lee JY, Kim J, Kang PM. Mitochondria to nucleus translocation of AIF in mice lacking Hsp70 during ischemia/reperfusion. *Basic Res Cardiol* 2011; 106: 397-407.
12. Moreland DB, Soloniuk DS, Feldman MJ. Leukotrienes in experimental spinal cord injury. *Surg Neurol* 1989; 31: 277-80.
13. Sener G, Sehirli O, Velioğlu-Oğünç A, et al. Montelukast protects against renal ischemia/reperfusion injury in rats. *Pharmacol Res* 2006; 54: 65-71.
14. Dامتew B, Marino JA, Fratianne RB, Spagnuolo PJ. Neutrophil lipoxygenase metabolism and adhesive function following acute thermal injury. *J Lab Clin Med* 1993; 121: 328-36.
15. Wallace JL, Beck PL, Morris GP. Is there a role for leukotrienes as mediators of ethanol-induced gastric mucosal damage? *Am J Physiol* 1988; 254:G117-23.
16. Rashmitha N ST, Srinivas CH, Srinivas N, et al. A validated RP-HPLC method for the determination of impurities in montelukast sodium. *EJ Chem* 2010; 7: 555-63.
17. Gedik HS, Korkmaz K, Erdem H, Karakilic E, Lafci G, Ankarali H. Protective effect of heparin in the end organ ischemia/reperfusion injury of the lungs and heart. *J Cardiothorac Surg* 2012; 7: 123.



18. Korkmaz K, Gedik HS, Budak AB, et al. Effect of heparin on neuroprotection against spinal cord ischemia and reperfusion in rats. *Eur Rev Med Pharmacol Sci* 2013; 17: 522-30.
19. Umehara S, Goyagi T, Nishikawa T, Tobe Y, Masaki Y. Esmolol and landiolol, selective beta1-adrenoreceptor antagonists, provide neuroprotection against spinal cord ischemia and reperfusion in rats. *AnesthAnalg*. 2010; 110: 1133-7.
20. Yener AU, Çiçek MC, Genç SB, et al. Protective role of heparin in the injury of the liver and kidney on the experimental model of ischemia/reperfusion. *J Cardiothorac Surg* 2014; 9: 35.
21. Harward TR, Welborn MB 3rd, Martin TD, et al. Visceral ischemia and organ dysfunction after thoracoabdominal aortic aneurysm repair. A clinical and cost analysis. *Ann Surg* 1996; 223: 729-34.
22. Wang Z, Liu Y, Han Y, et al. Protective effects of aliskiren on ischemia-reperfusion-induced renal injury in rats. *Eur J Pharmacol* 2013; 718: 160-6.
23. Yildar M, Aksit H, Korkut O, Ozyigit MO, Sunay B, Seyrek K. Protective effect of 2-aminoethyl diphenylborinate on acute ischemia-reperfusion injury in the rat kidney. *J Surg Res* 2014; 187: 683-9.
24. Nicoud IB, Knox CD, Jones CM, et al. 2-APB protects against liver ischemia-reperfusion injury by reducing cellular and mitochondrial calcium uptake. *Am J Physiol Gastrointest Liver Physiol* 2007; 293: G623-30.
25. Valko M, Leibfritz D, Moncol J, et al. Free radicals and antioxidants in normal physiological functions and human disease. *Int J Biochem Cell Biol* 2007; 39: 44-84.
26. Peters-Golden M, Henderson WR Jr. Leukotrienes. *N Engl J Med* 2007; 357: 1841-54.
27. Takamatsu Y, Shimada K, Chijiwa K, Kuroki S, Yamaguchi K, Tanaka M. Role of leukotrienes on hepatic ischemia/reperfusion injury in rats. *J Surg Res* 2004; 119: 14-20.
28. Lehr HA, Guhlmann A, Nolte D, Keppler D, Messmer K. Leukotrienes as mediators in ischemia-reperfusion injury in a microcirculation model in the hamster. *J Clin Invest* 1991; 87: 2036-41.
29. Virchow JC Jr, Faehndrich S, Nassenstein C, Bock S, Matthys H, Luttmann W. Effect of a specific cysteinyl leukotriene-receptor 1-antagonist (montelukast) on the transmigration of eosinophils across human umbilical vein endothelial cells. *ClinExp Allergy* 2001; 31: 836-44.
30. Anderson R, Theron AJ, Gravett CM, Steel HC, Tintinger GR, Feldman C. Montelukast inhibits neutrophil pro-inflammatory activity by a cyclic AMP-dependent mechanism. *Br J Pharmacol* 2009; 156: 105-15.
31. Cambria RP, Clouse WD, Davison JK, Dunn PF, Corey M, Dorer D. Thoracoabdominal aneurysm repair: results with 337 operations performed over a 15-year interval. *Ann Surg* 2002; 236: 471-9.
32. Jacobs MJ, van Eps RG, de Jong DS, Schurink GW, Mochtar B. Prevention of renal failure in patients undergoing thoracoabdominal aortic aneurysm repair. *J Vasc Surg* 2004; 40: 1067-73.
33. Svensson LG, Crawford ES, Hess KR, Coselli JS, Safi HJ. Thoracoabdominal aortic aneurysms associated with celiac, superior mesenteric, and renal artery occlusive disease: methods and analysis of results in 271 patients. *J Vasc Surg* 1992; 16: 378-89.
34. Adembri G, Kastamoniti E, Bertolozzi I, et al. Pulmonary injury follows systemic inflammatory reaction in infrarenal aortic surgery. *Crit Care Med* 2004; 9: 1170-7.
35. Norwood MG, Bown MJ, Sutton AJ, Nicholson ML, Sayers RD. Interleukin 6 production during abdominal aortic aneurysm repair arises from the gastrointestinal tract and not the legs. *Br J Surg* 2004; 9: 1153-6.
36. Donnahoo KK, Meng X, Ayala A, Cain MP, Harken AH, Meldrum DR. Early kidney TNF-alpha expression mediates neutrophil infiltration and injury after renal ischemia-reperfusion. *Immunology* 2001; 102: 53-8.
37. Lauriat S, Linas SL. The role of neutrophils in acute renal failure. *Semin Nephrol* 1998; 18: 498-504.
38. Ellis RJ, van der Vies SM. Molecular chaperones. *Annu Rev Biochem* 1991; 60: 321-47.
39. Hartl FU, Martin J, Neupert W. Protein folding in the cell: the role of molecular chaperones Hsp70 and Hsp60. *Annu Rev Biophys Biomol Struct* 1992; 21: 293-322.
40. Pan LJ, Zhang ZC, Zhang ZY, et al. Effects and mechanisms of store-operated calcium channel blockade on hepatic ischemia-reperfusion injury in rats. *World J Gastroenterol* 2012; 18: 356-67.
41. Dawson TL, Gores GJ, Nieminen AL, Herman B, Lemasters JJ. Mitochondria as a source of reactive oxygen species during reductive stress in rat hepatocytes. *Am J Physiol* 1993; 264: C961-7.
42. Kadkhodae M, Golab F, Zahmatkesh M, Ghaznavi R, Hedayati M, Arab HA, Ostad SN, Soleimani M. Effects of different periods of renal ischemia on liver as a remote organ. *World J Gastroenterol* 2009; 15: 1113-8.
43. Kaçmaz A, User EY, Sehirlı AO, Tilki M, Ozkan S, Sener G. Protective effect of melatonin against ischemia/reperfusion-induced oxidative remote organ injury in the rat. *Surg Today* 2005; 35: 744-50.
44. Awad AS, Kamel R, Sherief MA. Effect of thymoquinone on hepatorenal dysfunction and alteration of CYP3A1 and spermidine/spermine N-1-acetyl-transferase gene expression induced by renal ischaemia-reperfusion in rats. *J Pharm Pharmacol* 2011; 63: 1037-42.