

## Anti-oxidant, Anti-inflammatory, and Anti-apoptotic Effects of Rutin in Spleen Toxicity Induced by Sodium Valproate in Rats

Nurhan AKARAS<sup>1\*</sup>, Fatih Mehmet KANDEMİR<sup>2</sup>, Hasan ŞİMŞEK<sup>3</sup>, Cihan GÜR<sup>4</sup>, Serpil AYGÖRMEZ<sup>5</sup>

<sup>1</sup> Aksaray University, Faculty of Medicine, Department of Histology and Embryology, Aksaray, Türkiye

<sup>2</sup> Aksaray University, Faculty of Medicine, Department of Medical Biochemistry, Aksaray, Türkiye

<sup>3</sup> Aksaray University, Faculty of Medicine, Department of Physiology, Aksaray, Türkiye

<sup>4</sup> Atatürk University, Faculty of Veterinary, Department of Veterinary Biochemistry, Erzurum, Türkiye

<sup>5</sup> Kafkas University, Faculty of Veterinary, Department of Veterinary Biochemistry, Kars, Türkiye

Nurhan AKARAS ORCID No: 0000-0002-8457-9448

Fatih Mehmet KANDEMİR ORCID No: 0000-0002-8490-2479

Hasan ŞİMŞEK ORCID No: 0000-0001-5573-4923

Cihan GÜR ORCID No: 0000-0001-6775-7858

Serpil AYGÖRMEZ ORCID No: 0000-0002-5675-5096

\*Corresponding author: [nurakaras@hotmail.com](mailto:nurakaras@hotmail.com)

(Received: 20.05.2023, Accepted: 15.06.2023, Online Publication: 22.06.2023)

### Keywords

Sodium  
Valproate,  
Rutin,  
Oxidative  
stress,  
Inflammation,  
Apoptosis,  
Spleen Toxicity

**Abstract:** Long-term exposure to sodium valproate, an anti-epileptic drug, causes toxic effects in tissues, especially by increasing oxidative stress and inflammation. Rutin is a flavanoid with anti-oxidant, anti-inflammatory and anti-apoptotic effects found naturally in many plants. In this study, we aimed to investigate the effects of rutin, a natural anti-oxidant, on sodium valproate-induced spleen tissue damage. 35 male rats were divided into 5 groups as control, sodium valproate, rutin, sodium valproate+Rutin 50 and sodium valproate+Rutin 100 groups. For 14 days, 500 mg/kg dose of sodium valproate and 50 or 100 mg/kg of rutin were administered by oral gavage. On day 15, spleen tissues were removed and biochemical methods, oxidative stress, inflammation and apoptotic parameters were analyzed and histologic analysis was performed. The levels of sodium valproate-induced oxidative stress, inflammation and apoptosis parameters increased in spleen tissues compared to the control group ( $p<0.05$ ). With routine administration, all of these sodium valproate-induced increases were decreased ( $p<0.05$ ). It was concluded that rutin has potential protective properties against the toxic effect caused by sodium valproate exposure in spleen tissues.

## Sıçanlarda Sodyum Valproat ile İndüklenen Dalak Toksisitesinde Rutinin Anti-oksidan, Anti-inflamatuvar ve Anti-apoptotik Etkileri

### Anahtar Kelimeler

Sodyum  
Valproat,  
Rutin,  
Oksidatif  
stres,  
İnflamasyon,  
Apoptoz,  
Dalak  
Toksisitesi

**Öz:** Anti-epileptik bir ilaç olan sodyum valproatın uzun süreli maruziyeti, dokularda özellikle oksidatif stres ve inflamasyon artışına neden olarak toksik etki oluşturur. Rutin, birçok bitkide doğal olarak bulunan anti-oksidan, anti-inflamatuvar ve anti-apoptotik etkilere sahip bir flavanoiddir. Bu çalışmada, sodyum valproat kaynaklı dalak doku hasarı üzerine doğal bir anti-oksidan olan rutin etkilerinin araştırılması amaçlanmıştır. 35 adet erkek sıçan kontrol, sodyum valproat, rutin, sodyum valproat+Rutin 50 ve sodyum valproat+Rutin 100 grupları olmak üzere 5 gruba ayrıldı. 14 gün boyunca 500 mg/kg dozda sodyum valproat uygulamasıyla birlikte 50 veya 100 mg/kg rutin uygulaması oral gavaj yolla yapıldı. 15. günde dalak dokuları alındı ve biyokimyasal yöntemler ile oksidatif stres, inflamasyon ve apoptotik parametrelerin analizi ve histolojik analizler yapıldı. Dalak dokularında sodyum valproat kaynaklı oksidatif stres, inflamasyon ve apoptoz parametrelerin düzeyleri kontrol grubuna göre artmıştır ( $p<0,05$ ). Rutin uygulamasıyla birlikte sodyum valproata bağlı tüm bu artış miktarlarında azalmalar meydana gelmiştir ( $p<0,05$ ). Dalak dokularında sodyum valproat maruziyetinin neden olduğu toksik etkiye karşı rutin potansiyel koruyucu özelliklere sahip olduğu sonucuna varıldı.

## 1. INTRODUCTION

Sodium valproate (VPA) is an significant fatty acid (2-propylpentenoic acid) that has been used for more than 30 years to treat epilepsy, which affects more than 70 million people [1,2]. VPA is also used in the treatment of migraine and is an FDA-approved medicine [3]. Among the main reasons for the use of VPA in the treatment of seizure disorders is its GABA transaminase inhibitory action [4].

Despite the proven efficacy of VPA, it has varying side effects [5]. VPA toxicity can occur with dose adjustments to reach therapeutic levels in patients with metabolic disorders, drug-drug interactions, or self-harm attempts [6]. Its toxic effects are seen in multiple organ systems such as the hematological, nervous, and digestive systems [7]. Long-term use of VPA may cause nausea, vomiting, anorexia, sedation, weight gain, hair loss, hepatotoxicity, encephalopathy, and myopathy [8]. For all these reasons, the off-target toxicity of VPA, one of the drugs used against neurological diseases, remains a significant concern for some patients undergoing treatment [9]. Among the various mechanisms underlying the toxic effect of VPA, induction of oxidative stress and inflammation are among the most well-known. Therefore, research on natural active ingredients that regulate these mechanisms against VPA toxicity continues intensively [1].

Oxidative stress results from a disturbance in the balance between the anti-oxidant system and the production of reactive oxygen species (ROS) in the body in favor of ROS [10,11]. Lipid peroxidation produces MDA as a breakdown by-product. Superoxide dismutase (SOD), Catalase (CAT), and Glutathione peroxidase (GPx) are anti-oxidant enzymes that provide anti-oxidant defense in the body [12,10].

Flavonoids are secondary metabolites found naturally in plants [13]. Flavonoids are a popular research area due to their anti-oxidant, anti-inflammation, anti-allergic, anti-viral, anti-bacterial, and anti-tumor properties [14]. Rutin (3,3',4',5,7-pentahydroxyflavone-3-rhamnoglucoside - RUT) is a flavonoid glycoside found naturally in buckwheat, spinach, tomato leaves, apples, onions, and tea [15]. In studies, it has been reported that RUT has protective effects against many diseases, especially against diseases caused by oxidative stress and lipid peroxidation, due to its anti-inflammatory, anti-oxidant, anti-hypertensive, anti-apoptotic, anti-autophagic, and neuroprotective properties [16]. RUT can be considered a non-toxic and non-oxidizing molecule [17].

This study aimed to investigate the anti-oxidant, anti-inflammatory, and anti-apoptotic effects of RUT on VPA-induced splenic toxicity in rats by biochemical and histological methods.

## 2. MATERIAL AND METHOD

### 2.1. Drug and Chemicals

VPA (Depakin, Sanofi, Turkey) and RUT ( $\geq 94\%$ , Sigma, USA) and other chemicals (analytical purity, Sigma, USA) were used.

### 2.2. Groups and Experiment Protocol

In the experiment, 220-250 g, 10-12 weeks old, 35 male Sprague dawley rats were used. Rats were housed in standard cages with a constant temperature of 24-25°C and a 12-hour dark-light cycle. Rats were fed ad libitum with normal drinking water and standard rat chow. Ethics committee approval was obtained from Atatürk University Animal Experiments Local Ethics Committee (12.04.2021 - 2021/3-106). All animal experiments were performed at Atatürk University Animal Experiment Center. Experimental animals were randomly divided into 5 groups with 7 rats in each group. Doses were determined by using the literature [1].

1. Control Group: Saline was given by oral gavage for 14 days.
2. Rutin Group (RUT): 100 mg/kg rutin was given by oral gavage for 14 days.
3. Sodium Valproate Group (VPA): 500 mg/kg sodium valproate was given by oral gavage for 14 days.
4. Sodium Valproate+Rutin 50 Group (VPA+RUT50): 500 mg/kg sodium valproate was given by oral gavage for 14 days and 30 minutes later 50 mg/kg rutin was given by oral gavage for 14 days.
5. Sodium Valproate+Rutin 100 Group (VPA+RUT100): 500 mg/kg sodium valproate was given by oral gavage for 14 days and 30 minutes later 100 mg/kg oral gavage rutin was given for 14 days.

### 2.3. Tissue Collection

24 hours after the last administration of RUT (day 15), rats were decapitated under mild sevoflurane anesthesia, and spleen tissues were removed. Some of the spleen tissues were placed in 10% formalin solution for histopathologic analyses while the other part was stored at -20 °C until biochemical analyses were performed.

### 2.4. Lipid Peroxidation Analysis

MDA level was analyzed for lipid peroxidation. For the analysis, the spleen tissues of rats were homogenized in 1.15% potassium chloride (KCl) solution, and the homogenates were centrifuged at 3,500 RPM for 15 min. The supernatant obtained was used for analysis. MDA levels were determined spectrophotometrically (Bio-Tek, USA) using the method developed by Placer et al. [18].

## 2.5. Analysis of Anti-oxidant Markers

SOD, CAT and GPx activities, and Glutathione (GSH) levels were measured in rat spleen tissues for anti-oxidant status analysis. For the SOD and CAT activity, supernatants were obtained as in lipid peroxidation. The supernatants used for the determination of GPx activity and GSH levels were obtained after centrifugation at 10,000 RPM for 20 minutes. Previous methods were used for SOD [19], CAT [20], GPx [21] activity, and GSH [22] level analysis. Lowry et al. method was used for spleen tissue protein content analysis, which is necessary for the calculation of enzyme activities [23]. The spectrophotometric method (Bio-Tek, U.S.A.) was used in the analysis.

## 2.6. Analysis of Inflammatory Cytokines

Nuclear Factor Kappa B (NF- $\kappa$ B) and Tumor Necrosis Factor- $\alpha$  (TNF- $\alpha$ ) levels and P38 mitogen-activated protein kinases (P38 MAPK) activity were determined from spleen tissues using a commercial rat ELISA kit (Sunred, China).

## 2.7. Apoptosis Markers Analysis

Apoptotic factor Bax and anti-apoptotic factor Bcl-2 levels were determined using a commercial rat ELISA kit (Sunred, China) according to the manufacturer's instructions.

## 2.8. Histopathological Analysis

Spleen tissues were removed from anesthetized rats and fixed in 10% formalin solution for 48 hours. Spleen tissues were washed under running water overnight in accordance with the routine tissue monitoring procedure and then subjected to dehydration by passing through an ascending alcohol series (70% (1 hour), 80% (1 hour), 96% (1 hour) and 99% (1 hour)). Following alcohol, the tissues were placed in xylol in two stages for one hour and then treated with paraffin and infiltrated. The tissues were then embedded in paraffin in metal blocks and turned into hard blocks. The paraffin blocks were sectioned into 5-micrometer sections on slides using a semi-automatic microtone. Hematoxylin and Eosin staining was performed to examine the tissues in the sections. The stained sections were then examined using a binocular Olympus Cx43 light microscope (Olympus Inc., Tokyo, Japan) and photographed with an EP50 camera (Olympus Inc., Tokyo, Japan).

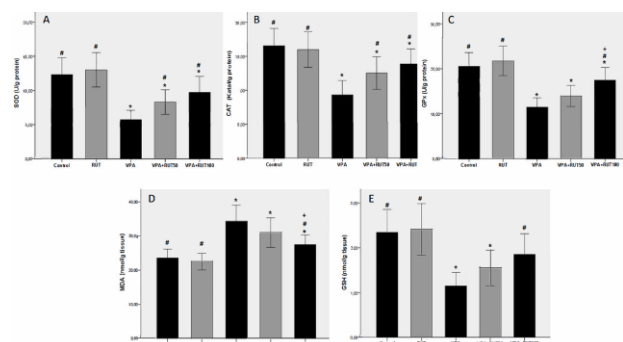
## 2.9. Statistical Analysis

Data obtained from all analyses were presented as mean  $\pm$  standard deviation using GraphPad Prism 5.0 software. Data were analyzed using one-way ANOVA with Tukey's post hoc tests for multiple comparisons. A value of  $p < 0.05$  was accepted for statistical significance.

## 3. RESULTS

### 3.1. Oxidative Stress Findings

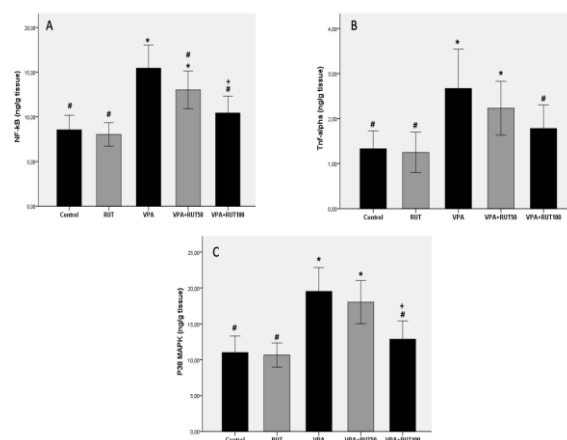
MDA levels for lipid peroxidation and SOD, CAT, GPx activities, and GSH level for anti-oxidant level were analyzed in spleen tissue. In the VPA group, the activities of SOD, CAT, GPx, and GSH levels were decreased, and the MDA level was increased compared to the control ( $p < 0.05$ ). Compared to the VPA group, SOD and CAT activities were increased in the VPA+RUT50 group ( $p < 0.05$ ), while all of them were increased in the VPA+RUT100 group ( $p < 0.05$ ). The 100 mg/kg dose of RUT reversed the negative effect of VPA administration on MDA and GSH levels ( $p < 0.05$ ).



**Figure 1.** The level of anti-oxidants and oxidant in the spleen tissue of rats. All data were expressed as mean  $\pm$  SD. Statistical significance (Control vs others: \* $p < 0.05$ , VPA vs others: # $p < 0.05$ , VPA+RUT50 vs VPA+RUT100: + $p < 0.05$ ) was analyzed using One Way ANOVA.

### 3.2. Inflammatory Cytokines Findings

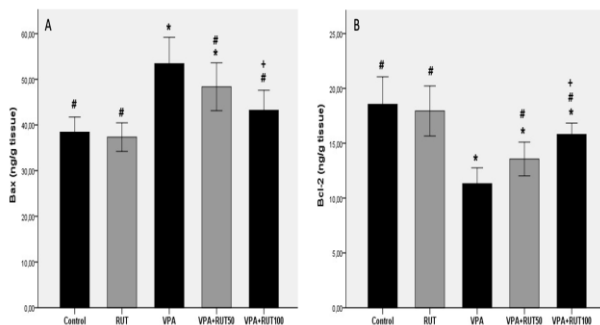
NF- $\kappa$ B, TNF- $\alpha$ , and P38 MAPK levels were measured in spleen tissue to show the inflammatory effect. P38 MAPK plays a significant role in the inflammatory response in many cell types [24]. NF- $\kappa$ B, TNF- $\alpha$ , and P38 MAPK levels increased in the VPA group compared to the control ( $p < 0.05$ ). When RUT was treated at 100 mg/kg dose, the parameters were decreased compared to the VPA group ( $p < 0.05$ ).



**Figure 2.** The level NF- $\kappa$ B, TNF- $\alpha$ , and P38 MAPK and in the spleen tissue of rats. All data were expressed as mean  $\pm$  SD. Statistical significance (Control vs others: \* $p < 0.05$ , VPA vs others: # $p < 0.05$ , VPA+RUT50 vs VPA+RUT100: + $p < 0.05$ ) was analyzed using One Way ANOVA.

### 3.3. Apoptosis Findings

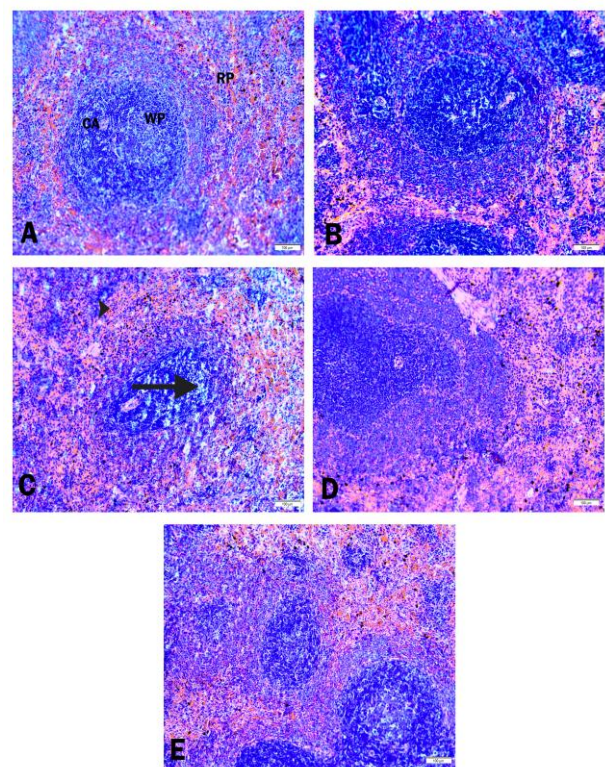
To investigate the apoptotic pathway in spleen tissue, the Bax/Bcl-2 ratio, which shows the effect of pro-apoptotic and anti-apoptotic factors, was analyzed (Figure 3A-3B). Compared to the control group, the Bax/Bcl-2 ratio was increased in the VPA group with an increase in Bax and a decrease in Bcl-2 ( $p < 0.05$ ). At both doses (50mg and 100mg), RUT counteracted this deleterious effect of VPA and decreased the Bax/Bcl-2 ratio ( $p < 0.05$ ).



**Figure 3.** The level of Bax, and Bcl-2 in the spleen of rats. All data were expressed as mean  $\pm$  SD. Statistical significance (Control vs others: \* $p < 0.05$ , VPA vs others: # $p < 0.05$ , VPA+RUT50 vs VPA+RUT100: + $p < 0.05$ ) was analyzed using One Way ANOVA.

### 3.4. Histopathologic Findings

When the spleen sections of the control group rats were examined, it was observed that the red and white pulps were well differentiated. The borders of the pulps were clear, and marginal zones and periarterial lymphatic sheath (PALS) could be distinguished. Splenic cords, venous sinuses, and veins in the spleen showed normal structure (Figure 4A). RUT administration alone preserved the histomorphology of the spleen (Figure 4B). When the spleens in the VPA group were examined, it was noted that the red and white pulp structure was disrupted and the white pulp was depleted. Vacuolated cells, dilatation of sinusoids, and hemorrhage were observed especially in the VPA groups (Figure 4C). There was no obvious damage in VPA+RUT 50 and VPA+RUT 100 groups compared to VPA. The boundaries between white and red pulps were clear, morphology was largely normal and vacuolization was reduced (Figure 4D,4E).



**Figure 4.** Photomicrographs of histological changes in spleen tissue (H&E staining, 100  $\mu$ m), (A) Control group, CA: central arteriole, WP: White pulp, RP: Red pulp, (B) RUT group, (C) VPA group, arrow: vacuolization, arrowhead: hemorrhage, (D) VPA+RUT 50, (E) VPA+RUT 100

## 4. DISCUSSION AND CONCLUSION

Epilepsy is one of the most common neurological disorders worldwide, and approximately 90% of patients with epilepsy live in developing regions [25]. Anti-epileptic drugs (AEDs) used in the treatment of epilepsy are widely used by patients [26]. Approximately one-third of patients given AEDs as treatment options do not achieve optimal seizure control. Patients adequately treated with AEDs and who do not become seizure-free are now considered to have drug-resistant epilepsy [27]. VPA is an AED used to treat various seizure disorders. However, serious side effects such as hepatotoxicity, pancreatitis, thrombocytopenia, and platelet aggregation are associated with VPA treatment [25]. After treatment with VPA, changes may occur in the number and characteristics of T lymphocytes in the spleen, a central organ of the immune system [28]. VPA has been reported to cause tissue damage mainly by causing oxidative stress followed by inflammation and apoptosis [16]. The discovery of anti-oxidant, anti-inflammatory, anti-autophagic, and anti-apoptotic properties in herbal medicines has led to renewed interest in these compounds [29]. RUT has different protective effects against oxidative stress-mediated diseases and lipid peroxidation in vitro and in vivo [1]. Metabolomic studies of VPA-induced toxicity have primarily focused on changes in serum and urine metabolites but have not evaluated changes in major organs or tissues [30]. Therefore, the present study was designed to determine the effect of RUT in preventing VPA-induced spleen toxicity in spleen tissue.

Since lipids are the most important component of the cell membrane, excessive production of free radicals causes lipid peroxidation in the cell [31]. Triglycerides play important roles in controlling interactions between lipoproteins. However, triglycerides have also been reported to play an active role in HDL remodeling and cholesterol esterification in human plasma. Oxidative stress reactions occur as a result of excessive ROS formation. Many diseases such as inflammation, liver diseases, atherosclerosis and neurodegenerative diseases are largely caused by oxidative stress [32,33]. Since MDA is the end product of polyunsaturated fatty acids, it is the strongest indicator of oxidative stress [31]. There are defense systems consisting of enzymatic and non-enzymatic anti-oxidant components to reduce the effect of oxidants in the cell. Some enzymes such as SOD, CAT, and GPx are some of the anti-oxidant enzymes involved in the removal of ROS from cells [34]. GSH removes radical species such as superoxide radicals and hydrogen peroxide from the cell and protects membrane protein thiols [35]. Glutathione-S-transferases (GSTs) are major enzymes of the phase II biotransformation system. GSTs can catalyze the conjugation of GSH to the electrophilic centers of many endogenous or exogenous toxic compounds including chemical carcinogens, oxidative stress products, insecticides, herbicides, and cancer chemotherapeutic agents [36,37]. The preferential reaction of GSTs with GSH through their enzymatic action results in the protection of cellular components [38].

In the present study, VPA administration in spleen tissue increased MDA levels and decreased GSH levels and SOD, CAT, and GPx activities. The decrease in GSH levels and the significant decrease in SOD, CAT, and GPx activities compared to control levels indicate that anti-oxidant capacity decreased and the increase in MDA levels indicates that oxidant capacity increased, in which case VPA increased oxidative stress in spleen tissue. On the other hand, RUT administration together with VPA reversed this situation and caused a decrease in oxidative stress. RUT showed this effect more prominently, especially at the dose of 100 mg/kg. Our *in vivo* findings are consistent with previous studies demonstrating the anti-oxidant and free radical scavenging properties of RUT in spleen tissue [17,39].

Inflammation is among the adaptive responses of the body to various damages, including biological and chemical factors [40]. Excessive ROS production is associated with the activation of inflammatory pathways. Among these pathways, the NF- $\kappa$ B signaling pathway is the main signal transduction pathway involved in gene regulation and activation of some proinflammatory cytokines including TNF- $\alpha$  [41]. TNF- $\alpha$  also regulates various signaling pathways such as inflammation and apoptosis. TNF- $\alpha$  has a vital function in the important innate immune response and cellular activation, followed by proliferation and programmed cell death or necrosis [42]. P38 MAPK promotes phosphorylation of I $\kappa$ B, leading to dissociation of NF- $\kappa$ B and I $\kappa$ B complexes [13]. In the present study, VPA administration increased the level of inflammation by significantly increasing NF-

$\kappa$ B and TNF- $\alpha$  levels and P38 MAPK activity reflecting inflammatory responses. On the other hand, RUT treatment showed anti-inflammatory properties by decreasing the levels and activity of these markers.

Apoptosis, known as programmed cell death, plays a critical role in both embryonic development and in the survival and function of developed tissues [43]. ROS are largely produced in mitochondria and have a significant impact on the development of apoptosis [44]. The mitochondrial pathway, which plays an important role in the apoptosis process, is controlled by members of the Bcl-2 protein family, which includes Bax and Bcl-2. An increase in the Bax/Bcl-2 ratio in favor of Bax leads to an increase in cytochrome c levels in the cytoplasm. This activates the caspase enzyme cascade, resulting in cell death [45,46]. In the current study, it was determined that VPA caused activation of the mitochondrial apoptotic pathway by increasing the Bax/Bcl-2 ratio together with oxidative damage in spleen tissue. On the other hand, RUT showed anti-apoptotic properties by acting in the opposite direction of VPA by decreasing both ROS formation and Bax/Bcl-2 ratio.

The findings of this study suggest that suppression of oxidative stress, inflammatory response, and apoptosis by RUT may be an effective strategic approach for the treatment of VPA-induced splenic toxicity.

## REFERENCES

- [1] Kandemir FM, Ileriturk M, Gur C. Rutin protects rat liver and kidney from sodium valproate-induced damage by attenuating oxidative stress, ER stress, inflammation, apoptosis and autophagy. *Mol Biol Rep.* 2022;49(7):6063-74.
- [2] Phillips A, Bullock T, Plant N. Sodium valproate induces apoptosis in the rat hepatoma cell line, FaO. *Toxicology.* 2003;192(2-3):219-27.
- [3] Parikh SK, Silberstein SD. Current status of antiepileptic drugs as preventive migraine therapy. *Curr Treat Options Neurol.* 2019;21(4):16.
- [4] de Campos Vidal B, Mello MLS. Sodium valproate (VPA) interactions with DNA and histones. *Int J Biol Macromol.* 2020;163, 219-231.
- [5] Khani S, Hejazi SA, Yaghoubi M, Sharifipour E. Comparative study of magnesium, sodium valproate, and concurrent magnesium-sodium valproate therapy in the prevention of migraine headaches: a randomized controlled double-blind trial. *J Headache Pain.* 2021;22(1), 1-10.
- [6] Patel AR, Nagalli S. Valproate toxicity. [Updated 2023 May 17]. In: StatPearls [Internet]. Treasure Island (FL): StatPearls Publishing; 2023 May-. Available from: <https://www.ncbi.nlm.nih.gov/books/NBK560898/>
- [7] Mei X, Wu HC, Ruan M, Cai LR. Acute liver failure with thrombotic microangiopathy due to sodium valproate toxicity: A case report. *World J Clin Cases.* 2021;9(17):4310-17.
- [8] Sharma A, Sinha S, Narang A, Chouhan DK, Gupta S. Waddling Gait: A complication of valproate

- therapy and a thought beyond vitamin d deficiency. Sultan Qaboos Univ Med J. 2020;20(1):e104-e108.
- [9] Ola OS, Adewole KE. Anticlastogenic and hepatoprotective effects of kolaviron on sodium valproate-induced oxidative toxicity in wistar rats. Egyptian Journal of Basic and Applied Sciences. 2021;8(1):167-79.
- [10] Ayna A, Darendelioğlu E. Evaluation of the biological activities of royal jelly on prostate and breast cancer cells. Türk Doğa ve Fen Dergisi. 2022;11(3):166-70.
- [11] Ayna A. Apoptotic effects of beta-carotene, alpha-tocopherol and ascorbic acid on PC-3 prostate cancer cells. Hacettepe Journal of Biology and Chemistry. 2020;48(3):211-18.
- [12] Varışlı B, Caglayan C, Kandemir FM, Gür C, Ayna A, Genç A, et al. Chrysin mitigates diclofenac-induced hepatotoxicity by modulating oxidative stress, apoptosis, autophagy and endoplasmic reticulum stress in rats. Mol Biol Rep. 2023;50(1):433-42.
- [13] Caglayan C, Kandemir FM, Darendelioğlu E, Yıldırım S, Kucukler S, Dortbudak MB. Rutin Ameliorates Mercuric Chloride-Induced Hepatotoxicity in Rats via Interfering with Oxidative Stress, Inflammation And Apoptosis. J Trace Elem Med Biol 2019;56:60-68
- [14] Kandemir FM, Caglayan C, Aksu EH, Yıldırım S, Kucukler S, Gur C, et al. Protective effect of rutin on mercuric chloride-induced reproductive damage in male rats. Andrologia 2020;52(3):e13524.
- [15] Caglayan C, Kandemir FM, Yıldırım S, Kucukler S, Eser G. Rutin protects mercuric chloride-induced nephrotoxicity via targeting of aquaporin 1 level, oxidative stress, apoptosis and inflammation in rats. J Trace Elem Med Biol. 2019;54:69-78.
- [16] Çelik H, Kandemir FM, Caglayan C, Özdemir S, Çomaklı S, Kucukler S, et al. Neuroprotective effect of rutin against colistin-induced oxidative stress, inflammation and apoptosis in rat brain associated with the CREB/BDNF expressions. Mol Biol Rep 2020;47(3):2023-34.
- [17] Kandemir FM, Ozkaraca M, Yıldırım BA, Hanedan B, Kirbas A, Kilic, et al. Rutin attenuates gentamicin-induced renal damage by reducing oxidative stress, inflammation, apoptosis, and autophagy in rats. Renal failure. 2015;37(3):518-525.
- [18] Placer ZA, Cushman LL, Johnson BC. Estimation of product of lipid peroxidation (malonyl dialdehyde) in biochemical systems. Anal Biochem 1966;16(2):359-64.
- [19] Sun Y, Oberley LW, Li Y. A simple method for clinical assay of superoxide dismutase. Clin Chem. 1988;34(3):497-500.
- [20] Aebi H. Catalase in vitro. Methods Enzymol 1984;105:121-26.
- [21] Lawrence RA, Burk RF. Glutathione peroxidase activity in selenium-deficient rat liver. Biochem Biophys Res Commun. 1976;71(4):952-58.
- [22] Sedlak J, Lindsay RH. Estimation of total, protein-bound, and nonprotein sulfhydryl groups in tissue with ellman's reagent. Anal Biochem. 1968;25(1):192-205.
- [23] Lowry OH, Rosebrough NJ, Farr AL, Randall RJ. Protein Measurement with the Folin Phenol Reagent. J Biol Chem. 1951;193(1):265-75.
- [24] Lo U, Selvaraj V, Plane JM, Chechneva OV, Otsu K, Deng W. p38 $\alpha$  (MAPK14) critically regulates the immunological response and the production of specific cytokines and chemokines in astrocytes. Scientific reports. 2014;4(1):7405.
- [25] Ardianto C, Wardani HA, Nurrahmi N, Rahmadi M, Khotib J. Alpha-lipoic acid ameliorates sodium valproate-induced liver injury in mice. Vet World. 2020;13(5):963-66.
- [26] Işık M, Demir Y, Kırıcı M, Demir R, Şimşek F, Beydemir Ş. Changes in the anti-oxidant system in adult epilepsy patients receiving anti-epileptic drugs. Arch Physiol Biochem 2015;121(3):97-102.
- [27] Beydemir Ş, Demir Y. Antiepileptic drugs: Impacts on human serum paraoxonase-1. J Biochem Mol Toxicol. 2017;31(6).
- [28] Mozūraitė R, Stakišaitis D, Didžiapetrienė J, Balnytė I, Matusevičius P, Valančiūtė A. Gender-related rat gl. thymus and spleen changes under the influence of Sodium valproate. In "Baltic Morphology VII Scientific Conference" Morphological Sciences in the Experimental and Clinical Medicine": November 7-9, 2013, Rīga, Latvia: abstract book/Rīga Stradiņš University (RSU). [Institute of Anatomy and Anthropology]; Committee: Māra Pilmane [et al.]. Rīga: Rīga Stradiņš University, 2013.
- [29] Yardım A, Gur C, Comaklı S, Ozdemir S, Kucukler S, Celik H, et al. Investigation of the effects of berberine on bortezomib-induced sciatic nerve and spinal cord damage in rats through pathways involved in oxidative stress and neuroinflammation. Neurotoxicology. 2022;89:127-39.
- [30] Gao Y, Jiang D, Wang C, An G, Zhu L, Cui C. Comprehensive analysis of metabolic changes in male mice exposed to sodium valproate based on GC-MS analysis. Drug Des Devel Ther. 2022:1915-30.
- [31] İleriturk M, Kandemir O, Akaras N, Simsek H, Genc A, Kandemir FM. Hesperidin has a protective effect on paclitaxel-induced testicular toxicity through regulating oxidative stress, apoptosis, inflammation and endoplasmic reticulum stress. Reprod Toxicol. 2023;118:108369.
- [32] Palabıyık E, Sulumer AN, Uguz H, Avcı B, Askın S, Askın H, et al. Assessment of hypolipidemic and anti-inflammatory properties of walnut (*Juglans regia*) seed coat extract and modulates some metabolic enzymes activity in triton WR-1339-induced hyperlipidemia in rat kidney, liver, and heart. J Mol Recognit. 2023;36(3):e3004.
- [33] Korkmaz IN, Türkeş C, Demir Y, Öztekin A, Özdemir H, Beydemir Ş. Biological evaluation and in silico study of benzohydrazide derivatives as paraoxonase 1 inhibitors. J Biochem Mol Toxicol. 2022;36(11):e23180.

- [34] Akaras N, Gur C, Kucukler S, Kandemir FM. Zingerone reduces sodium arsenite-induced nephrotoxicity by regulating oxidative stress, inflammation, apoptosis and histopathological changes. *Chem Biol Interact.* 2023;374:110410.
- [35] Ömür AD, Kandemir FM, Yıldırım BA. Protective effect of dandelion (*Taraxacum officinale*) extract Against gentamicin-induced reproductive damage in male rats. *Kafkas Univ. Vet. Fak.* 2016;22:929-36.
- [36] Özaslan MS, Demir Y, Aksoy M, Küfrevioğlu ÖI, Beydemir Ş. Inhibition effects of pesticides on glutathione-S-transferase enzyme activity of Van Lake fish liver. *J Biochem Mol Toxicol.* 2018;32(9):e22196.
- [37] Türkeş C, Kesebir AÖ, Demir Y, Küfrevioğlu ÖI, Beydemir Ş. Calcium channel blockers: The effect of glutathione S-Transferase enzyme activity and molecular docking studies. *ChemistrySelect.* 2021;6(40):11137-43.
- [38] Türkeş C, Demir Y, Beydemir Ş. Infection medications: Assessment in-vitro glutathione S-Transferase inhibition and molecular docking study. *ChemistrySelect.* 2021;6(43):11915-24.
- [39] Aksu EH, Kandemir FM, Özkaraca M, Ömür AD, Küçükler S, Çomaklı S. Rutin ameliorates cisplatin-induced reproductive damage via suppression of oxidative stress and apoptosis in adult male rats. *Andrologia.* 2017;49(1):e12593.
- [40] Caglayan C, Kandemir FM, Darendelioğlu E, Küçükler S, Ayna A. Hesperidin protects liver and kidney against sodium fluoride-induced toxicity through anti-apoptotic and anti-autophagic mechanisms. *Life Sciences.* 2021;281:119730.
- [41] Caglayan C, Kandemir FM, Ayna A, Gür C, Küçükler S, Darendelioğlu E. Neuroprotective effects of 18 $\beta$ -glycyrrhetic acid against bisphenol A-induced neurotoxicity in rats: involvement of neuronal apoptosis, endoplasmic reticulum stress and JAK1/STAT1 signaling pathway. *Metab Brain Dis.* 2022;37(6):1931-40.
- [42] Yardım A, Kandemir FM, Çomaklı S, Özdemir S, Caglayan C, Kucukler S, et al. Protective effects of curcumin against paclitaxel-induced spinal cord and sciatic nerve injuries in rats. *Neurochem Res.* 2021;46:379-95.
- [43] Şimşek H, Demiryürek Ş, Demir T, Atabay HD, Çeribasi AO, Bayraktar R, et al. Assessment of expressions of Bcl-XL, b-FGF, Bmp-2, Caspase-3, PDGFR- $\alpha$ , Smad1 and TGF- $\beta$ 1 genes in a rat model of lung ischemia/reperfusion. *Iran J Basic Med Sci.* 2016;19(2):209-14.
- [44] Simsek H, Akaras N. Acacetin ameliorates acetylsalicylic acid-induced gastric ulcer in rats by interfering with oxidative stress, inflammation, and apoptosis. *Int J Med Biochem.* 2023;6(2):96-103.
- [45] Kucukler S, Caglayan C, Darendelioğlu E, Kandemir FM. Morin attenuates acrylamide-induced testicular toxicity in rats by regulating the NF- $\kappa$ B, Bax/Bcl-2 and PI3K/Akt/mTOR signaling pathways. *Life Sciences.* 2020;261:118301.
- [46] Şimşek H, Akaras N, Gür C, Küçükler S, Kandemir FM. Beneficial effects of Chrysin on Cadmium-induced nephrotoxicity in rats: Modulating the levels of Nrf2/HO-1, RAGE/NLRP3, and Caspase-3/Bax/Bcl-2 signaling pathways. *Gene.* 2023;875:147502.