

Uterine Leiomyosarcoma and Bilateral Ovarian Cysts Subsequent to Mammary Tumor in a Guinea Pig (*cavia porcellus*)

Zeynep GÜNAY UÇMAK^{1,*}, Egemen MAHZUNLAR², Aslihan BAYKAL¹, İsmail KIRŞAN¹, Özge ERDOĞAN BAMAÇ³, Necati ÖZTÜRK²

¹Department of Obstetrics and Gynaecology, Faculty of Veterinary Medicine, Istanbul University- Cerrahpaşa, Istanbul, Türkiye

²Institute of Graduate Education, Istanbul University- Cerrahpaşa, Istanbul, Türkiye

³Department of Pathology, Faculty of Veterinary Medicine, Istanbul University- Cerrahpaşa, Istanbul, Türkiye

ABSTRACT

A 5-year-old, intact female guinea pig was brought to our clinic with a complaint of a large mass in the right mammary lobe. According to ultrasonographic examination, the mass was encapsulated, had a diameter of 8.1 cm, exhibited a polycystic structure, mixed echogenicity, and mixed vascularization. The patient underwent mastectomy. Histopathological analysis of the mass revealed a diagnosis of solid carcinoma (Grade-III). Approximately 2.5 months after mastectomy, the guinea pig developed abdominal swelling. Upon laparotomy, cysts were identified in both ovaries, and a mass containing leiomyosarcoma on the corpus uteri was detected. In conclusion, guinea pigs with a history of mammary tumors should be evaluated for genital organ pathologies as a precaution against the possibility of metastasis at the earliest opportunity.

Keywords: Guinea pig, Mammary tumor, Ovarian cysts, Uterine leiomyosarcoma

Bir Kobayda (*cavia porcellus*) Meme Tümörü Sonrası Uterus Leiomyosarkomu ve Bilateral Over Kistleri

ÖZ

Beş yaşında, kısırlaştırılmamış, dişi kobay sağ meme lobunda bir kitle şikayeti ile kliniğimize getirildi. Ultrasonografik muayeneye göre kitle; kapsüllü, 8,1 cm çapında, polikistik yapıda, miks ekojenite ve miks vaskülarizasyona sahipti. Hastaya mastektomi uygulandı. Kitlenin histopatolojisi sonucunda solid karsinom teşhisi konuldu (Grade-III). Mastektomiden ortalama 2,5 ay sonra kobayda karın şişliği meydana geldi. Laparotomi sonrasında her iki overde de kist ve korpus uteri üzerinde leiomyosarkom içeren kitle saptandı. Sonuç olarak, meme tümörü öyküsü olan gine piglerde metastas ihtimaline karşı genital organ patolojileri klinik açıdan mümkün olan en kısa süre içerisinde değerlendirilmelidir.

Anahtar kelimeler: Kobay, Meme tümörü, Ovaryan kist, Uterus leiomyosarkomu.

To cite this article: Uçmak ZG, Mahzunlar E, Baykal A, Kirşan İ, Bamaç ÖE, Öztürk N. Uterine Leiomyosarcoma and Bilateral Ovarian Cysts Subsequent to Mammary Tumor in a Guinea Pig (*cavia porcellus*) Kocatepe Vet J. (2023) 16(3):459-463

Submission: 12.06.2023 Accepted: 04.09.2023 Published Online: 11.09.2023

ORCID ID; ZGU: 0000-0003-2530-1291, EM: 0000-0002-6815-6082, AB: 0000-0002-2107-1874, İK: 0000-0003-0780-0118, ÖEB: 0000-0002-0352-4841, NÖ: 0000-0002-7154-0894.

*Corresponding author e-mail: zeynep.gunayucmak@iuc.edu.tr

INTRODUCTION

Guinea pigs are hystricognath rodents whose lifespan are 6-8 years. Multiple cysts in the ovaries of guinea pigs are usually appeared after 1 year old of age (Donnelly 2021). Cystic changes in the ovaries cause infertility in guinea pigs (Keller et al. 1987). Cysts can be unilateral or bilateral and clinical diagnosis should be made by radiography and ultrasonography (Kohutova et al. 2018).

Types of cystic structures which are serous cysts (cystic rete ovarii), follicular cysts, and paraovarian cysts, can only differentiate by histopathological examination (Pilny 2014). Tumors of the reproductive tract constitute 25% of spontaneous tumors in guinea pigs. The incidence of spontaneous tumors increases in guinea pigs older than 3 years old (Greenacre 2004). The most common guinea pig uterine neoplasms were uterine leiomyomas (46%), followed by adenomas (23%) and leiomyosarcomas (0.7%) (Veiga-Parga et al. 2016). Leiomyosarcoma is a malignant neoplasm with uncertain pathogenesis that originate from smooth muscle cells (Rivas et al. 2014). Mammary tumours are not common, but can occur in both males and females and are most often found in older guinea pigs. Most lesions are benign fibroadenomas and approximately 30% are

adenocarcinomas (Amorim et al 2009). Regarding mammary neoplasms, tubuler carcinoma (Oliveira et al. 2023), simple solid carcinomas and simple tubulopapillary carcinomas (Suárez-Bonnet et al. 2010) have been reported. The aim of the present case report is to exhibit the clinical and surgical approach to multiple reproductive pathologies in a female guinea pig.

CASE HISTORY

A five year old, intact, female guinea pig, weighing 1 kg was admitted to the Obstetrics and Gynecology clinic with a huge mass on the right mammary lobe. In the anamnesis, it was learned that the mass had been small for a year but had grown rapidly in the last 3 weeks. In clinical examination, the mass was not adhered to the abdominal muscles. On B-mode ultrasonography, the mass was capsulated, and 8.1 cm in diameter. It had polycystic structure and mixed echogenicity (Fig. 1A). Mix vascularization (both peripheral and central) was observed on color Doppler imaging (Fig. 1B). The examination was carried out with pulsed-wave Doppler USG to characterize the waveform of the vessels on the mammary mass (Fig. 1C).

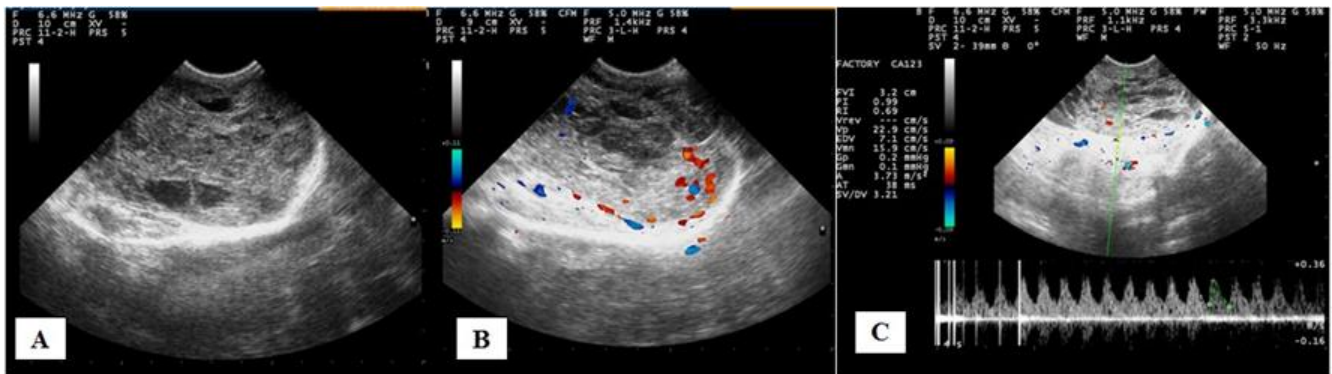


Figure 1. Ultrasonographic evaluation of a mass on the right mammary lobe. **A.** B-mode ultrasonography of the mass. **B.** Color Doppler ultrasonography and vascularization of the mass, **C.** Spectral Doppler ultrasonography and hemodynamics of the mass.

Pulsatility index and resistance index were 0.99 and 0.69, respectively. A radiographic examination of the thorax was requested to investigate possible lung metastasis but was not authorized by the owner. To detect the abdominal metastases, abdominal ultrasonography could not be performed successfully due to the size of the mass in the mammary lobe. Lobectomy was decided for treatment. For general anesthesia, ketamine (50 mg/kg, im) (Alfamine 10%, EgeVet, Turkey) and xylazine (5 mg/kg, im) (Alfazyne 2%, EgeVet, Turkey) were used (Fish et al. 2008). The anesthesia was maintained with isoflurane (1-2%) (Forane, Abbott Laboratories, USA) and oxygen (1-1.5%). In order to prevent the decrease in body temperature due to anesthesia, a warm bed was

prepared to put under the guinea pig during the surgical intervention. Because the large mass extended to the proximal part of the right leg (Fig. 2A), a Y-shaped incision was performed (Fig. 2B). Absorbable suture material (Monocryl No: 2/0, Medeks, Turkey) was used for all sutures. Enrofloxacin (Baytril 2.5% oral suspension, 10 mg/kg, BID for a week), meloxicam (0.3 mg/kg, sc) (Melox, Nobel, Turkey) and multivitamin (1 drop to each ounce of drinking water for 5 days) (Oasis Vita-Drops, USA) were prescribed for postoperative care. Wound healing was achieved in 10 days. Also, ovariectomy was recommended to avoid the occurrence of the metastasis. In the macroscopic examination, no deterioration was observed in the

skin of the extirpated mass (Fig. 2C). On the cross-sectional surface of the mass, many vacuolar areas

and tissue growths were detected (Fig. 2D).

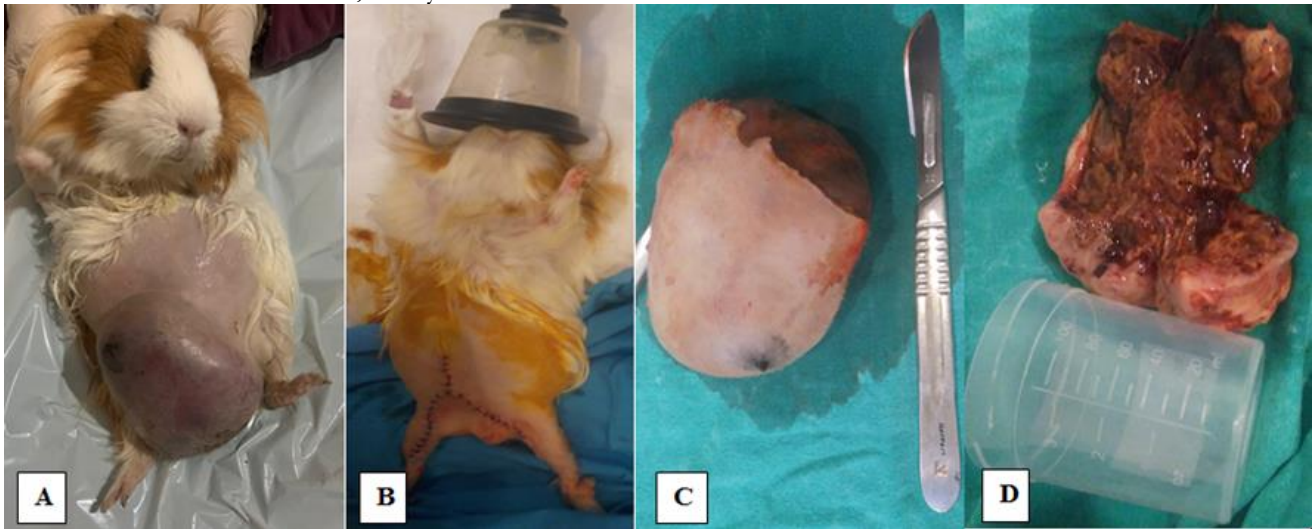


Figure 2. Guinea pig with mammary mass. **A.** Localization of a mass on the right mammary lobe. **B.** Appearance of caudoabdominal area after mastectomy **C.** Macroscopic view of the excised mammary mass. **D.** Cross-sectional surface of the mass.

Tissue samples were fixed in 10% neutral buffered formalin, routinely processed, and stained with hematoxylin and eosin (HE) to be examined by light microscopy. The mammary tumor in the right lobe was histologically diagnosed as a simple solid carcinoma (Grade-III). The arrangement of the neoplastic epithelial cells in nests with high cellularity and a high mitotic rate was remarkable (Fig. 4 C-D). The female guinea pig was presented to the clinic with a complaint of abdominal swelling on 2.5 months after the lobectomy. According to the abdominal ultrasonography, cysts in both ovaries and

a mass on corpus uteri were determined. On the right ovary, there were 2 cystic structures which were measured as 8.1 mm and 21 mm in diameter, respectively (Fig. 3A). On the left ovary, the cyst was 9 mm in diameter. Ovariohysterectomy (Fig. 3B) was performed as a treatment, with the same anesthesia protocol of the lobectomy section. Absorbable suture material (Monocryl No: 2/0, Medeks, Turkey) was used for all sutures. A mass on the corpus uteri was capsulated, solid and 9 cm in diameter.

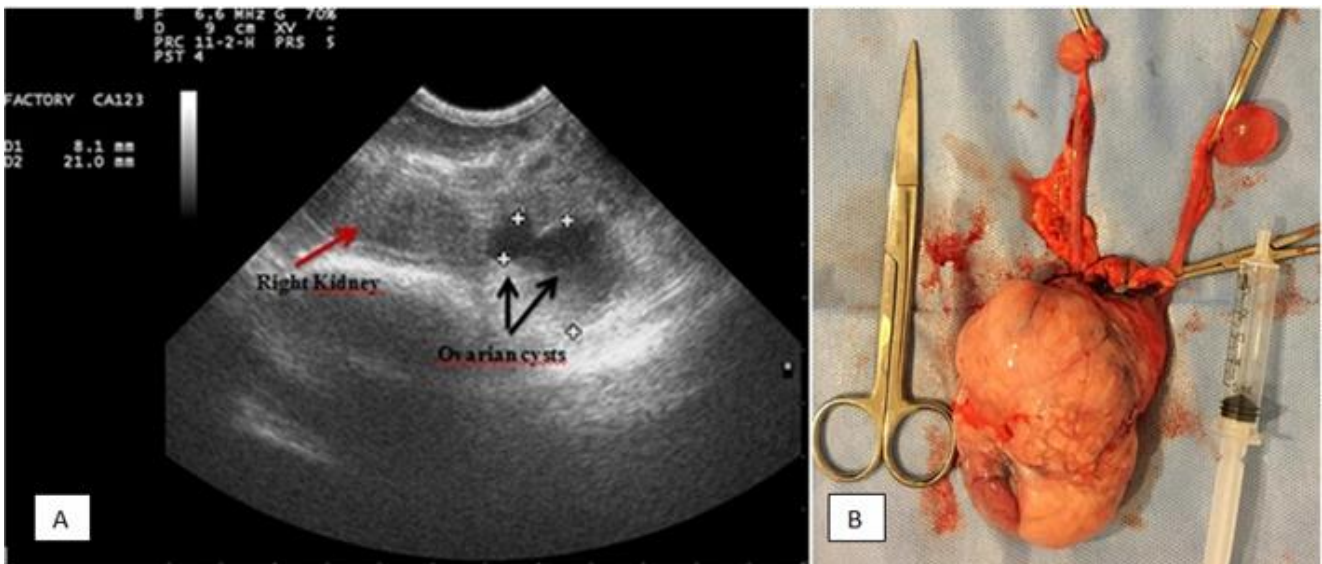


Figure 3. **A.** B-mode ultrasonography on right ovary **B.** Macroscopic view of the ovariohysterectomy material.

Histologic examination of the uterus revealed leiomyosarcoma characterized by interwoven fascicles of spindle cells with cigar-shaped nuclei that showed moderate pleomorphism (Fig. 4 A-B). Eight months

after the last surgical intervention, the guinea pig died at the age of 6 years. It was thought to be due to the old age.

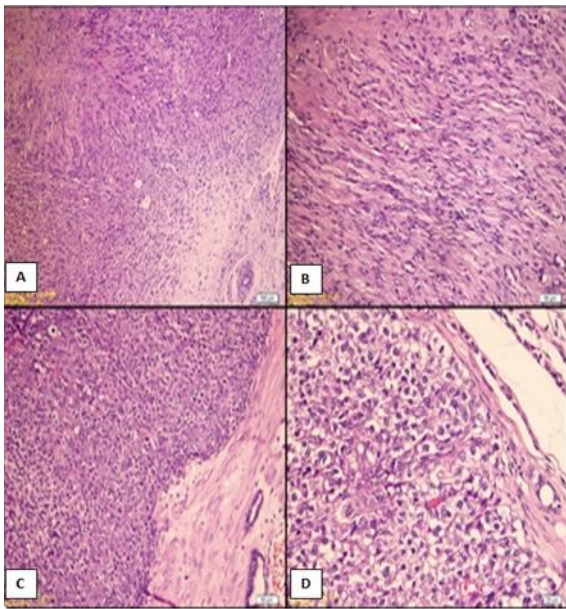


Figure 4. Histopathological examination. **A, B:** Uterus; guinea pig. Leiomyosarcoma. Interwoven fascicles of spindled cells with blunt-ended nuclei. HE. **C, D:** Mammary gland; guinea pig. Simple solid carcinoma(grade-III). HE.

DISCUSSION AND CONCLUSION

The lifespan of the guinea pigs are 6-8 years and spontaneous tumors usually occur in older than 3 years old while the ovarian cysts appear after 1 year old of age (Greenacre 2004; Donnelly 2021). In this case, gynecologic pathologies were diagnosed in an elderly guinea pig and its lifespan was 6 years, as previously reported. The prevalence of mammary tumors in male guinea pig is higher than in other species (Suarez-Bonnet et al. 2010). In contrast with the previous report, mammary tumor occurred in a female guinea pig in this case.

The vascularization of tumoral tissue can be assessed using noninvasive methods like power Doppler and color Doppler by performing the direct measurement of the distribution and flow of intratumoral blood vessels (Abma et al. 2019). The mixed pattern was frequently observed in malignant mammary tumors (Mantziaras and Luvani 2020). In accordance with the previous reports (Abma et al. 2019; Mantziaras and Luvani 2020), mixed vascularization was observed at the tumoral mass on the mammary gland by color Doppler ultrasonography in this case. There are few reports on mammary tumors in guinea pigs. Mammary tumors are generally locally invasive and rarely metastasize (Suarez-Bonnet et al. 2010). The researchers (Suarez-Bonnet et al. 2010) detected mammary carcinosarcoma in one case which was highly vascularized. Although simple solid carcinoma was detected in this case, the mammary tumor had high vascularization as Suarez-Bonnet et al. (2010) reported.

The researchers reported glandular cystic hyperplasia of the uterus and large polycystic ovaries complicated with adenoma in a 4 years old guinea pig with the sign of bilateral alopecia (Uyguner et al. 2021). In contrast with the researchers, glandular cystic hyperplasia of the uterus and bilateral alopecia were not observed in this case but large and polycystic ovaries were detected at bilaterally similar to the previously reported. The most common uterine neoplasms in guinea pigs are leiomyomas and followed by adenomas, leiomyosarcomas, anaplastic tumors of unknown origin and choriocarcinomas (Veiga-Parga et al. 2016). The researchers reported spontaneous reproductive tract leiomyomas usually in uterine body or horn of the aged guinea pigs. In contrast with the previous reports (Veiga-Parga 2016), leiomyosarcoma which was not the most common uterine pathology, was determined at corpus uteri in this case. A relationship exists between polycystic ovarian syndrome and gynaecological cancers in humans (Chittenden et al. 2009). The increased malignancy in the uterine pathology of the guinea pig in this case can be explained by the relationship between polycystic ovaries and gynecological pathologies as previously reported. Sua´rez-Bonnet et al. (2010) analyzed 10 spontaneous mammary gland tumors affecting guinea pigs histologically and immunohistochemically and they reported that all tumors were positive for type a estrogen and progesterone receptors, suggesting a role for steroid hormones in the development of these neoplasias in guinea pigs. Veiga-Parga et al. (2016) indicated that estrogen receptor and progesterone receptor expression was nearly 100% in uterine neoplasms of the guinea pigs. According to the previous reports, it is clear that there is a link between mammary cancer, ovarian cysts, and uterine neoplasia. Because of that reason, ovariohysterectomy was recommended to avoid the occurrence of the metastasis in this case.

It was concluded that guinea pigs with a history of mammary tumors should also be evaluated clinically in terms of internal genital tract pathologies. Surgical method is essential in the treatment of gynecological pathologies in guinea pigs and it is thought to be necessary to ensure the life welfare of these females.

Conflict of interest: The authors have no conflicts of interest to report.

Authors Contribution Rate: The authors declared that they contributed equally to the article.

Ethical Approval: This study is not subject to the permission of HADYEK in accordance with the “Regulation on Working Procedures and Principles of Animal Experiments Ethics Committees” 8 (k). The data, information and documents presented in this article were obtained within the framework of academic and ethical rules.

REFERENCES

- Abma, E., Stock, E., De Spiegelaere, W., Van Brantegem, L., Vanderperren, K., Ni, Y., Vynck, M., Daminet, S., De Clercq, S., & De Rooster, H. (2019).** Power Doppler ultrasound and contrast-enhanced ultrasound demonstrate non-invasive tumour vascular response to anti-vascular therapy in canine cancer patients. *Scientific Reports*, 9(1), 1-12. <https://doi.org/10.1038/s41598-019-45682-2>
- Amorim, I., Faria, F., Rema, A., & Gärtner, F. (2009).** Immunohistochemical Characterization of a Mammary Carcinoma in a Male Guinea Pig (*Cavia porcellus*). *Journal of Comparative Pathology*, 141(4), 279. <https://doi.org/10.1016/j.jcpa.2009.08.008>
- Chittenden, B. G., Fullerton, G., Maheshwari, A., & Bhattacharya, S. (2009).** Polycystic ovary syndrome and the risk of gynaecological cancer: a systematic review. *Reproductive Biomedicine Online*, 19(3), 398-405. [https://doi.org/10.1016/S1472-6483\(10\)60175-7](https://doi.org/10.1016/S1472-6483(10)60175-7)
- Donnelly, T.M. (2021).** Guinea pigs. Available at <https://www.merckvetmanual.com/all-other-pets/guinea-pigs/disorders-and-diseases-of-guinea-pigs#v3227529> (Accessed Jan 06, 2021).
- Greenacre, C. B. (2004).** Spontaneous tumors of small mammals. *Veterinary Clinics: Exotic Animal Practice*, 7(3), 627-651. <https://doi.org/10.1016/j.cvex.2004.04.009>
- Fish, R.E., Brown, M.J., Danneman, P.J. & Karas, A.Z. (2008)** *Anesthesia and Analgesia in Laboratory Animals* (2nd ed) Elsevier, San Diego, CA, U.S.A.
- Keller, L. S. F., Griffith, J. W., & Lang, C. M. (1987).** Reproductive failure associated with cystic rete ovarii in guinea pigs. *Veterinary pathology*, 24(4), 335-339. <https://doi.org/10.1177/030098588702400408>
- Kohutova, S., Paninarova, M., Škorič, M., Jekl, V., Knotek, Z., & Hauptman, K. (2018).** Cystic endometrial hyperplasia and bacterial endometritis associated with an intrauterine foreign body in a guinea pig with ovarian cystic disease. *Journal of Exotic Pet Medicine*, 27(1), 41-45. <https://doi.org/10.1053/j.jepm.2017.10.001>
- Mantziaras, G., & Luvoni, G. C. (2020).** Advanced ultrasound techniques in small animal reproduction imaging. *Reproduction in Domestic Animals*, 55, 17-25. <https://doi.org/10.1111/rda.13587>
- Oliveira, R.E.M., Oliveira, R.K.M., Dalmagro, M.J., Silva, D.N., Gurgel, J.V.O., Sousa, A.C.F.C., Attademo, F.L.N., Soares, M.K.F., Arcoverde, K.N., Olinda, R.G., Santos, P.R.S., Torres, D.C.B., Rego, R.O., Diniz, J.A.R., Moura, C.E.B., Batista, J.S., Oliveira, M.F. (2023).** Mammary tubular carcinoma in a guinea pig (*Cavia porcellus*): case report. *Brazilian Journal of Case Reports*, 3(4), 18-23. <https://doi.org/10.52600/2763-583X.bjcr.2023.3.4.18-23>
- Pilny, A. (2014).** Ovarian cystic disease in guinea pigs. *Veterinary Clinics: Exotic Animal Practice*, 17(1), 69-75. <https://doi.org/10.1016/j.cvex.2013.09.003>
- Rivas, G., Bonilla, C., Rubiano, J., & Arango, N. (2014).** Primary leiomyosarcoma of the ovary: A case report. *Case Reports in Clinical Medicine*, 3, 192-196. <https://doi.org/10.4236/crcm.2014.34045>
- Suárez-Bonnet, A., Martín de Las Mulas, J., Millan, M. Y., Herráez, P., Rodríguez, F., & Espinosa de los Monteros, A. (2010).** Morphological and immunohistochemical characterization of spontaneous mammary gland tumors in the guinea pig (*Cavia porcellus*). *Veterinary pathology*, 47(2), 298-305. <https://doi.org/10.1177/0300985809358426>
- Uyguner, K., Enginler, S. Ö., Yıldar, E., Öztürk, G. Y., & Gülçubuk, A. (2021).** Serous multicystic papillary adenoma of the ovaries and glandular cystic hyperplasia of uterus in a Guinea Pig (*Cavia porcellus*). *Journal of Istanbul Veterinary Sciences*, 5(3), 144-148. <https://doi.org/10.30704/http-www-jivs-net.999648>
- Veiga-Parga, T., La Perle, K. M., & Newman, S. J. (2016).** Spontaneous reproductive pathology in female guinea pigs. *Journal of Veterinary Diagnostic Investigation*, 28(6), 656-661. <https://doi.org/10.1177/1040638716665429>