



The Intraoperative Use of Hypochlorous Acid in Infected Hip Arthroplasty Revision Surgery

Revizyon Yapılan Enfekte Kalça Artroplastilerinde İntraoperatif Hipokloröz Asit Kullanımı


Muharrem KANAR

 0000-0003-1035-9183


Necmi CAM

 0000-0001-7101-3106

Enver İPEK

 0000-0001-6205-1207

Hacı Mustafa ÖZDEMİR

 0000-0001-6189-3605

Department of Orthopedics and
Traumatology, University of Health
Sciences Şişli Hamidiye Etfal Training
and Research Hospital, İstanbul,
Türkiye

Corresponding Author

Sorumlu Yazar

Muharrem KANAR

dr.kanar@hotmail.com

Received / Geliş Tarihi : 17.06.2023

Accepted / Kabul Tarihi : 03.08.2023

Available Online /

Çevrimiçi Yayın Tarihi : 16.08.2023

ABSTRACT

Aim: Arthroplasty infections are serious and difficult to treat complications. Hypochlorous acid (HOCl) is an oxidant produced endogenously in the body as a physiological part of the inflammatory process, with the aim of eliminating pathogens activated by neutrophils. The aim of this study was to evaluate the positive and negative effects on clinical results of HOCl used as an irrigation solution during surgical treatment.

Material and Methods: The study included 37 patients who underwent single- or two-stage revision surgery at the University of Health Sciences Şişli Hamidiye Etfal Training and Research Hospital Orthopedics and Traumatology Clinic between January 2017 and December 2021. Treatment was applied according to our standard protocol of irrigation with 450 cc HOCl following implant removal and an additional 50 cc HOCl to the subcutaneous tissue after closing the fascia. The patients were evaluated during follow-up in respect of infections.

Results: While single-stage revision surgery applied to 20 patients, two-stage revision surgery applied to 17 patients. 17 (45.9%) of the patients were male and 20 (54.1%) were female with a mean age of 72.8±11.1 years. The mean follow-up period was 25.8±14.1 months. Revision surgery was performed on one patient in each of the single and two-stage surgery groups. A success rate of 94.6% (n=37) was obtained when all patients were evaluated.

Conclusion: The HOCl solution can be considered to make a positive contribution to the eradication of infections in revision hip arthroplasty and can be an effective and safe alternative to other irrigation solutions.

Keywords: Arthroplasty; infection; hip; hypochlorous acid.

ÖZ

Amaç: Artroplastisi enfeksiyonları ciddi ve tedavisi güç olan komplikasyonlardır. Hipokloröz asit (hypochlorous acid, HOCl), patojenleri ortadan kaldırmak amacıyla, nötrofiller tarafından aktive edilen inflamatuvar sürecin fizyolojik kısmının bir parçası olarak vücutta endojen olarak üretilen bir oksidandır. Bu çalışmanın amacı, cerrahi tedavi sırasında irrigasyon solüsyonu olarak kullanılan HOCl'nin klinik sonuçlar üzerindeki olumlu ve olumsuz etkilerini değerlendirmektir.

Gereç ve Yöntemler: Çalışmaya Ocak 2017 ve Aralık 2021 tarihleri arasında Sağlık Bilimleri Üniversitesi Şişli Hamidiye Etfal Eğitim ve Araştırma Hastanesi Ortopedi ve Travmatoloji kliniğinde tek veya iki aşamalı kalça revizyon cerrahisi geçiren 37 hasta dahil edildi. Tedavi tüm implantlar çıkarıldıktan sonra standart protokolümüze göre 450 cc HOCl ile irrigasyon ve fasya kapatıldıktan sonra subkutan dokuya ek 50 cc HOCl uygulandı. Hastalar takip sırasında enfeksiyonlar açısından değerlendirildi.

Bulgular: 20 hastaya tek aşamalı revizyon cerrahisi uygulanırken, 17 hastaya ise iki aşamalı revizyon cerrahisi uygulandı. Hastaların 17'si (%45,9) erkek ve 20'si (%54,1) kadın olup ortalama yaşları 72,8±11,1 yıl idi. Ortalama takip süresi 25,8±14,1 ay idi. Tek ve iki aşamalı cerrahi uygulanan gruplardan ikisinde de birer hastaya revizyon cerrahisi uygulandı. Hastaların tamamı değerlendirildiğinde %94,6'lık (n=37) bir başarı oranı elde edildi.

Sonuç: HOCl solüsyonunun revizyon kalça artroplastilerinde enfeksiyonların eradikasyonu açısından olumlu katkılarının olduğu ve diğer irrigasyon solüsyonlarına alternatif olarak etkin ve güvenli bir yıkama solüsyonu olabileceğini öngörmektedir.

Anahtar kelimeler: Artroplastisi; enfeksiyon; kalça; hipokloröz asit.

INTRODUCTION

Over recent years there has been an increase in the number of total hip arthroplasty (THA) operations as a result of longer implant life and increased social expectations of patients. Although there has been a decrease in periprosthetic hip infections (PHI) together with developments in the field of healthcare, infections occurring after THA are one of the most serious complications encountered (1). Over time there has been a great increase in both length of stay in hospital and costs associated with PHI (2).

The treatment to be selected after the occurrence of PHI can be separated into two forms, single-stage or two-stage revision surgical procedures. Although there is no clear consensus on which surgical treatment is to be selected, single- or two-stage revisions are preferred depending on the clinical status of the patient, the severity of the infection, and the organism causing the infection (3).

There are positive contributions to the use of wound antiseptics in surgical wound irrigation, but these solutions can also have a cytotoxic effect. The ideal antiseptic to be used in irrigations should have a bactericidal effect at low concentrations and the cytotoxic effect should be minimal (4,5).

Hypochlorous acid (HOCl) is an oxidant produced endogenously in the body as a physiological part of the inflammatory process, with the aim of eliminating pathogens activated by neutrophils. HOCl has been shown to have a rapid bactericidal effect against most pathogens responsible for surgical site infections. In addition to the fragmentation effect on biofilms, HOCl has a low cytotoxic effect and a neutral pH value. As a result of these properties, there has started to be an increase in studies related to the use of HOCl solution on the skin, as an oral antiseptic, and during the surgical treatment of open wounds and infections (6-15).

Whichever method of surgical treatment is selected, surgical success with respect to infection eradication is affected by numerous factors, including the facilities and characteristics of the center where the surgery occurs, the selection and application of the irrigation solution, and human factors.

The aim of this study was to evaluate the positive and negative effects of HOCl use as an irrigation solution during the surgical treatment of patients who developed chronic PHI following hip arthroplasty.

MATERIAL AND METHODS

A retrospective examination was made of 41 patients who underwent single-stage or two-stage revision surgery because of PHI between January 2017 and December 2021, with the use of HOCl as the irrigation solution during the surgical treatment. All the patients were given information about the medical and surgical treatments to be applied in the management of PHI, and about the HOCl irrigation solution that was planned to be used and informed consent was obtained from all patients. This study was performed in line with the principles of the Declaration of Helsinki. Ethics committee approval was granted by the Ethics Committee of Health Sciences University Şişli Hamidiye Etfal Training and Research Hospital (dated 18.04.2023, and numbered: 3881). The study exclusion criteria were defined as treatment with

only anti-biotherapy or debridement irrigation and implant retention. Because four patients left the follow-up, the study was completed with 37 patients. A record was made for each patient of age, sex, body mass index (BMI), American Society of Anesthesiologists (ASA) score, operated side, and prophylactic antibiotics used.

The diagnosis of infection was made considering the criteria established by the Musculoskeletal Infection Society (MSIS) together with clinical, radiological, and laboratory findings such as fistulated discharge, elevated sedimentation and C-reactive protein (CRP), redness and increased temperature, and implant loosening observed on scintigraphy and radiographs (16).

All the patients were treated in a single center, and standard perioperative care was applied according to the rules of joint arthroplasty. Following sufficient debridement and the taking of a sample for culture, intravenous antibiotic prophylaxis in accordance with the national surgery guidelines was administered as 1-2 gr cefazolin or a single dose of 15-20 mg/kg vancomycin. Unless specific allergic reactions were reported, iodine-soaked drapes were used on all the patients. When there were no different indications related to comorbid diseases, low molecular weight heparin (once a day) was administered postoperatively.

Revision surgery was performed as single-stage to 20 patients and as two-stage to 17 patients. In both the single- and two-stage revision protocols, only isotonic and HOCl were used as irrigation solutions during debridement. During the single-stage revision, after the removal of the implant and surgical debridement, HOCl was used after mechanical debridement of the surgical site with physiological saline. In the first stage of the two-stage revision, the implant was removed, then following surgical and mechanical debridement with physiological saline, HOCl was used before the application of the spacer. In the second stage when clinical and hematological markers had returned to normal, the spacer was removed, then following surgical and mechanical debridement, and irrigation with HOCl, the revision implant was applied.

HOCl is produced from an inverse reaction of sodium hypochlorite and hydrogen peroxide (HP). The concentration used in this study was 200 ppm, pH 7.1, oxidation reduction potential (ORP) of 871 millivolt (mV), and stability for 24 months. For all patients, irrigation with 450 cc HOCl was applied to the surgical area for 5 minutes (Figure 1). After aspiration of the HOCl and closure of the fascia, irrigation was applied again with a 50 cc HOCl solution. The basic pathophysiological parameters of blood pressure, heart rate, and respiratory rate were recorded intraoperatively, before, during, and after the HOCl irrigation.

Standard postoperative follow-up in our institution includes follow-up examinations at 3 weeks, 6 weeks, 3 months, 6 months, and 1 year. The patients were followed up for at least 1 year. The sutures were removed after 21 days after checking wound healing. Anti-biotherapies were adjusted according to the recommendations of the Infectious Diseases Department according to the culture results. At the follow-up examinations, the presence of discharge, redness, or fistula was clinically evaluated.

Radiologically, it was examined whether or not there was loosening observed on the radiographs, and from blood samples, the infection parameters of sedimentation rate, white blood cell (WBC), and CRP were evaluated.

RESULTS

The evaluation was made of 37 patients operated on because of PHI, with single-stage revision surgery applied to 20 patients and two-stage revision surgery to 17. The patients comprised 17 (45.9%) males and 20 (54.1%) females with a mean age of 72.8±11.1 (range, 41-90) years. The operated hip was right side in 21 (56.8%) patients and left side in 16 (43.2%). The body weight of the patients was mean 76.0±7.8 (range, 60-100) kg, with mean BMI calculated as 27.9±3.6 kg/m². From the BMI measurements, 2 (5.4%) patients were classified as morbidly obese, 7 (18.9%) as obese, 21 (56.8%) as overweight, and 7 (18.9%) as normal weight. Additional diseases of the patients were determined as diabetes mellitus, hypertension, chronic renal failure, pulmonary diseases, history of cancer, cardiac pathologies, and cerebrovascular event (Table 1). The ASA scores were determined as ASA 1 in 4 (10.8%), ASA 2 in 12 (32.4%), ASA 3 in 17 (45.9%), and ASA 4 in 4 (10.8%) patients. A partial hip prosthesis was present in 19 (51.4%) patients, a total hip prosthesis in 13 (35.1%), and a revision hip prosthesis in 5 (13.5%). In 1 patient for whom two-stage revision was planned, despite sufficient anti-biotherapy after the first stage, because of elevated infection values and discharge, debridement and spacer placement were repeated before the second stage.

As infection was not eradicated, revision surgery was performed in 1 patient who had undergone single-stage surgery and in 1 patient who had undergone two-stage surgery. A success rate of 94.6% (n=37) was obtained when all patients were evaluated together. When evaluated separately, the success rates were 95.2% (n=20) in the single-stage group and 94.4% (n=17) in the two-stage group.

Polymicrobial organisms were seen to be produced in the cultures of 5 patients. The organisms produced were shown in Table 2. Despite the infection parameters in 8 patients, no microbial agent was produced in the culture.

No data related to any allergic or unusual reaction having developed associated with the use of HCOI were obtained from any patient perioperatively or in the postoperative period. No complication or delay in wound healing was observed in any patient.

The mean follow-up period was 25.8±14.1 (range, 12-64) months. With the exception of the 2 patients who were operated on again, the clinical and laboratory parameters throughout the follow-up period showed a regression of infection and there was observed to be a decreased need for analgesia. No findings of loosening of the components were observed radiologically.

DISCUSSION

Together with the increased number of arthroplasty operations, there has been a relative increase in the development of PHI. Increased antibiotic resistance, which has become a significant problem in recent years, has made the use of irrigation solutions during surgical treatment of PHI more important (2-4,6).

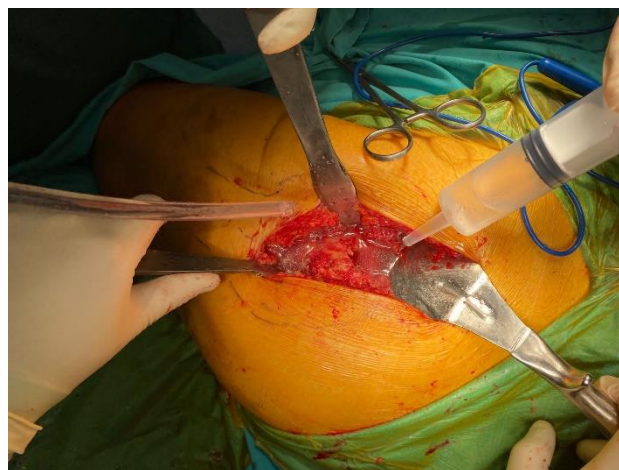

Figure 1. Hypochlorous acid application

Table 1. Additional diseases of the patients

Disease	n (%)
Diabetes mellitus	12 (32.4)
Hypertension	26 (70.3)
Chronic renal failure	6 (16.2)
Respiratory diseases	7 (18.9)
History of cancer	3 (8.1)
Heart diseases	11 (29.7)
Cerebrovascular event	3 (8.1)

Table 2. The organisms in the cultures of the patients

Pathogens
<i>Escherichia coli</i>
<i>Pseudomonas aeruginosa</i>
<i>Staphylococcus epidermidis</i>
<i>Corynebacterium amycolatum</i>
<i>Proteus mirabilis</i>
<i>Candida albicans</i>
<i>Klebsiella pneumoniae</i>
<i>Enterobacter aerogenes</i>
<i>Streptococcus pyogenes</i>
<i>Staphylococcus aureus</i>
Methicillin-resistant <i>Staphylococcus aureus</i> (MRSA)
<i>Enterococcus faecium</i>
Vancomycin-resistant <i>Enterococcus faecalis</i> (VRE)

HCOI is a small molecule produced by WBCs in the body in the oxidation process to kill pathogens. As it is small and neutral, it cannot be removed by bacteria membranes and thus has the effect of eliminating membrane components (15). In previous studies, HCOI has been shown to be extremely effective against antibiotic-resistant bacteria, those forming a biofilm, fungi, and viruses. All the micro-organisms produced in the cultures of the current study patients were seen to be micro-organisms against which HCOI has been shown to be effective in previous studies that have evaluated the bactericidal efficacy of HCOI (7,8,14).

The ideal irrigation solution should show destructive and bactericidal efficacy on biofilms even at low concentrations, and there should be a very low or no cytotoxic effect (4-6). Biofilm formation is accepted as a serious problem in chronic wound infections (17). HOCl has the characteristics of an ideal wound care solution in respect of showing a rapid micro-bactericidal effect against different micro-organism species within the biofilm. There is no negative effect on wound healing, and it has even been shown to make a positive contribution to wound healing as there are dose-related positive effects on fibroblast and keratinocyte migration (7,8). No wound healing problems and no delay in wound healing were observed in any of the current study patients.

Antiseptics that can be used as irrigation solutions during arthroplasty procedure include povidone-iodine (PI), chlorhexidine (CHG), acetic acid (AA), HP, sodium hypochlorite, and HOCI (6,18). In most clinical studies in the literature, PI and CHG have been used during arthroplasty (6). Hart et al. (19) used PI as the irrigation solution in a study of revision hip arthroplasty and reported revision because of infection in the first year at the rate of 5.2% after a 1-year follow-up period. In a study by Riesgo et al. (20), a success rate of 83.3% was reported with the use of PI together with vancomycin as the irrigation solution during implant change in infected hip and knee arthroplasties. Byren et al. (21) used CHG in implant change after PHI and reported a success rate of 86.5% (45/52).

Due to the low number of studies in literature, no consensus has yet been reached on the stage of determining the ideal irrigation solution. All the above-mentioned antiseptics have shown cytotoxic effects at different concentrations in studies in the literature (6,18). The cytotoxic effect of free iodine on chondrocytes, osteoblasts, and other normal host cells has been shown even at low concentrations (6,22,23). Compared with 1%

PI, CHG, and 10% PI, HCOI at doses effective on the biofilm has been shown to have a less cytotoxic effect (9). As HCOI is not irritant to the skin, does not show a cytotoxic effect, has a neutral pH, and converts to salty water similar to tears by breaking down within minutes, it is not necessary to wash it from the wound and skin, unlike other wound cleaning solutions (24,25).

In the current study of patients operated on because of PHI, it was seen to be necessary to repeat the revision due to the infection in 2 patients, and thus a success rate of 94.6% (n=37) was obtained in total. In a review and meta-analysis by Kunutsor et al. (26), the total re-infection development rate was reported to be 8% in patients applied with single- or two-stage revision surgery because of PHI. The total re-infection rate in the current study was determined to be 5.4% (n=2). The results published in the literature of patients applied with single- and two-stage surgery because of PHI are shown in (Tables 3 and 4). When evaluated together with the literature, it can be seen that the results of the current study are at least as successful as those in the literature.

When the literature was scanned related to the duration of HCOI within the wound, it can be seen that no clear consensus has been reached. After use, after having encountered pathogens and the biological load, HCOI returns to non-reactive NaCl and H₂O within minutes (23). Although it has been reported that the destructive and bactericidal effect is shown within seconds against many bacteria and the biofilms formed, there are also data in the literature that an effect against fungi is formed within 5 minutes (6,7,10). Therefore, in the current study, irrigation was applied for 5 minutes.

There are reports in the literature that the use of HCOI in orthopedic implant-related infections can cause corrosion and wear on CoCr and Ti metals. In a review study by Siddiqi et al. (6), it was recommended that care should be taken in the use of HCOI in patients with an implant and in

Table 3. The results of single-stage arthroplasty in literature

Authors	Year	Number of patients	Type of arthroplasty	Infection control rate (%)	Follow-up (year)
Winkler et al. (27)	2008	37	one-stage	92	4.4
Rudelli et al. (28)	2008	32	one-stage	93.8	8.5
Yoo et al. (29)	2009	12	one-stage	83.4	7
Klouche et al. (30)	2012	38	one-stage	100	2
Choi et al. (31)	2013	17	one-stage	82	5.2
Hansen et al. (32)	2013	27	one-stage	70	4.2
Zeller et al. (33)	2014	157	one-stage	95	5

Table 4. The results of two-stage arthroplasty in literature

Authors	Year	Number of patients	Type of arthroplasty	Infection control rate (%)	Follow-up (year)
Masri et al. (34)	2007	29	two-stage	89.7	2
Biring et al. (35)	2009	99	two-stage	89	12
Oussedik et al. (36)	2010	39	two-stage	94.9	6.8
Engesæter et al. (37)	2011	283	two-stage	95	3
Choi et al. (31)	2013	44	two-stage	86.4	5.8
Ibrahim et al. (38)	2014	125	two-stage	96	5
Chen et al. (39)	2014	157	two-stage	91.7	9.7

those where the implant is not removed. Therefore, when an implant is present, the use of HCOI would be appropriate with a good benefit-harm calculation. As the HCOI was applied in the current study after the removal of the implant, the effect on implants was not evaluated (6,11). There were some limitations to this study. These can be said to be the retrospective design, the lack of a control group, the relatively low number of patients, and the short follow-up period.

CONCLUSION

In the patients in this study with irrigation performed with HCOI, which is bactericidal and shows an effect on biofilms, no complications or allergic reactions were determined associated with the use of this solution. When compared with the results of other studies of revision surgery performed because of PHI, the current study results were seen to be at least as successful as the results of other studies. HOCl solution can be considered to make a positive contribution to the eradication of infections in revision hip arthroplasty and can be an effective and safe alternative to other irrigation solutions. Nevertheless, it would be appropriate to conduct further prospective studies with control groups and a longer follow-up period related to the use of HCOI.

Ethics Committee Approval: The study was approved by the Ethics Committee of Şişli Hamidiye Etfal Training and Research Hospital (18.04.2023, 3881).

Conflict of Interest: None declared by the authors.

Financial Disclosure: None declared by the authors.

Acknowledgments: None declared by the authors.

Author Contributions: Idea/Concept: MK, NC, Eİ; Design: MK, NC, Eİ; Data Collection/Processing: MK, NC, Eİ; Analysis/Interpretation: MK, NC, Eİ; Literature Review: MK, NC, Eİ; Drafting/Writing: MK, NC, Eİ, HMÖ; Critical Review: MK, NC, Eİ, HMÖ.

REFERENCES

1. Tande AJ, Patel R. Prosthetic joint infection. *Clin Microbiol Rev.* 2014;27(2):302-45.
2. Odum SM, Fehring TK, Lombardi AV, Zmistowski BM, Brown NM, Luna JT, et al. Irrigation and debridement for periprosthetic infections: does the organism matter? *J Arthroplasty.* 2011;26(6):114-8.
3. Sukeik M, Haddad FS. Periprosthetic joint infections after total hip replacement: an algorithmic approach. *SICOT J.* 2019;5:5.
4. Ruder JA, Springer BD. Treatment of periprosthetic joint infection using antimicrobials: dilute povidone-iodine lavage. *J Bone Jt Infect.* 2017;2(1):10-4.
5. van Meurs SJ, Gawlitta D, Heemstra KA, Poolman RW, Vogely HC, Kruyt MC. Selection of an optimal antiseptic solution for intraoperative irrigation: an in vitro study. *J Bone Joint Surg Am.* 2014;96(4):285-91.
6. Siddiqi A, Abdo ZE, Rossman SR, Kelly MA, Piuze NS, Higuera CA, et al. What is the optimal irrigation solution in the management of periprosthetic hip and knee joint infections? *J Arthroplasty.* 2021;36(10):3570-83.
7. Sakarya S, Gunay N, Karakulak M, Ozturk B, Ertugrul B. Hypochlorous Acid: an ideal wound care agent with powerful microbicidal, antibiofilm, and wound healing potency. *Wounds.* 2014;26(12):342-50.
8. Kramer A, Dissemmond J, Kim S, Willy C, Mayer D, Papke R, et al. Consensus on Wound Antisepsis: Update 2018. *Skin Pharmacol Physiol.* 2018;31(1):28-58.
9. Day A, Alkhalil A, Carney BC, Hoffman HN, Moffatt LT, Shupp JW. Disruption of biofilms and neutralization of bacteria using hypochlorous acid solution: an in vivo and in vitro evaluation. *Adv Skin Wound Care.* 2017;30(12):543-51.
10. Wang L, Bassiri M, Najafi R, Najafi K, Yang J, Khosrovi B, et al. Hypochlorous acid as a potential wound care agent: part I. Stabilized hypochlorous acid: a component of the inorganic armamentarium of innate immunity. *J Burns Wounds.* 2007;6:e5.
11. Clayman E, Beauchamp Z, Troy J. Salvage of infected orthopedic hardware with intraoperative and postoperative hypochlorous acid instillations. *Eplasty.* 2023;23:e1.
12. Wongkietkachorn A, Surakunprapha P, Wittayapairoch J, Wongkietkachorn N, Wongkietkachorn S. The use of hypochlorous acid lavage to treat infected cavity wounds. *Plast Reconstr Surg Glob Open.* 2020;8(1):e2604.
13. Bongiovanni CM. Effects of hypochlorous acid solutions on venous leg ulcers (VLU): experience with 1249 VLUs in 897 patients. *J Am Coll Clin Wound Spec.* 2016;6(3):32-7.
14. Severing AL, Rembe JD, Koester V, Stuermer EK. Safety and efficacy profiles of different commercial sodium hypochlorite/hypochlorous acid solutions (NaClO/HClO): antimicrobial efficacy, cytotoxic impact and physicochemical parameters in vitro. *J Antimicrob Chemother.* 2019;74(2):365-72.
15. Armstrong DG, Bohn G, Glat P, Kavros SJ, Kirsner R, Snyder R, et al. Expert recommendations for the use of hypochlorous solution: science and clinical application. *Ostomy Wound Manage.* 2015;61(5):S2-19.
16. Parvizi J, Zmistowski B, Berbari EF, Bauer TW, Springer BD, Della Valle CJ, et al. New definition for periprosthetic joint infection: from the Workgroup of the Musculoskeletal Infection Society. *Clin Orthop Relat Res.* 2011;469(11):2992-4.
17. Donlan RM, Costerton JW. Biofilms: survival mechanisms of clinically relevant microorganisms. *Clin Microbiol Rev.* 2002;15(2):167-93.
18. Caid M, Valk J, Danoff J. Irrigation solutions in total joint arthroplasty. *Spartan Med Res J.* 2022;7(2):37502.
19. Hart A, Hernandez NM, Abdel MP, Mabry TM, Hanssen AD, Perry KI. Povidone-iodine wound lavage to prevent infection after revision total hip and knee arthroplasty: an analysis of 2,884 cases. *J Bone Joint Surg Am.* 2019;101(13):1151-9.
20. Riesgo AM, Park BK, Herrero CP, Yu S, Schwarzkopf R, Iorio R. Vancomycin povidone-iodine protocol improves survivorship of periprosthetic joint infection treated with irrigation and debridement. *J Arthroplasty.* 2018;33(3):847-50.

21. Byren I, Bejon P, Atkins BL, Angus B, Masters S, McLardy-Smith P, et al. One hundred and twelve infected arthroplasties treated with 'DAIR' (debridement, antibiotics and implant retention): antibiotic duration and outcome. *J Antimicrob Chemother.* 2009;63(6):1264-71.
22. Kataoka M, Tsumura H, Kaku N, Torisu T. Toxic effects of povidone-iodine on synovial cell and articular cartilage. *Clin Rheumatol.* 2006;25(5):632-8.
23. von Keudell A, Canseco JA, Gomoll AH. Deleterious effects of diluted povidone-iodine on articular cartilage. *J Arthroplasty.* 2013;28(6):918-21.
24. Sipahi H, Reis R, Dinc O, Kavaz T, Dimoglo A, Aydın A. In vitro biocompatibility study approaches to evaluate the safety profile of electrolyzed water for skin and eye. *Hum Exp Toxicol.* 2019;38(11):1314-26.
25. Adam LC, Fabian I, Suzuki K, Gordon G. Hypochlorous acid decomposition in the pH 5-8 region. *Inorg Chem.* 1992;31(17): 3534-41.
26. Kunutsor SK, Whitehouse MR, Blom AW, Beswick AD; INFORM Team. Re-infection outcomes following one- and two-stage surgical revision of infected hip prosthesis: a systematic review and meta-analysis. *PLoS One.* 2015;10(9):e0139166.
27. Winkler H, Stoiber A, Kaudela K, Winter F, Menschik F. One stage uncemented revision of infected total hip replacement using cancellous allograft bone impregnated with antibiotics. *J Bone Joint Surg Br.* 2008;90(12):1580-4.
28. Rudelli S, Uip D, Honda E, Lima AL. One-stage revision of infected total hip arthroplasty with bone graft. *J Arthroplasty.* 2008;23(8):1165-77.
29. Yoo JJ, Kwon YS, Koo KH, Yoon KS, Kim YM, Kim HJ. One-stage cementless revision arthroplasty for infected hip replacements. *Int Orthop.* 2009;33(5):1195-201.
30. Klouche S, Leonard P, Zeller V, Lhotellier L, Graff W, Leclerc P, et al. Infected total hip arthroplasty revision: one - or two-stage procedure? *Orthop Traumatol Surg Res.* 2012;98(2):144-50.
31. Choi HR, Kwon YM, Freiberg AA, Malchau H. Comparison of one-stage revision with antibiotic cement versus two-stage revision results for infected total hip arthroplasty. *J Arthroplasty.* 2013;28(8):66-70.
32. Hansen E, Tetreault M, Zmistowski B, Della Valle CJ, Parvizi J, Haddad FS, et al. Outcome of one-stage cementless exchange for acute postoperative periprosthetic hip infection. *Clin Orthop Relat Res.* 2013;471(10):3214-22.
33. Zeller V, Lhotellier L, Marmor S, Leclerc P, Krain A, Graff W, et al. One-stage exchange arthroplasty for chronic periprosthetic hip infection: results of a large prospective cohort study. *J Bone Joint Surg Am.* 2014;96(1):e1.
34. Masri BA, Panagiotopoulos KP, Greidanus NV, Garbuz DS, Duncan CP. Cementless two-stage exchange arthroplasty for infection after total hip arthroplasty. *J Arthroplasty.* 2007;22(1):72-8.
35. Biring GS, Kostamo T, Garbuz DS, Masri BA, Duncan CP. Two-stage revision arthroplasty of the hip for infection using an interim articulated Prostalac hip spacer: a 10- to 15-year follow-up study. *J Bone Joint Surg Br.* 2009;91(11):1431-7.
36. Oussedik SI, Dodd MB, Haddad FS. Outcomes of revision total hip replacement for infection after grading according to a standard protocol. *J Bone Joint Surg Br.* 2010;92(9):1222-6.
37. Engesaeter LB, Dale H, Schrama JC, Hallan G, Lie SA. Surgical procedures in the treatment of 784 infected THAs reported to the Norwegian Arthroplasty Register. *Acta Orthop.* 2011;82(5):530-7.
38. Ibrahim MS, Raja S, Khan MA, Haddad FS. A multidisciplinary team approach to two-stage revision for the infected hip replacement : A minimum five-year follow-up study. *Bone Joint J.* 2014;96-B(10):1312-8.
39. Chen SY, Hu CC, Chen CC, Chang YH, Hsieh PH. Two-stage revision arthroplasty for periprosthetic hip infection: mean follow-up of ten years. *Biomed Res Int.* 2015;2015:345475.