



The Effectiveness of Complex Treatment of Ulcerative Colitis in Integrative Medicine

Tamamlayıcı Tıpta Kompleks Ülseratif Kolit Tedavisinin Etkinliği

Arzu GULIYEVA^{1*}, Gulnar GULIYEVA¹

¹Biological Medicine Clinic, Baku, Azerbaijan.

*drarzuqyeva@hotmail.com, ORCID: 0009-0006-3648-9006

q.gulnar1971@gmail.com, ORCID: 0009-0000-6124-3194

Received/Geliş Tarihi: 02/05/2023

Accepted/ Kabul Tarihi: 20/06/2023

*Corresponding author /Yazışılan yazar

Doi: 10.35206/jan.1319777

e-ISSN: 2667-4734

Abstract

The aim of the study was to develop a new complex treatment of ulcerative colitis using integrative medicine methods. The study was conducted on 16 patients with ulcerative colitis with total (8 patients) and left-sided lesions (8 patients). The progress of the disease was traced on the basis of complaints, levels of fecal calprotectin and lactoferrin, ESR and endoscopic picture of the colon mucosa. Depending on the severity and individual characteristics of the progress of the disease, the treatment lasted 2-8 months. The treatment was carried out against the background of taking mesalazine in two stages. At the first stage (1-3 weeks), treatment was carried out to eliminate the causes of the leaky gut syndrome (use of antiparasitic, antibacterial, antiprotozoal drugs) and restore the microbiota (use of eubiotics and short-chain fatty acids). The aim of the second stage of treatment (4-6 weeks) was immunomodulation and regeneration of the intestinal mucosa (the use of bioregulatory, isopathic, orthomolecular drugs and interleukin preparations). Patients received drugs orally, in the form of intravenous infusions and local injections into the metameric zones and acupuncture points of the large intestine. Also, in parallel, neural therapy was carried out with procaine at the points of the large intestine. The results obtained showed a significant decrease in calprotectin, lactoferrin and an improvement in the endoscopic picture of the large intestine. Colonoscopy showed complete recovery in group I in 2, and in group II in 3 patients, in other cases was noted 70% recovery of the mucous membrane. Thus, the use of a complex of integrative medicine methods with the use of safe bioregulatory drugs makes it possible to obtain high efficiency in the treatment of ulcerative colitis.

Keywords: Integrative medicine, Ulcerative colitis, Complex treatment

Özet

Bu çalışmanın amacı bütünlüyci tıp metotlarını kullanarak ülseratif kolit için yeni bir kompleks tedavi geliştirilmesidir. Çalışma tüm kolonu tutan ülseratif kolitli 8 hasta, sol kolunu tutan 8 hasta olmak üzere toplam 16 hasta üzerinde yapıldı. Hastalığıdaki ilerleme şikayetler, fekal kalprotektin ve laktoferrin düzeyleri, ESR ve kolon mukozasının endoskopik incelenmesi temelinde izlendi. Hastalığın ilerlemesinin ciddiyetine ve bireysel özelliklere göre tedavi 2-8 ay sürmüştür. Tedavi iki aşamalı mesalazin alımına karşı gerçekleştirildi. İlk aşamada (1-3 hafta) geçirgen bağırsak sendromunun nedenlerini ortadan kaldırmak (antiparaziter, antibakteriyel, antiprotozoal ilaç kullanımı) ve mikrobiyotayı yeniden yapılandırmak için (öbiyotiklerin ve kısa zincirli yağ asitlerinin kullanımı) uygulandı. Tedavinin ikinci aşamasının amacı ise (4-6 hafta) immünomodülasyon ve bağırsak mukozasının yenilenmesiydi (biyoregülatör, izopatik, ortomoleküler ilaç ve interlökin preparatlarının kullanımı ile). Hastalar kalın bağırsağın metamerik bölgelerine ve akupunktur noktalarına intravenöz infüzyonlar ve lokal enjeksiyonlar şeklinde oral yoldan ilaç aldılar. Ayrıca kalın bağırsağa prokain ile nöral terapi yapıldı. Kalprotektin, laktoferrin düzeylerinde anlamlı bir azalma ve endoskopik tabloda bir iyileşme sağlandı. Kolonoskopide grup 1'deki 2 hastada ve grup 2'deki 3 hastada tam iyileşme görüldü diğer vakalarda ise mukozada %70 iyileşme belirlendi. Güvenli biyoregülasyon ilaçlarının kullanımı ve tamamlayıcı tıp metotlarının kompleks kullanımı ile ülseratif kolit tedavisinde yüksek verimlilik elde edilmesini mümkün kılmıştır.

Anahtar Kelimeler: Tamamlayıcı tıp, Ülseratif kolit, Kompleks tedavi

Abbreviations: ESR, Eritrosit sedimentasyon hızı

1. INTRODUCTION

Ulcerative colitis is an idiopathic, chronic disease characterized by immune-mediated inflammation that occurs in the colon and rectum. It has long been recognized that ulcerative colitis begins in the rectum and usually spreads to part or all of the colon (Feuerstein et al., 2019; Ordás et al., 2012; Torres et al., 2012; Ungaro et al., 2017; Yan Sun et al., 2021). The cause of the aberrant immune response in this disease remains largely unknown, but dietary and environmental risk factors, as well as patient factors such as genetic predisposition and gut microbiota, play a role (Segal et al., 2021; Silverberg et al., 2005). It is important to note that the incidence and prevalence of ulcerative colitis is constantly increasing. The annual incidence is higher in industrialized countries and has been steadily increasing over the past decades worldwide (Asakura et al., 2009; Jones et al., 2019; Pasvol et al., 2020).

5-ASA preparations are the main medications for treatment for mild and moderate ulcerative colitis. In patients with an inadequate response to 5-ASA, is used immunosuppressive therapy. Despite therapeutic advances, treatment gaps still exist, only about 40% of patients with a short-term response to therapy maintaing clinical remission within a year (Hirten et al., 2018; Mao & Hu, 2016; Peyrin-Biroulet & Lemann, 2011; Robert et al., 2021).

In recent decades, there has been an increase in resistance to drugs used in the treatment of ulcerative colitis. Placebo-controlled studies using immunosuppressive drugs (tofacitinib, etrolizumab, infliximab, ustekinumab, etc.) showed a dose-dependent increase in the incidence of infections, especially viral and cases of thromboembolism (Sandborn et al., 2017; Sands et al., 2019; Vermeire et al., 2014; Vermeire et al., 2017). The above facts encourage the development of new approaches and methods for the treatment of ulcerative colitis.

Based on the foregoing, the aim of this study was to develop a new integrated approach to the treatment of ulcerative colitis using various integrative medicine therapies.

2. MATERIALS and METHODS

The work was performed in the clinic "Biological Medicine". The study was conducted on 16 patients with ulcerative colitis aged 15-45 years, divided into two groups: group 1 - 8 patients with total and group 2 - 8 patients with left-sided lesions of the large intestine. Patients with ulcerative colitis were diagnosed and grouped according to the Montreal classification (Lamb et al., 2019). General characteristics of patients are presented in Table 1.

Table 1. General characteristics of the examined patients with ulcerative colitis

Groups	Age years	Gender	
		Women	Men
Group 1 - patients with a total lesion of the large intestine	15-43	6	2
Group 2 - patients with left-sided lesions of the large intestine	24-45	3	5

The diagnosis of ulcerative colitis was based on clinical, laboratory, imaging, and endoscopic parameters. The course of the disease was traced on the basis of patient complaints, levels of fecal calprotectin and lactoferrin, ESR, CRP, and endoscopic picture of the colon mucosa. Calprotectin was determined by the immunofluorescent method on an express analyzer (CHROMA-2 Boditech Medince, South Korea), lactoferrin was determined by the enzyme immunoassay DRG (BIO SCREEN MS-500 BIOSAN, Latvia-England), and CRP was determined by the immunoturbulent method (ARCHITECT c 8000, Abbott USA). Endoscopic data were assessed by the presence of erythema in the colon, loss of normal vascular pattern, granularity, erosion, pseudo-erosion, friability, bleeding and ulceration using the PENTAX-Imagina EPK-i5500c apparatus, Japan.

Depending on the severity and individual characteristics of the flow patterns of the disease, the treatment lasted 2-8 months. The tactics and duration of treatment was determined by the degree of inflammation in the large intestine and was carried out in two stages while taking mesalazine. At the first stage, treatment was carried out to eliminate the causes of leaky gut syndrome (use of antiparasitic, antibacterial, antiprotozoal drugs) and restore the microbiota (use of eubiotics and short-chain fatty acids). The goal of the second stage of treatment was immunomodulation and regeneration of the intestinal mucosa (the use of bioregulatory, isopathic, orthomolecular drugs and interleukin preparations). Patients received drugs orally, in the form of intravenous infusions and local injections into the metameric zones and acupuncture points of the large intestine. Also, in parallel, neural therapy with procaine was carried out at the points of the large intestine.

The drugs used in the treatment were as follows:

At stage I

To eliminate increased intestinal permeability: Albendazole, Rifaximin, Bacteriophages, Metronidazole).

At stage II

For immunomodulation:

1. Isopathic therapy: Sanukehl Coli, Sanukehl Cand, Sanukehl Strep, Sanukehl Staph., Notakehl, Fortakehl (Sanum Kehlbeck, Germany)

2. Bioregulatory therapy: Mucosa comp., Traumel S, Belladonna HA, Pulsatilla HA (HEEL Germany)

2. Cytokine therapy: Anti-IL-1, IL-7, TGF beta (GUNA, Italy)

3. Orthomolecular therapy: Pascorbin 7.5g-50.0ml

4. Neural therapy: Novocain 1% 2.0-6.0 ml

5. Food supplements containing vitamins D, C, group B, zinc, curcumin, omega-3, butifara

For regeneration:

1. Chrysosan (Sanum Kehlbeck GmbH & Co. Germany)

2. Mucosa comp., Colon suis injeel, Graphites HA, Thuja injeel, Mercurius sublimatus corrosivus injeel (HEEL, Germany)

For restore the intestinal microbiota: Bifido- and Lactobacilli, Butyrate.

Drugs were administered orally, intravenously and locally.

Per os:

Mesalazine (1000 mg - 4000 mg / day, and 3 patients did not use mesalazine). If necessary, standard therapy also used glucocorticoids (prednisolone, metipred, solu-medrol, etc.) and monoclonal antibodies to TNF- α (azathioprine, infliximab).

For elimination causes of dysbiosis:

Sanukehl Coli, Sanukehl Strep, Sanukehl Staph., Notakehl (or together with Fortakehl). These drugs were used at a dose of 10 drops 3 times a day 30 minutes before meals.

For anti-inflammatory effect: Guna Anti İL 1 (the first 1-1.5 months during the period of exacerbation of the disease until the improvement of clinical symptoms, positive dynamics of inflammation indicators)

Guna IL7 (first 1-3 months and longer to increase intestinal IgA synthesis)

Guna TGF β (following 1-3 months and longer to improve regeneration).

The preparations were used 20 drops 2 times a day 30 minutes before meals.

Parenterally:

- **For bioregulation and immunomodulation** - Mucosa comp., Traumeel S, Belladonna HA, Pulsatilla HA (one ampoule of each IV every other day in one syringe).
- **Orthomolecular therapy** - Pascorbin 7.5 g - 50 ml IV drip every day, every other day, etc. depending on the severity of the course of the disease.

Locally:

- In the metameric zones of the intestine (Bioregulatory Segmental-Metameric Therapy) and acupuncture points (E 23,25,36; Rp12.13 (left),14,15; I6,7,9,10,12; Gi 4, 10 and eleven). Mucosa comp., Colon suis injeel., Graphites HA, Thuja injeel, Mercurius sublimatus corrosivus injeel, Chrysosan were administered 2 times a week, 5-15 procedures in total, depending on the severity of the disease.
- Neural therapy - Novocain 2% - 2.0 + 2.0 water for injection was injected into the acupuncture points Th9-L5 once a week (4-5 procedures in total).

3. RESULTS and DISCUSSION

The results obtained are presented in Table 2 and Figure 1. As can be seen from Table 2, after the complex treatment, there was a significant decrease in calprotectin, lactoferrin, ESR and CRP.

Table 2. Laboratory parameters in patients with ulcerative colitis after treatment (M ± m, n=16)

Indicators	Study timeline	
	Before treatment	After treatment
1st group (n=8)		
Calprotectin µg/g N <1 year <500 1-4 year <150 4-65 year <50 >65 year <100	246,8 ± 58,2	43,3 ± 19,9**
Min-Max	100-383	10,7-42
Lactoferrin µg/g N <7.25	179,3 ± 23,5	44,7 ± 17,7***
Min-Max	114,8-249,7	7,2-18,4
CRP µg/l N 0.0-5.0	18,12 ± 1,72	6,25 ± 0,36**
Min-Max	12,7-76	3-12,1
ESR mm/hour N >50 year 2-30 <50 year 2-20	20,75 ± 2.8	14,62 ± 3,2*
Min-Max	16-30	8-15
2nd group (n=8)		
Calprotektin µg/g N <1 year <500 1-4 year <150 4-65 year <50 >65 year <100	313,6 ± 70,1	18,12 ± 2,4***
Min-Max	100-383	10,7-30
Lactoferrin µg/g N <7.25	162,8 ± 28,32	37,4**
Min-Max	114,8-301	7,2-22
CRP µg/l N 0.0-5.0	22,88 ± 3,5	2,75 ± 0,36***
Min-Max	12,7-56,7	3-12,1
ESR mm/hour N >50 year 2-30 <50 year 2-20	37,88 ± 14,46	6,25 ± 0,59**
Min-Max	16-30	8-15

Statistical significance compared to pre-treatment scores: *-p <0,05; **-p < 0,01; ***-p < 0,001.

In the first group of patients who had a total lesion of the large intestine after the course of treatment, the level of calprotectin decreased by an average of 82% ($p < 0.001$), lactoferrin by an average of 75% ($p < 0.001$), the content of CRP decreased by an average of 65% ($p < 0.001$), and ESR - by 29% ($p < 0.01$). In the second group of patients who had a left-sided lesion of the large intestine in a comparative aspect with the first group, the decrease in the level of the studied parameters was more significant (table 2.). Thus, the level of calprotectin decreased by an average of 94% ($p < 0.001$), lactoferrin - by an average of 77% ($p < 0.001$), CRP - by an average of 88% ($p < 0.001$) and ESR - by an average of 83% ($p < 0.001$). It should be noted that the duration of treatment in the first group compared with the second group was longer.

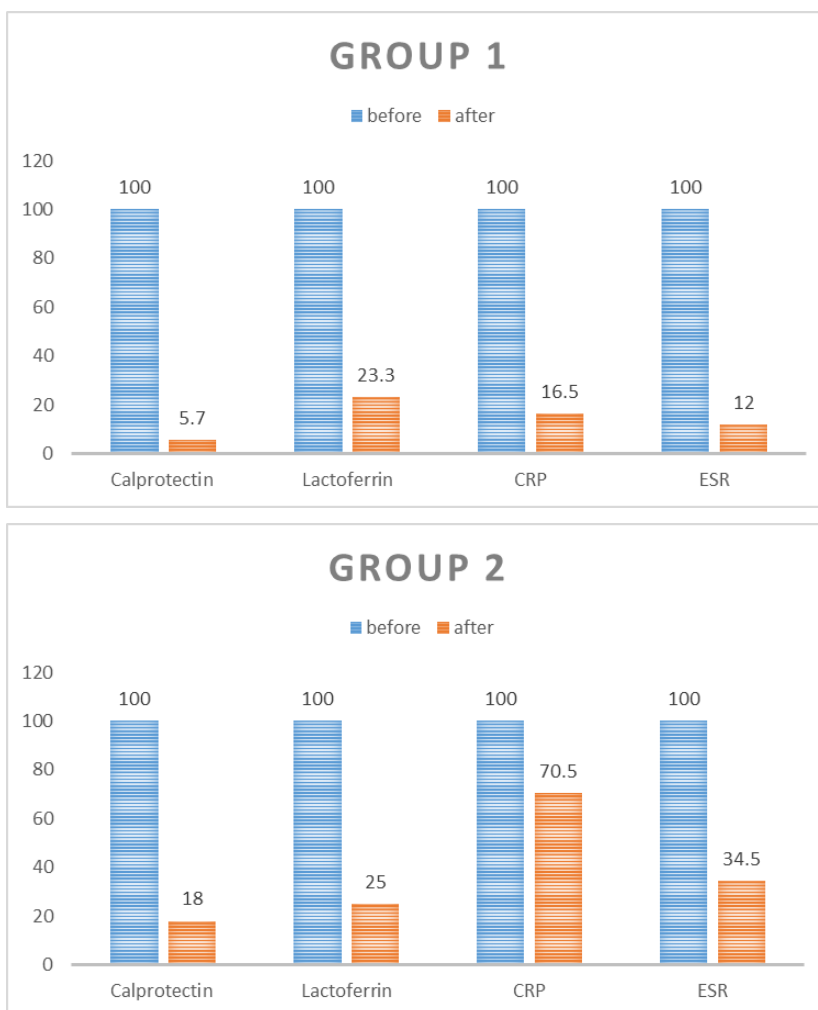


Figure 1. Dynamics of changes in laboratory parameters in patients with ulcerative colitis after treatment

The results of the colonoscopy performed before treatment were as follows. In patients with ulcerative colitis with a total lesion, the mucosa in all parts of the intestine during colonoscopy was sharply hyperemic, edematous, superficial ulcers were observed, prone to bleeding on contact, the veins in these places were obliterated in 7 patients (Figure 2). In 4 of

them, the mucosa bulged, having the appearance of a cobblestone pavement, in 2 patients were observed pseudopolyps. Repeat colonoscopy performed after improvement of clinical and laboratory parameters showed complete recovery in 2 patients with a total lesion; in two- restoration of the intestinal mucosa by 70% and single aphthous ulcers in separate areas.

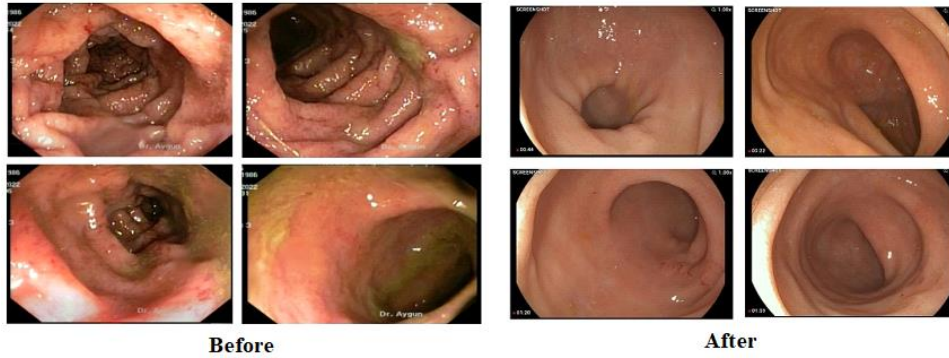


Figure 2. Colonoscopy picture in a patient of the 1st group before and after the treatment

In patients of the second group with ulcerative colitis with left-sided lesions, in 3 patients, starting from the distal transverse colon and in 4 patients, starting from the descending colon, the mucous membrane was sharply hyperemic and edematous, superficial ulcers were observed with a tendency to bleed on contact, veins in these areas were erased (Figure 3). In 2 patients, only the sigmoid colon was affected, and in one patient, only the rectum was affected.

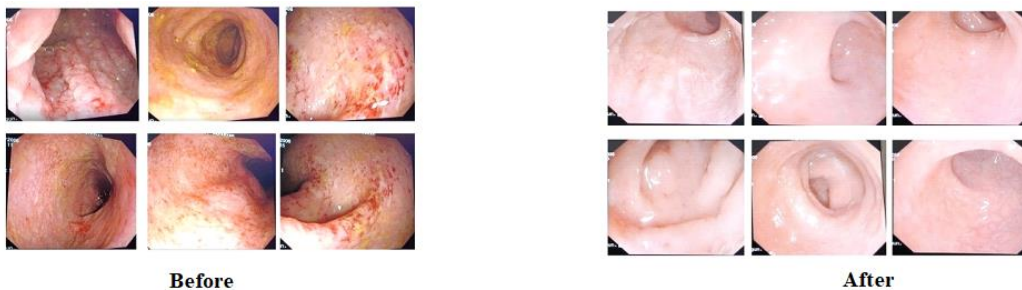


Figure 3. Colonoscopic picture in a patient of the 2nd group before and after the treatment

Repeated colonoscopy in this group also showed a pronounced improvement in the endoscopic picture of the large intestine after the treatment. In three patients with left-sided lesion, the colonoscopic picture was normal, in 2 patients healing was noted on most of the mucous membrane, in some places there were single superficial ulcers. Thus, in a comparative aspect, colonoscopy showed complete recovery in the first group in 2, and in the second group in 3 patients, in other cases, 70% recovery of the mucous membrane was noted in both groups of patients examined.

4. CONCLUSION

The complex use of bioregulatory, immunomodulatory, and regenerating drugs, along with standard therapy for patients with ulcerative colitis of varying degrees of colon damage, is highly effective and has a high level of safety. Causing adequate stimulation of nonspecific mechanisms of resistance and immunomodulation, the used drugs make it possible to influence on numerous pathogenetic links of this disease and provide repair of ulcerative defects of various depths in ulcerative colitis. An integrated approach to the treatment of the disease makes it possible to significantly optimize treatment and create new programs for the complex treatment of patients with ulcerative colitis.

DECLARATIONS

Some part of this article was presented as a oral presentation in 1st International Apitherapy and Nature Congress (1-3 June 2023, Nakhchivan).

All authors declare that they have no conflicts of interest.

REFERENCES

- Asakura, K., Nishiwaki, Y., Inoue, N., Hibi, T., Watanabe, M., & Takebayashi, T. (2009). Prevalence of ulcerative colitis and Crohn's disease in Japan. *Journal of Gastroenterology*, 44, 659-665.
- Feuerstein J. D., Moss A. C., & Farraye F. A. (2019). Ulcerative Colitis. *Mayo Clinic Proceedings*, 94,1357-1373.
- Hirten, R. P., & Sands, B. E. (2021). New therapeutics for ulcerative colitis. *Annual Review of Medicine*, 72, 199-213.
- Hirten, R. P., Iacucci, M., Shah, S., Ghosh, S., & Colombel, J. F. (2018). Combining biologics in inflammatory bowel disease and other immune mediated inflammatory disorders. *Clinical Gastroenterology and Hepatology*, 16, 1374-1384.
- Jones, G. R., Lyons, M., Plevris, N., Jenkinson, P. W., Bisset, C., Burgess, C., ... & Lees, C. W. (2019). IBD prevalence in Lothian, Scotland, derived by capture–recapture methodology. *Gut*, 68, 1953-1960.
- Lamb C. A., Kennedy N. A., Raine, T., Hendy, P. A., Smith, P. J., Limdi, J. K., ...& Hawthorne, A. B. (2019). British Society of Gastroenterology consensus guidelines on the management of inflammatory bowel disease in adults. *Gut*, 68, 101-106.

- Mao, R., & Hu, P. J. (2016). The future of IBD therapy: where are we and where should we go next?. *Digestive Diseases*, 34, 175-179.
- Ordás I., Eckmann L., Talamini M., Baumgart D., & Sandborn W. (2012). Ulcerative colitis. *Lancet*, 380,1606-1619.
- Pasvol, T. J., Horsfall, L., Bloom, S., Segal, A. W., Sabin, C., Field, N., & Rait, G. (2020). Incidence and prevalence of inflammatory bowel disease in UK primary care: a population-based cohort study. *BMJ Open*, 10, e036584.
- Peyrin-Biroulet, L., & Lémann, M. (2011). remission rates achievable by current therapies for inflammatory bowel disease. *Alimentary Pharmacology & Therapeutics*, 33, 870-879.
- Sandborn, W. J., Panés, J., Sands, B. E., Reinisch, W., Su, C., Lawendy, N., ... & Danese, S. (2019). Venous thromboembolic events in the tofacitinib ulcerative colitis clinical development programme. *Alimentary Pharmacology & Therapeutics*, 50, 1068-1076.
- Sandborn, W. J., Su, C., Sands, B. E., D'Haens, G. R., Vermeire, S., Schreiber, S., ... & Panés, J. (2017). Tofacitinib as induction and maintenance therapy for ulcerative colitis. *New England Journal of Medicine*, 376, 1723-1736.
- Sands, B. E., Sandborn, W. J., Panaccione, R., O'Brien, C. D., Zhang, H., Johans, J., ... & Marano, C. (2019). Ustekinumab as induction and maintenance therapy for ulcerative colitis. *New England Journal of Medicine*, 381, 1201-1214.
- Sands, B. E., Taub, P. R., Armuzzi, A., Friedman, G. S., Moscariello, M., Lawendy, N., ... & Feagan, B. G. (2020). Tofacitinib treatment is associated with modest and reversible increases in serum lipids in patients with ulcerative colitis. *Clinical Gastroenterology and Hepatology*, 18, 123-132.
- Segal, J. P., LeBlanc, J. F., & Hart, A. L. (2021). Ulcerative colitis: an update. *Clinical Medicine*, 21, 135.
- Silverberg, M. S., Satsangi, J., Ahmad, T., Arnott, I. D., Bernstein, C. N., Brant, S. R., ... & Warren, B. F. (2005). Toward an integrated clinical, molecular and serological classification of inflammatory bowel disease: report of a Working Party of the 2005 Montreal World Congress of Gastroenterology. *Canadian Journal of Gastroenterology*, 19, 5A-36A.
- Sun, Y., Zhang, Z., Zheng, C. Q., & Sang, L. X. (2021). Mucosal lesions of the upper gastrointestinal tract in patients with ulcerative colitis: A review. *World Journal of Gastroenterology*, 27, 2963-2978.

Ungaro, R., Mehandru, S., Allen, P., Peyrin-Biroulet, L., & Colombel, J-F. (2017). Ulcerative colitis. *Lancet*, 389, 1756-1770.

Vermeire, S., O'Byrne, S., Keir, M., Williams, M., Lu, T. T., Mansfield, J. C., ... & Rutgeerts, P. (2014). Etrolizumab as induction therapy for ulcerative colitis: a randomised, controlled, phase 2 trial. *The Lancet*, 384, 309-318.

Vermeire, S., Sandborn, W. J., Danese, S., Hébuterne, X., Salzberg, B. A., Klopocka, M., ... & Reinisch, W. (2017). Anti-MAdCAM antibody (PF-00547659) for ulcerative colitis (TURANDOT): a phase 2, randomised, double-blind, placebo-controlled trial. *The Lancet*, 390, 135-144.