

Clinical and Radiographic Outcomes of Pediatric Femoral Neck Fractures

Pediyatrik Femur Boyun Kırıklarının Klinik ve Radyolojik Sonuçları

Ahmet Issin¹, İsmet Yalkın Çamurcu¹, Mehmet Nuri Konya², Vedat Şahin³

1.Erzincan Üniversitesi Tıp Fakültesi, Ortopedi ve Travmatoloji Anabilim Dalı, Erzincan, Türkiye

2.Afyon Kocatepe Üniversitesi, Tıp Fakültesi, Ortopedi ve Travmatoloji AD, Afyonkarahisar, Türkiye

3.SBÜ Metin Sabancı Baltalimanı Kemik Hastalıkları Eğitim ve Araştırma Hastanesi, Ortopedi ve Travmatoloji Kliniği, İstanbul, Türkiye

ABSTRACT

Aim: The aim of this study was to evaluate the clinical and radiological results of pediatric femoral neck fractures and compare the results with the literature.

Methods: We retrospectively reviewed patients with the diagnosis of femoral neck fracture who were treated between 2005 and 2012. 14 patients (6 girls, 8 boys) were found in compliance with the follow-up and with a minimum follow-up of 1 year. Causes of the fracture and types of the treatment were investigated from our medical records. Delbet-Colonna classification was used to determine the type of the fractures. At the last follow-up, femoral neck shaft angle (FNSA) and range of motion (ROM) of the affected hip were measured. Outcome was scored according to Rattliff's assessment criteria. Avascular necrosis (AVN) was classified according to Rattliff's AVN classification system.

Results: The mean age of patients was 9.9 years and the mean follow-up was 35 months. According to Delbet-Colonna classification; 1 patient was type I (7.1%), 4 were type II (28.6%), 8 were type III (57.2%) and 1 was type IV (7.1%). Eight of 14 fractures were displaced (57.2%) and six were non-displaced (42.8%). Eleven of 14 patients had good (78.6%), 1 had fair (7.1%) and 2 had poor (14.3%) results according to Rattliff's assessment criteria. According to Rattliff's AVN classification, 2 patients had Type-III (14.2%) and 1 had Type-I AVN (7.1%).

Conclusion: According to our results, we recommend anatomical reduction (close or open) and stable internal fixation for the treatment of pediatric femoral neck fractures.

Keywords: femoral neck fracture, pediatrics, injuries, avascular necrosis

ÖZET

Amaç: Bu çalışmanın amacı, pediyatrik femur boyun kırıklarının klinik ve radyolojik sonuçlarını değerlendirmek ve sonuçları literatürle karşılaştırmaktır.

Yöntemler: 2005-2012 tarihleri arasında femur boyun kırıkları tanısıyla tedavi edilen hastaları retrospektif olarak taradık. Takiplerini aksatmayan ve minimum 1 yıllık takip süresi olan 14 hasta (6 kız çocuk, 8 erkek çocuk) kayıtlardan bulundu. Kırığın nedeni ve uygulanan tedavi tipi kayıtlardan araştırıldı. Kırık tipini belirlemede Delbet-Colonna sınıflaması kullanıldı. Son kontrolde, femur boyun-şaft açısı ve etkilenen kalçanın hareket açıklığı ölçüldü. Nihai sonuç Rattliff'in değerlendirme kriterlerine göre skorlandı. Avasküler nekrozlar (AVN) Rattliff'in AVN sınıflama sistemine göre sınıflandırıldı.

Bulgular: Hastaların ortalama yaşı 9.9 olup ortalama takip 35 aydı. Delbet-Colonna sınıflamasına göre; hastalardan 1'i tip 1 (%7.1), 4'ü tip 2 (%28.6), 8'i tip 3 (%57.2) ve 1'i tip 4'dü (%7.1). 14 kırığın 8'i kaymış kırık (%57.2) ve 6'sı kaymamış kırık (%42.8). Rattliff değerlendirme kriterlerine göre, 14 hastanın 11'inin iyi (%78.6), 1'inin orta (%7.1) ve 2'sinin (%14.3) kötü sonucu vardı. Rattliff AVN sınıflamasına göre, 2 hastada tip 3 (%14.3) ve 1 hastada tip 1 (%7.1) AVN vardı.

Sonuç: Sonuçlarımıza göre, pediyatrik femur boyun kırıklarının tedavisinde anatomik redüksiyon (kapalı veya açık) ve stabil internal tespiti öneriyoruz.

Anahtar kelimeler: femoral boyun kırıkları, pediatri, yaralanmalar, avasküler nekroz

Geliş Tarihi: 04.07.2017/ Kabul Tarihi: 04.07.2017/ Yayınlanma Tarihi: 15.07.2017

*Corresponding Author: İsmet Yalkın Çamurcu, Yrd.Doç.Dr. Erzincan Üniversitesi Tıp Fakültesi, Ortopedi ve Travmatoloji AD. Tel: 05334802310 Fax: 04462261819 mail: yalkin.camurcu@gmail.com

Femoral neck fractures are rare in children; they consist only less than 1% of all pediatric fractures, which require high-energy trauma to occur, and therefore usually associated with additional injuries. Pediatric femoral neck fractures also have high complication rate as much as adult counterparts such as avascular necrosis and pseudoarthrosis [1-5].

The aim of this study was to evaluate the clinical and radiological results of pediatric femoral neck fractures and compare the results with the literature.

PATIENTS AND METHOD

We retrospectively reviewed patients between 0 and 16 years old with the diagnosis of femoral neck fracture who were treated between 2005 and 2012. We found 14 patients (6 girls, 8 boys) from our data that were in compliance with the follow-up and with a minimum follow-up of 1 year. Causes of the fracture and types of the treatment were investigated from our medical records. We evaluated initial, post-treatment and the final antero-posterior (AP) and lateral pelvis radiographs of all patients from our radiologic database. Delbet-Colonna classification was used to determine the type of the fractures [6] (Figure 1).

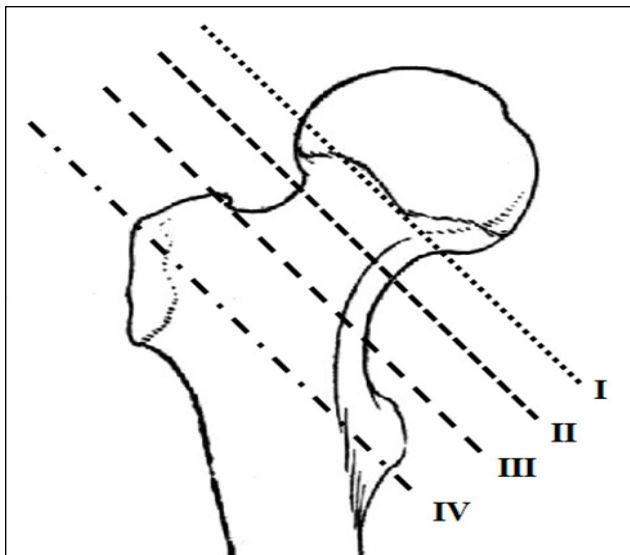


Figure 1. Delbet-Colonna classification for pediatric femoral neck fractures; (I) Type I: Transphyseal, (II) Type II: Transcervical, (III) Type III: Basocervical and (IV) Type IV: Intertrochanteric fracture lines were shown.

The quality of reduction was determined as anatomic (no angulations and step-off), acceptable (minimal angulations and step-off) and poor (unacceptable angulations and step-off) according to postoperative pelvis AP and lateral radiographs. At the last follow-up, fe-

moral neck shaft angle (FNSEA) and range of motion (ROM) of the affected hip were measured. Outcome was scored according to Ratliff's criteria (Table 1). Radiographs were also evaluated for joint congruency, arthritic changes and avascular necrosis (AVN). Avascular necrosis was classified according to Ratliff's AVN classification system [1].

Table 1 Ratliff's criteria for final results*

	Good	Fair	Poor
Pain	None or ignoring	Occasional	Disabling
Movement	Full or terminal restriction	Greater than 50 percent	Less than 50 percent
Activity	Normal or patient avoids games	Normal or patient avoids games	Restricted
Radiographs	Normal or some deformity femoral neck	Severe deformity of femoral neck and mild avascular necrosis	Severe avascular necrosis, degenerative arthritis, arthrodesis

* Ratliff AH. Fractures of the neck of the femur in children. J Bone Joint Surg Br. 1962 Aug;44-B:528-42

RESULTS

The mean age of patients was 9.9 years (ranges, 4 to 16 years) which was 9.4 ± 1 years (ranges, 6 to 12 years old) for girls and 10.3 ± 2 years (ranges, 4 to 16 years) for boys. Mean time from the injury to the last follow-up was 35 months (ranges, 15 to 97 months). When the etiologies of 14 fractures reviewed; 8 patients had a fall from height, 3 patients had a fall while playing on ground level, 1 patient had a passenger injury inside a motor vehicle, and 2 patients described previous minor trauma and gradual worsening before admission to our hospital. In these 2 patients, it was not clearly identified whether the main reason was stress fracture or gradually displaced fracture. According to Delbet-Colonna classification; 1 patient was type I (7.1%), 4 patients were type II (28.6%), 8 patients were type III (57.2%) and 1 patient was type IV (7.1%). Eight of 14 fractures were displaced (57.2%) and six fractures were non-displaced (42.8%) (Table 2).

A total of 12 cases were managed by surgical treatment and 2 cases were managed by closed reduction and spica cast. Closed reduction and internal fixation (CRIF) was performed in 8 patients, open reduction and internal fixation (ORIF) was performed in 2 patients. Internal fixation was performed by 3 cannulated screws in 6 patients, by 2 cannulated screws in 2 patients, by

Table 2. Demographic data, etiologies, fracture classifications and fracture displacements of the patients

Patient	Age (years)	Sex	Follow-up (months)	Mechanism of Trauma	Fracture Classification (Delbet-Colona)	Fracture Displacement
1	14	female	15	Fall while playing	3	Non-displaced
2	5	male	15	Minor previous trauma	1	Displaced
3	13	male	16	Fall from height	2	Displaced
4	15	male	17	Fall while playing	3	Displaced
5	16	male	20	Fall while playing	3	Non-displaced
6	7	male	21	Motor vehicle accident	3	Displaced
7	7	female	26	Fall from height	3	Displaced
8	11	female	27	Fall from height	3	Displaced
9	12	male	33	Fall from height	3	Displaced
10	11	female	36	Fall from height	2	Non-displaced
11	6	female	49	Minor previous trauma	2	Non-displaced
12	8	male	56	Fall from height	3	Displaced
13	9	female	60	Fall from height	2	Non-displaced
14	4	male	97	Fall from height	4	Non-displaced

1 cannulated screw with 1 k-wire in 1 patient, and by 4 k-wires in 1 patient. During the follow-up, valgus osteotomy with external fixation was performed in one neglected fracture, which was partially united at first admission. All cases except one neglected fracture were operated within 24 hours from injury. Of the 14 patients, anatomic reduction was achieved in 12 patients (85.7%) and acceptable reduction was achieved in 2 patients (Table 2).

Thirteen patients had a full hip ROM at last follow-up. One 9 years old girl who had a non-displaced transcervical fracture treated by spica cast and one 5 years old boy with a neglected fracture who had valgus osteotomy and external fixation had limited hip ROM at last follow-up. The mean FNSA at last control was 136 ± 2 degrees (ranges, 122 to 142 degrees) except the neglected case who had 95 degrees of FNSA and partially united Delbet-Colonna Type-I fracture in the beginning. Eleven of 14 patients had good (78.6%), 1 had fair (7.1%) and 2 had poor (14.3%) results according to Ratliff's assessment criteria (Fig. 2)(Table 3).

All patients had a congruent joint however, one patient had Type-I AVN with the signs of arthrosis at the final radiographs (Fig.3). According to Ratliff's AVN classification, 2 patients (14.3%) had Type-III and 1 patient (7.1%) had Type-I AVN. Eleven of the 14 patients (78.6%) did not have the signs of AVN. We had only one Delbet-Colonna Type-I fracture and it

was a 5 years old boy describing previous minor trauma and gradual worsening. At the time of the diagnosis that was partially united in a coxa-vara position thus, we did subtrochanteric valgus osteotomy and used an external fixator to correct the FNSA. This patient had Ratliff Type-III AVN, limited ROM, and a poor result at the latest follow-up. The second Type-III AVN was a 12 years old girl who had displaced Type-3 fracture after a 2 meters fall and treated by CRIF with

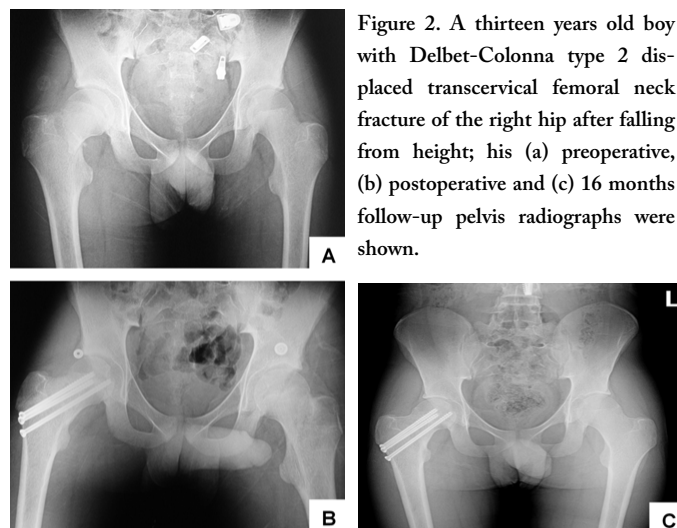


Figure 2. A thirteen years old boy with Delbet-Colonna type 2 displaced transcervical femoral neck fracture of the right hip after falling from height; his (a) preoperative, (b) postoperative and (c) 16 months follow-up pelvis radiographs were shown.

3 cannulated screws. The only Type-I AVN was a 9 years old girl who had non-displaced Type-2 fracture after a 2 meters fall and treated by a spica cast. Premature physseal closure was not noted in any of the treated

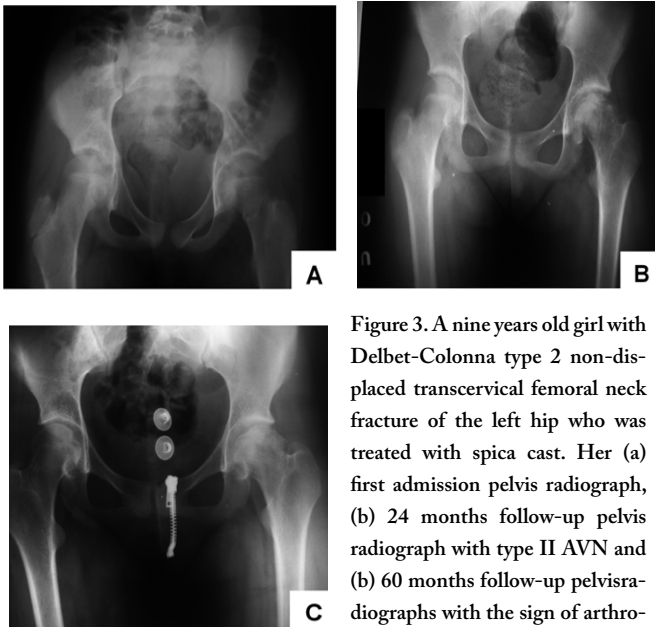


Figure 3. A nine years old girl with Delbet-Colonna type 2 non-displaced transcervical femoral neck fracture of the left hip who was treated with spica cast. Her (a) first admission pelvis radiograph, (b) 24 months follow-up pelvis radiograph with type II AVN and (c) 60 months follow-up pelvis radiographs with the sign of arthritis were shown.

DISCUSSION

There is a vast difference between the studies reporting their success rate on pediatric femoral neck fractures because of its rarity. Ratliff's study contains patients from 1947 to 1959 and the authors reported 42% AVN and almost 30% satisfactory results in displaced fractures [1]. In 1977, Canale et al examined 61 fractures treated in their clinic since 1922 and reported 43% AVN rate equally distributed between both sexes [3]. Their results were comparable with Ratliff's study. Authors showed Delbet Type-I fractures ended up with a 100% AVN rate while Type-II fractures had 52%, Type-III 27% and Type-IV 14% rate of AVN [3]. They also showed that 92% of the fractures, which had AVN, were displaced ones. Moreover, they showed that the risk for AVN increased by child's age [3]. However, Lam published his study with 75 patients treated between 1961 and 1970 and reported much higher successful results with only 17% AVN rate for the first time [2]. They used Knowles pins, Moore pins or Steinman pins primarily for fixation at that time, which are not capable of sufficient compression, therefore might cause worse outcome in displaced fractures. They also did not mention about the time passed until the surgery. Thus, direct comparison of those results with recent ones is not reasonable. However, their conclusions about the complications are still not obsolete and confirmed many times in later studies [2].

Forlin et al reviewed 16 femoral neck fractures with associated complications and showed that coxa vara and premature physeal closure alone was not responsible

for a poor result [7]. Authors concluded that AVN was the most important complication that affects the outcome [7]. Displacement of the fracture, timing of the surgery and quality of the reduction are found to be the predictors of the outcome in many other studies [1-5]. Heiser reported excellent results with non-displaced fractures but half of the displaced fractures in his series ended up with unsatisfactory results [8]. In our series, 2 out of 8 displaced fractures (25%) ended up with Type-III AVN, one poor and one fair results. Only 1 out of 6 (17%) non-displaced fractures ended up with Type-I AVN and poor result.

Flynn et al reported a 6 % incidence of AVN with urgent anatomical reduction rigid internal fixation and spica cast for 6 weeks [9]. Shrader et al reported that the timing of surgery was the major predictor for the risk of AVN [10]. They recommended urgent surgery within 24 hours to reduce the risk of AVN [10]. Other recent studies had also emphasized that delay in fixation is a primary factor responsible for the outcome [11, 12, 13]. In our study, all patients except one with a delayed diagnosis were operated within 24 hours. Neglected fracture ended up with a Type-III AVN. Excluding that neglected fracture, we had 1 Type-I and 1 Type-III AVN that represent 14 % of the patients.

Moon et al showed fracture type and the age were the best predictors of AVN in a large meta-analysis [4]. In our study the only Type-I fracture was a neglected fracture and was partially united at the time of diagnosis and ended up with a Type-III AVN. We had 9 Type-III fractures and only one ended up with a Type-III AVN that means 11% incidence. We had 1 Type-I AVN out of 4 Type-II fractures that means 25% incidence.

Nayeemuddin et al evaluated 15 fractures treated by CRIF with a mean age of 10 years, had a mean of 31 months follow-up, and reported a 93% success rate [14]. They addressed that anatomical reduction with a stable fixation may improve the outcome [14]. Dendane et al reported higher AVN rate after ORIF and they recommended CRIF [15]. However, Song et al reported higher success rate with ORIF (93.3 %) over CRIF (58.3 %) and stated that repeated attempts of closed reduction may harm the vessels of the femoral head and should be avoided [16]. Bali et al had only 2 satisfactory results out of 5 patients that had conservative treatment [17]. They recommended operative treatments especially ORIF over CRIF [17]. In a recent

Table 3. Treatment method and final outcomes of the patients

Patient	Age (years)	Treatment	Fixation Material	Reduction	Hip ROM	FNSA (degree)	Ratliff Classification	Complications
1	14	CRIF	3 Cannulated screws	Anatomic	Full	142	Good	None
2	5	Valgus osteotomy	External fixator	Acceptable	Limited	95	Poor	Type III AVN
3	13	CRIF	3 Cannulated screws	Anatomic	Full	138	Good	None
4	15	CRIF	3 Cannulated screws	Anatomic	Full	137	Good	None
5	16	CRIF	3 Cannulated screws	Anatomic	Full	122	Good	None
6	7	CRIF	3 Cannulated screws	Anatomic	Full	129	Good	None
7	7	CRIF	4 k-wire	Anatomic	Full	133	Good	None
8	11	ORIF	2 Cannulated screws	Acceptable	Full	130	Good	None
9	12	CRIF	3 Cannulated screws	Anatomic	Full	142	Fair	Type III AVN
10	11	CRIF	2 Cannulated screws	Anatomic	Full	138	Good	None
11	6	Spica Cast	None	Anatomic	Full	141	Good	None
12	8	ORIF	1 Cannulated screw and 1 k-wire	Anatomic	Full	140	Good	None
13	9	Spica Cast	None	Anatomic	Limited	137	Poor	Type I AVN, arthrosis
14	4	Spica Cast	None	Anatomic	Full	135	Good	None

study, Stone et al compared femoral neck fractures which were treated by CRIF and ORIF and reported higher AVN rates in CRIF group [18]. However, in the same study no significant difference seen in results according to Ratliff criteria [18]. In our patients, we did not insist on closed reduction and if reduction could not be maintained after a few gentle attempts, we reverted to open reduction. None of the 2 patients in ORIF group had AVN and both ended up with a good result.

Morsy, showed radiologic changes of AVN were evident at an average period of 10 months (ranges, 3 to 20 months) [19]. Therefore, as we know AVN is the most important indicator for unsatisfactory result, long term follow-up is not mandatory for predicting satisfactory outcome. In this manner, we believe our AVN rates would not increase when we lengthen the follow-up.

Inan et al could not find any relation between AVN rate and the age, gender, amount of displacement, treatment time or the type of the surgery [20]. Only factor affects the outcome was the type of the fracture and

Type-II fractures were the worst ones [20]. However, Kuo et al could not find significant relation between fracture type and AVN in their study [21]. Most recently Yeranorian et al made a systematic review of 935 cases in the literature and found early intervention was the only consistent factor that reduced the AVN rate [5]. They could not find clear evidence that capsular decompression had a benefit to avoid AVN [5]. Our AVN rate is also as low as in the studies that recommend capsular decompression even though we did not routinely perform capsular decompression in our patients.

Usually less severe patients are being referred to our hospital thus calculated rate of femoral neck fractures among all pediatric fractures is even less than other reported rates with a 0.16 %. Due to less severe patients, children in our series did not have concomitant injuries like additional fractures, internal organ trauma or brain damage, which may contribute to worse results. In our series, 1 patient was Delbet-Colonna Type-I (6.7%), 4 patients were Type-II (26.7%), 8 patients were Type-III (60%) and 1 patient was Type-IV

(6.7%) fracture. Almost in all previous studies Type-II and Type-III fractures were the most common ones. However, usually Type-II fractures were more often than Type-III. In our study, Type-III fractures were two folds more than Type-II. This may be the consequence of the less vigorously traumatized patients of ours.

Togrul et al reported high premature physeal arrest in their series and thought that was because of iatrogenic physeal damage by implants [22]. Therefore, they recommended not passing through the physis [22]. On the other hand, in our series; attention was mostly given to the stability of the fixation. Physeal penetration was avoided as much as possible without compromising the stability of the fracture. One 7 years old patient had 4 K-wires in her epiphysis and a total of 6 cannulated screws passed through the physis in 3 operated patients who had a mean age of 15 years old and none had noticeable premature physeal closure or AVN. In a recent prospective multi-center study in Indian population, 28 patients with femoral neck fractures were treated and the authors reported 14.2 % AVN rate with 82.1 % good results according to Ratliff's criteria [23]. In the same study, authors divided femoral neck into four zones and recommended smooth pins near to physis and cancellous screws in zones far to physis [23].

The main limitations of this study were its retrospective design and limited patient population. However, pediatric femoral neck fracture is a rare condition to report results in large patient populations. Besides, we compared our results with the literature widely

CONCLUSION: According to our results, we believe that anatomical reduction (close or open) and stable internal fixation is an appropriate method for treating pediatric femoral neck fractures.

Declaration of conflicting interests: The authors declared no conflicts of interest with respect to the authorship and/or publication of this article.

Funding: The authors received no financial support for

the research and/or authorship of this article.

REFERENCES

1. Ratliff AH. Fractures of the neck of the femur in children. *J Bone Joint Surg Br.* 1962 Aug;44-B:528-42.
2. Lam SF. Fractures of the neck of the femur in children. *J Bone Joint Surg Am.* 1971 Sep;53(6):1165-79.
3. Canale ST, Bourland WL. Fracture of the neck and intertrochanteric region of the femur in children. *J Bone Joint Surg Am.* 1977 Jun;59(4):431-43.
4. Moon ES, Mehlman CT. Risk factors for avascular necrosis after femoral neck fractures in children: 25 Cincinnati cases and meta-analysis of 360 cases. *J Orthop Trauma.* 2006 May;20(5):323-9.
5. Yeranossian M, Horneff JG, Baldwin K, et al. Factors affecting the outcome of fractures of the femoral neck in children and adolescents: a systematic review. *Bone Joint J.* 2013 Jan;95-B(1):135-42.
6. Colonna PC. Fractures of the neck of the femur in children. *Am J Surg* 1929;6:793-7.
7. Forlin, E., Guille, J. T., Kumar, S. J. et al. Complications associated with fracture of the neck of the femur in children. *Journal of Pediatric Orthopaedics.* 1992; 12: 503-509.
8. Heiser JM, Oppenheim WL. Fractures of the hip in children: a review of forty cases. *Clin Orthop Relat Res.* 1980 Jun;(149):177-84.
9. Flynn JM, Wong KL, Yeh GL, Meyer JS, Davidson RS. Displaced fractures of the hip in children. Management by early operation and immobilisation in a hip spica cast. *J Bone Joint Surg Br.* 2002 Jan;84(1):108-12.
10. Shrader MW, Jacofsky DJ, Stans AA, Shaughnessy WJ, Haidukewych GJ. Femoral neck fractures in pediatric patients: 30 years experience at a level 1 trauma center. *Clin Orthop Relat Res.* 2007 Jan;454:169-73.
11. Varshney MK, Kumar A, Khan SA, et al. Functional and radiological outcome after delayed fixation of femoral neck fractures in pediatric patients. *J Orthop Traumatol.* 2009 Dec;10(4):211-6. doi: 10.1007/s10195-009-0072-4.
12. Azam MQ, Iraqi A, Sherwani M, et al. Delayed fixation of displaced type II and III pediatric femoral neck fractures. *Indian J Orthop.* 2009 Jul;43(3):253-8.
13. Dhar SA, Ali MF, Dar TA, et al. Delayed fixation of the transcervical fracture of the neck of the femur in the pediatric population: results and complications. *J Child Orthop.* 2009 Dec;3(6):473-7.
14. Nayeemuddin M, Higgins GA, Bache E, O'hara J, Glitheroe P. Complication rate after operative treatment of paediatric femoral neck fractures. *J Pediatr Orthop B.* 2009 Nov;18(6):314-9.
15. Dendane MA, Amrani A, El Alami ZF, et al. Displaced femoral neck fractures in children: are complications predictable? *Orthop Traumatol Surg Res.* 2010 Apr;96(2):161-5.
16. Song KS. Displaced fracture of the femoral neck in children: open versus closed reduction. *J Bone Joint Surg Br.* 2010 Aug;92(8):1148-51.
17. Bali K, Sudesh P, Patel S, et al. Pediatric femoral neck fractures: our 10 years of experience. *Clin Orthop Surg.* 2011 Dec;3(4):302-8.
18. Stone JD, Hill MK, Pan Z, et al. Open Reduction of Pediatric Femoral Neck Fractures Reduces Osteonecrosis Risk. *Orthopedics.* 2015 Nov 1;38(11):e983-90.
19. Morsy HA. Complications of fracture of the neck of the femur in children. A long-term follow-up study. *Injury.* 2001 Jan;32(1):45-51.
20. Inan U, Köse N, Omeroğlu H. Pediatric femur neck fractures: a retrospective analysis of 39 hips. *J Child Orthop.* 2009 Aug;3(4):259-64.
21. Kuo FC, Kuo SJ, Ko JY, Wong T. Complications of hip fractures in children. *Chang Gung Med J.* 2011 Sep-Oct;34(5):512-9.
22. Togrul E, Bayram H, Gulsen M, Kalaci A, Ozbarlas S. Fractures of the femoral neck in children: long-term follow-up in 62 hip fractures. *Injury.* 2005 Jan;36(1):123-30.
23. Panigrahi R, Sahu B, Mahapatra AK, Palo N, Priyadarshi A, Biswal MR. Treatment analysis of paediatric femoral neck fractures: a prospective multicenter therapeutic study in Indian scenario. *Int Orthop.* 2015 Jun;39(6):1121-7.

How to cite this article/Bu makaleye atif için:

Issin A, Çamurcu İY, Konya MN, Şahin V. Clinical and Radiographic Outcomes of Pediatric Femoral Neck Fractures. *Acta Med. Alanya* 2017;1(2): 29-34