



## LETTER TO THE EDITOR

### An uncommon presentation of otogenic brain abscess secondary to acute mastoiditis

Akut mastoidite ikincil nadir görülen bir otojenik beyin apsesi tablosu

Wasim Feroz<sup>1</sup>, Vinodkumar Mugada<sup>2</sup>, Satya Sai Srinivas Allada<sup>2</sup>, Manojna Janipalli<sup>3</sup>

<sup>1</sup>James L. Winkle College of Pharmacy, University of Cincinnati, Ohio, USA

<sup>2</sup>Department of Pharmacy Practice, Vignan Institute of Pharmaceutical Technology, Visakhapatnam, AP, India

<sup>3</sup>Department of Medicine, GITAM Institute of Medical Sciences and Research, Visakhapatnam, AP, India

To the Editor,

A cerebellar abscess, while rare, is a formidable intracranial complication that can arise secondary to conditions such as chronic otitis media and mastoiditis. Despite significant advances in antibiotic therapy and diagnostic imaging modalities, the incidence and severity of brain abscesses remain distressingly high in developing countries, underlining their status as severe, life-threatening complications<sup>1</sup>. These complications can be broadly classified into intracranial, which includes meningitis, central nervous system abscess, and sigmoid sinus thrombosis, and extracranial, encompassing subperiosteal abscess, Luc's abscess, and Bezold's abscess. Delays in recognizing and effectively managing these complications can increase the risks of morbidity and mortality<sup>2</sup>.

Herein, we report an uncommon otogenic cerebellar abscess precipitated by acute mastoiditis in a 35-year-old female. Initial examination and imaging studies led to a tentative diagnosis of right mastoiditis concomitant with right cerebellar hemispheric basal meningitis. However, subsequent careful evaluation of the patient's imaging results prompted a revision of the diagnosis to a right cerebellar abscess, highlighting the complexity and difficulty in diagnosing such rare intracranial complications.

A 35-year-old female presented to a primary care clinic with complaints of severe right-sided ear pain (otalgia) associated with aural discharge and vertigo,

persisting for the past week. Despite the severity of her symptoms, the patient was found to be afebrile, and her vital signs remained stable. She reported no history of smoking or alcohol consumption, and her dietary history revealed a mixed diet consumption pattern. The patient's clinical history included a persistent sensation of blockage in her right ear. An audiogram revealed borderline hearing sensitivity in the right ear, while the left ear demonstrated normal auditory function. Based on these findings, an Ear, Nose, and Throat (ENT) specialist was consulted.

In contrast to the patient's symptoms, the specialist found no signs of otitis media or mastoiditis in the right ear. As such, a conservative treatment approach was recommended. Notwithstanding the recommended pharmacotherapy, the patient's symptoms remained unresolved. On February 9, 2023, the patient complained of a severe headache and vomiting, a reeling sensation lasting for ten days, and fainted twice at home.

Based on the contrast-enhanced brain MRI, the patient was diagnosed with right cerebellar hemispheric basal meningitis, accompanied by an extradural abscess approximately 1.5 cc in volume (Figures 1A and 1B). The MRI images exhibited marked enhancement of the meninges over the posteroinferior aspect of the cerebellum, coupled with an enhancing extradural lesion adjacent to these thickened meninges. Additionally, the imaging demonstrated the coalescence of mastoid air cells on the right side, further confirming the diagnosis.

Address for Correspondence: Wasim Feroz, Department of Pharmaceutical Sciences, James L. Winkle College of Pharmacy, University of Cincinnati, Ohio, USA E-mail: ferozwm@mail.uc.edu

Received: 05.07.2023 Accepted: 08.09.2023

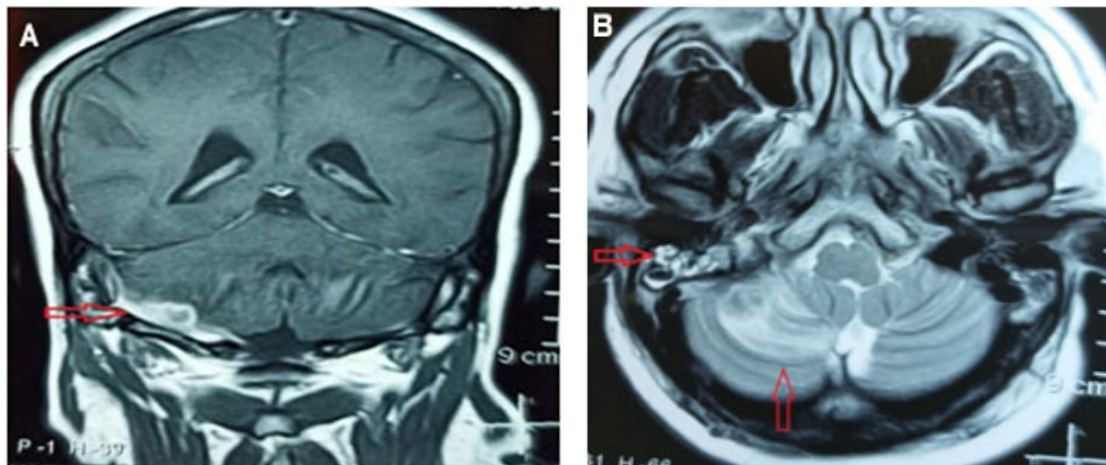


Figure 1(A). Magnetic Resonance Imaging (MRI): Post-contrast T1 image (left) shows extradural abscess.

Figure 1 (B). T2 axial image (right) shows a hyperintense area in the Antero/inferior aspect of right cerebellar hemisphere and hyperintensity noted in the right mastoid air cells.

The radiographic examination of the patient's mastoids, conducted in a Laws lateral view (also known as Schuller's view), revealed significant findings. The mastoid air cells on the right-side exhibited opacity, whereas those on the left side appeared hazy, as illustrated in Figure 2. These radiographic observations are consistent with sequelae indicative of acute mastoiditis on the right side. The initiation of an antibiotic regimen for the

patient began on February 9, 2023, and was planned to last for two weeks. Despite observed improvements in headaches and the absence of vomiting during the four-day hospital stay, the patient requested voluntary discharge. She opted to continue her treatment at a government hospital. Notably, the patient remained afebrile and maintained stable vital signs throughout her hospitalization; however, gait ataxia was observed.

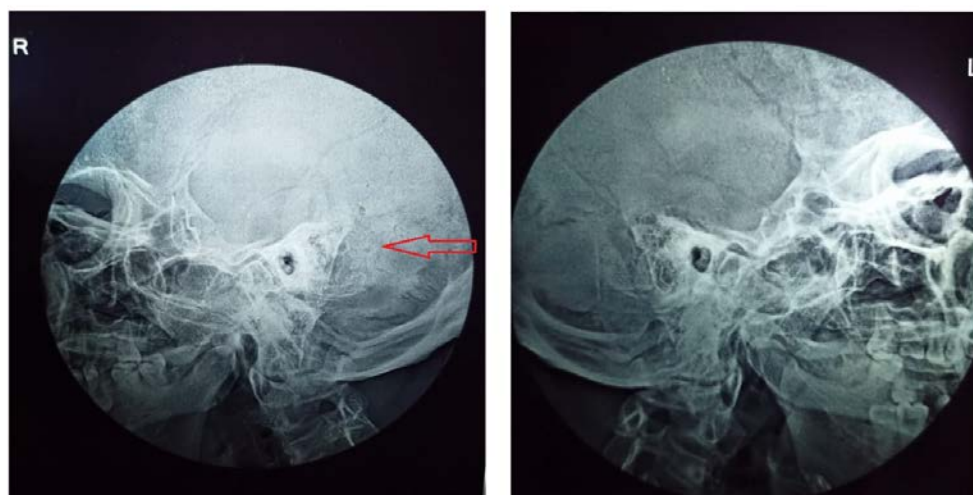


Figure.2 Mastoid air cells are opaque on the right side and hazy on the left side.

From February 13 to 15, 2023, the patient deviated from her antibiotic regimen and reported symptoms of nausea, right-sided headache, and vertigo. She sought the expertise of a neurologist, who diagnosed her condition as right mastoiditis accompanied by a subclinical abscess. A referral was made to both a neurosurgeon and an ENT surgeon, along with a recommendation for a second Magnetic Resonance Imaging (MRI) scan.

The subsequent brain MRI, conducted later, revealed a sub-centimeter lesion with altered signal intensity and minimal blooming on Susceptibility Weighted Imaging (SWI) along the lateral aspect of the right cerebellar hemisphere. Notably, perilesional edema was significantly reduced compared to previous contrast-enhanced MRI studies. In addition, a moderate effusion was observed in the right mastoid air cells. The patient was advised to adhere to the intravenous (IV) antibiotic regimen until March 1, 2023.

On March 2, 2023, the patient reported symptoms of headache and dizziness. A Contrast-Enhanced Computed Tomography (CECT) scan of the brain was ordered, and a revised medication regimen was prescribed. The CECT, performed on March 5, 2023, revealed a subtle calcific focus at the lateral aspect of the right cerebellar hemisphere, with no discernible enhancing lesion in the same region. The patient, who reported mild dizziness, nausea, and insomnia on March 18, 2023, was advised to discontinue the previous medications and was prescribed an alternative regimen. Regular follow-up visits were recommended for the patient's continued healthcare monitoring.

Acute mastoiditis can present in two forms: acute incipient mastoiditis, denoting inflammation of the mastoid air cells, and coalescent mastoiditis, characterized by inflammation of the mastoid's bony trabeculae that culminates in abscess formation<sup>3</sup>. The patient in our report developed coalescent mastoiditis, a condition that contrasts with the common symptoms of intracranial abscesses such as poorly localized, dull headaches<sup>4</sup>. Intriguingly, a triad of symptoms headaches, fever, and focal neurological symptoms was present in only 20% of patients<sup>5</sup>. Our patient presented with otalgia, headache, vomiting, and vertigo but remained afebrile.

The causative agents for brain abscesses are most commonly species of *Streptococcus* and *Staphylococcus*<sup>5</sup>. However, in this case, the likely

source of infection was mastoiditis, although the specific causative organism remained unidentified. Otogenic infections, such as otitis or mastoiditis, account for 33% of infection sources, followed by sinusitis, meningitis, and odontogenic sources<sup>5</sup>.

Intracranial abscesses commonly appear on the same side as the infected ear, typically involving the temporal lobe and cerebellum<sup>6</sup>. An MRI scan led our physician to consider a differential diagnosis of tubercular granuloma. However, a diagnosis of an otogenic brain abscess in the right cerebellar hemisphere was deemed more likely, given the confirmed mastoiditis in the right mastoid air cells via MRI and X-ray.

The management of otogenic brain abscesses requires a multidisciplinary approach, starting with the identification of the size and number of abscesses through imaging techniques. Larger abscesses, accompanied by local edema and hydrocephalus, typically necessitate drainage, whereas smaller abscesses are generally treated with antimicrobials<sup>7</sup>. In the case of our patient, the small size of the abscess and favorable clinical condition—evidenced by a Glasgow Coma Scale (GCS) score greater than 12—made her an ideal candidate for medical treatment. The antimicrobial regimen comprised drugs known to achieve therapeutic concentrations in intracranial pus, such as Cefoperazone+Sulbactam and Linezolid, and was followed by Ofloxacin after three days<sup>8-10</sup>.

The duration of antimicrobial therapy depends on various factors, including the size of the abscess, surgical intervention, the causative organism, and the patient's response to treatment. Recommendations generally suggest a 4–6-week course of treatment for surgically treated abscesses and a 6–8-week regimen of intravenous (IV) treatment for medically treated abscesses<sup>7</sup>. However, these guidelines are flexible and may be adjusted based on continuous patient assessment and follow-up imaging studies.

In our patient's case, despite a brief two-day period during which she voluntarily abstained from treatment, she underwent an 18-day course of IV treatment. Mild edema along the lateral aspect of the right cerebellar hemisphere warranted the addition of dexamethasone to the antimicrobial regimen. After completing the regimen, the patient was discharged when MRI and Contrast-Enhanced Computed Tomography (CECT) confirmed the absence of a right cerebellar abscess. However, she continued to

experience mild vertigo and headaches, for which she maintained her medication regimen.

The emergence of a cerebellar brain abscess, a potentially fatal condition, necessitates immediate medical intervention. The pathogenesis of otogenic intracranial complications is underpinned by multiple factors. In the case of our patient, limited access to healthcare, negligence, lack of health literacy, and socio-economic deprivation were contributing elements. The implementation of a targeted antimicrobial regimen and a strategic surgical approach are pivotal in reducing the associated morbidity and mortality of this disease.

---

**Author Contributions:** Concept/Design : WF, VM, SSSA, MJ; Data acquisition: -; Data analysis and interpretation: WF, VM, SSSA, MJ; Drafting manuscript: WF, VM, SSSA, MJ; Critical revision of manuscript: WF, VM, SSSA, MJ; Final approval and accountability: WF, VM, SSSA, MJ; Technical or material support: MJ; Supervision: -; Securing funding (if available): n/a.

**Ethical Approval:** Ethics Committee approval is not required as it is a case report. Informed consent has been received from the case.

**Peer-review:** Editorial review.

**Conflict of Interest:** Authors declared no conflict of interest.

**Financial Disclosure:** Authors declared no financial support

---

## REFERENCES

1. Mahadevan M, Navarro-Lochin G, Tan HK, Yamanaka N, Sonuwan N, Wang PC et al. A review of the burden of disease due to otitis media in the Asia-Pacific. *Int J Pediatr Otorhinolaryngol.* 2012;76:623-35.
2. Novoa E, Podvinec M, Angst R, Gürtler N. Paediatric otogenic lateral sinus thrombosis: therapeutic management, outcome and thrombophilic evaluation. *Int J Pediatr Otorhinolaryngol.* 2013;77:996-1001.
3. Secko M, Aherne A. Diagnosis of Bezold abscess using bedside ultrasound. *J Emerg Med.* 2013;44:670-2.
4. Tandon S, Beasley N, Swift AC. Changing trends in intracranial abscesses secondary to ear and sinus disease. *J Laryngol Otol.* 2009;123:283-8.
5. Brouwer MC, Coutinho JM, van de Beek D. Clinical characteristics and outcome of brain abscess: systematic review and meta-analysis. *Neurology.* 2014;82:806-13.
6. Sennaroglu I, Sozeri B. Otogenic brain abscess: review of 41 cases. *Otolaryngol Head Neck Surg.* 2000;123:751-5.
7. Arlotti M, Grossi P, Pea F, Tomei G, Vullo V, De Rosa FG et al. GISIG (Gruppo Italiano di Studio sulle Infezioni Gravi) Working Group on Brain Abscesses. Consensus document on controversial issues for the treatment of infections of the central nervous system: bacterial brain abscesses. *Int J Infect Dis.* 2010;14:79-92.
8. Infection in Neurosurgery Working Party of the British Society for Antimicrobial Chemotherapy. The rational use of antibiotics in the treatment of brain abscess. *Br J Neurosurg.* 2000;14:525-30.
9. Mangi RJ, Peccerillo KM, Ryan J, Berenson C, Greco T, Thornton G et al. Cefoperazone versus ceftriaxone monotherapy of nosocomial pneumonia. *Diagn Microbiol Infect Dis.* 1992;15:441-7.
10. Saito N, Aoki K, Sakurai T, Ito K, Hayashi M, Hirata Y et al. Linezolid treatment for intracranial abscesses caused by methicillin-resistant *Staphylococcus aureus*-two case reports. *Neurol Med Chir (Tokyo).* 2010;50:515-7.