



## The comparison of complication rates of subtype subciliary approaches: The review of literature

Osman Kelahmetoglu<sup>a\*</sup>, Ismail Melih Kuzu<sup>a</sup>, Mustafa Unal<sup>a</sup>, Caglayan Yagmur<sup>b</sup>, Kemalettin Yildiz<sup>a</sup>, Ethem Guneren<sup>a</sup>

<sup>a</sup> Department of Plastic, Reconstructive and Aesthetic Surgery, Medical Faculty, Bezmialem Vakif University, Istanbul, Turkey

<sup>b</sup> Department of Plastic, Reconstructive and Aesthetic Surgery, Medical Faculty, Ondokuz Mayıs University, Samsun, Turkey

### ARTICLE INFO

### ABSTRACT

#### Article History

Received 08 / 07 / 2016

Accepted 31 / 08 / 2016

#### \* Correspondence to:

Osman Kelahmetoglu  
Department of Plastic, Reconstructive  
and Aesthetic Surgery,  
Medical Faculty,  
Bezmialem Vakif University,  
e-mail: osmankelahmetoglu@gmail.com

#### Keywords:

Approach  
Ectropion  
Lower lid  
Scleral show  
Subciliary

Incision techniques to lower lid and midface skeleton and their surgical outcomes are often debated in the literature. Our main objective in this study was to discuss the main variations of subciliary approach with their potential complications and to review the literature about the subciliary incision subtypes and their complication rates. We tried to summarize the reported series of patients according to their subciliary approach subtypes and complication rates. A literature search with keywords “subciliary approach” and “subciliary incision” were done and the results were analyzed. All the studies stating information about the variation of subciliary approach and complication rates were included. Although there are many techniques described for approach to lower eyelid and midface skeleton, there are limited amount of studies comparing the complication rates between different approaches. Most of the studies have compared transcutaneous and transconjunctival approaches. Transcutaneous subciliary incision has 3 main modifications: Skin-only, nonstepped skin-muscle and stepped skin-muscle flap. There is only one study found comparing the skin-only and stepped skin-muscle flap series' complications. We included in this review all studies containing the subtype information and complication numbers. Among subciliary incision subtypes the skin-only flap approach has the highest complication rates. According to the literature skin-muscle approaches, either stepped or nonstepped are associated with lower incidence of complications with respect to skin-only flap. They also have more favorable long-term results with almost excellent aesthetic outcomes, decreased ecchymosis and skin necrosis, and significantly lower rates of ectropion.

© 2016 OMU

### 1. Introduction

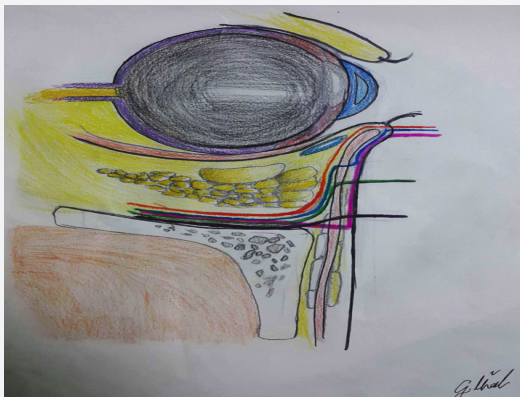
Subciliary incision is firstly described by Converse in 1944. It is frequently used in surgical approach to facial fractures such as traumatic blow-out injury, infraorbital rim and orbitozygomatic fracture repair. This approach is also used in aesthetic surgery of lower eyelid. Historically the subciliary approach is used in two

subtypes: the skin-only flap and the skin-muscle flap. Firstly the “skin-only flap” has been used and found that it was associated with high risk of skin necrosis and ectropion (Wray et al., 1977). The skin-muscle flap includes the skin and orbicularis oculi muscle and the dissection continues deep to orbicularis oculi till the infraorbital rim. The remarkable modification of the

skin-muscle flap is the stepped approach (Rohrich et al., 2003). This includes the subciliary skin incision and division of the muscle after elevating several millimeters of skin flap (Fig. 1). There are many articles and reviews comparing the transcutaneous and transconjunctival or subciliary and subtarsal approaches. The search on literature about subciliary modifications revealed one study comparing the skin-only flap and stepped skin-muscle flap (Ozakpınar et al., 2015). No review was found comparing all modifications of subciliary approach. In this article we tried to analyze the studies about the modifications of subciliary approach and their results.

## 2. Material and methods

A systematic review and a PUBMED search of the English language literature was performed of words such as “subciliary approach” and “subciliary incision”. Studies were included whether they showed a prospective data, retrospective data or case series



**Fig. 1.** Illustration of subciliary. **Red:** Skin-muscle; **Blue:** Stepped skin-muscle; **Purple:** skin; **Green:** Subtarsal; black: infraorbital incisions

data. Inclusion criteria were studies that stated the variation of the subciliary approach and detailed information about complications depending on the surgical technique.

## 3. Results

A search between the years 1950 and 2016 was performed on PUBMED central search engine. In total 35 articles were reached for this study. Fourteen of these articles containing information about the subtype of subciliary incision and their complication rates were studied in detail. The articles were evaluated about complications such as lagophthalmos, transient/permanent ectropion, scleral show, noticeable scar and entropion according to subtype of subciliary incision (Table 1).

## 4. Discussion

Subciliary approach can be used in blepharoplasty, maxillofacial fracture repair, external dacryocystorhinostomy, maxillectomy (Goyal et al., 2011), nasal bone reduction are the most common undesired results.

In the literature it has been frequently questioned (Loeb, 1989) whether scleral show and ectropion are varying degrees of same condition or are separate entities. Certainly both result from loss of muscle tonus and scar tissue formation between orbicularis muscle and surrounding soft tissue. Some authors believe that ectropion is just a severe form of scleral show with lid eversion (Bähr et al., 1992).

To prevent ectropion and scleral show many authors (Converse, 1981; Manson et al., 1987; Loeb, 1989) have proposed preserving a pretarsal portion of orbicularis muscle in the maintenance of proper lower lid tonus. This has been a milestone in widespread use of stepped skin-muscle approach. Subciliary

**Table 1.** Systemic review results

Authors	Number of patients	Technique	Lagophthalmus	Scleral show	Ectropion	Noticeable / Undesirable Scar
Heckler et al.	154	Skin-muscle	-	9	-	-
De Riu et al.	23	Stepped skin-muscle	5	-	-	10
Hwang et al.	57	Skin-muscle	-	-	-	-
Pausch et al.	225	Skin-muscle	-	-	8	-
Sevim et al.	98	Stepped skin-muscle	-	-	-	-
Liapakis et al.	35	Stepped skin-muscle	-	7 transient	-	-
Raschke et al.	92	Stepped skin-muscle	-	20	5	-
Appling et al.	27	Skin-muscle	-	8	3 transient	-
Bähr et al.	16	Skin-muscle	-	3	1	-
Salgarelli et al.	219	Stepped skin-muscle	-	3	-	38
Gosau et al.	13	Skin-muscle	-	-	5	-
Giraddi and Syed	10	Stepped skin-muscle	-	-	3 transient	-
Simon	20	Skin-muscle	-	-	3	-
Özakpınar et al.	39	Skin-only	-	18	8	16
	51	Stepped skin-muscle	-	4	-	1

incision via this stepwise approach helps to preserve a muscle strip and to prevent scarring of the eyelid, consequently preventing loss of muscle tonus, scleral show, ectropion and lagophthalmos. Furthermore Hwang et al. (2016) indicated stepped skin-muscle flap has wrinkle-reducing effect and good functional results so they preferred it over transconjunctival approach in blow-out fractures or zygomatic fractures.

### **Scleral show**

The early post-operative scleral show is common and may be transient. Liapakis et al. (2014) documented 35 patients operated for tear-through deformity and scleral show was noted in 7 (20%) patients but resolved in 6 months period without any surgical intervention. Raschke et al. (2013) had a series of 92 patients after zygomaticomaxillary complex fracture repair and in 9 months follow-up 21 patients (23%) had scleral show. Similarly Bähr et al. (1992) reported 18.8% of scleral show in their series. Heckler et al. (1983) reported in their series (154 patients) 6% rate of transient scleral show. The only study reporting a comparison between skin-only flap and skin-muscle flap technique found that scleral show without lid eversion rates were 46% and 7%, respectively (Ozakpinar et al., 2015).

### **Ectropion**

Postoperative ectropion is attributed to scarring of the anterior lamella of inferior eyelid. Transient/permanent ectropion is one of the most common complications after subciliary approach. Usually transient ectropion resolves in 6 months via conventional scar management therapies and massage without requiring surgery. Especially skin-only subciliary approach has been associated with a high rate of ectropion as high as 42% (Wray et al., 1977), whereas skin-muscle flap approach significantly reduces both transient and permanent ectropion rates. Ozakpinar et al. (2015) reported that 20% of patients operated with skin-only flap technique had ectropion and in skin-muscle flap group ectropion was not observed after one year follow-up. Pausch et al. (2016) reported a series with 225 subciliary approaches with skin-muscle flap and after six months follow-up 12 of 225 patients (5.3%) and eight of 225 patients (3.6%) had transient and permanent ectropion, respectively. Ectropion rates reported with stepped skin-muscle approach differs between 12% (Appling et al., 1993) and 6.3% (Bähr et al., 1992). Other series with stepped skin-muscle flap had no ectropion (De Riu et al., 2008; Liapakis et al., 2014; Sevim et al., 2014; Hwang et al., 2016). In most severe cases significant

scar formation may cause lower lid retraction. Gosau et al. (2011) reported 5 of 13 patients (38.5%) operated via subciliary incision developed postoperative lower lid retraction; three of them required surgical intervention with scar release followed by defect filling with a full thickness skin graft.

### **Lagophthalmos**

Lagophthalmos has been reported only in one article. De Riu et al. (2008) operated 23 patients with stepped skin-muscle approach and after one year follow-up five patients (22%) developed lagophthalmos without any ocular discomfort or local eye symptoms, with a mean scleral exposure of 0.80 mm.

### **Entropion**

None of the included studies with subciliary approach involved entropion. As a complication, entropion is usually associated with transconjunctival approach (Salgarelli et al., 2010; Giraddi and Syed, 2012).

### **Noticeable scar**

Scar formation after subciliary incision can be classified as noticeable scar and hypertrophic scar. In elderly patients noticeable scar formation is not common due to loose and wrinkled skin. However in young population noticeable scar formation may be likely depending on skin type. De Riu et al. (2008) reported 10 of 23 patients (44%) had noticeable scar. Salgarelli et al. (2010) reported a visible, non-hypertrophic scar developed in 38 of 219 patients (17.5%) who had been treated via a subciliary incision. Ozakpinar et al. (2015) compared the scar values of the skin-muscle flap and skin-only flap approaches and scar formation in skin-muscle group were significantly lower than the skin-only group statistically 2% and 40%, respectively. Hypertrophic scar formation requires very close follow-up and scar management. Ridgway et al. (2009) reported in 2 of 56 patients hypertrophic scar formation.

There are three described approaches to lower eyelid and midface skeleton with subciliary incision. To our knowledge and research it is obvious that skin-only flap has higherrates of complication such as lower eyelid malposition, scleral show and ectropion. (Heckler et al., 1983; Pospisil and Fernando, 1984; Ozakpinar et al., 2015). But, between nonsteppedskin-muscle and stepped skin-muscle flap, it has not been clearly demonstrated that one variation is superior to another. Many factors must be taken into consideration and the optimal approach should be chosen.

## **REFERENCES**

- Appling, W.D., Patrinely, J.R., Salzer, T.A., 1993. Trans conjunctival approachvs subciliary skin-muscle flap approach for orbital fracture repair. *Arch. Otolaryngol. Head Neck Surg.* 119, 1000-1007. doi: 10.1001/archotol.1993.01880210090012.

- Bähr, W., Bagambisa, F.B., Schlegel, G., Schilli, W., 1992. Comparison of transcutaneous incisions used for exposure of the infraorbital rim and orbital floor: A retrospective study. *Plast. Reconstr. Surg.* 90, 585-591. doi:10.1097/00006534-199210000-00006.
- Ben Simon, G.J., Molina, M., Schwarcz, R.M., McCann, J.D., Goldberg, R.A., 2005. External (subciliary) vs internal (transconjunctival) involutional entropion repair. *Am. J. Ophthalmol.* 139, 482-487. doi: 10.1016/j.ajo.2004.10.003.
- Converse, J., 1944. Two plastic operations for repair of orbit following severe trauma and extensive comminuted fracture. *Arch. Ophthalmol.* 31, 323-325. doi: 10.1001/archophth.1944.00890040061010.
- Converse, J., 1981. A randomized comparison of four incisions for orbital fractures. *Plast. Reconstr. Surg.* 67, 736. doi: 10.1097/00006534-198106000-00004.
- De Riu, G., Meloni, S.M., Gobbi, R., Soma, D., Baj, A., Tullio, A., 2008. Subciliary versus swinging eyelid approach to the orbital floor. *J. Craniomaxillofac. Surg.* 36, 439-442. doi: 10.1016/j.jcms.2008.07.005.
- Giraddi, G.B., Syed, M.K., 2012. Preseptal transconjunctival vs. subciliary approach in treatment of infraorbital rim and floor fractures. *Ann. Maxillofac. Surg.* 2, 136-140. doi: 10.4103/2231-0746.101338.
- Gosau, M., Schöneich, M., Draenert, F.G., Ettl, T., Driemel, O., Reichert, T.E., 2011. Retrospective analysis of orbital floor fractures - complications, outcome, and review of literature. *Clin. Oral Investig.* 15, 305-313. doi: 10.1007/s00784-010-0385-y.
- Goyal, A., Tyagi, I., Jain, S., Syal, R., Singh, A.P., Kapila, R., 2011. Transconjunctival incision for total maxillectomy - an alternative for subciliary incision. *Br. J. Oral Maxillofac. Surg.* 49, 442-446. doi: 10.1016/j.bjoms.2010.07.002.
- Heckler, F.R., Songcharoen, S., Sultani, F.A., 1983. Subciliary incision and skin-muscle eyelid flap for orbital fractures. *Ann. Plast. Surg.* 10, 309. doi: 10.1097/0000637-198304000-00009.
- Hwang, K., Choi, J.H., Kim, J.H., 2016. Improvement of nasojugal groove and wrinkles following a skin-muscle flap elevation through a subciliary approach to the orbital rim. *J. Craniofac. Surg.* 27, 741-744. doi: 10.1097/scs.0000000000002591.
- Liapakis, I.E., Paschalis, E.I., Zambacos, G.J., Englander, M., Mandrekas, A.D., 2014. Redraping of the fat and eye lift for the correction of the tear trough. *J. Craniomaxillofac. Surg.* 42, 1497-1502. doi: 10.1016/j.jcms.2014.04.020.
- Loeb, R., 1989. Scleral show. In *aesthetic surgery of the eyelids*, R. Loeb and S. Braley (Eds.), New York: Springer-Verlag, pp. 13-23. doi: n/a.
- Manson, P.N., Ruas, E., Iliff, N., Yaremchuk, M., 1987. Single eyelid incision for exposure of the zygomatic bone and orbital reconstruction. *Plast. Reconstr. Surg.* 79, 120. doi: 10.1097/00006534-198701000-00023.
- Ozakpinar, H.R., Sari, E., Tellioğlu, A.T., Sandıkci, M.M., Inozu, E., Seven, E., Eryilmaz, T., Karamursel, S., 2015. Comparison of subciliary approaches in orbito-zygomatic fractures: Skin flap versus skin-muscle flap. *J. Craniofac. Surg.* 26, 2094-2098. doi: 10.1097/scs.0000000000002076.
- Pausch, N.C., Sirintawat, N., Wagner, R., Halama, D., Dhanuthai, K., 2016. Lower eyelid complications associated with transconjunctival versus subciliary approaches to orbital floor fractures. *Oral Maxillofac. Surg.* 20, 51-55. doi: 10.1007/s10006-015-0526-1.
- Pospisil, O.A., Fernando, T.D., 1984. Review of the lower blepharoplasty incision as a surgical approach to zygomatic-orbital fractures. *Br. J. Oral Maxillofac. Surg.* 22, 261. doi: 10.1016/0266-4356(84)90082-2.
- Raschke, G.F., Rieger, U.M., Bader, R.D., Schaefer, O., Guentsch, A., Schultze-Mosgau, S., 2013. Transconjunctival versus subciliary approach for orbital fracture repair - anthropometric evaluation of 221 cases. *Clin. Oral Investig.* 17, 933-942. doi: 10.1007/s00784-012-0776-3.
- Ridgway, E.B., Chen, C., Colakoglu, S., Gautam, S., Lee, B.T., 2009. The incidence of lower eye lid malposition after facial fracture repair: A retrospective study and meta-analysis comparing subciliary, transconjunctival, and transconjunctival incisions. *Plast. Reconstr. Surg.* 124, 1578-1586. doi: 10.1097/prs.0b013e3181babb3d.
- Rohrich, R.J., Janis, J.E., Adams, W.P. Jr., 2003. Subciliary versus subciliary approaches to orbitozygomatic fractures. *Plast. Reconstr. Surg.* 111, 1708-1714. doi: 10.1097/01.prs.0000054209.18400.4e.
- Salgarelli, A.C., Bellini, P., Landini, B., Multinu, A., Consolo, U., 2010. A comparative study of different approaches in the treatment of orbital trauma: An experience based on 274 cases. *Oral Maxillofac. Surg.* 14, 23-27. doi: 10.1007/s10006-009-0176-2.
- Sevim, K.Z., Akcal, A., Dagdelen, D., Yazar, M., Yesilada, A., 2014. Beneficial effects of turn over orbicularis oculi muscle flap for treating facial fractures via subciliary incision. *J. Craniofac. Surg.* 25, 1465-1467. doi: 10.1097/scs.0000000000000870.
- Wray, R.C., Holtmann, B.N., Ribaldo, J.M., Keiter, J., Weeks, P.M., 1977. A comparison of conjunctival and subciliary incisions for orbital fractures. *Br. J. Plast. Surg.* 30, 142. doi: 10.1016/0007-1226(77)90009-1.