

# Clinical Detection of Presence and Absence of Palmaris Longus Tendon in Somali Population

## Somali Popülasyonunda Palmaris Longus Tendonunun Varlığı ve Yokluğunun Klinik Tespiti

Hasan May<sup>1</sup>, Abdullahi Yusuf Mohamed<sup>2</sup>

<sup>1</sup> Health Sciences University, Antalya Training and Research Hospital, Department of Orthopedics and Traumatology, Antalya, Turkey

<sup>2</sup> University of Health Sciences, Recep Tayyip Erdogan Vocational School of Health Sciences, Mogadisu, Somalia

### ABSTRACT

**Aim:** The aim of this study was to investigate whether the frequency of palmaris longus (PL) absence in Somali population differed from other populations in Africa and the rest of the world and to evaluate its association with sex and side of the limb involved.

**Methods:** Totally 1,000 participants (713 males and 287 females; age range: 7 to 80 years) were tested for the absence of PL tendon using Schaffer's test. In those with a negative Schaffer's test result, Thompson's test, Mishra's test I, Mishra's test II, and Pushpakumar's "two-finger sign" method were used to confirm its absence.

**Results:** Absence of PL tendon was found in 95 (9.5%) participants. The PL muscle was absent bilaterally in 42 (4.4%) and unilaterally in 53 (5.5%) participants. Unilateral absence of PL was higher in the right hand (3.0%) ( $p>0.05$ ). Agenesis of the right side in males was significantly correlated with the left side in males ( $rs=0.556$ ,  $p<0.01$ ). Right agenesis in females was significantly correlated with its left side ( $rs=0.625$ ,  $p<0.01$ ). The incidence of right and left agenesis in females was more strongly correlated than that in males. Age was significantly correlated with left agenesis ( $rs=0.154$ ,  $p<0.01$ ) and right agenesis ( $rs=0.145$ ,  $p<0.05$ ) in females.

**Conclusion:** The prevalence of PL agenesis in the Somali population is lower than the reported incidence of 15%, but more significantly higher than some of the other African populations. These findings may be helpful, particularly for the surgeons in the region, for orthopedic and reconstructive surgeries using PL grafting.

**Key Words:** Palmaris longus, Tendon grafts, Variation, Somalia

### ÖZET

**Amaç:** Bu çalışmada Somali popülasyonunda palmaris longus (PL) yokluğunun sıklığının Afrika ve dünyanın diğer ülkelerindeki popülasyonlardan farklı olup olmadığı araştırıldı ve bu durumun cinsiyet ve tutulan ekstremitenin tarafı ile olan ilişkisi incelendi.

**Yöntem:** Toplam 1000 katılımcı (713 erkek ve 287 kadın; yaş aralığı: 7-80 yıl) Schaffer testi ile PL tendon yokluğu açısından değerlendirildi. Schaffer testi sonucu negatif olanlara tanıyı doğrulamak amacıyla Thompson testi, Mishra testi I, Mishra testi II ve Pushpakumar "iki parmak işareti" yöntemi yapıldı.

**Bulgular:** Katılımcıların 95'inde (%9.5) PL tendonu bulunmuyordu. Katılımcıların 42'sinde (%4.4) iki taraflı ve 53'ünde (%5.5) tek taraflı olarak PL kası yoktu. Tek taraflı PL yokluğu sağ elde daha yüksek oranda izlendi (%3.0) ( $p>0.05$ ). Erkeklerde sağ taraflı agenezi, erkeklerde sol taraflı agenezi ile anlamlı düzeyde ilişkili bulundu ( $rs=0.556$ ,  $p<0.01$ ). Kadınlarda sağ taraflı agenezi, sol taraflı agenezi ile anlamlı düzeyde ilişkili bulundu ( $rs=0.625$ ,  $p<0.01$ ). Kadınlarda sağ ve sol taraflı agenezi insidansı, erkeklerinkine kıyasla daha yüksek düzeyde ilişkili idi. Yaş, kadınlarda sol taraflı agenezi ( $rs=0.154$ ,  $p<0.01$ ) ve sağ taraflı agenezi ( $rs=0.145$ ,  $p<0.05$ ) ile anlamlı düzeyde ilişkili bulundu.

**Sonuç:** Somali popülasyonunda PL agenezi prevalansı bildirilen %15'lik insidandan daha düşük olup, diğer Afrika popülasyonlarının bazılarında anlamlı düzeyde daha yüksektir. Bu bulgular, özellikle bölgedeki cerrahlar için PL greftleme ile yapılan ortopedi ve rekonstrüktif ameliyatları açısından yararlı olabilir.

**Anahtar Kelimeler:** Palmaris longus, Tendon greftleri, Varyasyon, Somali

Received Date: 14.08.2023 / Accepted Date: 16.09.2023 / Published (Online) Date: 29.10.2023

Corresponding author: Hasan MAY. Health Sciences University, Antalya Training and Research Hospital, Department of Orthopedics and Traumatology, Antalya, Türkiye.

Phone: 05055671331 / mail: mayhasan@gmail.com

ORCID: 0000-0001-7592-2147

To cited: May H & Mohamed AY. Clinical Detection of Presence and Absence of Palmaris Longus Tendon in Somali Population. Alanya 2023;7(2): 178-183  
doi: 10.30565/medalanya.1342908



Acta Medica Alanya MAY-AUG 2023 Open Access <http://dergipark.gov.tr/medalanya>  
This article is distributed under the terms of the Creative Commons Attribution 4.0 International License

## Introduction

Palmaris longus (PL) is a superficial muscle of the forearm, mainly tendinous except for a small portion of its length, which is composed of a muscle belly [1]. It originates from the medial epicondyle of the humerus and, as a long and thin tendon, it lies medial to the flexor carpi radialis [1,2]. Its long tendon passes above the flexor retinaculum and attaches to the connective tissue of the palmar aponeurosis [1,2]. Its primary function is the augmentation of the palmar fascia that serves as an accessory flexor of the wrist and thumb abductor [3]. Due to the proximity to the surface, as a long muscle and clear tendon, PL is simple to identify and easily accessible [4]. Of note, PL is considered a non-essential muscle, as its absence does not severely affect the functions of the wrist and hands [1]. The PL tendon is one of the most commonly used donors for autologous tendon graft or tendon transfer [5]. Therefore, identifying the presence of a PL tendon is critical for reconstructive hand surgeries to minimize potential complications. To date, several physical examination maneuvers have been described to detect the PL tendon [5].

The PL tendon is considered to be congenitally absent in approximately 15% of the population [6]. However, the reported incidence of agenesis varies extensively by ethnicity, from 0.6% in Korea [7] to 64% in Turkey [8]. The PL has been studied considerably using various examination methods, and the prevalence of its absence varies significantly across different populations, 0.6 to 3.2% in Koreans, 1.02% in Ugandans, 3 to 4.2% in Japanese, 3.3 to 17.2% in Brazilians, 4.5 to 22.5% in African Americans, 4.5 to 55.2% in Egyptians, 3.8 to 5.6% in Chinese, 4.4 to 32.2% in Hungarians, 5.8 to 15.2% in Canadians, 6.7 to 25% in Nigerians, 6.1 to 11.7% in Malaysians, 11.6% in Czechs, 13.2 to 33.7% in Iranians, 12.8 to 18.3% in Iraqis, 11.7% in Ethiopians, 24% in North American Caucasians, 16.8% in UK, 16.7 to 27.9% in Saudis and Bahraini, and 14.5 to 64% in Turkish population [9,10]. In addition to the congenital absence of the PL, morphological variations have been identified. The tendon may be duplicated, reversed, bifid, or have an accessory muscle belly or divided to form an ulnar accessory slip distally [11].

In this present study, we aimed to determine the frequency of the absence of the PL in the Somali population and to compare it with relevant populations in Africa and the rest of the world. The second objective was to evaluate the association of PL agenesis with sex and the laterality of the limb.

## Materials and Methods

### Study Design and Study Population

This study was designed as a single-center, cross-sectional study. A total of 1,000 participants including 713 males and 287 females with an age range of 7 to 80 years were

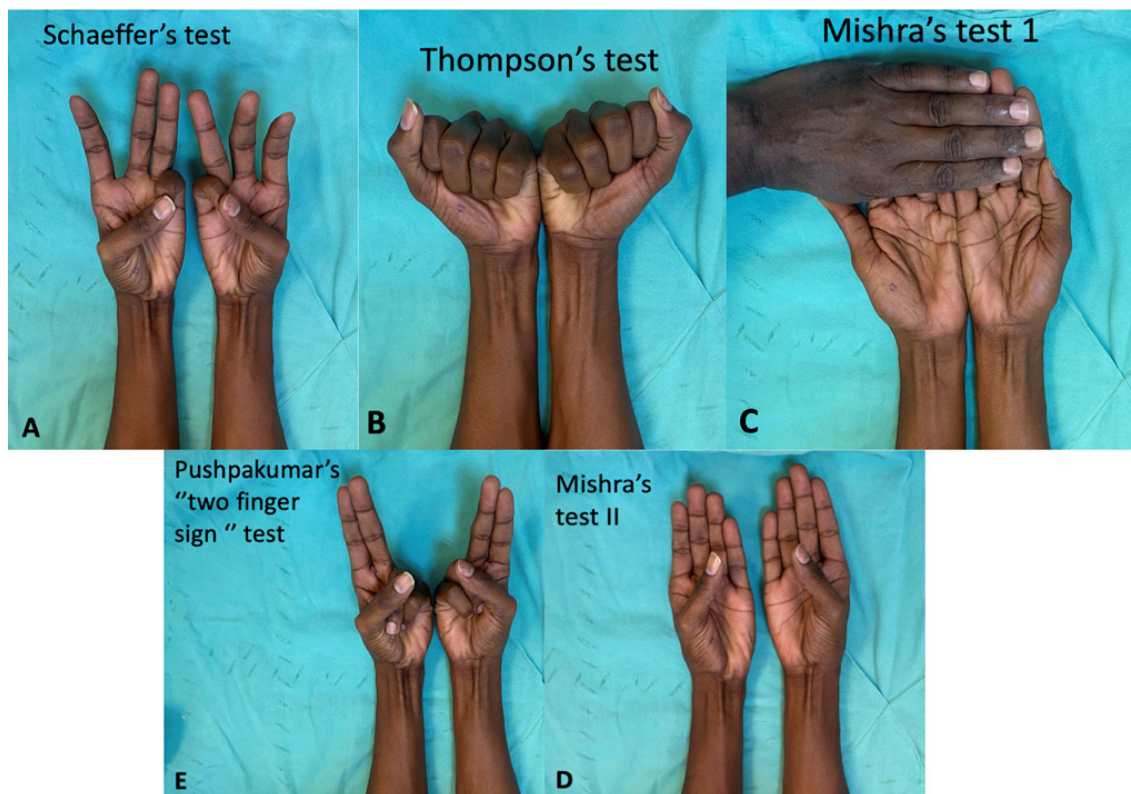
included. The participants consisted of patients visiting the Orthopedics and Traumatology Department of our hospital, hospital personnel from different areas, and soldiers from the TURKSOM military compound. Those with a history of injury, surgery, scars on the wrist area, or any physical disabilities of their upper limbs were excluded from the study. All participants were informed about the nature of the study and a written informed consent was obtained on a voluntary basis. The study protocol was approved by the institutional Ethics Committee (No: 10909, Date: 07/04/2022). The study was conducted in accordance with the principles of the Declaration of Helsinki.

### Clinical Tests

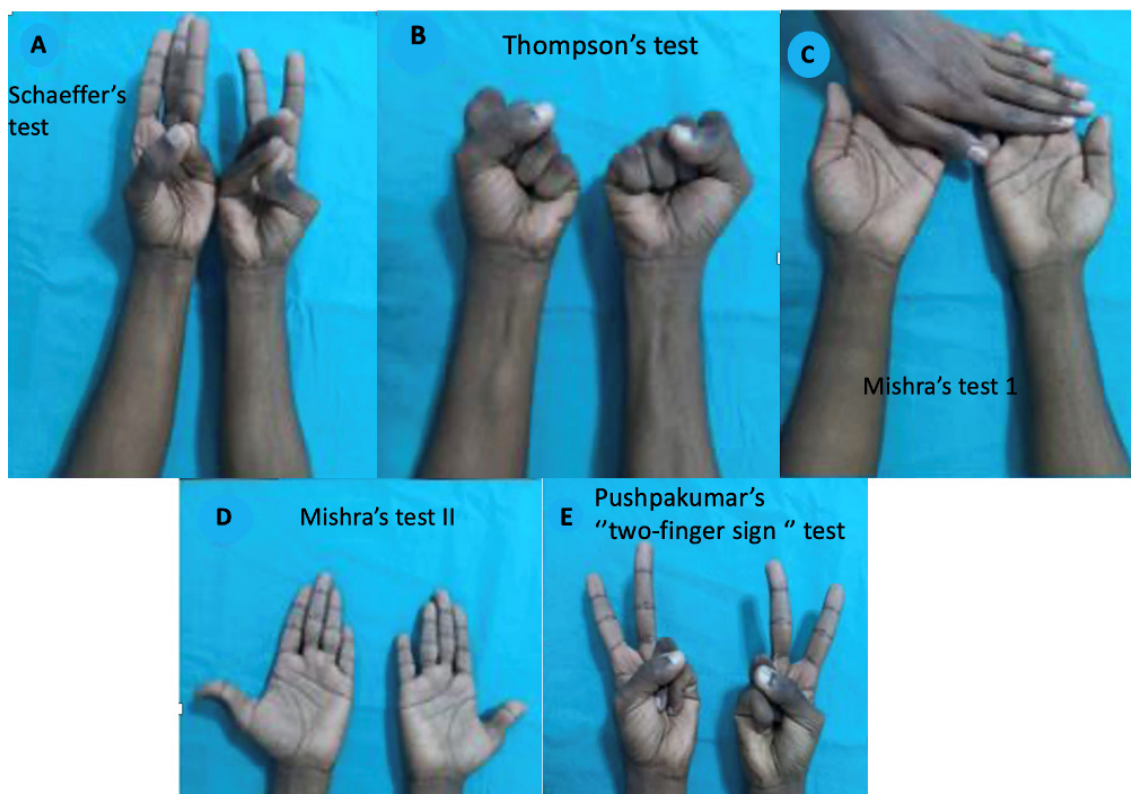
All participants underwent physical examination of both wrists by an orthopedics specialist and a fifth-year (PGY5) orthopedics senior resident physician. The presence of PL tendons was examined using five assessment methods. The participants were initially asked to perform Schaeffer's test [12]; opposition of the thumb to the little finger and then flexed the wrist to assess the PL tendon (Figure 1A). If the tendon was unable to be visualized due to the inability to maneuver the technique, the additional tests of Thompson's [13] (Figure 1B), Mishra's test I and II [14] (Figure 1C and Figure 1D), and Pushpakumar's "two-finger sign" [15] (Figure 1E) were performed to confirm the absence of the tendon. If the participant had a positive result for any of the five tests, the presence of PL was considered. To regard to have an absence of a PL, the participant must have a negative test for all of the five tests (Figure 2). The Thompson's test involves flexion of the fingers to form a fist and flexion of the wrist with the thumb as opposed and flexed over the fingers. In the Mishra's test I, the participants were asked to abduct the thumb against resistance with the wrist slightly flexed. The Mishra's test II involves the abduction of the thumb against resistance and wrist flexion partially. In the Pushpakumar's "two-finger sign" method, the volunteers were made to extend the index and middle fingers fully with the wrist and other fingers flexed, followed by opposition and flexion of the thumb.

### Statistical Analysis

Statistical analysis was performed using the Statistical Package for the Social Sciences (SPSS) version 26.0 software (IBM Corp., Armonk, NY, USA). Descriptive data were expressed in number and frequency. The Chi-square test was used to identify the differences between the categorical variables. Since the data was non-normally distributed, the Spearman's rank order test was used for correlation analyses to assess the association of PL absence in both sexes unilaterally and bilaterally. A  $p$  value of  $<0.05$  was considered statistically significant.



**Figure 1.** Presence of the palmaris longus tendon. A. Schaeffer's test; B. Thompson's test; C. Mishra's test I; D. Mishra's test II; E. Pushpakumar's "two-finger sign" test.



**Figure 2.** Absence of the palmaris longus tendon. A. Schaeffer's test; B. Thompson's test; C. Mishra's test I; D. Mishra's test II; E. Pushpakumar's "two-finger sign" test.



## Results

The overall PL absence was found in 95 (9.5%) participants (n=71 for males and n=24 for females). The PL muscle was absent bilaterally in 42 (4.4%) and unilaterally in 53 (5.5%) participants. There was no significant difference in the bilateral absence between the male (4.5%) and female (4.4%) participants ( $p>0.05$ ). In addition, there was no significant difference in the unilateral absence between the male (6%) and female (4.4%) participants ( $p>0.05$ ). Although the rate of unilateral absence of the PL was higher in the right hand (3.0%) than in the left hand (2.7%), it did not reach statistical significance ( $p>0.05$ ). The rate PL absence in the right and left hands was higher in males than females, while there was no significant difference between two sexes ( $p>0.05$ , Table 1).

The Spearman's rank order tests revealed that the agenesis of the right side in males was significantly correlated with the left side in males ( $r_s=0.556$ ,  $p<0.01$ ). Similarly, right agenesis in females was significantly correlated with its left side ( $r_s=0.625$ ,  $p<0.01$ ). The incidence of right and left agenesis in females was more strongly correlated than that in males. Age was significantly correlated with left agenesis ( $r_s=0.154$ ,  $p<0.01$ ) and right agenesis ( $r_s=0.145$ ,  $p<0.05$ ) in females.

## Discussion

In the present study, we attempted to investigate the prevalence of the absence of PL muscle in the Somali population. Our study results showed that the overall prevalence of PL absence was 9.5%. This ratio is comparable to the low prevalence of PL agenesis reported in African populations, Ghana (3.1%) [16], East Africa (4.4%) [17], Yoruba ethnic

population in Nigeria (6.7%) [18], African Antiguan population (12.8%) [19], and the lowest number was reported in Zimbabwe (1.5%) [20]. On the other hand, a slightly higher prevalence of PL absence was identified in Ethiopian (15.3%) [21] and South African (19.6%) [22] populations. The lower rate of the absence of PL may be explained by the higher prevalence of manual labor in African populations. It is reasonable that manual labor anticipates more dynamic wrist motion and increasing instances in which the PL is brought into action. Manual labor also requires tensed palmar fascia for a strong grip, which may lead less occurrence of agenesis of the PL muscle [17,19]. This low frequency of absence of the PL in the Somali population supports the racial differences previously noted. This finding may be helpful for the surgeons working in this field regarding the probability of identifying the PL tendon for tendon grafts or various reconstructive procedures.

Although not statistically significant, our study in Somali population showed that the overall prevalence of bilateral and unilateral agenesis is more common in males than females. The prevalence of unilateral agenesis was higher than bilateral agenesis, and right agenesis occurred more commonly. These findings are consistent with studies in Uganda [17], Nigeria [18], and South Africa [22]. On the other hand, studies conducted in Turkey [9,10], African Antiguan [19], Zimbabwe [20], and South India [23] have shown that bilateral agenesis is more common in males than the females. These reports also emphasize that the left side agenesis was more significant than the right-side agenesis.

The main limitation to this study is the utilization of clinical tests to detect the presence of the PL tendon. This examination depends on the examiner compared to cadaveric

**Table 1.** Distribution of palmaris longus agenesis and its lateralization by sex

Sex	PLP n (%)	PLA n (%)	PLP n (%)	ULA n (%)	PLP n (%)	BLA n (%)	PLP n (%)	RULA n (%)	PLP n (%)	LULA n (%)
Female (n=287)	263 91.6%	24 8.4%	263 95.6%	12 4.4%	263 95.6%	12 4.4%	263 97.4%	7 2.6%	263 98.1%	5 1.9%
Male (n=713)	642 90.0%	71 10.0%	642 94.0%	41 6.0%	642 95.5%	30 4.5%	642 96.8%	21 3.2%	640 97.0%	20 3.0%
Total (n=1000)	905 90.5%	95 9.5%	905 94.5%	53 5.5%	905 95.6%	42 4.4%	905 97.0%	28 3.0%	903 97.3%	25 2.7%
Pearson's Chi-Square	0.606		1.008		0.005		0.218		0.986	
P value	0.436		0.315		0.946		0.641		0.321	

PLP: Palmaris longus present, PLA: Palmaris longus agenesis

ULA: Unilateral agenesis, BLA: Bilateral agenesis

RULA: Right unilateral agenesis, LULA: Left unilateral agenesis

**Table 2.** Correlation analysis of palmaris longus absence with age and sex

	Age	Female Right PL	Female Left PL	Male Right PL	Male Left PL
Age	1				
Female Right PL	0.145*	1			
Female Left PL	0.154**	0.625**	1		
Male Right PL	-0.007	-	-	1	
Male Left PL	-0.003	-	-	0.556**	1

\*. Correlation significant at the 0.05 level (2-tailed).

\*\*. Correlation significant at the 0.01 level (2-tailed).

studies where the presence of the PL can be determined by visualizing the actual muscle. However, the main strengths of this study include the use of various clinical tests to identify the presence of the PL, which increases the possibility that all the tendons crossing the wrist to be detected. The large sample size of this study is also another strength.

### Conclusion

In conclusion, the prevalence of PL agenesis in the Somali population is lower than the reported incidence of 15%, but more significantly higher than some of the other African populations. These findings may be helpful, particularly for the surgeons in the region, for orthopedic and reconstructive surgeries using PL grafting.

**Conflict of Interest:** The authors declare that they have no potential conflict of interest regarding the investigation, authorship, and/or publication of this article.

**Funding sources:** This study received no specific grant from any funding agency in the public, commercial or not-for-profit sectors.

**Ethics Committee Approval:** This study was approved by the Mogadishu Somali Turkish Training and Research Hospital (MSTTRH) Ethics Committee with the Approval No: 10909 and Date: 07/04/2022.

**ORCID and Author contribution:** *H.M (0000-0001-7592-2147), AYM (0000-0002-2416-6262)*. All authors contributed to the research design and interpretation of data and the drafting and revising of the manuscript. The authors read and approved the final submitted manuscript.

**Peer-review:** Externally peer reviewed.

**Acknowledgement:** The authors would like to thank Samet Kose, MD, PhD, for his technical assistance and expertise.

### References

1. Standring S. 2007. Gray's Anatomy. 39th Ed. London: Churchill Livingstone p 995–1027.
2. Mathew AJ, Sukumaran TT, Joseph S. Versatile but temperamental: a morphological study of palmaris longus in the cadaver. *J Clin Diagn Res.* 2015;9(2):AC01-3. doi: 10.7860/JCDR/2015/11212.5542.
3. Erić M, Krivokuća D, Savović S, Leksan I, Vucinić N. Prevalence of the palmaris longus through clinical evaluation. *Surg Radiol Anat.* 2010;32(4):357-61. doi:10.1007/s00276-009-0573-0.
4. Ioannis D, Anastasios K, Konstantinos N, Lazaros K, Georgios N. Palmaris longus muscle's prevalence in different nations and interesting anatomical variations: Review of the literature. *J Clin Med Res.* 2015;7(11):825-30. doi:10.14740/jocmr2243w.
5. Johnson CC, Zusstone E, Miller TT, Nwawka OK, Lee SK, Wolfe SW. Clinical tests for assessing the presence and quality of the palmaris longus tendon: diagnostic accuracy of examination compared with ultrasound. *J Hand Surg Eur Vol.* 2020;45(3):292-8. doi: 10.1177/1753193419895160.
6. Holzgreffe RE, Anastasio AT, Farley KX, Daly CA, Mason AR, Gottschalk MB. Detection of the palmaris longus tendon: physical examination versus sonography. *J Hand Surg Eur Vol.* 2019;44(8):800-4. doi: 10.1177/1753193419863412.
7. Ahn DS, Yoon ES, Koo SH, Park SH. A prospective study of the anatomic variations of the median nerve in the carpal tunnel in Asians. *Ann Plast Surg.* 2000;44(3):282-7. doi: 10.1097/0000637-200044030-00006.
8. Ceyhan O, Mavt A. Distribution of agenesis of palmaris longus muscle in 12 to 18 years old age groups. *Indian J Med Sci.* 1997;51(5):156-60. PMID: 9355719.
9. Potu BK, Alnaggar AA, Fatima A, Salem AH, Fadel RA. Physical and ultrasonographic examination of palmaris longus tendon in the Arabian Gulf Region. *Eur J Anat.* 2021;25(4):397-406.
10. Pękala PA, Henry BM, Pękala JR, Skinningsrud B, Walocha JA, Bonczar M, et al. Congenital absence of the palmaris longus muscle: A meta-analysis comparing cadaveric and functional studies. *J Plast Reconstr Aesthet Surg.* 2017;70(12):1715-24. doi: 10.1016/j.bjps.2017.08.002.
11. Andring N, Kennedy SA, Iannuzzi NP. Anomalous Forearm Muscles and Their Clinical Relevance. *J Hand Surg Am.* 2018;43(5):455-63. doi: 10.1016/j.jhsa.2018.02.028.
12. Schaeffer JP. On the variations of the palmaris longus muscle. *Anat Rec.* 1909;3:275-8.
13. Thompson NW, Mockford BJ, Rasheed T, Herbert KJ. Functional absence of flexor digitorum superficialis to the little finger and absence of palmaris longus--is there a link? *J Hand Surg Br.* 2002;27(5):433-4. doi: 10.1054/jhsb.2002.0797.

14. Kumar, Pramod. Alternative Tests To Demonstrate The Presence Of Palmaris Longus. *Plastic And Reconstructive Surgery* 114(4):P 71e-72e, September 15, 2004.
15. Pushpakumar SB, Hanson RP, Carroll S. The 'two finger' sign. Clinical examination of palmaris longus (PL) tendon. *Br J Plast Surg.* 2004;57(2):184-5. doi: 10.1016/j.bjps.2003.11.024.
16. Osonuga A, Mahama HM, Brown AA, Osonuga OA, Serbeh G, Harding AN, et al. The Prevalence of Palmaris longus agenesis among the Ghanaian population. *Asian Pacific Journal of Tropical Disease.* 2012 Jan 1;2:S887-9. doi: 10.1016/S2222-1808(12)60286-2.
17. Kigera JW, Mukwaya S. Frequency of agenesis Palmaris longus through clinical examination--an East African study. *PLoS One.* 2011;6(12):e28997. doi: 10.1371/journal.pone.0028997.
18. Mbaka GO, Ejiwunmi AB. Prevalence of palmaris longus absence--a study in the Yoruba population. *Ulster Med J.* 2009;78(2):90-3. PMID: 19568443.
19. Sadacharan CM, Packiriswamy V. Clinical Assessment of Absence Of The Palmaris Longus Muscle In African Antiguan Population. *Ethioph Med J.* 2022;60(2):101-8
20. Gangata H. The clinical surface anatomy anomalies of the palmaris longus muscle in the Black African population of Zimbabwe and a proposed new testing technique. *Clin Anat.* 2009;22(2):230-5. doi: 10.1002/ca.20751.
21. Berhe T, Bekele A. Agenesis of palmaris longus muscle among selected Ethiopian students. *Anat Physiol.* 2014;4(2):1-5. doi: 10.4172/2161-0940.1000136.
22. Venter G, Van Schoor AN, Bosman MC. Degenerative trends of the palmaris longus muscle in a South African population. *Clin Anat.* 2014;27(2):222-6. doi: 10.1002/ca.22226.
23. Venkatapathy S, Bhargavan R. Clinical Assessment of Existence of Palmaris Longus Muscle among South Indian Population. *J Hand Surg Asian Pac Vol.* 2020;25(2):137-142. doi: 10.1142/S2424835520500149.