



## Cardiotoxic Effect of Fenamiphos and Protective Role of Naringenin in Rats

Gökçe Ceren BOYA<sup>1</sup>, Fatma Gökçe APAYDIN<sup>2\*</sup>

<sup>1</sup>Gazi University, Graduate School of Natural and Applied Sciences, Department of Biology, 06500, Ankara, Türkiye

<sup>2</sup>Gazi University, Faculty of Science, Department of Biology, 06500, Ankara, Türkiye

### Abstract

Fenamiphos is a broad-spectrum organophosphate insecticide. It is used in agriculture to control soil nematodes in several crops like peanuts, tomatoes, ginger, as well as in pineapples, cotton in worldwide. Naringenin is one of the flavonoids and was found to display strong anti-inflammatory and antioxidant effect. In this study, we investigated how naringenin had protective effects on the damaged rat heart tissue caused by fenamiphos. In the study, experimental rats were organized into four equal groups. These; control, naringenin, fenamiphos and fenamiphos plus naringenin. The chemicals were given to the rats by orally during for 28 days. After 4th week, malondialdehyde (MDA) levels and antioxidant enzyme activities (SOD, CAT, GPx and GST) in rat heart tissues were investigated spectrophotometrically by various methods. Also, histopathological changes were analysed by light microscope. Any important changes were observed between control and naringenin treated groups. End of the experimental timeline, fenamiphos caused increasing the levels of MDA while a decrease in antioxidant enzyme activities were detected in comparison with the control animals. In addition, many pathological changes were observed in fenamiphos treated group. Fewer pathological changes and less oxidative damage were detected in the group in which fenamiphos and naringenin were administered together. In the study it is observed that fenamiphos caused oxidative stress and histopathological changes in rat heart tissue, naringenin treatment reduced this toxicity.

**Keywords:** Fenamiphos, Naringenin, Heart, Oxidative stress, Histopathology

### 1. INTRODUCTION

Pesticides are known as important environmental pollutants to which we are exposed in different ways. They are very harmful to living organisms in the soil, water and induced various abnormalities in plants [1]. It has been known that pesticide exposure caused oxidative damages in many living organisms, leading to disruption of the cellular membrane structure, mutations, inflammations, and several toxic effects on metabolism [2]. Organophosphates (Ops) are a class of that are widely used in agricultural areas. Organophosphate compound residues or metabolites have been considerably founding in the vegetable fruit products and also soil [3]. It has been known that Ops caused inhibitions of blood and tissues acetylcholinesterase (AChE) activity in many organisms [4,5].

Fenamiphos (ethyl 4-methylthio-m-tolyl isopropylphosphoramidate-FNP) is a compound used in many agricultural products and agricultural areas for nematode control [6]. It is known to be highly soluble in water in terms of chemical properties [6]. It is a colourless, waxy, solid organophosphorus pesticide. It is known to rapidly decompose into metabolites in soil [7].

Reactive oxygen species (ROS) are extremely toxic compounds that occur during normal biochemical reactions in cells [3]. ROS compounds can oxidize macromolecules such as lipids, proteins, and nucleic acids. Especially unsaturated fatty acids in cell membranes are sensitive to oxidation and their oxidation initiates lipid peroxidation chain reactions. As a result of lipid peroxidation, lipid peroxides and other intermediates are formed, and the most common of these products, which affects the properties and physiological functions of cell membranes, is malondialdehyde (MDA). Antioxidant enzymes are responsible for the first line of cellular defense system against oxidative agents by suppressing the increase of ROS [8].

Phenolic compounds are known to be a secondary metabolite found in large amounts in plants. They protect the plant against insect and animal pests. Phenolic compounds are divided into two main groups as phenolic acids and flavonoids. Due to their structural differences, there are lots of different phenolic compounds in plants and the products obtained from them. Phenolic compounds also show natural antioxidant properties. By stopping or preventing the reactions caused by free radicals, they prevent the formation of

many diseases such as cancer, heart disease and lung diseases [9–11]. Naringenin (NAR) is a compound that has been accepted as a pharmacologically potential antioxidant and has anti-atherogenic, anti-carcinogenic, anti-mutagenic, anti-inflammatory, hepatoprotective and nephroprotective activities. It has a potential protection role properties of reactive oxygen species and it used for many therapeutic effect experiments [12,13].

The aim of this study is to investigate the protective effect of naringenin which has antioxidant properties, on the effect of FNP, which is widely used, on the lung tissue of rats. For this purpose, the histopathological effect of FNP in the heart tissue of rats, antioxidant enzyme activities [glutathione peroxidase (GPx), superoxide dismutase (SOD), glutathione-S-transferase (GST), catalase (CAT)] and malondialdehyde (MDA) levels possible changes and the protective effects of naringenin on these changes were investigated.

## 2. MATERIAL AND METHODS

### 2.1 Animals and Experimental Protocol

This study, the animal's experimental protocols were used, and Local Animal Ethics Committee of Gazi University approval was obtained (Ethical number: G.U. ET-22.011). Twenty-four male albino Wistar rats (average weight of 250-300 g) were provided from the Laboratory Animals Raising and Experimental Researcher Centre of Gazi University. The standard conditions of a 12-hour light/dark cycle at standard room temperature and 40% relative humidity were maintained, and standard rodent feed and free water were provided for all groups. Firstly, all rats are organized into control (n=6) and experimental groups (n=18). Control rats received only water (1 ml/kg bw. distilled water). FNP treated rats (1/25 LD<sub>50</sub>; 0,76 mg/kg bw.), naringenin treated rats (NAR, 50 mg/kg bw.), and FNP plus NAR treated rats (0,76 mg/kg bw. FNP and 50 mg/kg bw. NAR, respectively) Applications to all groups continued for 28 days by gavage.

### 2.2 Determination of Oxidative Stress Biomarkers

Heart tissues are homogenized using the homogenizer and these homogenates were in accordance with the procedure centrifuged and then separated. Separate homogenates were obtained for MDA and enzyme measurements. and centrifuges were performed according to separate protocols using spectrophotometer. The protein level in the heart was determined for all tissues in accordance with the protocol [14]. Catalase enzyme measurement was analysed in tissue homogenates study in accordance with Aebi's protocol [15]. Also, cellular antioxidants like superoxide dismutase (SOD) [16], glutathione-S-transferase (GST) [17], and glutathione peroxidase (GPx) [18] have been spectrophotometrically studies in homogenized tissues to found cellular oxidative damage markers with different methods in heart tissues. MDA, primarily the product of lipid peroxidation, was measured calorimetrically in all groups [19].

### 2.3 Histopathologic Investigations

After 28 days' protocol, all the treated rats along with the control group rats were sacrificed. Heart tissue sections were fixed in 10% neutral formal fixative solution, and then normal histological tissue procedure was applied. Tissues embedded in paraffin and then cut into 6-7 µm-thickness sections and sections were taken from a paraffin water bath using a slide. Hematoxylin and eosin were used to stain the sections of the tissues and observed using the light microscope at 400X magnification for any cellular changes.

### 2.4 Statistical Analyses

GraphPad prism version 8 and SPSS program version 22 were used for all statistical protocols. Data were detected using ANOVA and Tukey tests and expressed as ± SD.  $p < 0.05$  was considered significant.

## 3. RESULTS AND DISCUSSION

### 3.1 Evaluation of Antioxidant Enzyme Activities and Malondialdehyde Levels

According to the results shown in Figures 1–5, there is no important difference between control and NAR groups. We found increased MDA in the hearts in group FNP compared to group control. In heart tissues of FNP and we found a statistically significant decrease in enzyme activities ( $p \leq 0.05$ ). A significant increase was observed in GPx, CAT, GST, and SOD activities at the end of the

experimental period in FNP plus NAR group, compared to FNP group, ( $p \leq 0.05$ ). A significant decrease was observed in MDA levels in FNP plus NAR compared to FNP group ( $p \leq 0.05$ ).

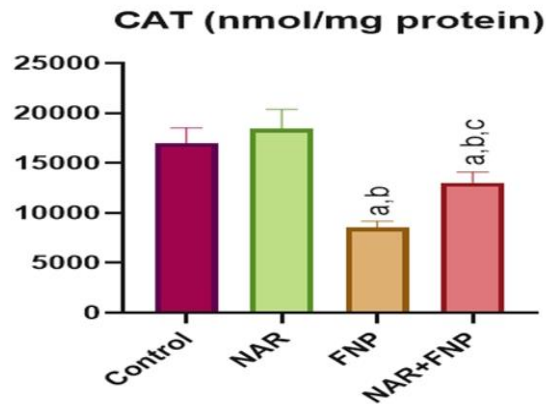


Figure 1. Effects of exposure to fenamiphos and naringenin on the CAT activity of rat heart tissues. <sup>a</sup>Significant difference between control group and other groups, <sup>b</sup>Significant difference between NAR and other groups, <sup>c</sup>Significant difference between FNP and other groups. Significance at  $p < 0.05$

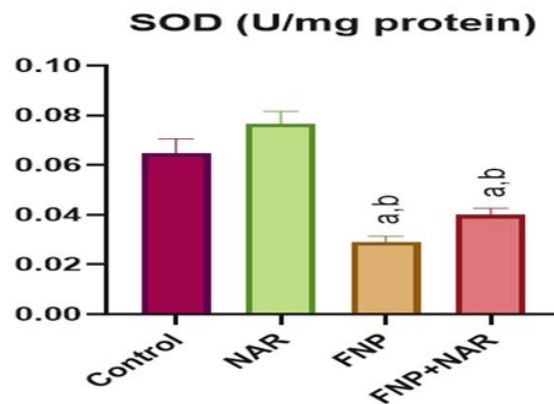


Figure 2. Effects of exposure to fenamiphos and naringenin on the SOD activity of rat heart tissues. <sup>a</sup> Significant difference between control group and other groups, <sup>b</sup> Significant difference between NAR and other groups. Significance at  $p < 0.05$

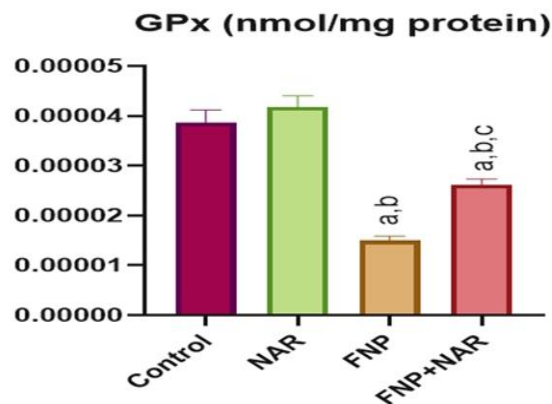


Figure 3. Effects of exposure to fenamiphos and naringenin on the GPx activity of rat heart tissues. <sup>a</sup>Significant difference between control group and other groups., <sup>b</sup>Significant difference between NAR and other groups, <sup>c</sup>Significant difference between FNP and other groups. Significance at  $p < 0.05$

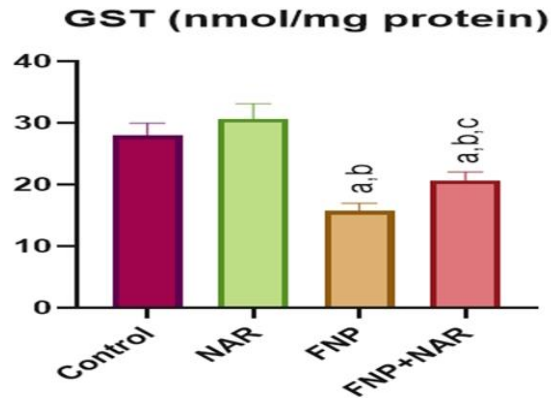


Figure 4. Effects of exposure to fenamiphos and naringenin on the GST activity of rat heart tissues. <sup>a</sup>Significant difference between control group and other groups, <sup>b</sup>Significant difference between NAR and other groups, <sup>c</sup>Significant difference between FNP and other groups. Significance at  $p < 0.05$

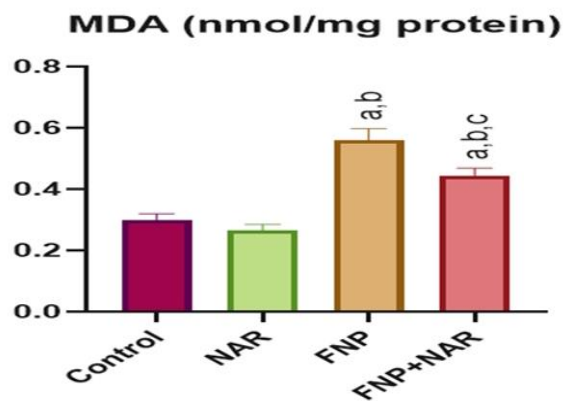


Figure 5. Effects of exposure to fenamiphos and naringenin on the MDA levels of rat heart tissues. <sup>a</sup>Significant difference between control group and other groups, <sup>b</sup>Significant difference between NAR and other groups, <sup>c</sup>Significant difference between FNP and other groups. Significance at  $p < 0.05$

### 3.2 Effects of FNP and NAR on Histopathological Findings

The heart in the control and NAR, we showed normal myocardial cells (Figure 6A-B). degeneration in myocardial cells, congestion of blood vessels and edema were seen in heart tissues of the FNP (Figure 6C). In the heart tissues of FNP plus NAR, degeneration myocardial cells, congestion of blood vessels were determined in microscopic studies (Figure 6D).



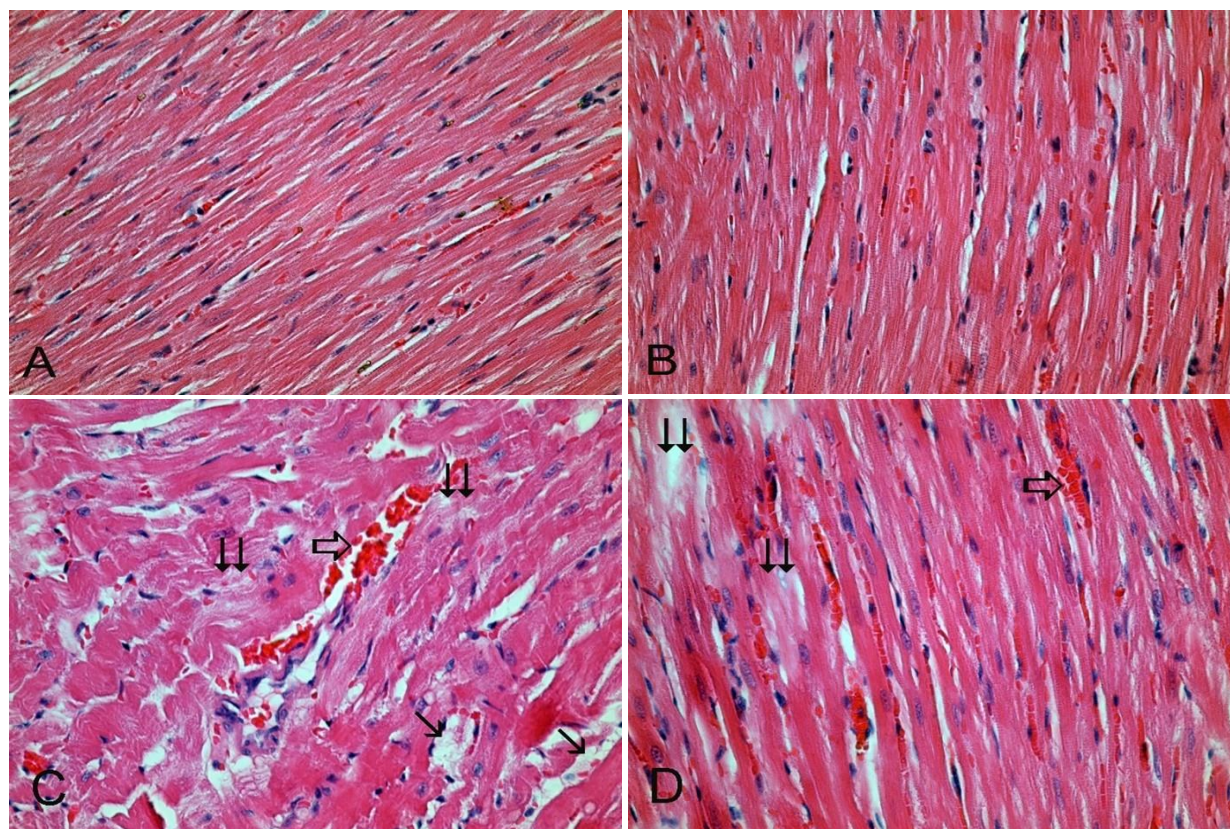


Figure 6. Histopathological appearance of hearts among groups. A. Normal tissue architecture in control group (H & E, 400 X), B. Treated rats with naringenin, normal heart histology (H & E, 400 X), C. Treated rats with fenamiphos, degeneration in myocardial cells ( $\Downarrow$ ), congestion of blood vessels ( $\Rightarrow$ ) and edema (H & E, 400 X), D. Treated rats with fenamiphos and naringenin degeneration in myocardial cells ( $\Downarrow$ ), congestion of blood vessels ( $\Rightarrow$ ) (H & E, 400 X)

Many chemicals, including pesticides, cause pathological changes and oxidative damage in various tissues of experimental animals [20–23]. Studies have reported that free radicals play a role in cardiac toxicity [24]. It is known that pesticides exposure may induce histopathological changes in cardiac [25]. Similarly, we found that many pathological changes in heart tissues in FNP treated rats.

Exposure to FNP may occur through different ways like absorption from dermatological way, ingestion of contaminated foods or water, and respiratory tract contaminated with FNP residues [26]. Oral lethal dose of FNP in rats has been reported as  $LD_{50}$  dose of 19 mg/kg [27]. In our study, we applied that  $1/25 LD_{50}$  dose and no rat mortality was observed during the experimental studies.

Our findings are in concordance with previous studies showing the effect of pesticides on oxidative damages [23]. It is known that several cellular pathways have been shown to be involved in pesticides cardiotoxicity. Especially organophosphates cause induces oxidative stress in a dose-related mode. They alter lipid metabolism and increases cytotoxicity enzymes activity [28].

Parameters measured in this study, MDA levels, SOD, CAT, GPX and GST enzymes are enzymes that work together in the cell. GST is a potent part of the intracellular non-enzymatic antioxidant system. It effectively scavenges free radicals. It responsible also as a cofactor for GSH peroxidase in the reduction of hydrogen peroxide [29]. In cell, SOD converts superoxide anion to hydrogen peroxide, while CAT and GPx convert hydrogen peroxide into molecular oxygen and water [30].

The normalization of LPO and other parameters following NAR treatment is very likely due to its anti-peroxidative and anti-inflammatory properties, as has been shown previously [31]. NAR may have been protective against heart damage due to these cellular protective properties, including those due to oxidative injuries in our study.

#### 4. CONCLUSION

In conclusion, FNP can alter heart cellular structure and then an increase in oxidative parameters, and histopathological damage to myocardial cells. Clearly, we can say that NAR displays antioxidant role via oxidative stress and tissues damages suppression against FNP-induced cardiotoxicity. The application of NAR via their therapeutic effects via antioxidant properties supplied to be reducing the FNP-induced this toxicity.

#### ACKNOWLEDGEMENT

We would like to thank Prof. Dr. Yusuf Kalender, Dr. Çağlar Adıgüzel and Dr. Hatice Karaboduk for helping us with our laboratory studies.

#### AUTHOR'S CONTRIBUTIONS

The research is the master's thesis of Gökçe Ceren Boya. The authors contributed equally.

#### CONFLICTS OF INTEREST

The authors declare no competing interests.

#### RESEARCH AND PUBLICATION ETHICS

The author declares that this study complies with Research and Publication Ethics.

#### REFERENCES

- [1] Z. Laghari, N. Manawar, S. Akash, A. Saddique, M. Malik, I. Basit, H. Rafeeq, and N. Fatima, "Role of Chlorpyrifos in Experimentally Based Rats," *Haya Saudi J. Biol. Sci.*, vol. 5, no. 10, pp. 220–225, Oct. 2020, doi: 10.36348/sjls.2020.v05i10.005.
- [2] X. Zeng, Z. Du, X. Ding, and W. Jiang, "Protective Effects of Dietary Flavonoids Against Pesticide-Induced Toxicity: A Review," *Trends Food Sci. Technol.*, vol. 109, pp. 271–279, Jan. 2021, doi: 10.1016/j.tifs.2021.01.046.
- [3] H. Uzunbayir and F. G. Apaydin, "Protective Role of Ferulic Acid on Testis-Histoarchitecture and Oxidative Damages Induced by Dimethoate in Rats," *Braz. Arch. Biol. Technol.*, vol. 64, pp. 21210300 Sep. 2021, doi: 10.1590/1678-4324-2021210300.
- [4] R. T. Alam, T. S. Imam, A. M. A. Abo-Elmaaty, and A. H. Arisha, "Amelioration of Fenitrothion Induced Oxidative DNA Damage and Inactivation of Caspase-3 in the Brain and Spleen Tissues of Male Rats by N-acetylcysteine," *Life Sci.*, vol. 231, pp. 116534, Aug. 2019, doi: 10.1016/j.lfs.2019.06.009.
- [5] A. A. A. Galal, R. A. Ramadan, M. A. A. Metwally, and S. M. A. El-Sheikh, "Protective Effect of N-acetylcysteine on Fenitrothion-induced Toxicity: The Antioxidant Status and Metabolizing Enzymes Expression in Rats," *Ecotoxicol. Environ. Saf.*, vol. 171, pp. 502–510, Jan. 2019, doi: 10.1016/j.ecoenv.2019.01.004.
- [6] A. A. Romeh and M. Y. Hendawi, "Biochemical Interactions between Glycine max L. Silicon Dioxide (SiO<sub>2</sub>) and Plant Growth-promoting Bacteria (PGPR) for Improving Phytoremediation of Soil Contaminated with Fenamiphos and its Degradation Product," *Pestic. Biochem. Phys.*, vol. 142, pp. 32–43, Oct. 2017, doi: 10.1016/j.pestbp.2017.01.001.
- [7] B. K. Singh, A. Walker, and D. J. Wright, "Bioremedial Potential of Fenamiphos and Chlorpyrifos Degrading Isolates: Influence of Different Environmental Conditions," *Soil Biol. Biochem.*, vol. 38, no. 9, pp. 2682–2693, Apr. 2006, doi: 10.1016/j.soilbio.2006.04.019.
- [8] E. Birben, U. M. Sahiner, C. Sackesen, S. Erzurum, and O. Kalayci, "Oxidative Stress and Antioxidant Defense," *WAOjournal.*, vol. 5, no. 1, pp. 9–19, Jan. 2012, doi: 10.1097/WOX.0b013e3182439613.
- [9] C. W. I. Haminiuk, G. M. Maciel, M. S. V. Plata-Oviedo, and R. M. Peralta, "Phenolic Compounds in Fruits – An Overview," *Int. J. Food Sci.*, vol. 47, no. 10, pp. 2023–2044, Apr. 2012, doi: 10.1111/j.1365-2621.2012.03067.x.
- [10] X. Zhang, M. Li, H. Wu, W. Fan, J. Zhang, W.i Su, Y. Wang, and P. Li, "Naringenin Attenuates Inflammation, Apoptosis, and Ferroptosis in Silver Nanoparticle-induced Lung Injury Through a Mechanism Associated with Nrf2/HO-1 axis: In Vitro and In Vivo Studies," *Life Sci.*, vol. 311, pp. 121127, Dec. 2022, doi: 10.1016/j.lfs.2022.121127.

- [11] L. Meng, H. Ma, H. Guo, Q. Kong, and Y. Zhang, "The Cardioprotective Effect of Naringenin Against Ischemia/ Reperfusion Injury Through Activation of ATP-sensitive Potassium Channel in Rat," *Can. J. Physiol. Pharmacol.*, vol. 94, no. 9, pp. 973–978, Apr. 2016, doi: 10.1139/cjpp-2016-0008.
- [12] M. Erişir, F. Benzer, A. Özkaya, and Ü. Dağ, "Kurşun Uygulanan Ratların Bazı Dokularında (Kalp, Akciğer, Beyin, Dalak, Kas) Oksidatif Stress Üzerine Naringenin Etkisi," *Atatürk Üniv. Vet. Bil.*, vol. 13, no. 1, pp. 34–41, Apr. 2018, doi: 10.17094/ataunivbd.417125.
- [13] M. A. Alam, N. Subhan, M. Rahman, S. J. Uddin, H. M. Reza, and S. D. Sarker, "Effect of Citrus Flavonoids, Naringin and Naringenin, on Metabolic Syndrome and Their Mechanisms of Action 1,2," *Adv. Nutr.*, vol. 5, no. 4, pp. 404–417, Jul. 2014, doi: 10.3945/an.113.005603.
- [14] O. H. Lowry, N. J. Rosebrough, A. L. Farr, and R. J. Randall, "Protein Measurement with the Folin Phenol Reagent," *J. Biol. Chem.*, vol. 193, no. 1, pp. 265–275, Nov. 1951, doi: 10.1016/S0021-9258(19)52451-6.
- [15] H. Aebi, "Catalase in Vitro," *Meth. Enzymol.*, vol. 105, pp. 121–126, 1984, doi: 10.1016/s0076-6879(84)05016-3.
- [16] S. Marklund and G. Marklund, "Involvement of the Superoxide Anion Radical in the Autoxidation of Pyrogallol and A Convenient Assay for Superoxide Dismutase," *Eur. J. Biochem.*, vol. 47, no. 3, pp. 469–474, Sep. 1974, doi: 10.1111/j.1432-1033.1974.tb03714.x.
- [17] W. H. Habig, M. J. Pabst, and W. B. Jakoby, "Glutathione-S-Transferases: The First Enzymatic Step in Mercapturic Acid Formation," *J. Biol. Chem.*, vol. 249, no. 22, pp. 7130–7139, Nov. 1974, doi: 10.1016/S0021-9258(19)42083-8.
- [18] D. E. Paglia and W. N. Valentine, "Studies on the Quantative and Qualitative Characterization of Erythrocyte Glutathione Peroxidase," *J. Lab. Med.*, vol. 70, no. 1, pp. 158–169, Jul. 1967.
- [19] H. Ohkawa, N. Ohishi, and K. Yagi, "Assay for Lipid Peroxides in Animal Tissues by Thiobarbituric Acid Reaction," *Anal. Biochem.*, vol. 95, no. 2, pp. 351–358, Jun. 1979, doi: 10.1016/0003-2697(79)90738-3.
- [20] E. Atabay and Y. Kalender, "Protective Effect of Taurine and Curcumin on Lung Toxicity of Bisphenol A in Rats," *Bozok J Sci.*, vol. 1, no. 1, pp. 16–22, Apr. 2023.
- [21] H. Baş, F. G. Apaydin, S. Kalender, and Y. Kalender, "Lead Nitrate and Cadmium Chloride Induced Hepatotoxicity and Nephrotoxicity: Protective Effects of Sesamol on Biochemical Indices and Pathological Changes," *J. Food Biochem.*, vol. 45, no. 7, pp. 13769, May. 2021, doi: 10.1111/jfbc.13769.
- [22] S. Kalender, F. G. Apaydin, and Y. Kalender, "Testicular Toxicity of Orally Administrated Bisphenol A in Rats and Protective Role of Taurine and Curcumin," *Pak. J. Pharm. Sci.*, vol. 32, no. 3, pp. 1043–1047, May. 2019.
- [23] F. G. Apaydin, S. Kalender, and Y. Kalender, "Subacute Exposure to Dimethoate Induces Hepatotoxic and Nephrotoxic Effects on Male Rats: Ameliorative Effects of Ferulic Acid," *Indian J. Exp. Biol.*, no. 61, no. 1, pp. 51–58, Jan. 2023, doi: 10.56042/ijeb.v61i01.49688.
- [24] İ. Aktaş, Ö. Özmen, H. Tutun, A. Yalçın, and A. Türk, "Artemisinin Attenuates Doxorubicin Induced Cardiotoxicity and Hepatotoxicity in Rats," *Biotech. Histochem.*, vol. 95, no. 2, pp. 121–128, Sep. 2019, doi: 10.1080/10520295.2019.1647457.
- [25] E. Akbel, D. Arslan-Acaroz, H. H. Demirel, I. Kucukkurt, and S. Ince, "The Subchronic Exposure to Malathion, an Organophosphate Pesticide, Causes Lipid Peroxidation, Oxidative Stress, and Tissue Damage in Rats: The Protective Role of Resveratrol," *Toxicol. Res.*, vol. 7, no. 3, pp. 503–512, Apr. 2018, doi: 10.1039/c8tx00030a.
- [26] B. Qader, M. G. Baron, I. Hussain, R. P. Johnson, and J. Gonzalez-Rodriguez, "Electrochemical Determination of the Organophosphate Compound Fenamiphos and its Main Metabolite, Fenamiphos Sulfoxide," *Monatsh. Chem.*, vol. 150, no. 3, pp. 411–417, Jan. 2019, doi: 10.1007/s00706-018-2334-4.
- [27] B. K. Singh, A. Walker, and D. J. Wright, "Bioremedial Potential of Fenamiphos and Chlorpyrifos Degrading Isolates: Influence of Different Environmental Conditions," *Soil Biol. Biochem.*, vol. 38, no. 9, pp. 2682–2693, Sept. 2006, doi: 10.1016/j.soilbio.2006.04.019.
- [28] N. Georgiadis, K. Tsarouha, C. Tsitsimpikou, A. Vardavas, R. Rezaee, I. Germanakis, A. Tsatsakis, D. Stagos, and D. Kouretas, "Pesticides and Cardiotoxicity. Where Do We Stand?," *Toxicol. Appl. Pharmacol.*, vol. 353, pp. 1-14, Aug. 2018, doi: 10.1016/j.taap.2018.06.004.
- [29] A. Goel, V. Dani, and D. K. Dhawan, "Protective Effects of Zinc on Lipid Peroxidation, Antioxidant Enzymes and Hepatic Histoarchitecture in Chlorpyrifos-induced Toxicity," *Chem. Biol. Interact.*, vol. 156, no. 2–3, pp. 131–140, Oct. 2005, doi: 10.1016/j.cbi.2005.08.004.

- [30] Y. B. Othmène, H. Hamdi, I. Amara, and S. Abid-Essefi, "Tebuconazole Induced Oxidative Stress and Histopathological Alterations in Adult Rat Heart," *Pestic. Biochem. Physiol.*, vol. 170, pp. 104671, Nov. 2020, doi: 10.1016/j.pestbp.2020.104671.
- [31] R. H. Moghaddam, Z. Samimi, S. Z. Moradi, P. J. Little, S. Xu, and M. H. Farzaei, "Naringenin and Naringin in Cardiovascular Disease Prevention: A Preclinical Review," *Eur. J. Pharmacol.*, vol. 887, pp. 173535, Nov. 2020, doi: 10.1016/j.ejphar.2020.173535.