



Comparison of Results of the sIPOM and the IPOM-Plus Techniques for Small and Medium-Sized Primary Midline Abdominal Wall Hernias

Küçük ve Orta Büyüklükteki Primer Ortahat Karın Duvarı Fıtıklarında sIPOM ve IPOM-Plus Tekniklerinin Sonuçlarının Karşılaştırılması

Halil Afşin Taşdelen

Trabzon Kanuni Training and Research Hospital, Department of General Surgery, Trabzon, Turkey

Abstract

Aims: To compare the results of the standard intraperitoneal onlay mesh (sIPOM) and intraperitoneal onlay mesh-plus (IPOM-Plus) techniques for the repair of small and medium-sized primary midline abdominal wall hernias (PMAWHs).

Material and Method: A prospectively documented data of 82 patients who underwent the sIPOM and IPOM-Plus approach between January 2016 and December 2021 was retrospectively evaluated. Forty-one patients with PMAWH repaired with sIPOM (18) and IPOM-Plus (23) were included in the study. Median follow-up for the sIPOM and IPOM-Plus was 73 and 51 months (mean 73.83 ± 7.81 vs. 47.43 ± 19.22), respectively.

Results: Both groups had no difference in demographics, comorbidities, and smoking habits. The mesh area (MA) and the mesh-to-defect ratio (MDR) were not significant ($p=0.083$ and $p=0.30$, respectively); however, the defect area (DA) was higher in the sIPOM group ($p=0.005$). The IPOM-Plus group had a longer operative time and length of hospital stay (LOHS) and higher early postoperative pain than the IPOM group ($p=0.002$, $p=0.049$ and $p<0.001$). Seroma developed in 4 (22.2%) and 2 (8.6%) patients in the sIPOM and IPOM-Plus groups, respectively, with no significant difference ($p=0.477$). There was two (11.1%) recurrence in the sIPOM group, while no recurrences were observed in the IPOM-Plus group ($p=0.196$).

Conclusion: The IPOM-Plus approach has similar seroma and recurrence rates to sIPOM in small and medium-sized PMAWH, but with higher postoperative pain and longer LOHS. More randomized controlled studies (RCTs), meta-analyses, and multi-center studies with large samples are needed for more valuable results.

Keywords: sIPOM, IPOM-Plus, Primary abdominal wall hernia, Laparoscopic hernia repair

Öz

Amaç: Küçük ve orta büyüklükteki primer orta hat karın duvarı fıtıklarının (PMAWH) onarımında standart intraperitoneal onlay mesh (sIPOM) ve intraperitoneal onlay mesh-plus (IPOM-Plus) tekniklerinin sonuçlarının karşılaştırılması amaçlandı.

Gereç ve Yöntem: Ocak 2016 ile Aralık 2021 arasında sIPOM ve IPOM-Plus yaklaşımı uygulanan 82 hastanın prospektif olarak belgelenmiş verileri retrospektif olarak değerlendirildi. Çalışmaya sIPOM (18) ve IPOM-Plus (23) ile onarılan 41 PMAWH hastası dahil edildi. sIPOM ve IPOM-Plus için ortalama takip süresi sırasıyla 73 ve 51 (ortalama 73.83 ± 7.81 vs. 47.43 ± 19.22) aydı.

Bulgular: Her iki grupta demografik özellikler, eşlik eden hastalıklar ve sigara içme alışkanlığı açısından fark yoktu. Mesh alanı (MA) ve mesh-defekt oranı (MDR) istatistiksel olarak anlamlı değildi (sırasıyla $p=0,083$ ve $p=0,30$); ancak defekt alanı (DA) sIPOM grubunda daha yüksekti ($p=0,005$). IPOM-Plus grubunda ameliyat süresi ve hastanede kalış süresi (LOHS) daha uzundu ve erken ameliyat sonrası ağrı daha fazlaydı ($p=0,002$, $p=0,049$, $p<0,001$). sIPOM ve IPOM-Plus gruplarında sırasıyla 4 (%22,2) ve 2 (%8,6) hastada seroma gelişti, anlamlı fark yoktu ($p=0,477$). sIPOM grubunda iki (%11,1) nüks görülürken, IPOM-Plus grubunda nüks gözlenmedi ($p=0,196$).

Sonuç: IPOM-Plus yaklaşımı, küçük ve orta büyüklükteki PMAWH'de sIPOM ile benzer seroma ve nüks oranlarına sahiptir, ancak ameliyat sonrası ağrı daha yüksek ve LOHS daha uzundur. Daha değerli sonuçlar için daha fazla randomize kontrollü çalışmaya (RKÇ), meta-analizlere ve geniş örneklemli çok merkezli vaka kontrol çalışmalarına ihtiyaç vardır.

Anahtar kelimeler: sIPOM, IPOM-Plus, Primer karın duvarı fıtığı, Laparoskopik fıtık tamiri



INTRODUCTION

Until approximately three decades ago, the repair of abdominal wall hernias was executed with open techniques. Following the initial introduction of the laparoscopic ventral and incisional abdominal wall hernia repair (LVIHR) technique in 1993, it began to receive recognition and approval within the surgical community.^[1,2] The paramount element of this acceptance is that laparoscopic repair manifests significantly reduced incidences of surgical site complications despite presenting recurrence rates similar to open repairs.^[3] The LVIHR technique involves using a large mesh to bridge hernia defects. The mesh is anchored to the abdominal wall with transfascial sutures and permanent staples. Various techniques have been developed for closing defects over the years to prevent issues like seroma formation, postoperative bulging, and recurrences caused by incomplete anatomical restoration of the abdominal wall with bridging.^[4-7] As per the IEHS (International Endohernia Society) Guideline, the LVIHR technique accompanied by defect closure has been designated as intraperitoneal onlay mesh-plus (IPOM-plus), and the conventional LVHIR technique has been defined as standard intraperitoneal onlay mesh (sIPOM).^[8,9]

Incisional and primary abdominal wall hernias (AWHs) exhibit distinctions in terms of underlying causes, patient characteristics, outcomes of surgical interventions, and potential complications. When writing a scientific report about abdominal wall hernias, it is recommended to analyze and report the results of incisional and primary hernia repairs as separate entities.^[10-12] The EHS reported distinct classifications for incisional and primary AWHs.^[13] This study aims to present a comparison of the outcomes of the sIPOM and the IPOM-Plus techniques in primary midline abdominal wall hernia repairs. All surgical procedures were performed by the same surgeon. The main hypothesis of this study was that in the IPOM-Plus technique, adding the closing of the defects could decrease the seroma formation and recurrence rates, but the postoperative pain could increase due to the tension on the midline.

MATERIAL AND METHOD

A prospectively documented data emanating from the primary and incisional AWH repairs with laparoscopic IPOM-Plus on 64 patients or sIPOM technique on 18 patients, which were performed by the same surgeon within the timeframe spanning from January 2016 to December 2021 at the Trabzon Kanuni Training and Research Hospital General Surgery Clinic, were retrospectively evaluated. The study protocol received endorsement from the ethics committee of Trabzon Kanuni Training and Research Hospital (11384-2022/22).

Patients over 18 years of age with midline primary ventral hernia and operated with laparoscopic IPOM-Plus or sIPOM technique were included in the study. Exclusion criteria: Ventral and incisional hernia repairs with open or other laparoscopic procedures, incisional hernia repairs, primary lateral AWH repairs, emergency cases, hernias complicated with fistula

formation and surgical site infection, and loss of domain (LOD) were determined. All patients underwent preoperative physical examination and routine laboratory tests. In addition, non-contrast abdominal computed tomography (CT) was performed in all cases to evaluate the location and size of AWH defects according to the European Hernia Society Classification. CT-defined features of hernia defects were also measured and verified during the operation. Demographic characteristics of the patients (age, gender, body mass index (BMI), history of previous hernia surgery, comorbidities, smoking habit), American Society of Anesthesiology (ASA) scores, surgical technique, operation times, hernia defect characteristics and mesh area, the type of mesh, mesh fixation methods, complications during and after the operation, postoperative length of hospital stay (LOHS), morbidity, recurrence and reoperations, pain scores (Visual Analogue Scale – VAS, ranging from 0 to 10) were evaluated retrospectively. All patients were examined on the 10th postoperative day, in the first, third, and sixth months, and at the end of the first year. Abdominal CT was included in the first-year controls. Individuals who failed to participate in their clinical appointments were contacted by telephone.

Outcomes of the IPOM-Plus and the sIPOM techniques for PMAWHs were compared. Statistical calculations were made using the SPSS22 program. Chi-square or Fischer's exact test was used for categorical data (presented as n (%)), and the Student-t test or Manny-Whitney U test was used for continuous data (presented as the mean±SD (standard deviation)). A $p < 0.05$ value was considered as significant.

Surgical Technique

The IPOM-Plus and sIPOM techniques share identical steps except for the closure of the defect. A single intravenous dose of 1 g cefazoline was administered to all patients roughly thirty minutes prior to the surgical procedure. The patients were positioned on the operating table in the supine position, with their arms secured on both sides. Following the administration of general anesthesia, carbon dioxide insufflation was initiated by introducing a Veress needle through Palmer's point, progressing until an intra-abdominal pressure of up to 12 mmHg was achieved. Next, the abdominal cavity was entered with the help of an optical trocar through an incision made on the left mid-axillary line, usually at the level of the umbilicus. Two 5 mm working ports were inserted approximately 5 cm above and below the optical trocar. The trocar layout was chosen flexibly according to the location and size of the defects. All trocars were placed lateral to the linea semilunaris (**Figure 1**). A 5 mm working port was entered from the opposite side if there was difficulty on the same side while fixing the mesh. After intra-abdominal exploration, all omental and intestinal adhesions to the anterior abdominal wall, if any, were separated with sharp dissections. The use of energy devices was avoided to prevent thermal injury during adhesiolysis. However, energy devices were kept ready for use when necessary. The omentum or intestines within the hernia

defects were separated with sharp dissection (**Figure 2a**). A plastic ruler was sent into the abdomen, and measurements were made to determine the defect's width and adequate mesh size. The falciform and umbilical ligaments were dissected and separated from the abdominal wall for proper laying and fixation of the mesh (**Figure 2b**). A composite mesh was sent into the abdomen through the optical trocar. Usually, two, sometimes four, cardinal transfascial sutures were used to attach the mesh to the anterior abdominal wall. Next, the mesh was secured in a double-crown style, using either absorbable or titanium staples, with intervals of approximately 2 centimeters (**Figure 2d**). The intra-abdominal pressure was lowered to 8 mmHg during measurement and fixation of the mesh.

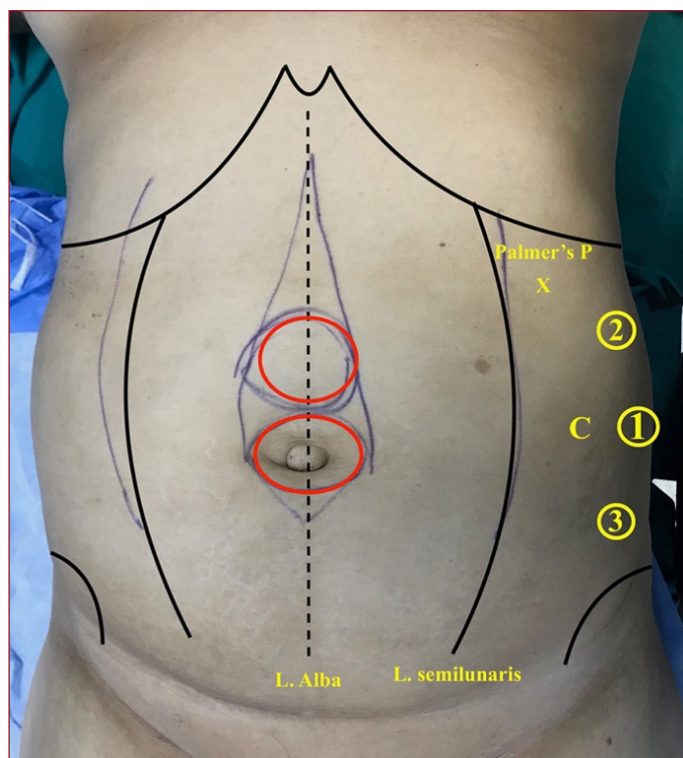


Figure 1 Port placements

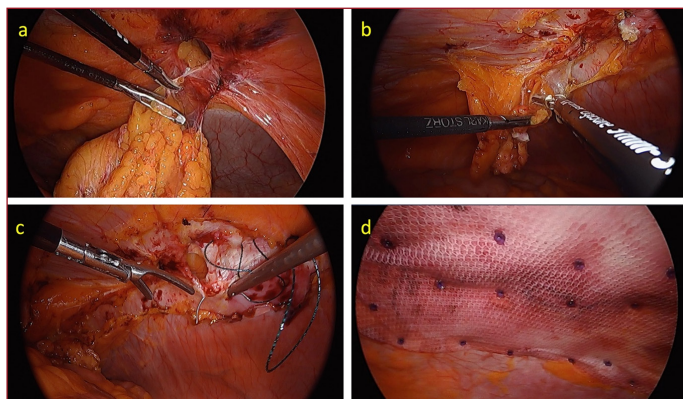


Figure 1 a. Adhesiolysis. b. Separation of the umbilical ligament. c. Closing the defect and plication of linea alba. d. Composite mesh placement with transfascial sutures + double crown style

Various techniques have been described for the closure of the defects in the IPOM-Plus technique. In this study, the defects were closed with extracorporeal interrupted no 0 or no1 polypropylene sutures, usually with the help of the Endoclose™. In some cases, closure of the defect was performed with no1 polydioxanone (PDS) or 0 barbed (V-Loc™ no0, Medtronic) sutures in a continuous fashion. A linea alba plication was added to the technique for a primary midline hernia concomitant with diastasis (**Figure 2c**). The 10 mm trocar site fascia was routinely closed with a single no0 polypropylene suture.

RESULTS

Data prospectively gathered and documented from 82 patients who underwent the IPOM-Plus and sIPOM procedures for ventral and incisional hernia repairs between January 2016 and December 2021 were retrospectively assessed. Forty-one patients operated on with IPOM-Plus for incisional midline or lateral AWHs were excluded from the current study. However, no incisional or lateral hernia cases underwent the sIPOM technique in this cohort. Ultimately, the study included 23 patients for the IPOM-Plus group and 18 for the sIPOM group. For the IPOM-Plus group, the mean follow-up duration was 73.83 ± 7.81 , whereas for the sIPOM group, it was 47.43 ± 19.22 .

Both cohorts exhibited no significant disparities concerning gender, age, Body Mass Index (BMI), American Society of Anesthesiologists (ASA) scores, comorbidities, or smoking habits. Both groups had predominantly female patients (77.8% vs. 65.2%, $p=0.30$), with a mean age of 54.16 ± 11.08 for the sIPOM group and 53.43 ± 9.7 for the IPOM-Plus group ($p=0.82$). The average BMI was 34.40 ± 8.8 for both groups ($p=0.58$), and most patients in both groups had an ASA score of 2 ($p=0.88$). Comorbidities in the sIPOM and IPOM-Plus groups were as follows: hypertension 8 (44.4%) vs. 10 (43.5%), type II diabetes mellitus 4 (22.2%) vs. 6 (26.1%), hyperlipidemia 0 (0.0%) vs. 3 (13%), coronary artery disease (CAD) 3 (16.7%) vs. 2 (8.7%), and chronic obstructive pulmonary disease (COPD) 3 (16.7%) vs. 3 (13%). The number of smoker patients was 4 in each group (22.2% vs. 17.4%, $p=0.71$). The demographic characteristics are presented in **Table 1**.

Intraoperative and postoperative data of the groups are displayed in **Table 2**. The width of the defects was lower than four centimeters for both groups. The sIPOM group had a higher defect area (DA) of $9.16 \text{ cm}^2 \pm 4.42$ compared to the IPOM-Plus group's $6.52 \text{ cm}^2 \pm 3.08$ ($p=0.005$). The sIPOM group's mesh area (MA) was $220.83 \text{ cm}^2 \pm 70.31$, while the IPOM-Plus group had an MA of $185.86 \text{ cm}^2 \pm 63.43$. The mesh-to-defect ratio (MDR) for the sIPOM group was $27.80 \text{ cm}^2 \pm 10.45$, and the IPOM-Plus group's MDR was $33.24 \text{ cm}^2 \pm 16.5$. In both groups, the MA and the MDR were found to be statistically insignificant ($p=0.083$ and $p=0.30$, respectively). In four patients (22.2%) from the sIPOM group and five patients (21.7%) from the IPOM-Plus group, there was concomitant rectus muscle diastasis, but it was not statistically significant ($p=1.0$).

Table 1 Demographic characteristics

	IPOM (n=18)	IPOM-Plus (n=23)	p value
Age (years), mean±SD (min-max)	54.16±11.08 (34-71)	53.43±9.7 (37-70)	0.82
Sex			0.38
Female	14 (77.8%)	15 (65.2%)	
Male	4 (22.2%)	8 (34.8%)	
BMI (kg/m ²), mean±SD (min-max)	34.40±8.8 (23.4-55.8)	34.59±7.5 (22.4-50.5)	0.58
ASA score			0.88
1	4 (22.2%)	5 (21.7%)	
2	9 (50.0%)	11 (47.8%)	
3	5 (27.8%)	7 (30.5%)	
Hypertension	8 (44.4%)	10 (43.5%)	0.95
Diabetes mellitus	4 (22.2%)	6 (26.1%)	1.00
Hyperlipidemia	0 (0.0%)	3 (13.0%)	0.24
CAD	3 (16.7%)	2 (8.7%)	0.63
COPD	3 (16.7%)	3 (13.0%)	1.0
Smoker	4 (22.2%)	4 (17.4%)	0.71

Continuous and categorical variables are shown as the mean±Standard Deviation (SD) and n (%), respectively. BMI Body mass index, ASA American Society of Anesthesiologists, CAD Coronary artery disease, COPD Chronic obstructive pulmonary disease

Table 2 Intraoperative and postoperative data

	IPOM (n=18)	IPOM-Plus (n=23)	p value
The defect area (cm ² , mean±SD min-max)	9.16±4.42 (4-18)	6.52±3.08 (4-16)	0.005
The mesh area (cm ² , mean±SD min-max)	220.83±70.31 (150-300)	185.86±63.43 (150-300)	0.083
Mesh-to-defect ratio (mean±SD min-max)	27.80±10.45 (9.38-50.0)	33.24±16.5 (16.67-75.0)	0.306
Operative time (minutes, mean±SD min-max)	74.16±14.1 (50-100)	94.0±23.9 (55-155)	0.002
Concomitant Diastasis	4 (22.2%)	5 (21.7%)	1.0
LOHS (mean±SD min-max, Median)	3.11±0.90 (2-4) (3)	2.56±1.16 (1-6) (2)	0.049
Complications			
Intraoperative complications	0	0	(-)
Surgical site complications			
Seroma (total)	4 (22.2%)	2 (8.6%)	0.477
Conservative treatment	2 (11.1%)	1 (4.3%)	
Interventional treatment	2 (11.1%)	1 (4.3%)	
Infection	0	0	(-)
Wound dehiscence	0	0	(-)
30-day readmissions	0	0	(-)
Chronic pain	0	0	(-)
Recurrence	2 (11.1%)	0 (0.0%)	0.196
Conversion to open	0	0	(-)

Categorical and continuous variables are presented as n (%) and the mean± Standard Deviation (SD), respectively. LOHS Length of hospital stay

The operative time was shorter in the sIPOM group and was statistically significant (74.16 minutes ±14.1 vs. 94.0 minutes ±23.9, p=0.002). The length of hospital stay (LOHS) was longer in the IPOM-Plus group (3.11 days ±0.90 vs. 2.56 days ±1.16, p=0.04). There were no intraoperative complications and conversion to other techniques in both groups. Postoperative seroma formation occurred in 4 (22.2%) and 2 (8.6%) patients in the sIPOM and IPOM-Plus groups, respectively, with no significant difference (p =0.477). Both groups had

no surgical site infection (SSI) and wound dehiscence. The VAS pain scores during periods of rest and throughout daily activities showed improvement on both the first and 10th days postoperatively in both groups. However, the pain scores were significantly higher in the IPOM-Plus group (p <0.001). The early postoperative pain assessment with the VAS is shown in **Table 3**. There was two (11.1%) recurrence in the sIPOM group, while no recurrences were observed in the IPOM-Plus group (p=0.196).

Table 3 The VAS pain scores during at rest and daily activity.

VAS scores (mean±SD, min-max)	IPOM (n=18)	IPOM-Plus (n=23)	p value
Postop day 1 (at rest)	3.33±0.42 (2.5-4)	4.28±0.42 (3.5-5)	<0.001
Postop day 1 (daily activity)	4.13±0.58(3-5)	5.08±0.51 (4-6)	<0.001
Postop day 10 (at rest)	1.91±0.35 (1.5-2.5)	2.95±0.45 (2-3.5)	<0.001
Postop day 10 (daily activity)	2.97±0.55 (2-4)	3.97±0.46 (3-4.5)	<0.001

VAS Visual analog scale

DISCUSSION

The LVIHR technique offers various advantages over open repair, including reduced operative time, shorter LOHS, and lower complication rates. However, it demonstrates comparable postoperative pain and recurrence rates.^[3,14,15] As outlined in the Society of American Gastrointestinal Endoscopic Surgeons (SAGES) guideline, the decision to close the defects (the IPOM-Plus) is left to the discretion of the operating surgeon, and its potential benefits have not yet been conclusively established through high-quality research.^[14] Conversely, the IEHS guideline recommends defect closure for ventral and incisional hernias with level-3 and level-4 statements.^[8] Incisional and primary AWHs differ in terms of pathophysiologic characteristics and possible outcomes of the surgical repair. Several studies comparing the sIPOM and IPOM-Plus approaches have also presented combined findings for repairs of incisional and primary AWHs.^[16-20] This article focuses on small and medium-sized PMAWHs and compares the outcomes of the sIPOM and IPOM-Plus techniques.

In the IPOM-Plus group, the surgical time was statistically significantly longer than in the sIPOM group. It is obvious that closure of the defects is the only difference in surgical steps between both techniques and requires more time. Recent studies have indicated that incorporating defect closure into the laparoscopic repair of primary and incisional hernias increases surgery times.^[17,19,21] Conversely, Martin-del-Campo et al. found no correlation between defect closure and operating time.^[22] Similarly, in their research, no significant difference was noted between the two groups in terms of length of hospital stay.^[22] However, Basakula et al. reported an extended LOHS in the IPOM-Plus group.^[17] Our study also found significantly longer LOHS in the IPOM-Plus group.

According to the SAGES Guideline, the development of seromas in hernia surgery should be viewed as an anticipated outcome rather than a complication.^[14] Closure of defects helps reduce dead space, potentially leading to lower seroma rates in laparoscopic incisional and primary AWH repairs, as reported by several case series, a meta-analysis, and a randomized controlled study (RCT).^[21–24] However, not statistically significant, numerically higher seroma rates were found in the sIPOM group in this study.

The VAS-pain scores decreased between the first and 10th postoperative days in both groups; however, pain scores were significantly higher in the IPOM-Plus group. Ahonen-Siirtola et al. reported increased early pain following the IPOM-Plus procedure compared to the sIPOM. In contrast, a randomized controlled study (RCT) declared that closing the hernia defect during laparoscopic ventral hernia repair did not increase postoperative pain.

Two patients in the sIPOM group experienced recurrence at the end of the postoperative first year. There were no recurrences in the IPOM-Plus group. However, the differences between the two groups were statistically insignificant ($p=0.196$) despite the numerical difference. Numerous articles reported that incorporating the closing of the defects to the sIPOM approach decreased the recurrence rates.^[17,21,22]

Low sample numbers and the retrospective nature were the significant limitations of this study. In addition, detailed quality-of-life (QoL) and long-term pain assessments could not be presented despite the long-term follow-up period.

CONCLUSION

In conclusion, despite the increased early-postoperative pain and LOHS, the IPOM-Plus technique has similar seroma and recurrence rates for repairing small to medium-sized primary midline abdominal wall hernias compared to the non-closure technique (despite the numerical difference). The seroma formation and recurrence rates seem higher for the medium-large primary and incisional AWHs repaired with the sIPOM technique versus the IPOM-Plus. More RCTs, meta-analyses, and multi-center case-control studies with large samples are needed for more valuable and definitive results.

ETHICAL DECLARATIONS

Ethics Committee Approval: The study was approved by the Trabzon Kanuni Training and Research Hospital Ethics Committee (Date:28.02.2022 Decision no: 11384-2022/22).

Informed Consent: All patients signed the free and informed consent form.

Referee Evaluation Process: Externally peer-reviewed.

Conflict of Interest Statement: The authors have no conflicts of interest to declare.

Financial Disclosure: The authors declared that this study has received no financial support.

Author Contributions: All of the authors declare that they have all participated in the design, execution, and analysis of the paper, and that they have approved the final version.

REFERENCES

1. LeBlanc KA, Booth WV. Laparoscopic repair of incisional abdominal hernias using expanded polytetrafluoroethylene: preliminary findings. *Surg Laparosc Endosc* 1993;3:39–41.
2. Franklin JE, Gonzalez JJ, Glass JL, Manjarrez A. Laparoscopic ventral and incisional hernia repair: An 11-year experience. *Hernia* 2004;8:23–7.
3. Sauerland S, Walgenbach M, Habermalz B, Seiler CM, Miserez M. Laparoscopic versus open surgical techniques for ventral or incisional hernia repair. *Cochrane Database Syst Rev*. 2011;(3):CD007781.
4. Agarwal BB, Agarwal S, Gupta MK, Mishra A, Mahajan KC. Laparoscopic ventral hernia meshplasty with "double-breasted" fascial closure of hernial defect: A new technique. *J Laparoendoscopic Adv Surg Tech* 2008;18:222–9.
5. Liang MK, Subramanian A, Awad SS. Laparoscopic Transcutaneous Closure of Central Defects in Laparoscopic Incisional Hernia Repair. *Surg Laparosc Endosc Percutan Tech* 2012;22:e66–70.
6. Orenstein SB, Dumeer JL, Monteagudo J, Poi MJ, Novitsky YW. Outcomes of laparoscopic ventral hernia repair with routine defect closure using "shoelacing" technique. *Surg Endosc* 2011;25:1452–7.
7. Chelala E, Thoma M, Tatete B, Lemye AC, Dessily M, Alle JL. The suturing concept for laparoscopic mesh fixation in ventral and incisional hernia repair: Mid-term analysis of 400 cases. *Surg Endosc Other Int Techniques* 2007;21:391–5.
8. Bittner R, Bingener-Casey J, Dietz U, Fabian M, Ferzli GS, Fortelny RH, et al. Guidelines for laparoscopic treatment of ventral and incisional abdominal wall hernias (International Endohernia Society (IEHS) - Part 1. *Surg Endosc* 2014;28:2–29
9. Muysoms F. IPOM: history of an acronym. *Hernia* 2018;22:743–6.
10. Kroese LF, Gillion JF, Jeekel J, Kleinrensink GJ, Lange JF. Primary and incisional ventral hernias are different in terms of patient characteristics and postoperative complications - A prospective cohort study of 4,565 patients. *Int J Surg* 2018;51:114–9.
11. Bittner R, Bain K, Bansal VK, Berrevoet F, Bingener-Casey J, Chen D, et al. Update of Guidelines for laparoscopic treatment of ventral and incisional abdominal wall hernias (International Endohernia Society (IEHS))—Part A. *Surg Endosc* 2019;33:3069–139.
12. Köckerling F, Schug-Paß C, Adolf D, Reinhold W, Stechemesser B. Is Pooled Data Analysis of Ventral and Incisional Hernia Repair Acceptable? *Front Surg* 2015;2.
13. Muysoms FE, Miserez M, Berrevoet F, Campanelli G, Champault GG, Chelala E, et al. Classification of primary and incisional abdominal wall hernias. *Hernia* 2009;13:407–14.
14. Earle D, Roth JS, Saber A, et al. SAGES guidelines for laparoscopic ventral hernia repair. *Surg Endosc* 2016;30:3163–83.
15. Sajid MS, Bokhari SA, Mallick AS, Cheek E, Baig MK. Laparoscopic versus open repair of incisional/ventral hernia: a meta-analysis. *Am J Surg* 2009;197:64–72.
16. Bernardi K, Olavarria OA, Holihan JL, et al. Primary Fascial Closure during Laparoscopic Ventral Hernia Repair Improves Patient Quality of Life: A Multi-center, Blinded Randomized Controlled Trial. *Ann Surg* 2020;271:434–9.
17. Basukala S, Tamang A, Rawal SB, et al. Comparison of outcomes of laparoscopic hernioplasty with and without fascial repair (IPOM-Plus vs IPOM) for ventral hernia: A retrospective cohort study. *Ann Med Surg* 2022;80.
18. Olmi S, Millo P, Piccoli M, et al. Laparoscopic treatment of incisional and ventral hernia. *Journal of the Society of Laparoendoscopic Surgeons* 2021;25.
19. Saijo F, Tokumura H, Narushima Y, Matsumura N, Sato K, Okazaki Y. The quality of life after laparoscopic ventral and incisional hernia repair with closure and non-closure of fascial defect. *Surg Today* 2019;49:942–7.

20. Gómez-Menchero J, Balla A, Fernández Carazo A, Morales-Conde S. Primary closure of the midline abdominal wall defect during laparoscopic ventral hernia repair: analysis of risk factors for failure and outcomes at 5 years follow-up. *Surg Endosc* 2022;36:9064–71.
21. Christoffersen MW, Westen M, Rosenberg J, Helgstrand F, Bisgaard T. Closure of the fascial defect during laparoscopic umbilical hernia repair: a randomized clinical trial. *Br J Surg* 2020;107:200–8.
22. Martín-del-Campo LA, Miller HJ, Elliott HL, Novitsky YW. Laparoscopic ventral hernia repair with and without defect closure: comparative analysis of a single-institution experience with 783 patients. *Hernia* 2018;22:1061–5.
23. Tandon A, Pathak S, Lyons NJR, Nunes QM, Daniels IR, Smart NJ. Meta-analysis of closure of the fascial defect during laparoscopic incisional and ventral hernia repair. *Br J Surg* 2016;103:1598–607.
24. Chelala E, Baraké H, Estievenart J, Dessily M, Charara F, Allé JL. Long-term outcomes of 1326 laparoscopic incisional and ventral hernia repair with the routine suturing concept: a single institution experience. *Hernia* 2016;20:101–10.