

PYCNODYSOSTOSIS: SURGICAL CHALLENGES OF INTRAMEDULLARY NAILING FOR LONG BONE FRACTURES: A CASE REPORT

*Piknodisostozis: Uzun Kemik Kırıklarında Kanal İçi Çivilemenin Cerrahi Zorlukları:
Vaka Sunumu*

İbrahim Deniz CANBEYLİ¹, Meriç ÇIRPAR¹, Birhan OKTAŞ¹, Cüneyt Emre ÖKKEŞİM²

¹ Kırıkkale University, Faculty of Medicine, Department of Orthopaedics and Traumatology, KIRIKKALE, TÜRKİYE

ABSTRACT

ÖZ

Pycnodysostosis, known as osteopetrosis acro-osteolytica, is a rare sclerotic bone disease with an autosomal recessive heritage pattern. Characteristic features of the disease are short stature, delayed closure of cranial sutures, partial or total dysplasia of the phalanges, obtuse mandibular angle, skeletal abnormalities and increased bone density. Type I collagen catabolism and bone resorption are defective in these patient due to lysosomal cysteine protease and cathepsin K enzyme defects resulting in dense and more brittle bones. Herein, we report a 45-year-old pycnodysostosis patient with a subtrochanteric transverse fracture of the left femur. We aim to reveal the difficulties encountered during intramedullary nailing of long bone fractures of patients with pycnodysostosis.

Osteopetrosis akro-osteolitik olarak da bilinen piknodisostozis, otozomal resesif kalıtım özelliği gösteren, nadir görülen sklerotik bir kemik hastalığıdır. Hastalığın karakteristik özellikleri boy kısalığı, kranial sütürlerin geç kapanması, falanksların tam ya da kısmi displazisi, mandibula köşelerinin geniş açılı olması, iskelet anomalileri ve artmış kemik yoğunluğudur. Bu hastalarda, lizozomal sistein proteaz ve katepsin K enzim defektleri nedeniyle kırılabilir kemik oluşumuna neden olan tip I kollajen katabolizması ve kemik rezorpsiyon defektleri mevcuttur. Bu makalede, sol subtrokanterik femur kırığı gelişmiş olan piknodisostozisli 45 yaşında bir hasta bildirilmektedir. Amacımız, piknodisostozis hastalarında uzun kemik kırıklarının kanal içi çivilenmesi sırasında karşılaşılan zorlukları gözden geçirmektir.

Anahtar Kelimeler: Pycnodysostosis, long bone fractures, intramedullary nailing

Keywords: Piknodisostosis, uzun kemik kırıkları, kanal içi çivileme



Yazışma Adresi / Correspondence:

Kırıkkale University, Faculty of Medicine, Department of Orthopaedics and Traumatology, Kırıkkale, TÜRKİYE

Telefon: +90 532 2214147

Geliş Tarihi / Received: 30.05.2017

Dr. İbrahim Deniz CANBEYLİ

E-posta: denizcanbeyli@kku.edu.tr

Kabul Tarihi / Accepted: 15.08.2017

INTRODUCTION

Pycnodysostosis, known as osteopetrosis acro-osteolytica, is a rare sclerotic bone disease with an autosomal recessive heritage pattern (1). The term pycnodysostosis is formed by the Greek words pycnos (dense), dys (defective) and ostosis (bone) (2). It is caused by 12 different mutations in chromosome 1q21 resulting in defective expression of lysosomal cysteine protease and cathepsin K enzymes (3). The disease was first described by Maroteaux and Lamy in 1962 (4). Characteristic features of the disease are short stature, delayed closure of cranial sutures, partial or total dysplasia of the phalanges, obtuse mandibular angle, skeletal abnormalities and increased bone density (5-7). The disease is usually diagnosed at childhood during investigation for short stature and delayed closure of cranial sutures.

Type I collagen catabolism and bone resorption are defective in these patient due to above mentioned enzyme defects resulting in dense and more brittle bones (3). Patients usually encounter long bone fractures with minor trauma. Numerous femoral subtrochanteric cases have been reported in patients with pycnodysostosis in literature (5,8). Intramedullary nailing (IMN) is recommended for the treatment of long bone fractures in patients with pycnodysostosis (9). However, due to anomalies and increased bone density, many unexpected problems arise during surgical treatment in these patients. In this case report, we aimed to reveal the difficulties encountered during intramedullary nailing of long bone fractures of patients with pycnodysostosis and underline what needs to be done to overcome these difficulties.

CASE REPORT

A 45-year-old woman was admitted to the emergency department due to hip pain after a fall from standing height. In the lower extremity examination, there was shortening of the left leg with an external rotation

deformity. Neurovascular examination was normal. All laboratory examinations were normal. Radiographic examination revealed a subtrochanteric transverse fracture of the left femur (Figure I). The patient had abnormal findings such as short stature (142 cm), small jaw structure, delayed closure of cranial sutures, marked nose and hypoplasia in the fingers, indicating a concomitant syndromic disorder (Figure II). From her history, it was learned that, she was diagnosed with pycnodysostosis as a result of genetic screening for investigation of etiology of short stature at age of 18. She also had a history of plate osteosynthesis due to tibial fracture at 31 years of age and a history of prosthetic treatment due to periodontal complaints at age of 38. Family story was negative for pycnodysostosis.

On x-ray and computed tomography examination during preoperative planning, the femur was significantly sclerotic and the medullary canal was narrow. The diameter of the medullary canal was measured as 9.4 mm at the isthmus. We planned to fix the fracture according to these measurements with a 9mm thick and 300 mm long trochanteric nail.

During surgery following closed reduction of the fracture, two short guide wires which were used for guiding wide flexible reamers for proximal canal reamerisation, broke during the insertion of the wires. Therefore it was not possible to insert the wire to the desired level. When reaming the proximal portion of the canal with wider flexible reamers with a motor was attempted, these reamers also broke. Proximal reamerisation was completed manually with a rigid reamer. For reamerisation of the canal distal to the fracture line, the fracture line was surgically exposed with a lateral incision. The canal was perforated with a thick rigid K wire prior to reamerisation with a rigid reamer. Against all these attempts, it was not possible to ream the canal to the anticipated level. However, the only available shortest nail was 300 mm. Thus, the nail

protruded about 1 cm proximally from the tip of the trochanter major (Figure III). In addition, during insertion of the proximal and distal locking screws, the drills got overheated and carbonized. Two drills were broken. Proximal locking screw also seated proximally at the level of servicotrochanteric region rather than trochanter minor. The battery of the reamer had to be changed three times during the surgery.

Despite all these difficulties, the patient did not have any problems during healing (Figure IV). At last control at 2 years, she had full range of motion at her hip and knee. There was not any pain due to irritation of the hip abductor musculature by the protruded end of the nail. The Trendelenburg test was also negative. Informed consent form was signed by the patient for this case.

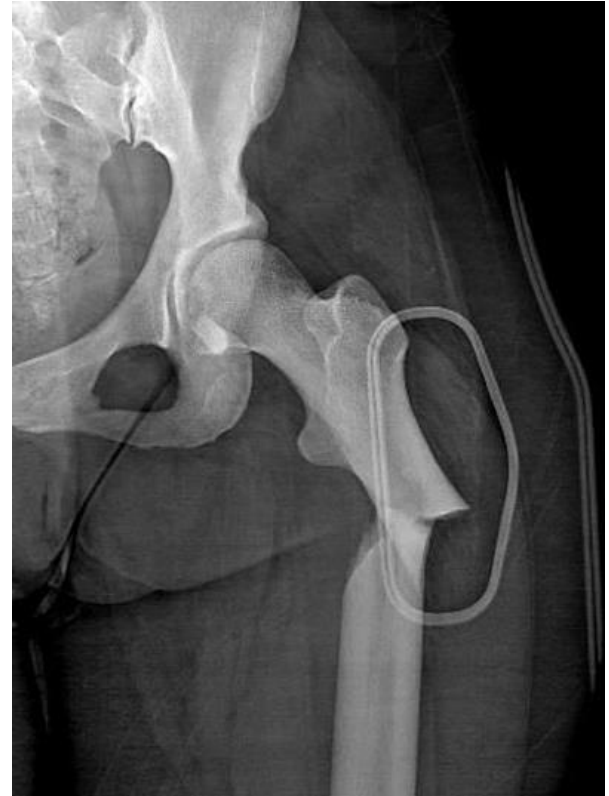

Figure 1. Anteroposterior x-ray of the patient demonstrating the transvers subtrochanteric fracture.

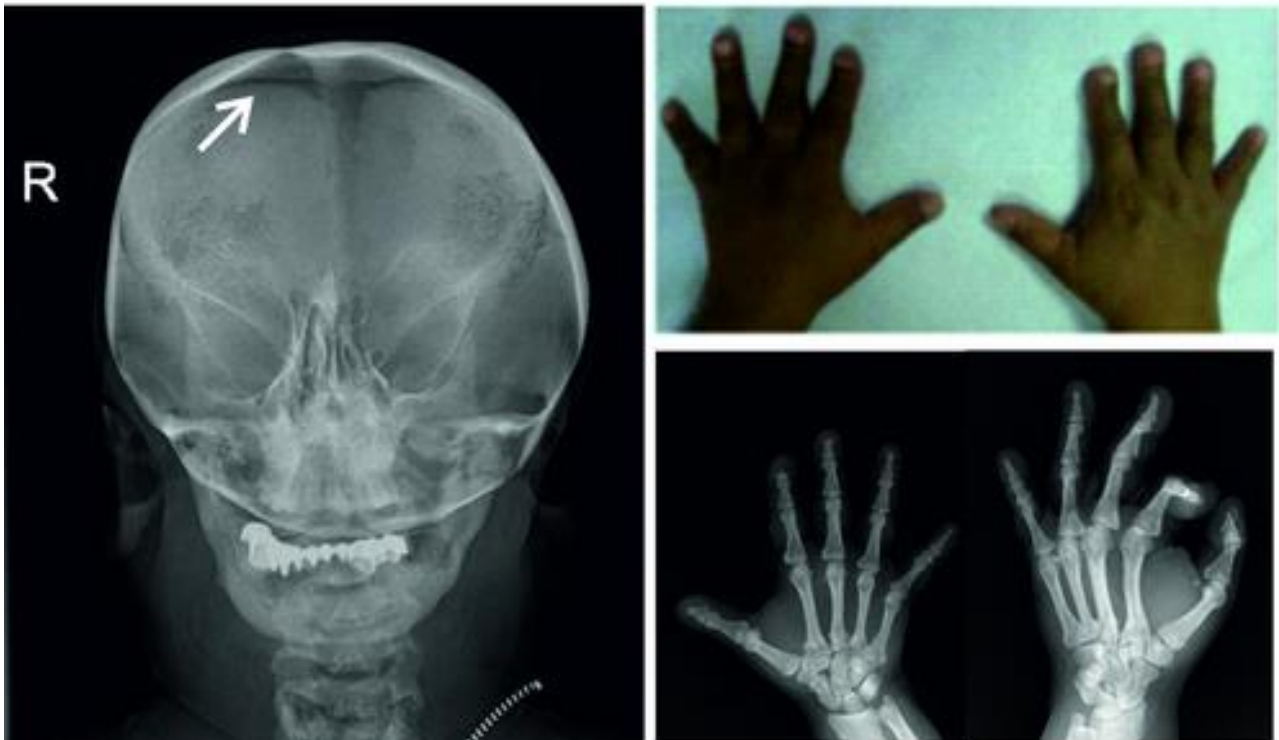


Figure 2. Characteristics of pycnodysostosis. Persisting open sagittal suture on cranial x-ray (white arrow) and phalangeal hypoplasia are demonstrated.

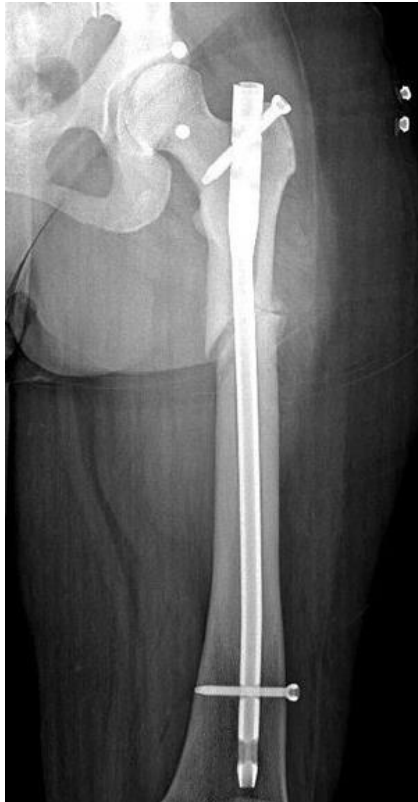

Figure 3. Postoperative anteroposterior x-ray of the left hip. The protruding proximal end of the nail is demonstrated.

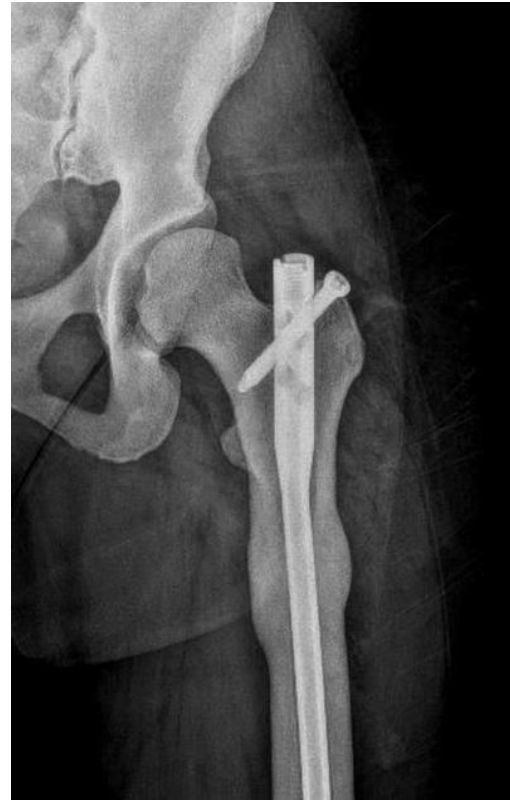

Figure 4. Postoperative 2nd year anteroposterior of the left femur. The fracture healed without any complication.

DISCUSSION

In pycnodysostosis, the affected bone is abnormally sclerotic, brittle and have an increased density. The other skeletal anomalies associated with pycnodysostosis are short stature, failure of closure of cranial sutures, wormian bones, hypoplastic mandible ramus, acro-osteolysis of terminal phalangeas, and absence of clavicular acromial ends (2,4,5). On radiography, pansclerotic appearance of the long bones can be seen in osteosclerosis, hypophosphatasia and long term use of bisphosphonates as well as pycnodysostosis (5,10,11). In pycnodysostosis, blood count, blood chemistry, 25-hydroxyvitamin D and bone turn over markers such as bone ALP, N-terminal telopeptide are usually normal. In literature, subtrochanteric femur fractures have been reported in cases of pycnodysostosis (5). Treatment modalities reported for these fractures vary from conservative to operative interventions as open reduction and plate

fixation, closed reduction and external fixation or intramedullary nailing (5,12-14). Conservative treatment in these patients is not recommended because of the high complication rates associated with long-term immobilization (1). Nakase et al. in their study with 5 cases of pycnodysostosis, reported late disappearance of the fracture line beyond 2 even 3 years, a refracture and a nonunion (14). They underlined the difficulty of the surgery in these patients and advice IM nailing as a better choice for long bone fractures of the lower extremity at the initial surgery. Yates et al. also reported late evidence of fracture healing in this group of patients (15). Implant failure and osteonecrosis of the femoral head are other reported problems associated with fixation of atypical subtrochanteric femur fractures in pycnodysostosis with plate and screws (13). No problem or complication was encountered in fracture healing after IMN at two years follow-up against all technical

difficulties encountered during surgery. Thus, we also advice IMN for long bone fractures of these patients. Matar HE et al. reported that they had difficulty in drilling screw holes during osteosynthesis with plate, and had to use 1 drill for each hole (1). They also suggest IM nailing for the treatment of long bone fractures in these patients due to these problems experienced in intraoperative drilling and postoperative healing. However, difficulty in reaming is a major concern in these patients. Hashem et al. reported that IMN could not proceed to the intramedullary canal in a pycnodysostosis patient with motorized and manual reamerisation, and used high-speed burr to open the canal (9). Similarly, Kundu et al. reported difficulty during reamerisation of the canal due to intramedullary stenosis for a preplanned 8 mm diameter Kuntcher nail (5). We also experienced difficulties during reamerisation in our patient. Although the nail length was measured as 9 mm x 300 mm in the preoperative CT guided plans, we couldn't insert the nail because of the inability to perform the desired level of reamerisation. Two flexible reamers were broken and the reamerisation had to continue with rigid reamers. In these patients, it is necessary to consider the difficulty of the fixation with any kind of implantation because of the sclerosis of the bone. We recommend starting surgery with a large number of rigid and flexible reamers and multiple sharp-edged drills present. And also We strongly recommend that having the plate screw and external fixation set in the operating room with the nail set.

In conclusion, pycnodysostosis is a rare condition having many skeletal manifestations. Long bone fractures possess difficulties in fracture fixation and complications related with fracture healing. IMN may be the choice of treatment in these atypical fractures. On the other hand, different types of implants as well as rigid and flexible drills should be ready for surgery. A meticulous followed up is advised both for implant survival and fracture healing in this particular group of patients.

REFERENCES

1. Matar HE, James LA. A challenging paediatric pathological femur fracture in pyknodysostosis (osteopetrosis acro-osteolytica): lessons learnt. *BMJ Case Reports*. 2014; 2014: 207730.
2. Darcan S, Akisu M, Taneli B, Kendir G. A case of pycnodysostosis with growth hormone deficiency. *Clin Genet*. 1996; 50: 422-5.
3. Naeem M, Sheikh S, Ahmad W. A mutation in CTSK gene in an autosomal recessive pycnodysostosis family of Pakistani origin. *BMC Medical Genetics*. 2009; 10: 76.
4. Donnarumma M, Regis S, Tappino B, Rosano C, Assereto S, Corsolini F, et al. Molecular analysis and characterization of nine novel CTSK mutations in twelve patients affected by pycnodysostosis. *Human Mutation*. 2007; 28: 524.
5. Maroteaux P, Lamy M. Pyknodysostosis. *Presse Med*. 1962; 70: 999-1002.
6. Kundu ZS, Marya KM, Devgan A, Yadav V, Rohilla S. Subtrochanteric fracture managed by intramedullary nail in a patient with pycnodysostosis. *Joint Bone Spine*. 2004; 71: 154-6.
7. Fleming KW, Barest G, Sakai O. Dental and facial bone abnormalities in pyknodysostosis: CT findings. *AJNR American Journal of Neuroradiology*. 2007; 28: 132-4.
8. Mujawar Q, Naganoor R, Patil H, Thobbi AN, Ukkali S, Malagi N. Pycnodysostosis with unusual findings: a case report. *Cases J*. 2009; 2: 6544.
9. Alves Pereira D, Berini Aytes L, Gay Escoda C. Pycnodysostosis. A report of 3 clinical cases. *Med Oral Patol Oral Cir Bucal*. 2008; 13: 633-5.
10. Roth VG. Pycnodysostosis presenting with bilateral subtrachantheric fractures: case report. *Clinical Orthopaedics and Related Research*. 1976; 117: 247-53.

11. Bor N, Rubin G, Rozen N. Fracture management in pycnodysostosis: 27 years of follow-up. *J Pediatr Orthop B*. 2011; 20: 97-101.
12. Hashem J, Krochak R, Culbertson MD, Mileto C, Goodman H. Atypical femur fractures in a patient with pycnodysostosis: a case report. *Osteoporosis Int*. 2015; 26: 2209-12.
13. Whyte MP, McAlister WH, Novack DV, Clements KL, Schoenecker PL, Wenkert D. Bisphosphonate-induced osteopetrosis: novel bone modeling defects, metaphyseal osteopenia, and osteosclerosis fractures after drug exposure ceases. *J Bone Miner Res*. 2008; 23: 1698-707.
14. Shane E, Burr D, Ebeling PR, Abrahamsen B, Adler RA, Brown TD et al. Atypical subtrochanteric and diaphyseal femoral fractures: report of a task force of the American Society for Bone and Mineral Research. *J Bone Miner Res*. 2010;25:2267-94.
15. Taylor MM, Moore TM, Harvey JP Jr. Pycnodysostosis. A case report. *The Journal of Bone and Joint Surgery American volume*. 1978; 60: 1128-30.
16. Yuasa T, Maeda K, Kaneko K, Yoshikata K. Total Hip Arthroplasty after Treatment of an Atypical Subtrochanteric Femoral Fracture in a Patient with Pycnodysostosis. *Case Rep Orthop*. 2015; 2015: 731910.
17. Nakase T, Yasui N, Hiroshima K, Ohzono K, Higuchi C, Shimizu N et al. Surgical outcomes after treatment of fractures in femur and tibia in pycnodysostosis. *Archives of Orthopaedic and Trauma Surgery*. 2007; 127: 161-5.
18. Yates CJ, Bartlett MJ, Ebeling PR. An atypical subtrochanteric femoral fracture from pycnodysostosis: a lesson from nature. *Journal of Bone and Mineral Research*. 2011; 26: 1377-9.