






## LETTER TO THE EDITOR

### Treatment of postpneumonectomy syndrome with silicone breast implant and chimeric latissimus dorsi and serratus anterior muscle flaps

Postpnömonektomi sendromunun silikon meme implantı ve kimerik latissimus dorsi ve serratus anterior kas flepleri ile tedavisi

Eyüphan Gencil<sup>1</sup> , Alper Avcı<sup>1</sup> , Ömer Kokaçya<sup>1</sup> , İbrahim Tabakan<sup>1</sup> , Cemal Özçelik<sup>1</sup> 

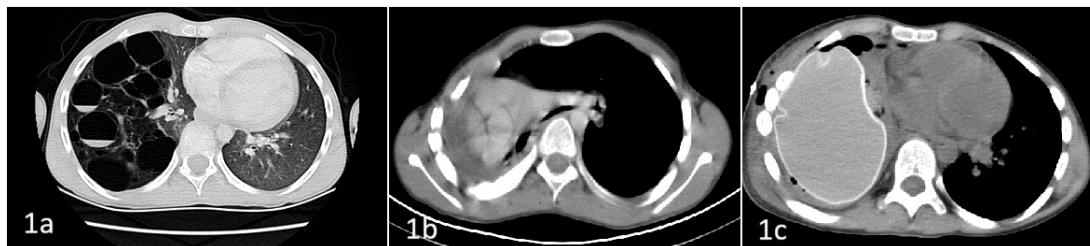
<sup>1</sup>Cukurova University, Adana, Türkiye

To the Editor,

Postpneumonectomy syndrome (PPS) was introduced by Wassermann in 1979.<sup>1</sup> Due to underdeveloped cartilaginous structures, PPS occurs more often in children than in adults, whereas pneumonectomy is rarely performed in children. It can be a life-threatening condition without treatment.<sup>2</sup> With a reported incidence of 11% in all pneumonectomy cases, mediastinal shift primarily compresses the trachea and neurovascular structures, with overexpansion of contralateral hemithorax.<sup>3</sup> Patients show progressive dyspnea, stridor, worsening of their general condition, and recurrent pulmonary infections.<sup>4</sup> Computer tomography (CT), bronchoscopy, and pulmonary function tests rule out diseases that cause dyspnea. There is no optimal reconstructive approach for restoring intrathoracic

airflow while restoring intrathoracic volume with acceptable cosmetic results.

In this letter, we report the first use of a silicone breast implant combined with intrathoracic transposition of latissimus dorsi and serratus anterior muscle flaps to stabilize tracheal repositioning. We present a case of an 11-year-old male patient with postpneumonectomy syndrome after undergoing right pneumonectomy for congenital cystic adenoid malformation (Figure 1a). In the fifth postoperative month, the patient was hospitalized with severe dyspnea, cough, and oxygen saturation of less than 60%. Chest x-ray, bronchoscopy, and thorax computerized tomography (Figure 1b) revealed a mediastinal shift with bronchial tree stenosis. Right-sided postpneumonectomy syndrome was diagnosed in the patient.



**Figure 1. (a) Right lung cystic adenomatoid malformation, (b) mediastinal shift, and (c) right main bronchus repositioning and breast implant**

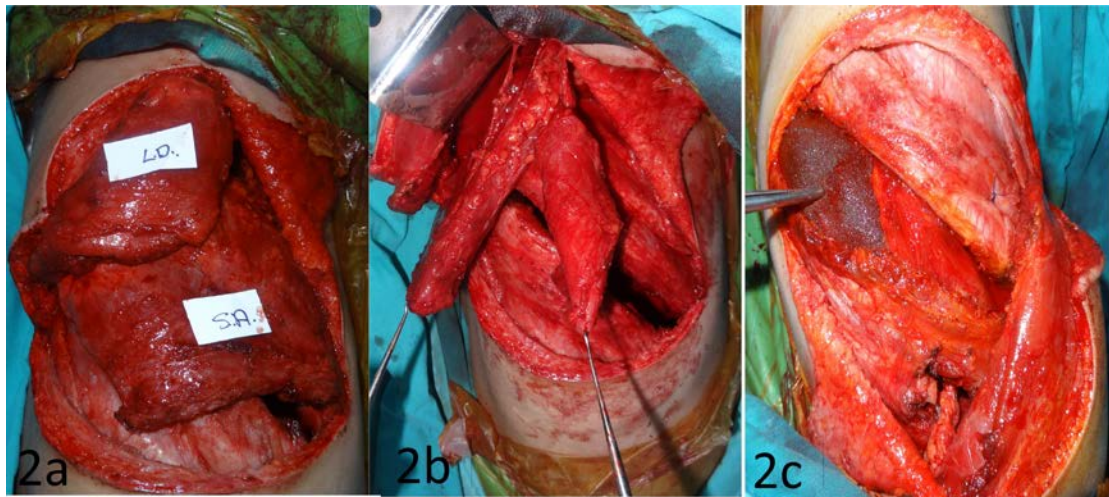
Address for Correspondence: Ömer Kokaçya, Cukurova University, Faculty of Medicine, Department of Plastic, Reconstructive and Aesthetic Surgery, Adana, Türkiye E-mail: kokacya@yahoo.com

Received: 26.09.2023 Accepted: 14.12.2023

Under general anesthesia, a previous right posterolateral thoracotomy incision was used to explore the pneumonectomy pouch through the fifth intercostal space for the treatment of the postpneumonectomy syndrome. After the release of the adhesions between the pericardium and the chest wall, silicone breast implant sizers with varied volumes (range 400–520 cc) were temporally placed into a pouch, and rigid bronchoscopy was performed to evaluate the stenotic site for airway reestablishment.

A 520-cc sizer supplied the proper mediastinal position and an open airway. The latissimus dorsi muscle flap was harvested on thoracodorsal vessels using the subscapular arterial system, and the serratus anterior muscle flap was gathered on the serratus branch and as a chimeric flap (Figure 2a). The third

costal cartilage was then partially resected to create a window, and flaps were inserted into the thoracotomy pouch (Figure 2b). After a rehearsal of implant and flap positions, the sizer was replaced with a permanent 520-cc cohesive gel-filled, textured silicon prosthesis (Mentor, California). The serratus flap was used as a barrier between the silicone implant and the primary vascular structures, and it was fixed inferiorly to the diaphragm. The latissimus dorsi was used to provide anterior coverage for the silicone implant that was fixed to the intercostal muscles with 3/0 polydioxanone sutures (Figure 2c). Thorax CT (Figure 1c) and bronchoscopic examination indicated that the right main bronchus had been repositioned without stenosis. The patient was discharged on the fifth postoperative day without incident, and no complications were observed throughout the 4-yr follow-up.



**Figure 2.** (a) Harvested latissimus dorsi and serratus anterior muscle flaps, (b) flaps inserted to the thorax through a window produced by partial resection of the third costal cartilage, and (c) inset of breast implant, latissimus dorsi, and serratus muscle flaps.

In our case, the PPS was observed in the fifth postoperative month after the right-sided pneumonectomy surgery. After pneumonectomy procedures, the mediastinum shifts to the operation side, and the contralateral lung becomes overexpanded.<sup>2</sup> After the right pneumonectomy, the right heart and tracheobronchial tree rotate counterclockwise. The left main bronchus is kinked over the aorta. Remarkably, cartilaginous structures

in children can easily bend on themselves. As a result, it is understandable that the PPS is commonly observed after right pneumonectomy surgeries in children. Mediastinum repositioning and silicon prosthesis implant,<sup>2</sup> tracheobronchial stent,<sup>3</sup> tissue expander,<sup>4</sup> intrapleural expandable prosthesis,<sup>5</sup> resection of the anterior vertebral body, interposition of intercostal muscle aortic division, and by-pass<sup>2</sup> are some treatment options.

There is no optimal reconstructive approach for restoring intrathoracic volume while maintaining intrathoracic airflow with acceptable cosmetic results. Although the tracheobronchial stent procedure is less invasive, it is associated with several risks, including pulmonary embolism, pneumonia, respiratory failure, and pericardial tamponade. Recurrent pneumonia may occur after using a nitinol stent. Pneumonia caused by multidrug-resistant pathogens like *Pseudomonas aeruginosa* and *Staphylococcus aerogenous* have been reported in cases.<sup>3</sup> Tissue expanders are an uncomplicated procedure involving minimally invasive surgical intervention. Tissue expanders have disadvantages, such as leakage, malposition, herniation, and luxation, which may necessitate reoperation.<sup>4</sup> Furthermore, expander implantation is not advised for use beyond six months. Mediastinum immobilization by perichondral graft may be accompanied by infection in the graft.

We freed the main bronchia using the appropriate volume of textured silicone gel-filled breast implant. We combined two muscle flaps around the breast implant to prevent implant malposition and spare the main vascular structure. This procedure may prevent the frequent complications associated with tissue expanders, such as leakage and infection. After implantation, the implant or expander might change positions, resulting in malposition. Malposition can be prevented by combining muscle flaps, as in our case, or using a tailored 3D prosthesis with Teflon coverage.<sup>6</sup> In this case, a textured silicone implant was used. Textured implants have two advantages over nontextured saline implants: reduced wrinkling and softness to prevent rigid pressure on vascular tissue and less mobility in the cavity.

The follow-up period was <5 yr, and long-term studies on pediatric postpneumectomy syndrome are needed to corroborate the findings.

In conclusion, this is the first report of a breast implant and intrathoracic use of chimeric muscle flaps combination for the treatment of PPS. Our

experience shows that using muscle flaps combined with breast implants may effectively restore main bronchi airflow, prevent volume loss, and prevent further surgeries, such as malposition and herniation.

---

**Author Contributions:** Concept/Design : ŞÖ, MBK, SŞ; Data acquisition: MBK, SŞ; Data analysis and interpretation: SŞ, FÖKS; Drafting manuscript: ŞÖ, MBK, SŞ, FÖKS, SÇ; Critical revision of manuscript: ŞÖ, MBK, SÇ; Final approval and accountability: ŞÖ, MBK, SŞ, FÖKS, SÇ; Technical or material support: ŞÖ, SŞ, FÖKS, SÇ; Supervision: SÇ; Securing funding (if available): n/a.

**Ethical Approval:** Since this study is a case report, there is no need for the approval of the ethics committee.

**Peer-review:** Editorial review.

**Conflict of Interest:** The authors declare no conflict of interest concerning this article's authorship and/or publication.

**Financial Disclosure:** The authors received no financial support for the research and/or authorship of this article.

**Information:** This case was presented as a poster at Turkish Society of Plastic Reconstructive and Aesthetic Surgery 38th Annual Meeting in Antalya 27-30 October, 2016.

---

## REFERENCES

1. Wasserman K, Jamplis RW, Lash H, Brown HV, Cleary MG, Lafair J. Post-pneumectomy syndrome. Surgical correction using Silastic implants. *Chest*. 1979;75:78-81.
2. Soll C, Hahnloser D, Frauenfelder T, Russi EW, Weder W, Kestenholz PB. The postpneumectomy syndrome: clinical presentation and treatment. *Eur J Cardiothorac Surg*. 2009;35:319-24.
3. Abe J, Hasumi T, Tanaka R, Saito Y, Kanma K, Takahashi S. Long-term outcome of nitinol stenting to treat asphyxia caused by postpneumectomy syndrome. *Respirol Case Rep*. 2017;5:e00207.
4. Macaré van Maurik AF, Stubenitsky BM, van Swieten HA, Duurkens VA, Laban E, Kon M. 2007. Use of tissue expanders in adult postpneumectomy syndrome. *J Thorac Cardiovasc Surg*. 2007;134:608-12.
5. Ozcelik C, Onat S, Askar I, Topal E. 2004. Surgical correction of postpneumectomy syndrome by intrapleural expandable prosthesis in a child. *Interact Cardiovasc Thorac Surg*. 2004;3:390-2.
6. Wang B, Tan S, Yu F. 2018. Correction of postpneumectomy syndrome with tridimensional carbon fiber-printed implant. *J Thorac Cardiovasc Surg*. 2018;155:e135-7.