



## Laparoscopic management of urachal remnants in children

Gulnur Gollu\*, Gonul Kucuk, Ufuk Ates, Bilge Turedi, Farid Khanmammadov, Aydin Yagmurlu, Huseyin Dindar, Meltem Bingol Kologlu

Department of Pediatric Surgery, Faculty of Medicine, Ankara University, Ankara, Turkey

### ARTICLE INFO

### ABSTRACT

#### Article History

Received 05 / 05 / 2016

Accepted 23 / 06 / 2016

#### \* Correspondence to:

Gulnur Gollu  
Department of Pediatric Surgery,  
Faculty of Medicine,  
Ankara University,  
Ankara, Turkey  
e-mail: drggollu@yahoo.com

#### Keywords:

Children  
Laparoscopy  
Minimal invasive  
Urachal

Urachal remnant is an uncommon congenital anomaly which is caused by the persistence of embryologic communication between the bladder and the umbilicus. The surgical approach to these remnants has been open for years but endoscopic surgery has become more popular because of its better cosmetic results, less postoperative pain and faster returns to daily activities. The aim of this study is to present 17 cases of urachal remnants that were treated by laparoscopic excision. Retrospective review was performed included all patients diagnosed with an urachal remnant (UR) and underwent laparoscopic excision between January 2009 and January 2015. Patient variables included age, gender, presenting symptoms, diagnostic modality, type of urachal remnant, operative time, post-operative complications and follow-up were recorded. Laparoscopic surgery was performed using three ports. The urachal remnant was excised starting from the umbilicus to the bladder dome by cauterization. Stump on the bladder was ligated with endoloop sutures. We identified 17 pediatric patients with an urachal cyst (n=8), urachal diverticulum (n=4), urachal sinus (n=4) and patent urachus (n=1). Median age of the patients was 7 years (5 months-17 years). All patients had symptomatic URs. Abdominal pain (n=8), umbilical discharge (n=6), and umbilical mass (n=3) were presenting symptoms. Ultrasonography confirmed the diagnosis of urachal remnant in all children. Mean operating time was 30 minutes (12-60 minutes). No intraoperative or postoperative complications were reported at a mean follow-up of 28 months. Histopathological examination revealed benign urachal remnant. Laparoscopic excision of urachal remnants is a preferable alternative to traditional open surgery with better postoperative analgesia, cosmetic results and rapid healing. Laparoscopic approach is an effective and minimal invasive technique to treat of urachal remnants in children.

© 2017 OMU

### 1. Introduction

The urachal remnant is a rare congenital anomaly which is an allontois remnant that usually obliterates after birth (Cutting et al., 2005). The incidence of urachal remnant is 1:150000 in infants and 1:5000 in adults (Yohannes et al., 2003; Chiarenza et al., 2009).

There are various types of urachal remnants including sinus, diverticulum, cyst and fistula. Although most of the cases with urachal remnant are

asymptomatic, the most common presenting symptoms are umbilical discharge, abdominal pain and recurrent urinary tract infection.

Urachal remnants should be surgically treated even they are asymptomatic because of possibility of future malign degeneration (Yohannes et al., 2003; Chiarenza et al., 2009). The surgical approach to these remnants has been open for years but endoscopic surgery has become more popular because of its better cosmetic

results, less postoperative pain and faster returns to daily activities.

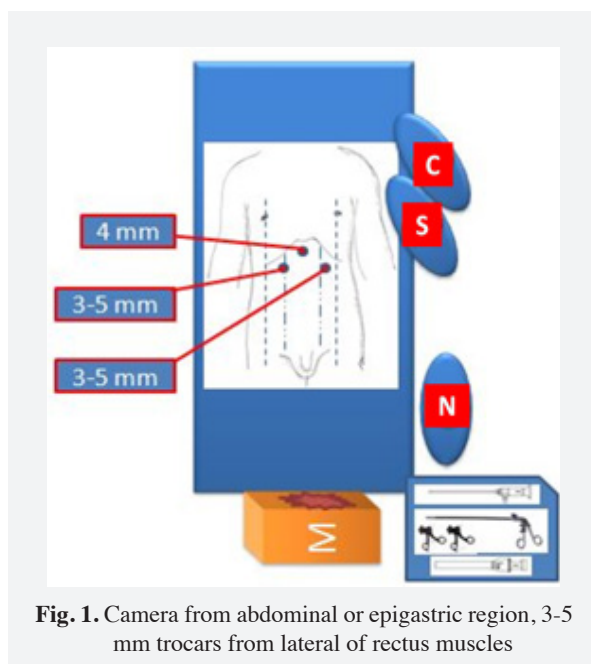
The aim of this study is to present 17 cases of urachal remnants that were treated by laparoscopic excision.

## 2. Materials and methods

The study was performed in adherence to the Declaration of Helsinki. Retrospective review was performed included all patients diagnosed with an urachal remnant (UR) and underwent laparoscopic excision between January 2009 and January 2015. Patient variables included age, gender, presenting symptoms, diagnostic modality, type of urachal remnant, operative time, post-operative complications and follow-up were recorded.

### Operative Technique

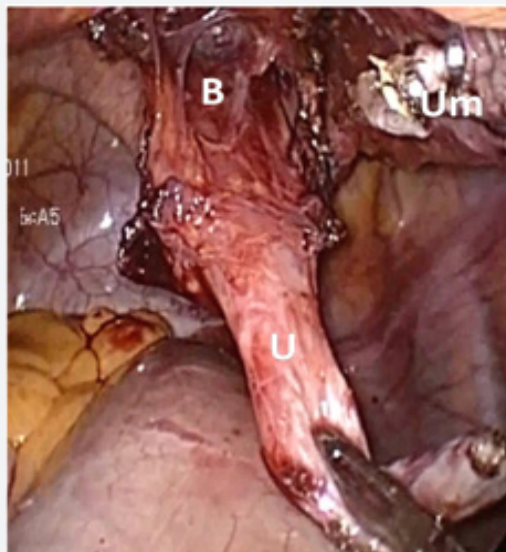After urethral catheterization, all of the patients were placed in supine position. All patients were administered a single dose of parenteral Ceftriaxone during induction of anesthesia. The 4mm camera trocar was inserted through the umbilicus or epigastric region. Once the camera port was placed inside the peritoneal cavity, a CO<sub>2</sub> pneumoperitoneum was created with a pressure of 8-12 mmHg. A 4 mm, 30 degree lens camera (Karl Storz Endoscopy, Tuttlingen, Germany) was used. Working ports (3-5 mm) were inserted to the lateral of rectus muscles (Fig. 1).



**Fig. 1.** Camera from abdominal or epigastric region, 3-5 mm trocars from lateral of rectus muscles

Three millimeters working ports were preferred if the child was under 10 kilograms. The working ports were placed upper quadrants if the child was older than 5 years old and lower quadrants if the child was younger than 5 years old. Surgeon and camera assistant were on the left side of the table on which the child was in

Trendelenburg position. The monitor was placed near the patient's feet. The urachal remnant was dissected beginning from the umbilicus down to the dome of bladder (Fig. 2).



**Fig. 2.** Dissection of the urachal diverticulum  
U: Urachal remnant; B: Bladder;  
Um: Umbilicus

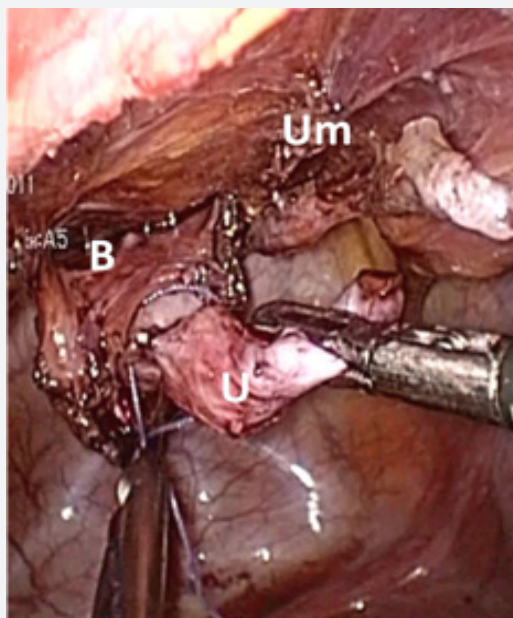
Sometimes 5 mm clips or endoloop were used to ligate umbilicus side. The urachal remnant was excised starting from the umbilicus to the bladder dome by hook electrocautery. Except hook cautery, other devices were not needed for dissection. Stump on the bladder was ligated with 2/0 polyglactin endoloop sutures (Fig. 3). After ligation, the bladder was filled with warm saline solution to check if there was a leakage. The remnant was excised through the working or umbilicus trocar-site. Urethral catheter was removed after the procedure.

We think that for urachal sinuses which can be excised from the umbilicus, laparoscopic surgery may be a major intervention. For this reason, we exclude these patients from laparoscopy group. The patients with infected remnants undergone surgery after antibiotherapy.

## 3. Results

We identified 17 pediatric patients (12 girls, 3 boys) with either an urachal cyst (n=8), urachal diverticulum (n=4), urachal sinus (n=4) and patent urachus (n=1). Median age of the patients was 7 years (5 months-17 years). All patients had symptomatic urachal remnants. Abdominal pain (n=8), umbilical discharge (n=6), and umbilical mass (n=3) were presenting symptoms. Ultrasonography confirmed the diagnosis of urachal remnant in all children.

Mean operating time was 30±12.33 minutes. No intraoperative or postoperative complications were



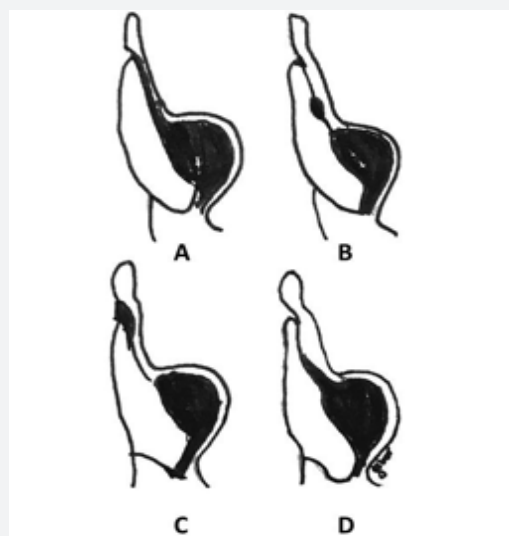
**Fig. 3.** Ligation of urachal diverticulum. **U:** Urachal remnant; **B:** Bladder; **Um:** Umblicus

reported at a mean follow-up of 28 months. All of the patients were fed on postoperative sixth-hour and discharged on postoperative first day. Histopathological examination revealed benign urachal remnant.

#### 4. Discussion

The urachus is a remnant of the allantois which is an embryological communication between the bladder and the umbilicus. Urachus usually obliterated shortly after birth and becomes median umbilical ligament which is between peritoneum and transversalis fascia in the midline (Cutting et al., 2005). The incidence of urachal remnant is 1:150000 in infants and 1:5000 in adults (Yohannes et al., 2003; Chiarenza et al., 2009). There are many types of persistent urachal remnants depending on the section which is obliterated. A sinus is where the patent part of urachus is communicates with the umbilicus. Diverticulum is where there is a communication between the urachus and apex of the bladder. Cyst, which is the most common type, occurs when there is no communication with umbilicus and bladder. When whole of the urachus is not obliterated, then it forms urachal fistula (Cutting et al., 2005; Chiarenza et al., 2009, Sato et al., 2015) (Fig. 4). Urachal cyst was also the most common type in our series. In one of our patients who was five months old, there was a patent urachus. Although most of urachal remnants are asymptomatic, the most common presenting symptoms are umbilical discharge, abdominal pain and recurrent infection (Yohannes et al., 2003; Chiarenza et al., 2009). The urachal fistula commonly presents in neonates with a urinary discharge from the umbilicus. Sinus

usually presents with a discharge from the umbilicus and diverticulum may present with recurrent urinary tract infections. The cysts usually become symptomatic when they are infected. Then, they present as a painful mass in the lower midline with associated signs of infection (Cutting et al., 2005). If cyst is infected, epithelial degeneration or bacterial contamination may expand the cyst and it may establish a tract between the bladder or umbilicus or rupture into abdomen (Chiarenza et al., 2009).



**Fig. 4.** Urachal remnant types **A:** Patent urachus; **B:** Urachal cyst; **C:** Urachal sinus; **D:** Urachal diverticulum

Urachal remnants should be surgically treated even if they are asymptomatic to avoid development of carcinoma in the remnant (Yohannes et al., 2003; Kojima et al., 2007; Chiarenza et al., 2009). Urachal cancer is very rare and it occurs less than 1% of bladder cancers (Fanning et al., 2011). The remnant should be totally excised in order to prevent recurrence (Cutting et al., 2005; Kojima et al., 2007).

Traditionally the urachal remnants are treated by open surgical techniques, however as minimally invasive surgery has recently gained increased acceptance especially in children (Cutting et al., 2005; Kojima et al., 2007). Laparoscopic excision of urachal remnant was first described in 1993 by Trondsen et al. (1993) and extended to the pediatric patients in 1995 (Fahlenkamp et al., 1995; Kurtz and Masiakos, 2008). In all of our patients, one camera port and two working ports were used. Camera trocar was inserted through epigastrium in children who had umbilical discharge to evaluate the relation between umbilicus and remnant. If there was a connection between umbilicus and remnant, clips or endoloop were used to ligate umbilicus side. The remnant was excised either by using endoloop.

All of the patients had good cosmetic result. There was no recurrence or any problem in the follow-up. In order to compare the laparoscopic approach with the open technique randomized controlled trial should be conducted. As the number of case reports and small series about endoscopic approach to urachal remnants increased, this procedure appears to be safe and effective (Masuko et al., 2013; Bertozzi et al., 2014; Siow et al., 2015). Therefore, it can be suggested as a primary alternative technique to open surgery because

of its association with less postoperative pain, good cosmesis, and rapid convalescence.

Laparoscopic excision of urachal remnants is a preferable alternative to traditional open surgery with better postoperative analgesia, cosmetic results and rapid healing.

Laparoscopic approach is an effective and minimal invasive technique to treat of urachal remnants in children.

## REFERENCES

- Bertozzi, M., Riccioni, S., Appignani, A., 2014. Laparoscopic treatment of symptomatic urachal remnants in children. *J. Endourol.* 28, 1091-1096. doi: 10.1089/end.2014.0203.
- Chiarenza, S.F., Scarpa, M.G., D'Agostino, S., Fabbro, M.A., Novek, S.J., Musi, L., 2009. Laparoscopic excision of urachal cyst in pediatric age: Report of three cases and review of the literature. *J. Laparoendosc. Adv. Surg. Tech. A.* 19, 183-186. doi: 10.1089/lap.2008.0184.
- Cutting, C.W., Hindley, R.G., Poulsen, J., 2005. Laparoscopic management of complicated urachal remnants. *BJU Int.* 96, 1417-1421.
- Fahlenkamp, D., Schönberger, B., Lindeke, A., Loening, S.A., 1995. Laparoscopic excision of the sinusoidal remnants of the urachus in a 3-year-old boy. *Br. J. Urol.* 76, 135-137.
- Fanning, D.M., Sabah, M., Conlon, P.J., Mellotte, G.J., Donovan, M.G., Little, D.M., 2011. An unusual case of cancer of the urachal remnant following repair of bladder exstrophy. *Ir. J. Med. Sci.* 180, 913-915. doi: 10.1007/s11845-009-0310-z.
- Kojima, Y., Hayashi, Y., Yasui, T., Itoh, Y., Maruyama, T., Kohri, K., 2007. Laparoscopic management for urachal cyst in a 9-year-old boy. *Int. Urol. Nephrol.* 39, 771-774.
- Kurtz, M., Masiakos, P.T., 2008. Laparoscopic resection of a urachal remnant. *J. Pediatr. Surg.* 43, 1753-1754. doi:10.1016/j.jpedsurg.2008.04.021.
- Masuko, T., Uchida, H., Kawashima, H., Tanaka, Y., Deie, K., Iwanaka, T., 2013. Laparoscopic excision of urachal remnants is a safe and effective alternative to open surgery in children. *J. Laparoendosc. Adv. Surg. Tech. A.* 23, 1016-1019. doi: 10.1089/lap.2013.0127.
- Sato, H., Furuta, S., Tsuji, S., Kawase, H., Kitagawa, H., 2015. The current strategy for urachal remnants. *Pediatr. Surg. Int.* 31, 581-587. doi: 10.1007/s00383-015-3712-1.
- Siow, S.L., Mahendran, H.A., Hardin, M., 2015. Laparoscopic management of symptomatic urachal remnants in adulthood. *Asian J. Surg.* 38, 85-90. doi: 10.1016/j.asjsur.2014.04.009.
- Trondsen, E., Reiertsen, O., Rosseland, A.R., 1993. Laparoscopic excision of urachal sinus. *Eur. J. Surg.* 159, 127-128.
- Yohannes, P., Bruno, T., Pathan, M., Baltaro, R., 2003. Laparoscopic radical excision of urachal sinus. *J. Endourol.* 17, 475-479.