

# Prenatal diagnosis and clinical outcomes of isolated interruption of the inferior vena cava: an analysis of 12 cases

 Zuat Acar<sup>1</sup>,  Işıl Turan Bakırcı<sup>2</sup>,  Deniz Kanber Acar<sup>3</sup>,  Helen Bornaun<sup>4</sup>

<sup>1</sup>Department of Obstetrics and Gynecology, İstanbul Tema Hospital, İstanbul, Turkey

<sup>2</sup>Division of Perinatology, Department of Obstetrics and Gynecology, Başakşehir Çam and Sakura City Hospital, İstanbul, Turkey

<sup>3</sup>Division of Perinatology, Department of Obstetrics and Gynecology, Kanuni Sultan Süleyman Training and Research Hospital, İstanbul, Turkey

<sup>4</sup>Department of Pediatric Cardiology, Kanuni Sultan Süleyman Training and Research Hospital, İstanbul, Turkey

**Cite this article as:** Acar Z, Turan Bakırcı I, Acar DK, Bornaun H. Prenatal diagnosis and clinical outcomes of isolated interruption of the inferior vena cava: an analysis of 12 cases. *J Med Palliat Care*. 2023;4(5):530-534.

Received: 10.09.2023

Accepted: 03.10.2023

Published: 27.10.2023

## ABSTRACT

**Aims:** This study aimed to thoroughly examine the clinical presentations and outcomes associated with prenatally detected isolated interrupted inferior vena cava (IIVC) with azygos continuation. The intention was to provide further insight into the importance of prenatal diagnosis for this particular condition.

**Methods:** A longitudinal study was conducted on a cohort of 12 fetuses who had been diagnosed prenatally with inferior vena cava interruption and azygos vein continuation. Comprehensive fetal anomaly scans and echocardiography were performed, and pediatric cardiologists further validated postnatal diagnoses. In addition, genetic testing and comprehensive follow-up procedures were implemented.

**Results:** The research findings substantiated the considerable diagnostic precision of prenatal identification, as evidenced by the 100% confirmation rate in postnatal assessments. Most patients demonstrated positive outcomes, underscoring the significance of prenatal diagnosis. Genetic testing results indicated that all the studied cases exhibited normal chromosomal configurations.

**Conclusion:** This study contributes to understanding this rare vascular anomaly and its implications in clinical practice. Additionally, our findings emphasize the importance of regular prenatal screenings and the need for healthcare providers to be knowledgeable about isolated IIVC cases. By increasing awareness and understanding of this vascular anomaly, healthcare professionals can provide better care and support for affected patients and their families. Furthermore, future research should investigate the potential genetic factors contributing to the development of isolated IIVC, which could further enhance our understanding of this condition.

**Keywords:** Isolated interruption inferior vena cava, azygos continuation, prenatal diagnosis, echocardiography

## INTRODUCTION

Vascular anomalies known as interrupted inferior vena cava (IIVC) with azygos continuation have yet to receive considerable attention. However, their clinical significance should be considered. The inferior vena cava (IVC) forms during embryonic development when the cardinal, subcardinal, and supracardinal veins join. Any deviation or stoppage in this physiological process, namely inside the right subcardinal vein, can result in an alternative pathway that redirects blood flow through azygos continuation, bypassing the hepatic segment.<sup>1</sup>

According to available reports, evidence suggests a higher occurrence of this uncommon vascular variant, affecting an estimated 0.2-3% of the overall population, in persons with congenital cardiac anomalies, specifically left isomerism and atrial septal defects.<sup>1-4</sup> In individuals

who do not experience any physiological abnormalities, solitary occurrences of IIVC constitute a significant fraction, with an estimated prevalence of approximately one in 5,000 individuals.<sup>5</sup> The prognosis for these isolated variants, especially those with a normal karyotype, is typically favorable, although there may be significant variability. The overall prognosis for isolated variants, particularly those with a normal karyotype, tends to be favorable; however, there can be large variations.<sup>5,7</sup>

Prenatal detection of the IIVC is becoming increasingly common in medical practice. This vascular aberration has many clinical ramifications, including venous thromboembolic diseases and abnormal spleen function.<sup>5</sup>

**Corresponding Author:** Işıl Turan Bakırcı, isilturan@yahoo.com



This study aimed to conduct a thorough analysis of the clinical presentations of IIVC at different stages of life, focusing on the importance of prenatal diagnosis for making therapeutic intervention more effective. In light of the complex characteristics of IIVC and the little scholarly discussion around this phenomenon, the present work aims to make a valuable contribution towards enhancing the comprehension of this anomaly.

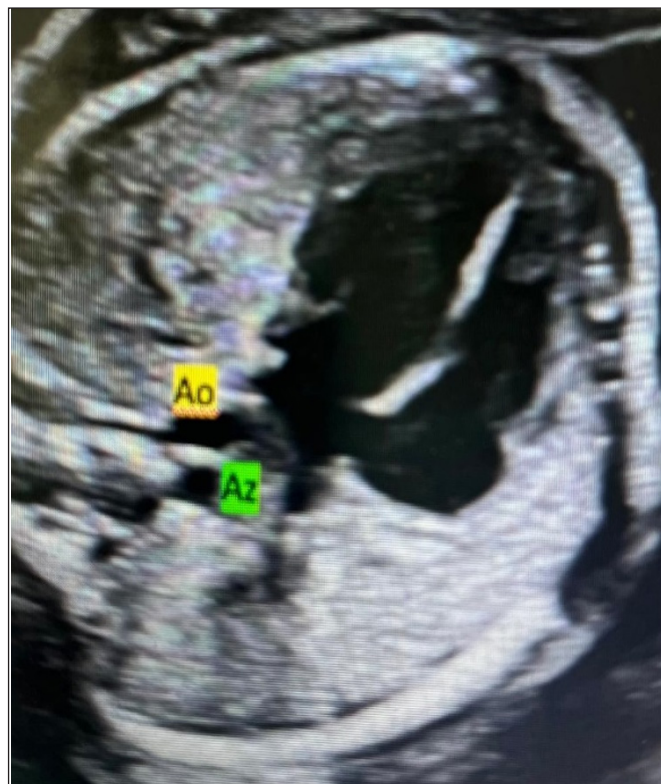
## METHODS

The study was carried out with the permission of Kanuni Sultan Süleyman Training and Research Hospital Clinical Researches Ethics Committee (Date: 2019, Decision No: KAEK/2019.06.144). All procedures were carried out in accordance with the ethical rules and the principles of the Declaration of Helsinki.

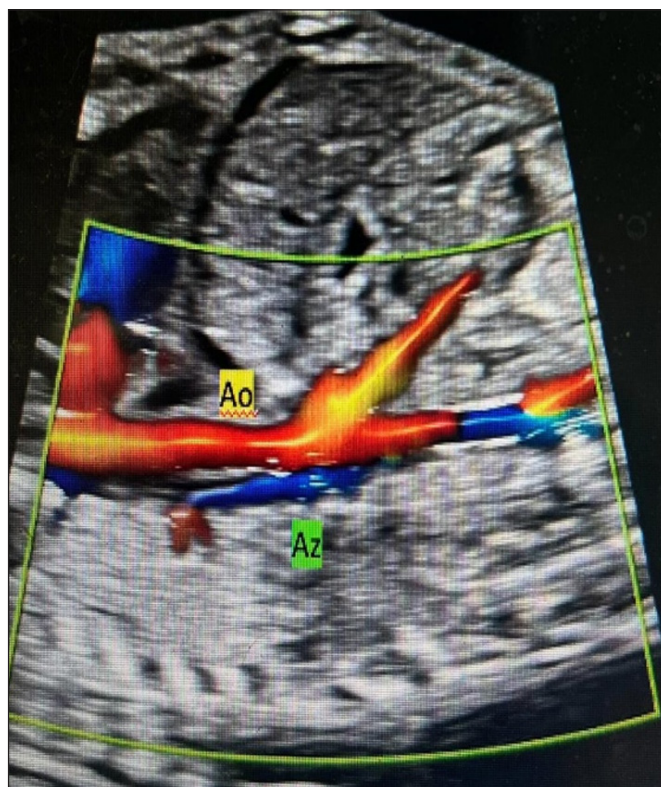
The current study employed longitudinal research involving 12 fetuses diagnosed with IIVC with azygos continuation during the prenatal period. All participating families provided informed consent, and the Institutional Ethics Board approved the study. Echocardiographic and sonographic examinations were conducted using Voluson E6 Expert ultrasound equipment manufactured by GE Healthcare, Milwaukee, WI, USA. Pulsed-wave and color Doppler techniques were employed. All imaging techniques were performed by highly skilled professionals in both perinatology and cardiology, demonstrating proficiency in fetal heart imaging. All enrolled fetuses underwent a thorough examination consisting of a comprehensive fetal abnormality scan and echocardiography. Several crucial diagnostic characteristics were identified in the study. The “double vessel sign”<sup>7,8</sup> is distinguished by the concurrent existence of the aorta and another vein of comparable dimensions on the right side of the spinal column or posterior to the heart (Figure 1).

The present investigation involved the identification of a dilated azygos vein that traversed the diaphragm and drained into the superior vena cava (SVC). The sagittal plane image of the fetal abdomen revealed the absence of a hepatic section of the inferior vena cava. A dilated vessel running parallel to the aorta was observed in the longitudinal view. This image suggested the presence of an inferior vena cava with azygos continuation (Figure 2). Color Doppler imaging confirmed that the flow direction within the azygos vein was in direct opposition to that observed within the descending aorta. Postnatal diagnoses were confirmed using neonatal echocardiography, which a specialist in pediatric cardiology conducted. Supplementary examinations were performed to evaluate cardiac rhythm and anatomical positioning of the visceral organs, including electrocardiography (ECG), Holter

ECG, abdominal ultrasonography, and chest radiography. Longitudinal sonographic follow-up was conducted on all fetuses throughout pregnancy and postpartum to observe and assess any potential problems or related conditions.



**Figure 1.** An axial view reveals the aorta (Ao) and the dilated paraspinal azygos vein (Az) situated posteriorly to the heart, indicating the presence of the ‘double-vessels’ sign.



**Figure 2.** The azygos vein is positioned parallel to and behind the descending thoracic and abdominal aorta in sagittal view (Ao, aorta; Az, azygos)

## Statistical Analysis

This study employed a sample size of 12 instances, and descriptive statistics were utilized to characterize the obtained results succinctly. Owing to the limited quantity of our dataset, we opted for a simplistic methodology whereby we computed the medians and ranges for continuous variables, including maternal age, diagnosis week, delivery week, and birth weight. It is essential to highlight that we abstained from performing more sophisticated statistical analyses due to the restricted sample size. The limited sample size, which made it impossible to conduct complex statistical analysis, was the driving force behind the decision to prioritize descriptive statistics.

## RESULTS

This study examined 12 cases of isolated IIVC during fetal development. Each case was meticulously investigated, and the accuracy of the diagnosis was subsequently validated by a pediatric cardiologist, resulting in a diagnostic accuracy rate of 100%. The findings of this study provide robust evidence supporting the reliability of prenatal diagnostics in detecting this infrequent, although medically relevant, vascular abnormality.

The clinical outcomes observed in this study were predominantly positive (Table 1). The median gestational age at diagnosis was 22 weeks (range 21-31 weeks). The median gestational age at birth was 39 weeks, and the median birth weight was 3485 g. The predominant mode of delivery observed in the study population was normal spontaneous delivery (NSD), which is frequently associated with favorable Apgar scores. Three instances were observed wherein newborn problems were observed in the context of preterm deliveries. Owing to the significant implications associated with preterm birth, it is imperative to evaluate this aspect of clinical therapy carefully. In genetics, it is worth mentioning that a significant proportion of families opted to undergo prenatal genetic testing. However, the four remaining individuals who underwent karyotyping exhibited typical chromosomal configurations, highlighting the potential occurrence of isolated inferior vena cava interruption without any accompanying genetic disorders. None of the newborns that were not subjected to testing had observable indications of aneuploidy. No fetal arrhythmia or intrauterine growth restriction was observed during prenatal monitoring of the 12 fetuses with isolated IIVC. In addition, postnatal

**Table 1.** Prenatal and postnatal findings of cases

Case no	Gestational age at diagnosis (wk)	Prenatal findings	Postnatal diagnosis	Mode of delivery	Gestational age at delivery (wk)	Birth weight (grams)	1-minute Apgar score	5-minute Apgar score	Neonatal complications
1	23	Interruption of the inferior vena cava (IVC) with azygos continuation	Similar	Vaginal delivery	38	3205	7	8	
2	21	Interruption of the inferior vena cava (IVC) with azygos continuation	Similar	Vaginal delivery	35	2709	5	10	Respiratory distress syndrome
3	24	Interruption of the inferior vena cava (IVC) with azygos continuation	Similar	Vaginal delivery	39	3300	7	10	
4	22	Interruption of the inferior vena cava (IVC) with azygos continuation	Similar	Cesarean section	28	980	6	8	Respiratory distress syndrome
5	29	Interruption of the inferior vena cava (IVC) with azygos continuation	Similar	Vaginal delivery	36	2578	8	10	
6	31	Interruption of the inferior vena cava (IVC) with azygos continuation	Similar	Vaginal delivery	39	3980	7	10	
7	21	Interruption of the inferior vena cava (IVC) with azygos continuation	Similar	Vaginal delivery	40	3780	8	10	
8	25	Interruption of the inferior vena cava (IVC) with azygos continuation	Similar	Cesarean section	39	3980	6	10	
9	22	Interruption of the inferior vena cava (IVC) with azygos continuation	Similar	cesarean section	40	4100	8	10	
10	22	Interruption of the inferior vena cava (IVC) with azygos continuation	Similar	Vaginal delivery	34	2370	8	10	Sepsis
11	22	Interruption of the inferior vena cava (IVC) with azygos continuation	Similar	Vaginal delivery	39	3670	8	10	
12	22	Interruption of the inferior vena cava (IVC) with azygos continuation	Similar	Cesarean section	40	4200	10	10	

abdominal ultrasonography findings indicated that the anatomical locations of the stomach, spleen, and liver were within the expected range in all neonates. Furthermore, it was observed that none of the 12 fetuses exhibited any postnatal arrhythmia as determined by electrocardiogram (ECG) or Holter investigations.

## DISCUSSION

Interrupted inferior vena cava, also called azygos continuation of the inferior vena cava, is a congenital anomaly in the blood vessels that occurs when the link between the right subcardinal vein and the right vitelline vein does not form fully during embryonic development. When this happens, venous blood from the lower limbs is redirected to the heart through the azygos vein and superior vena cava instead of the usual route through the inferior vena cava. The prevalence of this particular illness is considered low, with an estimated occurrence rate ranging from one in every 20,000 to 40,000 live births, as reported in various studies.<sup>1-4</sup> Prenatal screening techniques frequently detect IIVC, a significant congenital anomaly that is relatively uncommon. This study contributes significantly to the current knowledge base by focusing solely on cases with isolated IIVC, in contrast to earlier studies that mostly associated inferior vena cava interruption with isomerism and other complex illnesses.<sup>5-8</sup> IIVC has been recognized as a noteworthy diagnostic indicator for some medical conditions, such as atrial heterotaxy and polysplenia syndrome.<sup>1,9,10</sup> Nevertheless, our findings suggest that IIVC can present as a distinct illness without concomitant abnormalities.

Xu<sup>6</sup> examined a sample of 21 fetuses with interrupted inferior vena cava with azygos continuation. This study provides significant insights into the clinical outcomes of this uncommon vascular defect. The results indicate that the outlook for patients with a solitary interrupted inferior vena cava is typically positive, especially when the fetal karyotype is normal.<sup>6</sup> A similar study conducted by Babaoğlu et al.<sup>11</sup> also suggests that the prognosis for isolated instances was generally favorable unless there were concurrent cardiac or chromosomal problems. The work conducted by Celentano<sup>3</sup> offers valuable insights into identifying isolated IIVC with azygos continuation during regular prenatal imaging. This study emphasized that this vascular abnormality generally does not have identifiable disease effects and tends to result in positive outcomes.<sup>3</sup> Our study aligns with these findings and highlights the limited occurrence of serious clinical consequences in individual instances.

The absence of an inferior vena cava has substantial implications for medical treatments that use the venous system. For instance, in certain cases, other techniques

may be required for venous angiography or treatment of portal hypertension. One strategy is ligation of the azygos vein, associated with potentially catastrophic outcomes.<sup>5,12</sup> This situation underscores the significance of employing specialized surgical planning and adopting a multidisciplinary approach, mainly when performing procedures that have the potential to damage the azygos vein unintentionally. While IIVC typically does not exhibit symptoms, it has the potential to introduce complexities within the therapeutic context.<sup>13</sup> Instances of fortuitous venous thromboembolism (VTE) have been recorded, highlighting the potential prothrombotic hazards linked to this vascular anomaly.<sup>14-20</sup>

A study by Bronshtein<sup>5</sup> emphasizes the significance of isolated cases of interrupted inferior vena cava, which frequently result in favorable outcomes and are typically not associated with additional fetal abnormalities. Nevertheless, this observation brings attention to the fact that in certain instances, an atypical spleen functioning may be identified following delivery, necessitating the administration of pneumococcal immunization after birth. The idea behind this study is that having an isolated inferior vena cava interruption might affect how the spleen works, which is why new ways of immunizing women after giving birth are needed.

## Limitations of the Study

Although our research provides vital insights, it is essential to acknowledge its limitations. Our study's limited number of participants hinders our ability to apply our findings to a broader population. Furthermore, the lack of comprehensive long-term follow-up data makes it challenging to thoroughly understand the potential difficulties that could manifest in the later stages of life. Hence, it is advisable to conduct additional studies using a larger sample size and an extended duration of follow-up to validate our findings.

## CONCLUSION

Our research and accompanying studies highlight the importance of understanding and effectively managing instances of prenatally detected isolated interrupted inferior vena cava. This is particularly relevant because of the generally positive outlook associated with this condition. Furthermore, our findings underscore the crucial role of prenatal diagnosis in ensuring optimal future outcomes.

## ETHICAL DECLARATIONS

**Ethics Committee Approval:** The study was carried out with the permission of Kanuni Sultan Süleyman Training and Research Hospital Clinical Researches Ethics Committee (Date: 2019, Decision No: KAEK/2019.06.144).

**Informed Consent:** All patients signed the free and informed consent form.

**Referee Evaluation Process:** Externally peer-reviewed.

**Conflict of Interest Statement:** The authors have no conflicts of interest to declare.

**Financial Disclosure:** The authors declared that this study has received no financial support.

**Author Contributions:** All of the authors declare that they have all participated in the design, execution, and analysis of the paper, and that they have approved the final version.

## REFERENCES

- Giang DTC, Rajeesh G, Vaidyanathan B. Prenatal diagnosis of isolated interrupted inferior vena cava with azygos continuation to superior vena cava. *Ann Pediatr Cardiol.* 2014;7:49-51.
- Bass JE, Redwine MD, Kramer LA, Huynh PT, Harris JHJ. Spectrum of congenital anomalies of the inferior vena cava: cross-sectional imaging findings. *Radiographics.* 2000;20(3):639-652.
- Celentano C, Malinger G, Rotmensch S, Gerboni S, Wolman Y, Glezerman M. Prenatal diagnosis of interrupted inferior vena cava as an isolated finding: a benign vascular malformation. *Ultrasound Obstet Gynecol.* 1999;14(3):215-218.
- Tubau A, Grau J, Filgueira A, et al. Prenatal and postnatal imaging in isolated interruption of the inferior vena cava with azygos continuation. *Prenat Diagn.* 2006;26:872-874.
- Bronshtein M, Khatib N, Blumenfeld Z. Prenatal diagnosis and outcome of isolated interrupted inferior vena cava. *Am J Obstet Gynecol.* 2010;202(4):398.e1-4.
- Shahrouki P, Lee EW, Ruehm S. Polysplenia syndrome and sickle cell trait: extensive deep venous thrombosis from venous stasis and hypercoagulability. *Clin Imaging.* 2022;82:127-131.
- Xu Q, Sun HX, Xie JS, Wang JL, Pei QY, Zhang XH. Characteristics and prognosis of interrupted inferior vena cava with azygos continuation. *Zhonghua Fu Chan Ke Za Zhi.* 2018;53(3):149-154.
- Vijayaraghavan SB, Raja V, Chitra T V. Interrupted inferior vena cava and left-sided subrenal inferior vena cava: prenatal diagnosis. *J Ultrasound Med.* 2003;22(7):747-752.
- Moradi B, Moosavi NS, Kazemi MA, Tahmasebpour AR, Fattahi Masrouf F. A case of prenatally detected left isomerism and hemiazygos continuation of inferior vena cava. *J Clin Ultrasound.* 2017;45(7):430-433.
- Sheley RC, Nyberg DA, Kapur R. Azygos continuation of the interrupted inferior vena cava: a clue to prenatal diagnosis of the cardiosplenic syndromes. *J Ultrasound Med.* 1995;14(5):381-387.
- Babaoğlu K, Doğan Y, Başar EZ, Usta E. Prenatal diagnosis of hepatic interruption of the inferior vena cava with azygos/hemiazygos continuation without structural heart defects: a case series. *J Clin Ultrasound.* 2022;50(6):795-802.
- Effler DB, Greer AE, Sifers EC. Anomaly of the vena cava inferior; report of fatality after ligation. *JAMA.* 1951;146(14):1321-1322.
- Mandato Y, Pecoraro C, Gagliardi G, Tecame M. Azygos and hemiazygos continuation: an occasional finding in emergency department. *Radiol Case Rep.* 2019;14(9):1063-1068.
- Lambert M, Marboeuf P, Midulla M, et al. Inferior vena cava agenesis and deep vein thrombosis: 10 patients and review of the literature. *Vasc Med.* 2010;15(6):451-459.
- Kwan KJ, Li H-L, Chan YC, Huang J-X, Cui D-Z, Cheng SW. Venous thromboembolism in a patient with interrupted inferior vena cava and compressed azygos continuation: a case report and review of literature. *Vasc Endovascular Surg.* 2023;57(6):643-649.
- Pasqui E, de Donato G, Camarri S, et al. Case report: inferior vena cava agenesis in a young male patient presenting with bilateral iliac veins thrombosis. *Front Surg.* 2022;9:832336.
- Thomas SD, Ofri A, Tang T, Englund R. Endovascular reconstruction of an interrupted inferior vena cava. *Int J Surg Case Rep.* 2014;5(2):59-62.
- Raymundo SRO, Cabral VS, Cavalieri RF, Reis Neto F. Thrombolysis for deep venous thrombosis associated with inferior vena cava agenesis in a young patient. *BMJ Case Rep.* 2019;12(5):e229840.
- Sagban TA, Grotemeyer D, Balzer KM, et al. Surgical treatment for agenesis of the vena cava: a single-centre experience in 15 cases. *Eur J Vasc Endovasc Surg.* 2010;40(2):241-245.
- Parsa P, Lane JS 3rd, Barleben AR, Owens EL, Bandyk D. Congenital agenesis of inferior vena cava: a rare cause of unprovoked deep venous thrombosis. *Ann Vasc Surg.* 2015;29(5).