

# Radioprotective Effects of *Annona Muricata* Leaf Extract in the Spinal Cord

## *Annona Muricata* Yaprak Ekstratının Spinal Korddaki Radyoprotektif Etkileri ve Histopatolojik Sonuçları

Özlem ELMAS<sup>1</sup> , Havva Hande KESER ŞAHİN<sup>2</sup> , Emrah KESKİN<sup>3</sup> , Özlem APSAR BAŞARAN<sup>1</sup> 

<sup>1</sup>Zonguldak Bülent Ecevit University Faculty of Medicine, Department of Radiation Oncology, Zonguldak, Türkiye

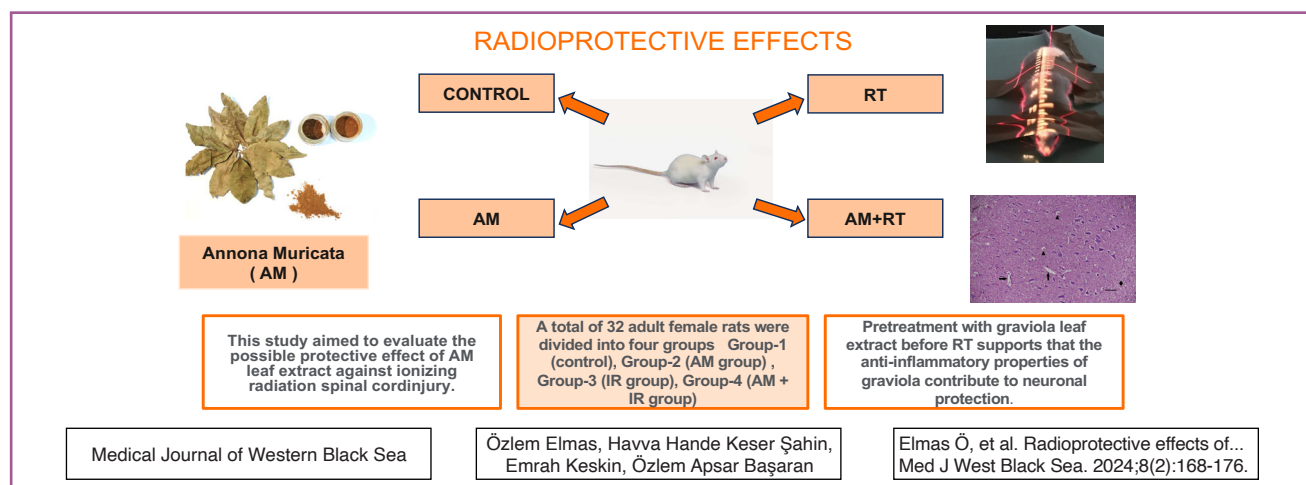
<sup>2</sup>Hitit University Faculty of Medicine, Department of Pathology, Çorum, Türkiye

<sup>3</sup>Zonguldak Bülent Ecevit University Faculty of Medicine, Department of Neurosurgery, Zonguldak, Türkiye

**ORCID ID:** Özlem Elmas 0000-0001-8039-9610, Havva Hande Keser Şahin 0000-0003-1827-1039, Emrah Keskin 0000-0001-5326-741X, Özlem Apsar Başaran 0009-0006-5767-1456

*Cite this article as:* Elmas Ö et al. Radioprotective effects of *annona muricata* leaf extract in the spinal cord. Med J West Black Sea. 2024;8(2):168-176.

### GRAPHICAL ABSTRACT



### ABSTRACT

**Aim:** The spinal cord is often involved in radiotherapy to treat malignancies and is considered as one of the most critical dose-limiting organs. Histopathological changes of radiation-induced spinal cord injury include gliosis, demyelination, and necrosis in the white matter, as well as vascular changes in both white and gray matter. *Annona muricata* (AM), popularly known as "graviola", is a plant that grows in countries with tropical climates (South America, West Africa, Southeast Asia) and is used as an antioxidant, anticancer, analgesic and antispasmodic. Its leaves, roots, bark, seeds and fruits are used in various ways in traditional and alternative medicine by the local people. In our study, graviola leaves obtained from the South American local people were used. This study aimed to evaluate the possible protective effect of AM leaf extract against ionizing radiation spinal cord injury.

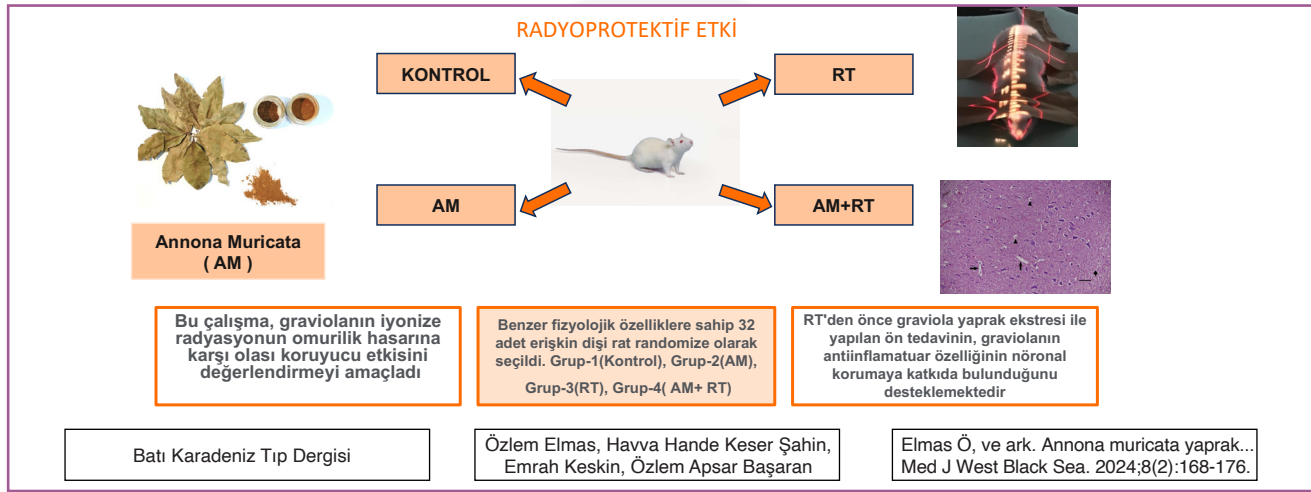
**Material and Methods:** A total of 32 adult female Wistar Albino rats were divided into four groups (a control and three intervention groups): Group-1 (control), Group-2 (AM group), Group-3 (IR group) Group-4(AM+IRgroup). After the sacrificing, spinal cords were dissected out, embedded in paraffin, and stained with Hematoxylin-Eosin, and 11 parameters were microscopically examined and scored. All analyses were performed on Statistical Package for the Social Sciences v21 (SPSS Inc., Chicago, IL, USA).  $P < 0.05$  values were accepted as statistically significant results.

**Results:** AM administration prior to irradiation (IR) lowered the histopathological scores for all parameters that were verified in the IR group at most severe levels: inflammatory cells infiltration, edema, neuron swelling, gliocytes hyperplasia, spinal cord cavitation (loosened tissue structure), pyknotic nuclei, vacuolar denaturation, and loss of Nissl substance. Necrosis was present in IR group and was higher compared to Control and AM treated groups. We noticed that necrosis was present in the AM group too and was higher compared to the control.

**Conclusion:** The data of our study suggest that pretreatment with 300 mg/kg of AM leaf extract prior to IR reduce inflammatory cells infiltration, edema, and neuron swelling. 300 mg/kg was given as in the study 'The neuroprotective and anti-inflammatory effects of *Annona muricata* (Graviola) on radiation-induced rat sciatic nerve injury'. This supports the fact that AM-proposed anti-inflammatory property may contribute to neuroprotection. Similarly, AM was documented to have efficient protection on neural cells from apoptosis or necrosis.

**Keywords:** *Annona muricata*, spinal cord, irradiation, radioprotective

#### GRAFİKSEL ÖZET



#### ÖZ

**Amaç:** Radyoterapi (RT), primer ve metastatik tümörler için önemli bir kanser tedavisidir. Çok sayıda çalışma, DNA'nın, l ipitlerin ve proteinlerin, iyonize radyasyon (IR) tarafından indüklenen serbest radikaller tarafından saldırıya uğradığını ve dolayısıyla ciddi hücre hasarına yol açtığını göstermiştir. Yaygın olarak "graviola" olarak bilinen *Annona muricata* (AM) bitkisi tropik iklimde sahip ülkelerde (Güney Amerika, Batı Afrika, Güneydoğu Asya) yetişmekte olup antioksidan, antikanser, analjezik ve antispazmodik ajan olarak kullanılmaktadır. Yerel halk tarafından geleneksel ve alternatif tıp amaçlı yaprakları, kökü, kabuğu, tohumları ve meyvesi çok çeşitli formlarda kullanılmaktadır. Çalışmamızda graviola yaprakları kullanılmış olup, Güney Amerika'nın yerel halkından temin edilmiştir. Bu çalışma, graviolanın iyonize radyasyonun omurilik hasarına karşı olası koruyucu etkisini değerlendirmeyi amaçladı.

**Gereç ve Yöntemler:** Benzer fizyolojik özelliklere sahip 32 adet erişkin dişi (250±50gr) Wistar Albino rat randomize olarak seçildi. Ratlar Grup 1 (n=8) (control grubu), Grup 2 (n=8) (Graviola grubu), Grup 3 (n=8) (RT grubu), Grup 4 (n=8) (Graviola+ RT grubu) şeklinde gruplandı. Öz, etanol bazlı filtrasyon yoluyla Graviola bitkisinin kurutulmuş yapraklarından elde edildi. Oluşan öz, ratlara aktif bir bileşen olarak uygulandı. Prone pozisyonda sabitlenmiş ratların spinal korduna toplam 20Gy (1GY/dk) dozda tek bir fraksiyon halinde uygulandı. Tüm analizler SPSS ile yapıldı. Sonuçlar %95 güven aralığında değerlendirilecek olup,  $p < 0.05$  değeri anlamlı kabul edilecektir.

**Bulgular:** Dört ayrı grupta inflamatuvar hücre infiltrasyonu, ödem, nöron şişmesi, gliosit hiperplazisi, nekroz, spinal kord kavitasyonu, Nissl cisimcik kaybı, çekirdek çevresinde kavitasyon, piknotik çekirdek gibi parametreler incelendi. İstatistiksel analiz dört grup arasında yukarıdaki parametreler değerlendirilerek yapılmıştır. Doku ve hücrelerin histomorfolojik bulguları skorlandı. Her kriter 0 ile 3 arasında puanlandı. (0=normal, 1=Hafif, 2=orta ve 3=ağır).

**Sonuç:** Ratların RT'den önce graviola ile tedavisinin, control grubuna kıyasla omurilikte nekrotik hasarları önlediğini göstermiştir. RT'den önce graviola yaprak ekstresi ile yapılan ön tedavinin, graviolanın antiinflamatuvar özelliğinin nöronal korumaya katkıda bulunduğunu desteklemektedir.

**Anahtar Sözcükler:** *Annona muricata*, spinal kord, iyonize radyasyon, radyoprotectif

## INTRODUCTION

Radiation therapy (RT) is an important cancer treatment for primary and metastatic tumors. Approximately 50% of cancer patients would benefit from RT to cure localized disease and control incurable cancer diseases (1, 2). The central nervous system (CNS) is one of the main dose-limiting tissues in RT (3). The spinal cord is often involved in RT to treat malignancies involving the neck, thorax, abdomen, and pelvis, as well as head, neck, and lung neoplasms. In addition, metastatic spinal disease requiring RT treatment occurs in 40% of all cancer patients; thus, the spinal cord is considered as one of the most critical dose-limiting organs (4). The first cases of radio damage in the brain and spinal cord were reported by Fisher and Holfelderin 1930 (5). Based on clinical experience for many decades, provided the spinal cord dose is not exceeded, the risk of permanent damage is known to be very low, estimated from 0.03% to 0.2% (6). Clinical manifestations of radiation-induced CNS damage develop after a period from several months to years including focal cerebral necrosis, neurocognitive deficits, and less frequently cerebrovascular disease, myelopathy, or secondary neoplasms (7). Little evidence of damage was reported at the histological level; however, an increase in neurological signs is often observed after CNS irradiation (IR). Histopathological changes of radiation-induced spinal cord injury include gliosis, demyelination, and necrosis in the white matter, as well as vascular changes in both white and gray matter (7, 8). *Annona muricata* (AM), generally known as Graviola, is a member of the Annonaceae family and is widely distributed throughout tropical and subtropical parts of the world, which was used as traditional medicine for various diseases, such as arthritis, diarrhea, neuralgia, and parasitic infections (9). All aerial parts of AM are used in traditional medicine practices; however, the leaf is widely used in current commercially available products (10). AM is used in folk medicine as sedative, anxiolytic and anti convulsant (11,12). In addition to CNS depressant activity, studies in literature confirmed the neurodegenerative effects of this plant on the nervous system that causes neurotoxicity (10, 13). Previous studies also revealed that AM leaf extract has radioprotective effect against gamma-IR (14). However, the radioprotective potential of AM in radiation-induced spinal cord injury has not been sufficiently analyzed and understood. Therefore, this study aimed to evaluate the possible protective effect of AM leaf extract against ionizing radiation spinal cord injury. To the best of our knowledge, this is the first study to analyze the possible radioprotective effects of AM leaf extract in the spinal cord.

## MATERIAL and METHODS

### Animals

The current experimental study was conducted in Bulent Ecevit University, Faculty of Medicine Experimental Animal Research Unit. Female Wistar Albino rats weighing  $250 \pm 50$ gr with similar physiological characteristics were used in this study. Animals were initially randomized into four groups, one control and three experimental groups. Throughout the experimental period, all animals were fed daily with drinking water and pellet feeds containing 21% crude protein under optimum laboratory conditions ( $22 \pm 1^\circ\text{C}$ , 12hours light/dark cycle).

All experimental protocols involving animals were approved by Zonguldak Bulent Ecevit Ethics Committee.

### IR Procedure

During IR, animals were immobilized using an intraperitoneal anesthesia (90mg/kg of ketamin [Ketalar-Eczacıbaşı/Türkiye] and 10 mg/kg of xylazine [Rompun Bayer/Türkiye]). Complete spinal cord IR procedures were carried out in the Radiation Oncology Department of Zonguldak Bulent Ecevit University, Faculty of Medicine. Subsequently, the required dose of IR to create measurable radiation damage was calculated (16 Rats [ $\sim 250$  gr]-300 mg/kg—seven days- $>16$  rats  $\times$  60mg  $\times$  7 days = 6720 mg). Radiation was delivered in a single fraction using a linear accelerator device to a total dose of 20 Gy, (1 GY/min) to the spinal cord, fixed in a supine position.

### Preparation of AM Extract

The extract obtained from dried leaves of the AM plant by ethanol-based filtration was administered to the rats as an active ingredient.

### Experimental Design

A total of 32 adult female Wistar Albino rats were divided into four groups: Group-1 (n = 8) (control group) received 0.01 mL/kg of physiologic serum (saline) by oral gavage once a day for seven days, Group-2 (n = 8) (AM group) received 300 mg/kg of AM leaf extract in 0.01 mL/kg of physiologic serum by oral gavage once a day for seven days, Group-3 (n = 8) (IR group) received 0.01 mL/kg of physiologic serum (saline) by oral gavage once a day for seven days and a single dose of spinal cord radiation (20 Gy) an hour after the last gavage, and Group-4 (n = 8) (AM + IR group) received 300 mg/kg of AM leaf extract in 0.01 mL/kg of physiologic serum by oral gavage once a day for seven days and spinal cord radiation (20 Gy) an hour after the last gavage.

Animals were sacrificed 96 hours after the last treatment, under anesthesia with intraperitoneal 90 mg/kg ketamine (Ketalar-Eczacıbaşı, Turkey). Tissues from all animals were

collected and stored at  $-80^{\circ}\text{C}$  until the analytical assays were performed.

### Histopathological Evaluation

After the sacrificing, spinal cord was dissected out and divided into smaller segments of approximately 1 cm and fixed in 4% paraformaldehyde at room temperature. Formalin-fixed spinal cord tissue samples were routinely processed using automated tissue processing Equipment (Leica ASP300S, Wetzlar, Germany). Then, embedded in paraffin and sectioned to a  $4\text{-}\mu\text{m}$  thickness transversely at midplane by using a Leica RM2255 rotary microtome (Wetzlar, Germany). Tissue sections were stained with Hematoxylin-Eosin (HE) and examined microscopically. All sections were examined similarly for all samples. All study materials were observed, and digital micrographs were captured using a Nikon Eclipse Ni-U microscope equipped with a Nikon Digital DS-Ri2 camera and related software (Nikon, Tokyo, Japan).

In four separate groups, nine parameters were examined for inflammatory cells infiltration, edema, neuron swelling, gliocytes hyperplasia, necrosis, spinal cord cavitation, Nissl body loss, cavitation around the nucleus, pyknotic nuclei, and edema.

Statistical analysis was performed by evaluating the above parameters among the four groups. Histomorphological findings of tissues and cells were scored. Each criterion was scored from 0 to 3 (0 = normal, 1 = Light, 2 = medium, and 3 = heavy). The following findings are listed in the histopathological scoring table in 'Table 1'.

Inflammatory cells IR Group: (75.0) Medium, AM+IR Group: (75.0) Medium, AM Group: (75.0) Light, Gliocytes hyperplasia IR Group: (87.5) Heavy, AM+IR Group: (75.0) Medium, AM Group: (75.0) Light, Neuron swelling IR Group: (87.5) Heavy, AM+IR Group: (75.0) Medium, AM Group: (87.5) Light, Spinal cord cavitation IR Group: (100.0) Heavy, AM+IR Group: (75.0) Medium, AM Group: (87.5) Light, Nissl body loss IR Group: (87.5) Heavy, AM+IR Group: (87.5) Medium, AM Group: (100.0) Light, Cavitation around the nucleus IR Group: (75.0) Heavy, AM+IR Group: (75.0) Medium, AM Group: (87.5) Light, Pyknotic nuclei IR Group: (87.5) Heavy, AM+IR Group: (62.5) Medium, AM Group: (87.5) Light, Edema IR Group: (75.0) Heavy, AM+IR Group: (75.0) Light, AM Group: (87.5) Light.

### Statistical Analysis

All analyses were performed on Statistical Package for the Social Sciences v21 (SPSS Inc., Chicago, IL, USA). For the normality assessment, the Kolmogorov-Smirnov test was used. Data are given as mean  $\pm$  standard deviation or median (1<sup>st</sup> quartile–3<sup>rd</sup> quartile) for continuous variables according to normality of distribution and frequency (percentage) for categorical variables. Normally distributed variables were

analyzed with one-way analysis of variance test. Post-hoc Tukey test was used to determine the significant difference. Non-normally distributed variables were analyzed with Kruskal Wallis test. Pairwise comparisons were performed with the Bonferroni correction method. Categorical variables were evaluated using the Pearson's Chi-square test.  $P < 0.05$  values were accepted as statistically significant results.

## RESULTS

### Histopathological Findings

All irradiated animals remained clinically well and neurologically intact in the duration of the study. On H&E-stained sections, the spinal cord of all groups remained grossly normal. Hemorrhage was not observed, and no gross vascular lesions were apparent.

Group-1 (control) had normal structure without histopathological changes in the spinal cord tissues (Figure 1A).

Minimal changes were detected in Group-2 (AM). Inflammatory cells infiltration and edema were elevated compared to control. Necrosis was noted in the AM group and was higher compared to the control (Figure 1B-1D).

Radiation damage in the spinal cords of irradiated animals was confirmed.

Irradiated group shows inflammatory cells infiltration and edema at most severe levels, as well as neuron swelling, gliocytes hyperplasia, spinal cord cavitation (loosened tissue structure), pyknotic nuclei, vacuolar denaturation, and Nissl body loss. Neuron swelling was higher compared to AM group. Necrosis was also present in this group that was higher compared to Control and AM treated group. Findings were at the most severe level in Group-3 (IR) (Figure 3).

All parameters verified in the IR group were present at a lower score in the irradiated group that received AM treatment (AM + IR) (Figure 2).

The calculated histopathological scores are shown in Table 1.

## DISCUSSION

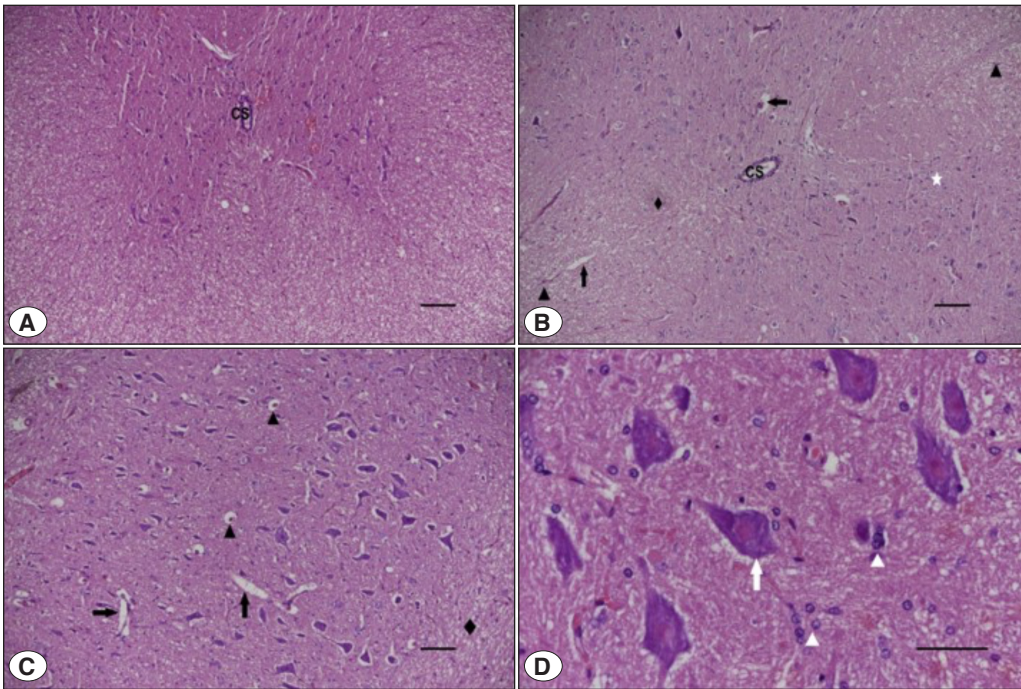
In the current study, the effect of IR on the spinal cord and the defensive abilities of AM were investigated. In previous studies, a wide spectrum of histopathological changes such as demyelination, white matter necrosis, telangiectasias, and glial atrophy has been described (15,16). In this current study, radiation damage in the spinal cords of irradiated animals was observed, and histopathological findings are evaluated at the highest score rate. Histopathological changes of IR injury include inflammatory cells infiltration, edema, neuron swelling, hyperplastic gliocytes, spinal cord cavitation, pyknotic nuclei, vacuolar denaturation, and Nissl body loss.

**Table 1:** Calculated histopathological scores.

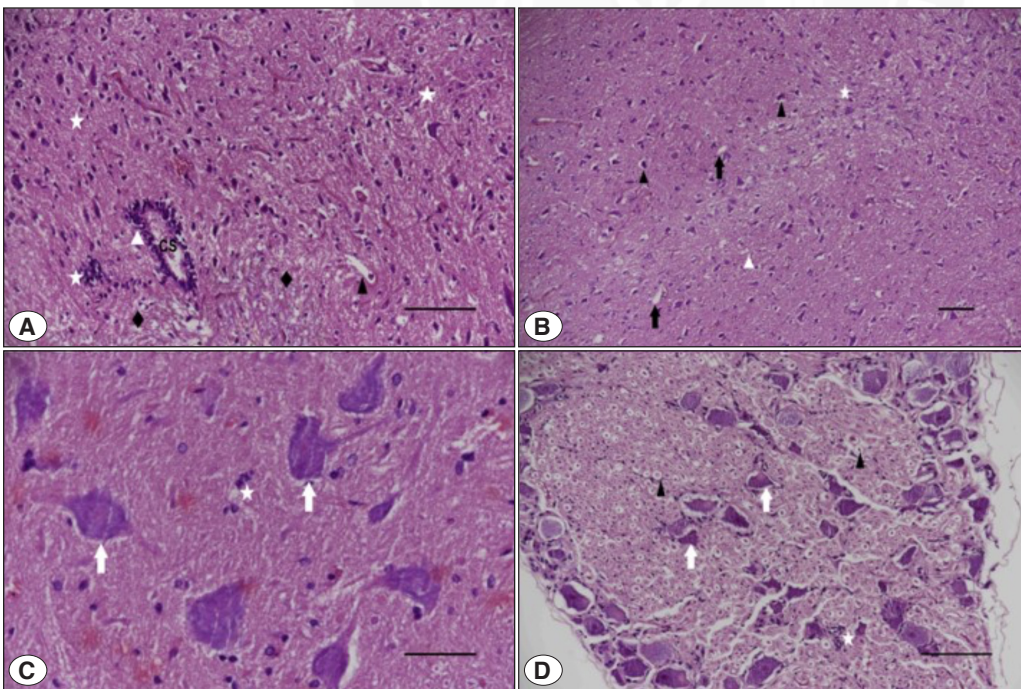
Histopathological scores	Treatment group				P
	Control (n=8)	AM (n=8)	IR (n=8)	AM+IR (n=8)	
Inflammatory cells*	0 (0-0)	1 (1-1.5)a	2 (2-2)a	2 (2-2)a	<0.001
Normal**	13 (100.0)	0 (0.0)	0 (0.0)	0 (0.0)	<0.001
Light**	0 (0.0)	6 (75.0)	1 (12.5)	1 (12.5)	
Medium**	0 (0.0)	2 (25.0)	6 (75.0)	6 (75.0)	
Heavy**	0 (0.0)	0 (0.0)	1 (12.5)	1 (12.5)	
Gliocytes hyperplasia*	0 (0-0)	1 (1-1.5)	3 (3-3)a	2 (2-2)a	<0.001
Normal**	13 (100.0)	0 (0.0)	0 (0.0)	0 (0.0)	<0.001
Light**	0 (0.0)	6 (75.0)	0 (0.0)	1 (12.5.0)	
Medium***	0 (0.0)	2 (25.0)	1 (12.5.0)	6 (75.0)	
Heavy**	0 (0.0)	0 (0.0)	7 (87.5.0)	1 (12.5.0)	
Neuron swelling*	0 (0-0)	1 (1-1)	3 (3-3)ab	2 (2-2)a	<0.001
Normal**	13 (100.0)	0 (0.0)	0 (0.0)	0 (0.0)	<0.001
Light**	0 (0.0)	7 (87.5)	0 (0.0)	1 (12.5)	
Medium**	0 (0.0)	1 (12.5)	1 (12.5)	6 (75.0)	
Heavy**	0 (0.0)	0 (0.0)	7 (87.5)	1 (12.5)	
Necrosis*	0 (0-0)	1 (1-1.5)a	2 (2-2)a	0 (0-0)bc	<0.001
Normal**	13 (100.0)	0 (0.0)	0 (0.0)	8 (100.0)	<0.001
Light**	0 (0.0)	6 (75.0)	0 (0.0)	0 (0.0)	
Medium**	0 (0-0)	1 (1-1)	2 (2-2)	2 (2-2.5)	
Spinal cord cavitation*	0 (0-0)	1 (1-1)	2 (2-2)a	2 (2-2.5)a	<0.001
Normal**	13 (100.0)	0 (0.0)	0 (0.0)	0 (0.0)	<0.001
Light**	0 (0.0)	7 (87.5)	0 (0.0)	0 (0.0)	
Medium**	0 (0.0)	1 (12.5)	8 (100.0)	6 (75.0)	
Heavy**	0 (0.0)	0 (0.0)	0 (0.0)	2 (25.0)	
Nissl body loss*	0 (0-0)	1 (1-1)c	3 (3-3)a	2 (2-2)a	<0.001
Normal**	13 (100.0)	0 (0.0)	0 (0.0)	0 (0.0)	<0.001
Light**	0 (0.0)	8 (100.0)	0 (0.0)	0 (0.0)	
Medium**	0 (0.0)	0 (0.0)	1 (12.5)	7 (87.5)	
Heavy**	0 (0.0)	0 (0.0)	7 (87.5)	1 (12.5)	
Cavitation around the nucleus*	0 (0-0)	1 (1-1)	3 (2.5-3)a	2 (2-2.5)a	<0.001
Normal**	13 (100.0)	0 (0.0)	0 (0.0)	0 (0.0)	<0.001
Light**	0 (0.0)	7 (87.5)	0 (0.0)	0 (0.0)	
Medium**	0 (0.0)	1 (12.5)	2 (25.0)	6 (75.0)	
Heavy**	0 (0.0)	0 (0.0)	6 (75.0)	2 (25.0)	
Pyknotic nuclei*	0 (0-0)	1 (1-1)		2 (1.5-2)a	<0.001
Normal**	13 (100.0)	0 (0.0)	0 (0.0)	0 (0.0)	<0.001
Light**	0 (0.0)	7 (87.5)	0 (0.0)	2 (25.0)	
Medium**	0 (0.0)	1 (12.5)	1 (12.5)	5 (62.5)	
Heavy**	0 (0.0)	0 (0.0)	7 (87.5)	1 (12.5)	
Edema*	0 (0-0)	1 (1-1)a	3 (2.5-3)a	1 (1-1.5)a	<0.001
Normal**	13 (100.0)	0 (0.0)	0 (0.0)	0 (0.0)	<0.001
Light**	0 (0.0)	7 (87.5)	0 (0.0)	6 (75.0)	
Medium**	0 (0.0)	1 (12.5)	2 (25.0)	2 (25.0)	
Heavy**	0 (0.0)	0 (0.0)	6 (75.0)	0 (0.0)	

Data were given as \* median (1<sup>st</sup> quartile - 3<sup>rd</sup> quartile) for continuous variables and n(%), \*\*as frequency (percentage, n(%)) for categorical variables. a, b, c Significantly different from the control group and AM treated group, IR group respectively.

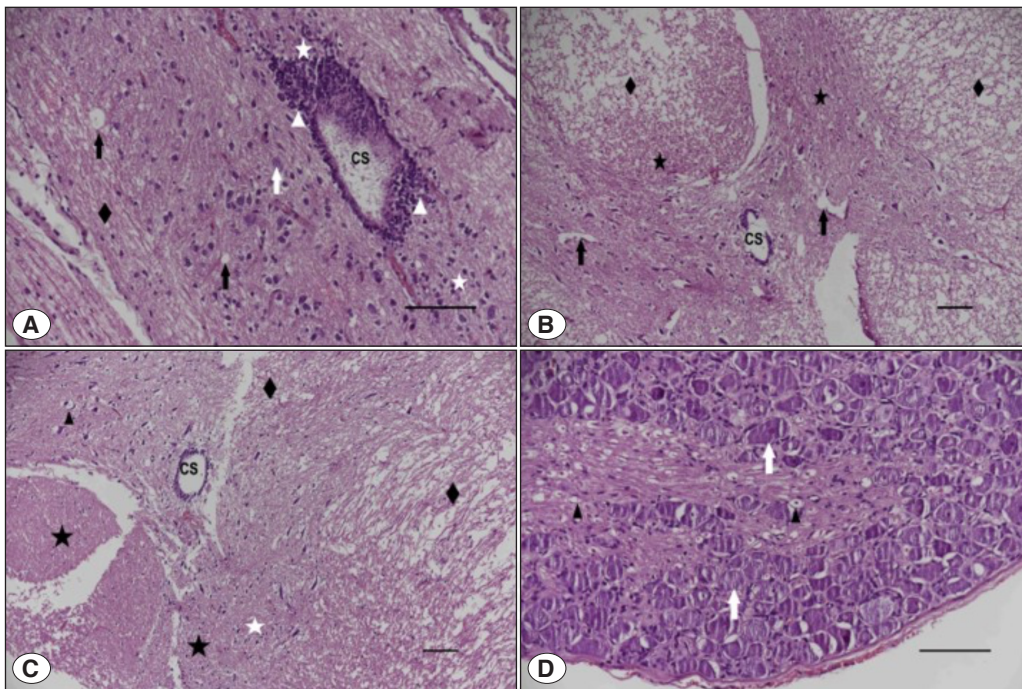
**AM:** Annonamuricata, **IR:** Irradiation.



**Figure 1:** Representative photomicrographs of spinal cord sections showing; **A)** control group (G1) with normal histological features demonstrating evenly spaced well preserved neurons (H&E, Scale Bar:200 $\mu$ m); **B-D)** Graviola group (G2) with light degeneration in the gray matter (H&E, Scale Bar:200  $\mu$ m, 200 $\mu$ m, 50  $\mu$ m) White arrow, light neuron swelling, light lost of nissl substance; black arrow, light repair holes; white asterisk, light inflammatory cell; black diamond, light edema; white triangle, light gliocytes hyperplasia; black triangle, light picnotic nuclei and light cavitation around the nucleus; **CS:** Central channel.



**Figure 2:** Spinal cord tissue morphology in Graviola+ 20GyRT group(G3) **A-D)** with medium degeneration (H&E,Scale Bar:100 $\mu$ m,200 $\mu$ m,50 $\mu$ m,100 $\mu$ m) White arrow, medium neuron swelling and lost of nissl substance; black arrow, medium repair holes; white asterisk, medium inflammatory cell; black diamond, light edema; white triangle, medium gliocytes hyperplasia; black triangle, medium picnotic nuclei and cavitation around the nucleus, **CS:** Central channel.



**Figure 3:** Spinal cord tissue morphology in 20 Gy RT group (G4) **A-D** with high degeneration (H&E, ScaleBar: 100 $\mu$ m, 200 $\mu$ m, 200 $\mu$ m, 100 $\mu$ m) White arrow, heavy neuron swelling and lost of nissl substance; black arrow, medium repair holes; black diamond, heavy edema; white asterisk, medium inflammatory cell; black asterisk, medium necrosis; white triangle, heavy gliocytes hyperplasia; black triangle, heavy picnotic nuclei and cavitation around the nucleus, **CS:** Central channel.

Inflammatory cells infiltration and edema were decreased in AM treated IR group, thus, the use of AM prior to IR may be effective in reducing inflammation and edema in radiation-induced spinal cord injury. These findings are in accordance with other studies proving the anti inflammation properties of AM (17, 18).

In the current study, IR caused neuronal swelling in the spinal cord that was scored as heavy. Cytotoxic edema most commonly results from energy shortage that refers to the swelling of brain cells due to the entry of water from the extracellular space (19). The neuroprotective abilities of AM (20) lowered the neuron swelling score, preventing cytotoxic edema.

In accordance with other studies, IR caused cavitation in the spinal cord sections (21, 22). In this current study, degeneration and cavitation were prevented in AM treated rats to a variable degree compared with untreated rats.

Nissl body loss and pyknosis are also often seen as histopathological findings in irradiated spinal cords in experiments with animals and humans (23). Pyknotic nuclei are impotent morphological criterion for apoptosis. Radiation-induced apoptosis has been reported in Irradiated spinal cord (24), and the number of apoptotic cells in irradiated group significantly Increased in this current study. In addition, treatment of rats with AM before IR was determined to

inhibit radiation- induced apoptosis. The healthy group treated with AM shows a light scoring level of pyknotic nuclei. In literature, AM leaf extract was proven to induce apoptosis (10, 25); however, a very low level of spontaneous apoptosis observed in the rat spinal cord was considered to be part of the over all homeostatic process that regulates cell.

Proliferation and controls cell number at ascertain level. One of the limitations of this study is the absence of biochemical evidence and immune histochemical apoptosis evaluation.

Okada and Okeda reported in their review paper that white matter necrosis developed at 15 Gy (26). In accordance to our study, other similarly-designed studies confirm that IR caused radiation-induced necrosis (27,28). The pre-radiation administration of AM appears to ameliorate these changes, as determined by mild histopathological findings in the AM + IR group. Furthermore, our results showed that the treatment of rats with AM prior to IR prevented necrotic damages in the spinal cord compared to the control group. Blood vessel also can be affected in radiation myelopathy (26); however, the lack of evaluation of varying degrees of vascular changes in both white and gray matter is another limitation of this study. Necrosis was also noted in the AM group that was higher compared to the control. This made us suspect that AM 300 mg/kg may have a toxic effect in healthy rats. The use of all parts of the plant is considered very safe; however, literature studies reported its toxicity

(29). Further studies are needed to confirm the toxic effect of AM on the spinal cord of healthy rats.

More investigation in this field is needed to better clarify the mechanisms of AM in radiation-induced spinal cord injury and its relation to histopathological alterations; however, data from our study suggest that pretreatment with 300 mg/kg concentrations of AM leaf extract prior to IR reduced inflammatory cells infiltration, edema, and neuron swelling, supporting the proposed AM anti-inflammatory property that may contribute to neuroprotection. 300 mg/kg was given as in the study 'The neuroprotective and anti-inflammatory effects of *Annona muricata* (Graviola) on radiation-induced rat sciatic nerve injury'.

Similarly, we documented that AM had efficient protection on neural cells from apoptosis or necrosis.

However, further studies are needed to approve the use of this plant as a protective medicine in humans before and during IR and further toxicity testing should be conducted to confirm its safe usage.

#### Acknowledgment

None.

#### Author Contributions

Concept, design, data collection, analysis and interpretation of the article: **Özlem Elmas**, Design: **Havva Hande Keser Şahin**, Data collection: **Özlem Apsar Başaran**, Analysis and interpretation **Emrah Keskin**.

#### Conflicts of Interest

There is no conflict of interest between the authors.

#### Financial Support

No financial support was received from any institution.

#### Ethical Approval

The study's ethics committee approval was obtained from the Zonguldak Bülent Ecevit University Experimental Animals Ethics Committee.

(Meeting date: 02/07/2020 and Meeting number: 2020/06 and Decision number: 2020-18-02/07)

#### Review Process

Extremely and externally peer-reviewed.

## REFERENCES

- Barton MB, Jacob S, Shafiq J, Wong K, Thompson SR, Hanna TP, Delaney GP. Estimating the demand for radiotherapy from the evidence: a review of changes from 2003 to 2012. *Radiother Oncol*. 2014 Jul;112(1):140-4.
- Poortmans P, Valentini V, Lievens Y. Expanding global access to radiotherapy: the European Society for Radiotherapy and Oncology perspective. *Lancet Oncol*. 2015 Sep;16(10):1148-9.
- Kirkpatrick JP, van der Kogel AJ, Schultheiss TE. Radiation dose-volume effects in the spinal cord. *Int J Radiat Oncol Biol Phys*. 2010 Mar 1;76(3 Suppl):S42-9.
- Klimo P Jr, Thompson CJ, Kestle JR, Schmidt MH. A meta-analysis of surgery versus conventional radiotherapy for the treatment of metastatic spinal epidural disease. *Neuro Oncol*. 2005 Jan;7(1):64-76.
- Fischer, A.W., Holfelder Lokales Amyloid im Gehirn. *Deutsche Zeitschrift f. Chirurgie* 227, 475–483 (1930).
- Schultheiss TE. The radiation dose-response of the human spinal cord. *Int J Radiat Oncol Biol Phys*. 2008 Aug 1;71(5):1455-9.
- Wong CS, Fehlings MG, Sahgal A. Pathobiology of radiation myelopathy and strategies to mitigate injury. *Spinal Cord*. 2015 Aug;53(8):574-80.
- Schultheiss TE, Stephens LC, Maor MH. Analysis of the histopathology of radiation myelopathy. *Int J Radiat Oncol Biol Phys*. 1988 Jan;14(1):27-32.
- Moghadamtousi SZ, Fadaeinasab M, Nikzad S, Mohan G, Ali HM, Kadir HA. *Annona muricata* (Annonaceae): A Review of Its Traditional Uses, Isolated Acetogenins and Biological Activities. *Int J Mol Sci*. 2015 Jul 10;16(7):15625-58.
- Chan WJ, McLachlan AJ, Hanrahan JR, Harnett JE. The safety and tolerability of *Annona muricata* leaf extract: a systematic review. *J Pharm Pharmacol*. 2020 Jan;72(1):1-16.
- Akhondzadeh S, Naghavi HR, Vazirian M, Shayeganpour A, Rashidi H, Khani M. Passionflower in the treatment of generalized anxiety: a pilot double-blind randomized controlled trial with oxazepam. *J Clin Pharm Ther*. 2001 Oct;26(5):363-7.
- Souza DO, Dos Santos Sales V, de Souza Rodrigues CK, de Oliveira LR, Santiago Lemos IC, de Araújo Delmondes G, Monteiro ÁB, do Nascimento EP, Sobreira Dantas Nóbrega de Figueiredo FR, Martins da Costa JG, Pinto da Cruz GM, de Barros Viana GS, Barbosa R, Alencar de Menezes IR, Bezerra Felipe CF, Kerntopf MR. Phytochemical Analysis and Central Effects of *Annona Muricata* Linnaeus: Possible Involvement of the Gabaergic and Monoaminergic Systems. *Iran J Pharm Res*. 2018 Fall;17(4):1306-1317.
- Champy P, Höglinger GU, Féger J, Gleye C, Hocquemiller R, Laurens A, Guérineau V, Laprêvotte O, Medja F, Lombès A, Michel PP, Lannuzel A, Hirsch EC, Ruberg M. Annonacin, a lipophilic inhibitor of mitochondrial complex I, induces nigral and striatal neurodegeneration in rats: possible relevance for atypical parkinsonism in Guadeloupe. *J Neurochem*. 2004 Jan;88(1):63-9.
- Mansour H.H., Elkady A.A., Elrefaei A.H., Hafez H.F. Radioprotective, antioxidant and antitumor efficacy of *Annona muricata* L. leaf extract. *Indian J Biochem Biophys*. 2018;55:205–214.
- Schultheiss TE, Kun LE, Ang KK, Stephens LC. Radiation response of the central nervous system. *Int J Radiat Oncol Biol Phys*. 1995 Mar 30;31(5):1093-112. Erratum in: *Int J Radiat Oncol Biol Phys*. 1995 Jul 15;32(4):1269.
- Li YQ, Chen P, Jain V, Reilly RM, Wong CS. Early radiation-induced endothelial cell loss and blood-spinal cord barrier breakdown in the rat spinal cord. *Radiat Res*. 2004 Feb;161(2):143-52.
- de Sousa OV, Vieira GD, de Jesus R G de Pinho J, Yamamoto CH, Alves MS. Antinociceptive and anti-inflammatory activities of the ethanol extract of *Annona muricata* L. leaves in animal models. *Int J Mol Sci*. 2010 May 6;11(5):2067-78.



18. Ishola IO, Awodele O, Olusayero AM, Ochieng CO. Mechanisms of analgesic and anti-inflammatory properties of *Annona muricata* Linn. (Annonaceae) fruit extract in rodents. *J Med Food*. 2014 Dec;17(12):1375-82.
19. Dijkstra K, Hofmeijer J, van Gils SA, van Putten MJ. A Biophysical Model for Cytotoxic Cell Swelling. *J Neurosci*. 2016 Nov 23;36(47):11881-11890.
20. Kim WS, Kim YE, Cho EJ, Byun EB, Park WY, Song HY, Kim K, Park SH, Byun EH. Neuroprotective effect of *Annona muricata*-derived polysaccharides in neuronal HT22 cell damage induced by hydrogen peroxide. *Biosci Biotechnol Biochem*. 2020 May;84(5):1001-1012.
21. Kalderon N, Fuks Z. Structural recovery in lesioned adult mammalian spinal cord by x-irradiation of the lesion site. *Proc Natl Acad Sci U S A*. 1996 Oct 1;93(20):11179-84. Erratum in: *Proc Natl Acad Sci U S A* 1996 Dec 10;93(25):14992.
22. LeRoux LG, Bredow S, Grosshans D, Schellingerhout D. Molecular imaging detects impairment in the retrograde axonal transport mechanism after radiation-induced spinal cord injury. *Mol Imaging Biol*. 2014 Aug;16(4):504-10.
23. Sotoudeh A, Jahanshahi A, Zareiy S, Darvishi M, Roodbari N, Bazzazan A. The influence of low-level laser irradiation on spinal cord injuries following ischemia-reperfusion in rats. *Acta Cir Bras*. 2015 Sep;30(9):611-6.
24. Li YQ, Guo YP, Jay V, Stewart PA, Wong CS. Time course of radiation-induced apoptosis in the adult rat spinal cord. *Radiother Oncol*. 1996 Apr;39(1):35-42.
25. Moghadamtousi SZ, Kadir HA, Paydar M, Rouhollahi E, Karimian H. *Annona muricata* leaves induced apoptosis in A549 cells through mitochondrial-mediated pathway and involvement of NF- $\kappa$ B. *BMC Complement Altern Med*. 2014 Aug 15;14:299.
26. Okada S, Okeda R. Pathology of radiation myelopathy. *Neuropathology*. 2001 Dec;21(4):247-65.
27. Okada S, Okeda R, Matsushita S, Kawano A. Histopathological and morphometric study of the late effects of heavy-ion irradiation on the spinal cord of the rat. *Radiat Res*. 1998 Sep;150(3):304-15.
28. Schultheiss TE, Stephens LC. Radiation Myelopathy. *AJNR Am J Neuroradiol*. 1992 Jul-Aug;13(4):1056-8.
29. Ana V, Coria-Téllez, Efigenia Montalvo-González, Elhadi M. Yahia, Eva N. Obledo-Vázquez *Annona muricata*: A comprehensive review on its traditional medicinal uses, phytochemicals, pharmacological activities, mechanisms of action and toxicity. *Arabian Journal of Chemistry*. 2018;11(5): 662- 91.
30. Keskin, E., Elmas, O., Keser Sahin, H. H., Tonge, C., et al. (2022). The neuroprotective and anti-inflammatory effects of *Annona muricata* (Graviola) on radiation-induced rat sciatic nerve injury. *Marmara Medical Journal*, 35(2), 211-218.