

RESEARCH ARTICLE

The Effect of Ticagrelor on Survival of Skin Flap in Rat Model

Ali Riza Yildirim¹, Mehmet Tapan², Hasan Murat Ergani³

¹ARY Clinic, Aesthetic Plastic Surgery, Istanbul, Türkiye

²Akdeniz University Medical School, Department of Plastic Surgery, Antalya, Türkiye

³Sağlık Bilimleri University Ankara City Hospital, Department of Plastic Surgery, Ankara, Türkiye

Abstract

Introduction: Necrosis due to ischemia at the distal end of a flap is an important problem encountered during flap operations. Several procedures and drugs including delayed procedures, leeches, and anticoagulants, can be used to maintain flap viability. **Methods:** Sixteen rats were randomly divided into two groups of eight: the ticagrelor and the control groups. Rats in the ticagrelor group were administered ticagrelor diluted with 0.3 mL of saline at a dose of 10 mg/kg twice a day for 7 days, starting at 2 h preoperatively and 10 h postoperatively, by oral gavage. Similar stress in the control group was induced orally with saline solution at the same time. The results were statistically analyzed for both clinical and histopathological evaluations. **Results:** During the clinical examination, the area of necrosis and the entire flap area were measured using transparent acetate paper (grid method). In the histopathological examination, tissue samples were taken from the transition zone between necrotic tissue and intact tissue in the flaps of rats sacrificed on the 7th day. There were significant differences in clinical evaluation. ($p < 0,05$) The mean and SD of necrosis were $15,65 \pm 1,84$ cm² in the control group and $8,59 \pm 3,75$ cm² in ticagrelor group. There were no significant differences ($p > 0,05$) in the histopathological examinations; however, compared with the control group, fewer inflammatory cells and necrosis were observed in the ticagrelor group. **Conclusion:** We found a statistically significant difference in clinical outcomes with the use of ticagrelor. However, no significant differences were found in the histopathological observations. Our results suggest that ticagrelor is effective on survival of skin flaps of rats in clinical evaluation.

Article Info

Received Date:24.06.2023

Revision Date: 24.07.2023

Accepted Date:01.08.2023

Keywords:

Flap Viability, Necrosis,
Rat Flap, Ticagrelor

Correspondence Address: Dumlupınar Boulevard Number: 5 Akdeniz University Hospital
Block B 2nd Floor 07058 Antalya - Türkiye **Phone:** +90 2422496000 / **e-mail:** drmtapan@gmail.com

Follow this and additional works at: <https://achmedicaljournal.com>

Introduction

Flaps are used to repair tissue defects during plastic and reconstructive surgeries. When a flap is harvested, its circulation is disrupted. Sympathetic innervation is acutely lost, and neurotransmitters that cause vasoconstriction are released spontaneously.¹ One of the important problems encountered in flap operations is necrosis due to ischemia at the distal end of the flap. In the literature, several procedures and drugs have been shown to maintain flap viability, such as delayed procedures, leeches, and anticoagulants.²⁻⁶ Ticagrelor is an oral P2Y₁₂ inhibitor that selectively and reversibly binds adenosine diphosphate (ADP) receptor antagonists on the ADP receptor. It has vasodilator, antiplatelet, and antithrombotic effects.^{7,8} However, the effect of ticagrelor on random-pattern skin flaps was not investigated. Here, we designed to examine whether these features of ticagrelor have positive effects on the viability of random-pattern skin flaps according to previous studies.⁹⁻¹²

Material and Methods

All animal experiments were approved by the Institutional Animal Care and Use Committee (Decision Number: 2016-9-101). Sixteen Wistar albino rats, weighing 200–300 g, were used. The rats were randomly divided into two groups of eight: ticagrelor and control groups. The animals in the ticagrelor group were administered ticagrelor (Brilinta, AstraZeneca, UK) diluted in 0.3 ml of saline at a dose of 10 mg/kg twice a day for 7 days, starting at 2 h preoperatively and 10 h postoperatively, by oral gavage. To induce similar stress in the animals in the first group, the same volume of saline was administered orally at the same time.

The subjects were anesthetized by administering intramuscular ketamine hydrochloride (Ketalar, Pfizer) and xylazine hydrochloride (Rompun, Bayer). The surgical field was prepared under anesthesia. The rats were placed in a prone position. A 3 × 10 cm caudal-based McFarlane flap¹³ was planned and elevated from the dorsum of each rat. The flap was then adapted to its location using a running technique with a 3/0 polyglactin (Vicryl, Ethicon) suture not to occur a wound dehiscence.

The results were examined by clinical evaluation, including planimetric measurement and Image J program (USA), and histopathologic evaluation. Statistical analyses were performed using SPSS software version 20.0 (IBM, USA). While performing the

data analysis, the Independent 2-group t-test (Student's t-test) was used for the comparison of the two groups, and the Mann Whitney-U test was used if the prerequisites were met. Categorical contents were analyzed with Fisher's Exact Test and Chi-Square test. The rats were sacrificed on the 7th day and were photographed at a distance of 40 cm. Images were transferred to the Image J program. The reason which was chosen the 7th day that new anastomoses formed between a flap and a recipient site become active from the 5th-7th day. From the 7th day, there is no increase in vascularization.¹⁴ It was an enough period for demarcation area. The area of necrosis and the entire flap area were measured using a transparent acetate paper (grid method). Although all flaps were planned to be the same size, the ratio of the necrotic area to the flap was used as flap contraction of each rat may be different during the wound healing process. Thus, this ratio was used to avoid errors due to contraction during wound healing. The percentage values were calculated. (Figure 1)

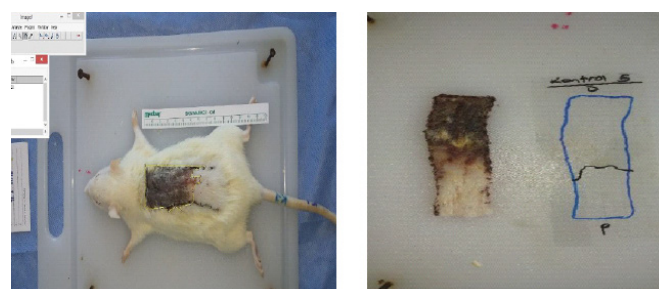


Figure 1: Clinical Evaluation of The Rats

Full thickness tissue samples taken from the transition zone between necrotic and intact tissue in the flaps of rats sacrificed on the 7th day were preserved under appropriate conditions. The transition zone was preferred because it has a tendency to necrosis or healing process. Tissue samples were fixed in 10% buffered formalin solution. They which were dehydrated by passing through graded alcohols were taken into xylene and kept until their transparency was completed. After 5 hours of liquid paraffin infiltration in a 60°C oven after clearing, the tissues were embedded in hard paraffin blocks. The blocks were kept in the refrigerator at +4°C. Before starting the cutting process, 4 µm sections were taken from the blocks, which were taken to -18°C, with a microtome. Sections were stained with Hematoxylin Eosin and

Mallory Azan histological stains. The sections were stained with Hematoxylin Eosin and Mallory Azan histological scales. Polymorphonuclear leukocyte and lymphocyte density, edema in the papillary dermis, extravasated erythrocytes, and edema in the reticular dermis were evaluated with scores from 0 to 4 according to their respective quantities. (Table 1)

Table 1: The Histopathologic Evaluation

	None	Few	Average	Dense	Very dens
Polymorphonuclear leukocyte and lymphocyte density	0	1+	2+	3+	4+
Edema in the Papillary Dermis	0	1+	2+	3+	4+
Extravasated Erythrocytes	0	1+	2+	3+	4+
Edema in the Reticular Dermis	0	1+	2+	3+	4+

Results

Overall, 14 rats survived and were evaluated. The groups were evaluated both clinical and histopathological results.

Clinical evaluation

The quantity of necrosis was different during the inspection. (Figure 2) Contraction developed in all flaps after 7 days postoperatively, and total flap surface area at 7th day between the two groups were statistically different. (p=0,005) The percentages determined after data from planimetric measurements and Image J program were compared between the ticagrelor and control groups, and it was found that in the ticagrelor group, flap necrosis rates were statistically lower than in the control group. (p=0,002) (Table 2)

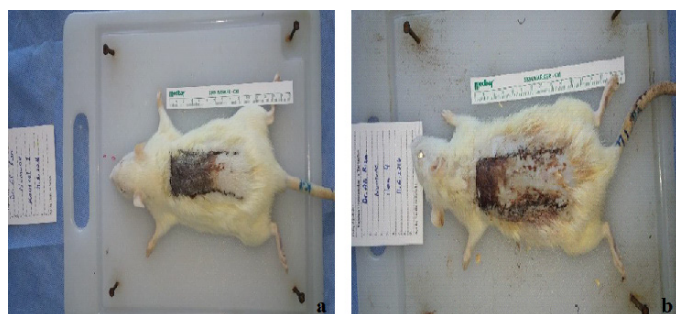


Figure 2.
a) One of The Control Group Rats at 7th Day.
b) One of The Ticagrelor Group Rats at 7th Day.

Table 2: Statistical Analysis of The Clinical Evaluation of The Clinical Evaluation

Group	n	Mean value	Standard deviation	Standard error	p value	
Total surface area at 7th day (mm)	Control	7	2812,286	56,257	21,263	0,005
	Ticagrelor	7	2648,429	111,747	42,236	
Necrotic area (mm)	Control	7	1565,143	184,960	69,908	0,002
	Ticagrelor	7	859,286	375,815	142,045	

Histopathological evaluation

Inflammatory cells and necrosis were observed less frequently in the ticagrelor-treated group than in the control group. (Figure 3) However, no significant differences were observed between the histopathological scores of the groups. (Table 3)

Table 3. Statistical Analysis of The Histopathologic Evaluation

	Polymorphonuclear leukocyte and lymphocyte density	Edema in the Papillary Dermis	Extravasated Erythrocytes	Edema in the Reticular Dermis
Treatment group (n=7)	2.0	0.85	0.71	0.85
Control group (n=7)	2.71	1.0	1.0	1.0
p	0,255	0,317	0,287	0,299

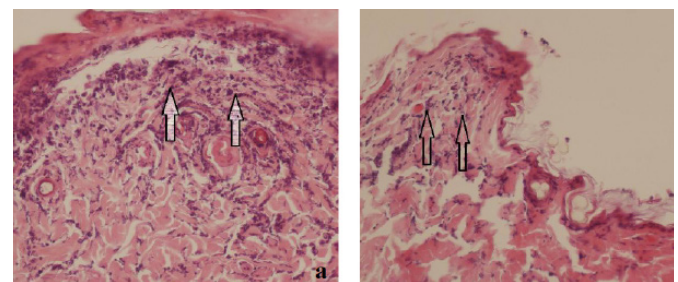


Figure 3: Polimorphonuclear Leucoyst Infiltration of The Control Group b) Less Intense PMNL Infiltration Was Observed in The Ticagrelor Group .

Discussion

In random pattern skin flaps, the blood supply is through the superficial plexus, and the flaps can be harvested using the 2:1 length:width ratio rule. As this ratio increases, the probability of necrosis also increases. When necrosis occurs, undesirable results, such as additional surgical interventions, increased hospital stay, and increased treatment costs, are encountered. In this context, it is clinically important to increase the viable part of the flap

by reducing ischemia-reperfusion damage that develops in the distal part of the random pattern flaps.^{15,16}

As soon as the flap is harvested, vasoconstriction occurs owing to adrenaline, noradrenaline, thromboxane A², and prostaglandin F² α .¹⁷ Afterwards, the perfusion of the flap decreases with the cutting of the surrounding vessels, and intravascular thrombosis formation increases owing to mechanical damage to the vascular endothelium. Platelet aggregation, intravascular thrombosis, and ultimately flap necrosis may occur in vessels with endothelial damage.^{7,18} Therefore, vasodilators, antithrombotic agents, agents that prevent neutrophil aggregation and adhesion, anti-inflammatory agents, and antioxidant agents have been used.^{19,20}

Ticagrelor is prescribed to reduce the risk of first myocardial infarction or stroke in patients with coronary artery disease at a high risk for these events, such as patients with type 2 diabetes, to reduce the rate of thrombotic cardiovascular events in patients with acute coronary syndrome, and to reduce the risk of stroke in patients with acute ischemic stroke or high-risk transient ischemic attack.²¹ However, various anticoagulant and antiaggregant agents have been studied to increase blood flow in skin flaps and prevent ischemia, but no previous study has examined the effect of ticagrelor in increasing the viability of random pattern flaps. In our study, the dose of ticagrelor was preferred considering the effective doses in studies on the inhibition of vascular smooth muscle contraction,²² protection of the heart from reperfusion injury after myocardial infarction,²³ and reduction of platelet activation in diabetic rats.²⁴ However, further research can be conducted using variable doses and applications.

Compared to clopidogrel, ticagrelor has faster, more potent, and more consistent effects.²⁵ Studies have also shown that ticagrelor, which increases the plasma concentration of adenosine, is superior to clopidogrel in preventing no-reflow.²⁶ According to literature, the viability of random skin flaps in rats is increased by the use of clopidogrel.^{6,27} In our study, necrotic area in the ticagrelor group was lower than low-molecular weight heparin, combined therapy group and clopidogrel group in the study of Fatemi et al.²⁷ Our results showed that ticagrelor had a similar effect in improving the viability of random skin flaps.

Conclusion

We found a statistically significant difference in clinical outcomes with the use of ticagrelor. However, no significant differences were found

in the histopathological observations. A limitation of this study is the fact that histopathological examination of the transition zone is a subjective. However, further research is required.

Acknowledgements

The authors thank to Ramazan Erkin Ünlü for scientific contribution and mentorship.

Presented as an oral presentation at the 16th National 4th International Wound Congress in Antalya.

Ethics Committee Approval:

The Decision Number of Local Ethical Committee approval at Ankara University Animal Experimentation Ethical Committee was 2016-9-101.

Conflict of Interest:

The authors declare no conflict of interest associated with this manuscript. can be shared on demand if any concern rises due to the reliability of the data but according to the ethical and legal regulations in Turkey the authors can not share the data via a data repository.

References

- 1- Banbury J, Siemionow M, Porvasnik S, Petras S, Zins JE. Muscle flaps' triphasic microcirculatory response to sympathectomy and denervation. *Plast Reconstr Surg.* 1999;104:730-7.
- 2- Boyd JB, Markland B, Dorion D, Pang CY, Morris S. Surgical augmentation of skin blood flow and viability in a pig musculocutaneous flap model. *Plast Reconstr Surg.* 1990;86:731-8
- 3- Lee C, Mehran RJ, Lessard ML, Kerrigan CL. Leeches: controlled trial in venous compromised rat epigastric flaps. *Br J Plast Surg.* 1992;45:235-8.
- 4- Maeda, M., A. Fukui, and S. Tamai, Combined therapy with antithrombotic agents and radical scavengers for reperfusion injury of flaps. *J Reconstr Microsurg,* 1991;7:233-43.
- 5- Shalom, A. and M. Westreich, Effect of high dose and low dose aspirin on survival of random pattern flaps in rats. *Scand J Plast Reconstr Surg Hand Surg,* 2001;35:117-21.
- 6- Ersoy A, Sevin K, Sevin A, Serel S. Effects of clopidogrel on survival of rat skin flaps. *J Plast Reconstr Aesthet Surg.* 2007;60:861-3.
- 7- Wittfeldt A, Emanuelsson H, Brandrup-Wognsen G, van Giezen JJJ, Jonasson J, Nylander S, et al. Ticagrelor enhances adenosine-induced coronary vasodilatory responses in humans. *J Am Coll Cardiol.* 2013;61:723-7.

- 8- Orme RC, Parker WAE, Thomas MR, Judge HM, Baster K, Sumaya W, et al. Study of Two Dose Regimens of Ticagrelor Compared with Clopidogrel in Patients Undergoing Percutaneous Coronary Intervention for Stable Coronary Artery Disease (STEEL-PCI). *Circulation*. 2018;138:1290–300.
- 9- Wu H, Ding J, Wang L, Lin J, Li S, Xiang G, Jiang L, Xu H, Gao W, Zhou K. Valproic acid enhances the viability of random pattern skin flaps: involvement of enhancing angiogenesis and inhibiting oxidative stress and apoptosis. *Drug Des Devel Ther*. 2018;12:3951-60.
- 10- Oztürk CN, Tezel E, Yalçın O. Evaluation of the effects of losartan on a random pattern skin flap model in rats. *Ulus Travma Acil Cerrahi Derg*. 2011;17:97-102.
- 11- Livaoglu M, Kerimoğlu S, Sönmez B, Livaoglu A, Karaçal N. The effect of Hirudoid on random skin-flap survival in rats. *J Plast Reconstr Aesthet Surg*. 2010;63:1047-51.
- 12- Akan M, Cakir B, Misirlioğlu A, Yildirim S, Taylan G, Aköz T. Effects of clopidogrel and high dose aspirin on survival of skin flaps in rats. *Scand J Plast Reconstr Surg Hand Surg*. 2005;39:7-10.
- 13- McFarlane RM, Deyoung G, Henry RA. The design of a pedicle flap in the rat to study necrosis and its prevention. *Plast Reconstr Surg*. 1965;35:177-82.
- 14- JE, H., Pedicle flaps-overview, in ed: Symposium on Basic Science in plastic Surgery, I.K. TJ, Editor. 1976: St. Louis, Mosby. p. p:241-259.
- 15- Foster BC, Arnason JT, Briggs CJ. Natural health products and drug disposition. *Annu. Rev. Pharmacol. Toxicol.*, 2005;45:203-26.
- 16- Pang Y, Lineaweaver WC, Lei MP, Oswald T, Shamburger S, Cai Z, et al. Evaluation of the mechanism of vascular endothelial growth factor improvement of ischemic flap survival in rats. *Plast Reconstr Surg*. 2003;112:556-64.
- 17- Kerrigan CL, Daniel RK. Critical ischemia time and the failing skin flap. *Plast Reconstr Surg*. 1982;69:986-9.
- 18- Hirose H, Kimura T, Okada M, Itoh Y, Ishida F, Mochizuki N, et al. Antiplatelet and antithrombotic effects of a novel selective phosphodiesterase 3 inhibitor, NSP-513, in mice and rats. *Jpn J Pharmacol*, 2000;82:188-98.
- 19- Suarez Nieto C, Suarez Garcia MJ, Barthe Garcia P. A comparative study on the effect of various pharmacological agents on the survival of skin flaps in the rat. *Br J Plast Surg*, 1992;45:113-6.
- 20- Vedder NB, Bucky LP, Richey NL, Winn RK, May Jr JW. Improved survival rates of random flaps in rabbits with a monoclonal antibody that blocks leukocyte adherence. *Plast Reconstr Surg*. 1994;93:1035-40.
- 21- Kabil MF, Abo Dena AS, El-Sherbiny IM. Ticagrelor. Profiles Drug Subst Excip Relat Methodol. 2022;47:91-111.
- 22- Grzesk G, Kozinski M, Navarese EP, Krzyzanowski M, Grzesk E, Kubica A, et al. Ticagrelor, but not clopidogrel and prasugrel, prevents ADP-induced vascular smooth muscle cell contraction: a placebo-controlled study in rats. *Thromb Res*. 2012;130:65-9.
- 23- Ye Y, Birnbaum GD, Perez-Polo JR, Nanhwan MK, Nylander S, Birnbaum Y. Ticagrelor protects the heart against reperfusion injury and improves remodeling after myocardial infarction. *Arterioscler Thromb Vasc Biol*. 2015;35:1805-14.
- 24- Flierl U, Schöpp C, Jaitner J, Bauersachs J, Schäfer A. The novel P2Y₁₂ antagonist AZD6140 rapidly and reversibly reduces platelet activation in diabetic rats. *Thromb Res*. 2010;125:93-9.
- 25- Dobesh PP, Oestreich JH. Ticagrelor: pharmacokinetics, pharmacodynamics, clinical efficacy, and safety. *Pharmacotherapy*. 2014;34:1077-90.
- 26- Wittfeldt A, Emanuelsson H, Brandrup-Wognsen G, van Giezen JJ, Jonasson J, Nylander S, et al. Ticagrelor enhances adenosine-induced coronary vasodilatory responses in humans. *J Am Coll Cardiol*. 2013;61:723-7.
- 27- Fatemi MJ, S Forootan K, S Jalali SZ, Mousavi SJ, Pedram MS. The effect of enoxaparin and clopidogrel on survival of random skin flap in rat animal model. *World J Plast Surg*. 2012;1:64-70.