



ATR-FTIR Spectroscopic Analysis of Novel Fixatives and Their Histological Properties on Sheep Heart

Koyun Kalbinde Yeni Fiksatiflerin ATR-FTIR Spektroskopik Analizi ve Histolojik Özellikleri

Fikri Özdemir¹ | Sevil Özkınalı² | Emine Nazlı Hayırlı Özyol³

¹ Hitit University, Faculty of Medicine, Department of Anatomy, Çorum, Türkiye.

² Hitit University, Department of Chemistry, Faculty of Science and Arts, Çorum, Türkiye.

³ Hitit University, Faculty of Medicine, Department of Basic Medical Sciences, Çorum, Türkiye.

Sorumlu Yazar | Correspondence Author

Fikri Özdemir

fikriozdemir@hitit.edu.tr

Address for Correspondence: Tıp Fakültesi İkbalkent Kampüsü Ulukavak Mah. Çiftlik Çayırı Cad. No: 45 19040 Çorum, Türkiye.

Makale Bilgisi | Article Information

Makale Türü | Article Type: Araştırma Makalesi | Research Article

Doi: <https://doi.org/10.52827/hititmedj.1370056>

Geliş Tarihi | Received: 02.10.2023

Kabul Tarihi | Accepted: 11.01.2024

Yayın Tarihi | Published: 30.06.2024

Atıf | Cite As

Özdemir F, Özkınalı S, Özyol E.N.H. ATR-FTIR Spectroscopic Analysis of Novel Fixatives and Their Histological Properties on Sheep Heart. Hitit Medical Journal 2024;6(2):98-107. <https://doi.org/10.52827/hititmedj.1370056>.

Hakem Değerlendirmesi: Alan editörü tarafından atanan en az iki farklı kurumda çalışan bağımsız hakemler tarafından değerlendirilmiştir.

Etik Beyanı: Etik kurul onayı alınmasına gerek yoktur.

İntihal Kontrolleri: Evet (iThenticate)

Çıkar Çatışması: Yazarlar çalışma ile ilgili çıkar çatışması beyan etmemiştir.

Şikayetler: hmj@hitit.edu.tr

Katkı Beyanı: Fikir/Hipotez: FÖ, SÖ Tasarım: FÖ, SÖ Veri Toplama/Veri İşleme: FÖ, SÖ, ENHÖ Veri Analizi: FÖ, SÖ Makalenin Hazırlanması: FÖ, SÖ, ENHÖ.

Hasta Onamı: Hasta onamı alınmasına gerek yoktur.

Finansal Destek: Finansal destek alınmamıştır.

Telif Hakkı & Lisans: Dergi ile yayın yapan yazarlar, CC BY-NC 4.0 kapsamında lisanslanan çalışmalarının telif hakkını elinde tutar.

Peer Review: Evaluated by independent reviewers working in the at least two different institutions appointed by the field editor.

Ethical Statement: Not applicable.

Plagiarism Check: Yes (iThenticate)

Conflict of Interest: The authors declared that, there are no conflicts of interest.

Complaints: hmj@hitit.edu.tr

Authorship Contribution: Idea/Hypothesis: FÖ, SÖ Design: FÖ, SÖ Data Collection/Data Processing: FÖ, SÖ, ENHÖ Data Analysis: FÖ, SÖ Manuscript Preparation: FÖ, SÖ, ENHÖ.

Informed Consent: Not applicable.

Financial Disclosure: There are no financial funds for this article.

Copyright & License: Authors publishing with the journal retain the copyright of their work licensed under CC BY-NC 4.0.

ATR-FTIR Spectroscopic Analysis of Novel Fixatives and Their Histological Properties on Sheep Heart

ABSTRACT

Objective: In this study, new fixative solutions that are odorless and non-toxic were tested on the hearts of sheep to preserve the cellular structure and tissue architecture in a life-like manner.

Material and Method: The changes of new fixatives before and after contact with tissue were detected for the first time by the ATR-FTIR spectroscopic method. After a preliminary inspection, hearts were fixed with six different solutions. It was periodically evaluated for weight, size, color, and hardness. Samples taken from the left ventricle of each heart stained with Hematoxylin eosin and examined histologically.

Results: As a result of the measurements of heart weights, reduction in Solution 1 (Standard Formaldehyde Fixative), Solution 4, and Solution 5 were detected at 5.64%, 23.70%, and 14.38%, respectively. In Solution 4 and Solution 5, it was observed that the integrity of the myocardium was protected in terms of morphology, the stiffness was suited for sectioning and the coronary vessels were preserved better than Solution 1. Further, compared to solution 1, it was determined that the endocardium and myocardium layers were well preserved in the tissues fixed in Solution 4 and Solution 5. Typical cross striation appearance in cardiac muscle tissue existed in all three Solution 1, Solution 4, and Solution 5.

Conclusion: Solution 4 and Solution 5 were found to have superior fixative properties than Solution 1 (Formaldehyde). As a result of ATR-FTIR studies, it was determined that formaldehyde was converted into toxic formic acid in Standard Solution 1, while very few harmless changes were detected in Solution 4 and Solution 5.

Keywords: Anatomy education, ATR-FTIR spectroscopy, fixative, organ preservation.

ÖZET

Amaç: Bu çalışmada, hücresel yapının ve doku mimarisinin canlı gibi korunması amacıyla, kokusuz ve toksik olmayan yeni fiksatif çözeltiler koyun kalbi üzerinde test edildi.

Gereç ve Yöntem: Yeni fiksatiflerin dokuyla temas öncesi ve sonrasındaki değişiklikleri ilk kez ATR-FTIR spektroskopik yöntemiyle tespit edildi. Ön incelemenin ardından kalpler altı farklı çözeltiyle fikse edildi. Ağırlık, boyut, renk ve sertlik açısından periyodik olarak değerlendirildi. Her kalbin sol ventrikülünden alınan ve Hematoksilen Eozin ile boyanan örnekler histolojik olarak değerlendirildi.

Bulgular: Kalp ağırlıkları ölçümleri sonucunda Çözelti 1 (Standart %10' luk Formaldehit Çözeltisi), Çözelti 4 ve Çözelti 5'te sırasıyla %5,64, %23,70 ve %14,38 azalma tespit edildi. Çözelti 4 ve Çözelti 5'te miyokardın morfolojik açıdan bütünlüğünün korunduğu, sertliğin kesit almaya uygun olduğu ve Çözelti 1'e göre koroner damarların iyi korunduğu gözlemlendi. Ayrıca Çözelti 1 ile karşılaştırıldığında, Çözelti 4 ve Çözelti 5'te fikse edilen dokularda endokardiyum ve miyokard katmanlarının iyi korunduğu belirlendi. Çözelti 1, Çözelti 4 ve Çözelti 5'in içerisindeki kalp kası dokularında tipik enine çizgilenme görünümü mevcuttu.

Sonuç: Çözelti 4 ve Çözelti 5'in Çözelti 1'e (Formaldehit) göre daha üstün fiksatif özelliklere sahip olduğu bulundu. ATR-FTIR çalışmaları sonucunda Standart Çözelti 1'de formaldehitin toksik formik asite dönüştüğü belirlenirken, Çözelti 4 ve Çözelti 5'te çok az ve zararsız değişiklikler tespit edildi.

Anahtar Sözcükler: Anatomi eğitimi, ATR-FTIR spektroskopisi, fiksatif, organ koruma.

Introduction

The use of embalmed specimens for three-dimensional anatomy education has been valid for years and is the most effective way to learn human anatomy (1-4). Although Cadaver dissection, a classical teaching method, has been an integral part of anatomy education for centuries, with the advancing technology in the 21st century, more effective ways of using teaching methods such as cadaver dissection are sought (2, 5-7). Anatomy education is the foundation for the successful acquisition of clinical skills and contributes significantly to students' understanding of general anatomy (2). Students working with cadaver materials is a significant part of their professional development toward becoming a doctor, dentist, or scientist (3). Especially in the surgical discipline, In-depth understanding of anatomy is indispensable for safe clinical practice (8).

Formaldehyde solution is widely used in anatomical studies as an essential component of embalming fluid in the preparation of cadavers (9). In contrast, it involves a serious health risk among students, instructors, and all parties involved, and the immediate symptoms of throat, nose, eyes, and skin irritation are the major drawbacks of formaldehyde (9). Formaldehyde has been classified as a carcinogenic substance for humans such as nasopharyngeal cancer, ocular melanoma, lung cancer, brain cancer and leukemia by the United States Environmental Protection Agency and the International Agency for Research on Cancer (9). Accordingly, the Occupational Safety and Health and Administration has set the short-term exposure limit (STEL) for formaldehyde to 2 ppm and 0.75 ppm for the time-weighted average (TWA). Hitherto, to minimize the harmful side effects of formaldehyde, alternative methods such as improving ventilation and exhausting systems, limiting the learning time in the laboratory, increasing the use of personal protective equipment or anatomical modeling such as corrosive cast and plastination have been developed (9). Although new methods such as corrosive cast and plastination are developed, they cannot replace real cadavers due to their deficiencies in teaching methods (9).

Fixation is a physicochemical process in which cells and tissues remain chemically unchanged. It is also the process of fixing tissues and cells using chemicals,

with disfigurement negligible morphological. With this process, while the components in the cell become insoluble, it resists tissue destruction for the next processing and eliminates the damage caused by osmotic pressure in the tissue (10,11). Fixatives perform functions such as preventing autolysis and tissue putrefaction as well as tissue component degradation. Various stabilizing agents include formaldehyde, ethanol, osmium tetroxide, glutaraldehyde, picric acid, glyoxal, and so on (11). Temperature plays a pivotal role in increasing the fixation rate or decreasing the diffusion rate of fixative both of which affect tissue architecture (10). Generally, fixation of tissues at room temperature is appraised as the ideal temperature, except for histochemistry and electron microscopy processes that occur between 0 and 4 degrees (10).

Fourier transform infrared (FTIR) spectroscopy has significant advantages compared to many other conventional techniques as it is a dye-free, non-invasive, label-free, fast and low-cost modern method in biochemical applications (12,13). FTIR spectroscopy has attracted attention in biomedical applications in recent years due to it relies on the characteristic absorbance of the corresponding functional groups in the organic sample. Therefore, it can be a powerful diagnostic tool in anatomical studies, in the discrimination of fixatives and tissues with impaired organic structure (12-14).

The aim of this study is to find a new fixative to preserve the cellular structure and tissue architecture in a life-like manner and to detect the change in functional groups in fixatives as a result of contact with tissue by the ATR-FTIR spectroscopic method. For this, histological studies at the cellular level were performed on sheep hearts with new fixatives.

Material and Method

Tissue Collection and Fixation

Sheep hearts were obtained from a local slaughterhouse and immediately transferred to the laboratory. Hearts were rinsed with saline three times and after washing, the pericardial membrane outside the heart was removed by the Anatomy specialist. The heart was incised from the Sulcus Anterior Interventricularis using a scalpel, the mitral and tricuspid valve was ejected, but the papillary

muscles were quitted. The weights of the hearts were measured with a Precisa XB 1200 C branded weighing, their height and width were recorded, their photographs were taken and then they were placed in the prepared six fixative solutions.

Table I. The content of the prepared solutions for sheep hearts

Solutions	Contents
1	10% Formaldehyde aqua solution (200 mL) [54.05 mL Formaldehyde (37%) + 145.95 mL water]
2	1 g MgSO ₄ + 1 g NaCl + 0.5 g NaHCO ₃ + 50 mL Ethanol + 150 mL aqua
3	2 g Phenol + 2 g pine oil + 1.75 g Vitamin E + 5 mL Acetone + 200 mL aqua
4	50 mL glycerol + 10 mL ethoxyphenol + 10 mL Toluene + 30 mL olive oil + 50 mL Tetrahydrofuran + 50 mL Ethanol
5	2 g Phenol+ 50 mL propan-2-ol+ 50 mL aqua
6	1% Resorcinol aqua solution (200 mL)

The contents of the prepared solutions are given in Table I. All chemicals and solvents were obtained from Aldrich (U.S.). The weighted tissues were placed in six different fixative solutions prepared with polar and nonpolar properties. At the end of the 3rd day, obvious dissolution and softening of the tissues in Solution 2, Solution 3, and Solution 6 were observed and they were excluded from the study because they were unsuitable form for demonstration. At the beginning of the study, samples were stored at 4 °C in a refrigerator for 56 days. After 56 days, the hearts were allowed to stand at room temperature, and weight loss, odor, and color change were determined.

Solution 1 is the standard solution and the contents of the other five solutions are represented in Table I. In solution 2 ethanol was used due to its anti-infective agent properties, sodium bicarbonate was preferred to prevent the oxidation of ethanol to acetic acid and salts were preferred due to their antibacterial properties. In Solution 3, phenol was preferred due to its bacteriostatic properties at low concentrations, and acetone was preferred in the fixative process due to its dehydration agent feature. Pine oil was used due to it contains toluene and toluene is known to have disinfectant properties against various viruses and bacteria. In solution 4, Ethoxy phenol an aromatic compound was preferred due to as a derivative of

phenol. Tetrahydrofuran is a cyclic ether structure, water-miscible organic liquid and it is preferred due to its antibacterial properties. Glycerol was preferred due to its antimicrobial properties. Isopropanol (Propan-2-ol), a better antiseptic and germicidal agent than ethanol, was used in Solution 5. In solution 6, Resorcinol is an aromatic compound and was preferred due to it being a phenol derivative.

Histological Sample Preparation

After fixation tissues were prepared with the standard histological process; dehydration, clearing, infiltration, embedding, sectioning, staining, and mounting. 5 µm thick sections were stained with Hematoxylin and eosin to assess the morphological integrity of the hearts (15). Sections were examined by a Nikon Eclipse Ni model light microscope and images were taken.

ATR-FTIR Analysis

The infrared spectra of the compounds were recorded by a Thermo Scientific Class 1 Laser FT-IR (USA) spectrophotometer with ATR (Attenuated Total Reflection) mode.

Results

The first day and 3rd days later photographs of sheep hearts were seen in Figure S1 (Supplementary Data). At the end of the third day, the weight change of the hearts in six different solutions is seen in Figure 1. While an increase in weight was observed in the first three days in Solution 1, Solution 3, and Solution 6, a decrease in weight was observed in Solution 2, Solution 4, and Solution 5. The experiment was not continued, as Solution 2, Solution 3, and Solution 6 were observed dissolution in the hearts and coloration in the solutions. Deterioration of hearts and coloration of solutions were not observed in Solution 4 and Solution 5 as seen in Solution 1 (Standard Solution).

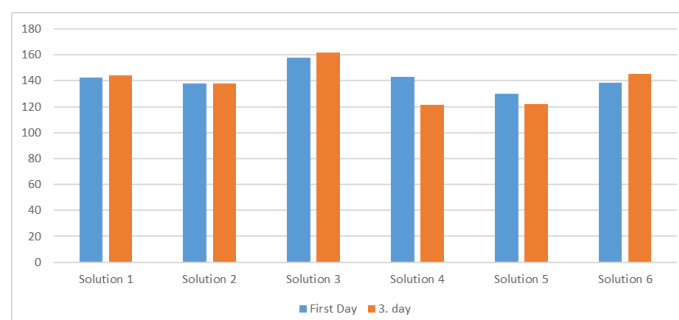


Figure 1. Weight change in hearts in six different solutions over three days

Weight reduction was observed in Solution 1, Solution 4, and Solution 5 with 5.64%, 23.70%, and 14.38% respectively at the end of the 316th day (Figure 2). In Solution 4 and Solution 5, it was observed that the integrity of the myocardium was preserved in terms of morphology, its stiffness was suitable for sectioning and the overlying coronary vessels were well protected. When the tissues fixed with Solution 4 and Solution 5 were compared with the tissues fixed with formaldehyde (Solution 1), it was observed that the endocardium and myocardium layers were well preserved. There was a typical transverse striation appearance in the cardiac muscle tissue. It was preserved in all three Solutions.

Table II. Weight losses in sheep hearts

Hearts	First Day Weights	3 days Weights	10 days Weights	56 days Weights	116 days Weights	316 days Weights
1	142.62 g	143.92 g	143.11 g	141.57 g	140.78 g	134.58 g
2	138.13 g	137.98 g				
3	157.58 g	162.06 g				
4	143.22 g	121.23 g	111.32 g	111.98 g	111.53 g	109.28 g
5	130.12 g	121.90 g	117.76 g	114.64 g	113.86 g	111.41 g
6	138.60 g	145.05 g				

Except for Solution 1, the least weight reduction was observed in Solution 5 (Table II). The maximum weight change for Solution 4 and Solution 5 was observed in the first three days in Table II. After 10 days, weight reduction for Solution 4 and Solution 5 progressed very slowly, while after 116 days for Solution 1, the weight reduction increased. From this, it is seen that formaldehyde (Solution 1) causes weight loss in tissues after long periods and is less protective than Solution 4 and Solution 5. The oxidation of formaldehyde to formic acid by oxygen after long periods and the extremely toxic nature of formic acid also limit the use of this solution. The sizes of the hearts used are given in Table III. It can be seen that the dimensions are close to each other.

Table III. Size values of sheep hearts

Hearts	First Day Wide- Length	316 Days Wide-Length
1	7.5 - 8.0 cm	7.0 - 7.50 cm
2	8.0 - 9.0 cm	-
3	7.3 - 9.3 cm	-
4	8.2 - 7.9 cm	7.50 - 7.60 cm
5	7.2 - 7.9 cm	7.20- 6.90 cm
6	6.9 - 8.2 cm	-

After 316th days, Solution 4 and Solution 5 showed that the integrity of the myocardium was preserved morphologically, the stiffness was suitable for sectioning and the coronary vessels were well preserved compared to Solution 1 (Figure S2 in Supplementary Data). The tissue appearance in Solution 4 was close to the first day. For heart tissues from sheep, solution 4 and Solution 5 were found to have excellent fixative properties compared to Solution 1. Solution 4 and Solution 5 are colorless, odorless and the solutions do not deteriorate over time, making them an excellent fixative.

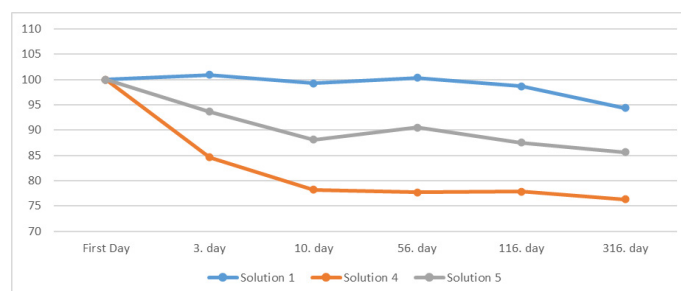


Figure II. Percentage change of heart weights in Solution 1, Solution 4, and Solution 5

Histological analysis

Hematoxylin and eosinstained sections from tissues fixed with three different fixatives were evaluated. Solution 1 fixed tissue sections are shown in Figure III. Endothelial cells in the endocardium layer were well preserved. Due to deficient washing of the fixative during tissue processing or a long fixation time, formalin pigment artifacts were detected. The nuclei of cardiomyocytes were in normal shape and position. Typical cross-striations were seen in transverse sections. In addition, erythrocytes in blood vessels were in normal appearance.

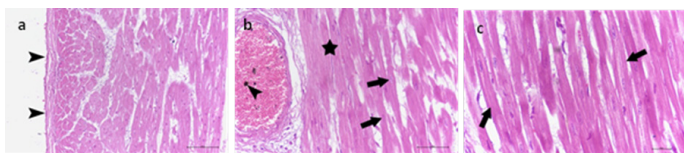


Figure III. Histology of hematoxylin and eosin-stained sections of Solution 1 fixed tissue. a) arrowheads: endocardium; b) arrowhead: formalin pigment, star: cross striations, arrows: cardiomyocyte nucleus; c) arrows: cross striations (a: 20x, b: 40x, c: 60x)

Light microscopic examination of tissues fixed in Solution 4 (Figure IV) and Solution 5 (Figure V) showed well-preserved endothelial cells in the endocardium layer. Purkinje fibers were stained paler than cardiomyocytes as it should be in both tissue samples. Their sarcoplasm was occupied by glycogen that is not preserved in most histological preparations. In our study, the tissue fixed with Solution 4 showed much better preservation of glycogen compared to Solution 5. In cross and longitudinal sections, myofibrils maintained their typical appearance better in Solution 5 fixed tissue compared to tissue fixed with Solution 4. In both samples, the nuclei were not well preserved.

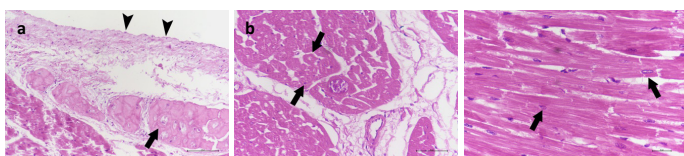


Figure IV. Histology of hematoxylin and eosin-stained sections of Solution 4 fixed tissue. a) arrowheads: endocardium, arrow: Purkinje fibers; b) arrows: cross sections of cardiac muscle fibers; c) arrows: cardiomyocyte nucleus (a: 20x, b: 40x, c: 60x)

FTIR Analyses

The FTIR spectra of the fixatives (Solution 1, Solution 4, Solution 5), initial (red color) and final (purple color) in the fingerprint region are given in Figure VI. Since changes were detected in the range of fingerprint region (1500-600 cm^{-1}) of IR spectrums of the fixatives, the peaks in this region were investigated. The IR spectrums of the solutions obtained between 4000-600 cm^{-1} are included in Supplementary File 2. When the spectrum of 10% formaldehyde solution in red color (A) is examined, weak out-of-plane C-H bending peaks are observed

at 1104 cm^{-1} and 1026 cm^{-1} . When the second spectrum in the purple color (A) is examined, the stretching peak of the strong C-O single bond seen at 1025 cm^{-1} can be attributed to the oxidation of formaldehyde to the corrosive formic acid. The strong peak of the C-O single bond seen at 1025 cm^{-1} is evidence of the presence of corrosive formic acid.

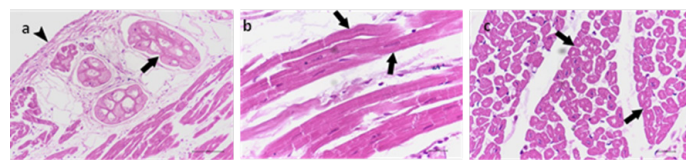


Figure V. Histology of hematoxylin and eosin-stained sections of Solution 5 fixed tissue. a) arrowhead: endocardium, arrow: Purkinje fibers; b) arrows: longitudinal sections of cardiac muscle fibers; c) arrows: cross sections of cardiac muscle fibers (a: 20x, b: 40x, c: 60x)

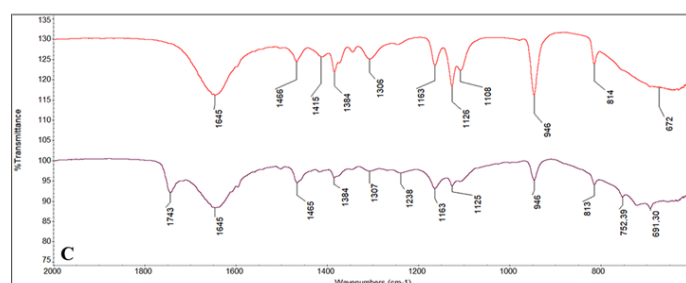
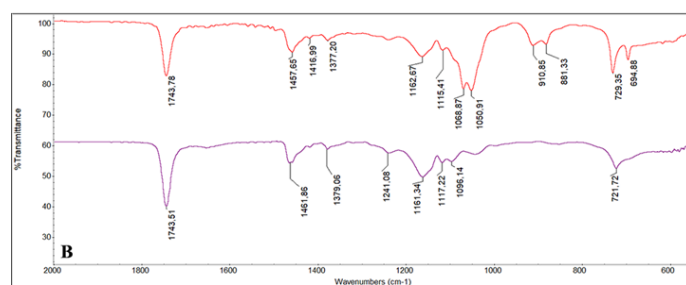
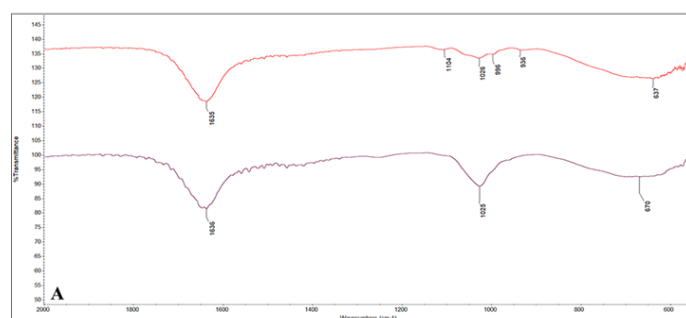


Figure VI. FTIR spectra of organic molecules used in solutions. A) Solution 1 (10% Formaldehyde aqua solution); B) Solution 4 (glycerol; ethoxyphenol; toluene; olive oil; tetrahydrofuran; ethanol); C) Solution 5 (Phenol; propan-2-ol; aqua) (red spectra: 1. st day, purple spectra: 316. days)

When the IR spectrum of fixative 4 (B) is examined, the stretching peaks of the C-O single bond (red spectrum) are seen at 1068 cm^{-1} and 1050 cm^{-1} weakened in the purple spectrum. This change indicates that some of the ethanol in the solution may have been converted to oxidation products (acetaldehyde/acetic acid). The C-O stretching peak seen at 1161 cm^{-1} in the purple spectrum belongs to the C-O single bonds of glycerin and olive oil, indicating that these compounds remain intact.

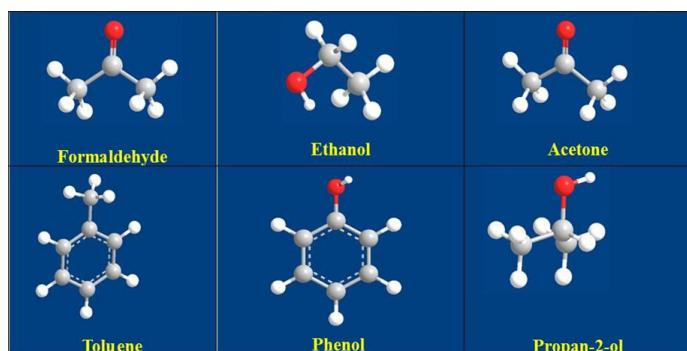


Figure VII. Structure of organic molecules used in solutions.

When the IR spectrum of Solution 5 is examined, carbonyl stretching vibration (purple spectrum) is observed at 1743 cm^{-1} , unlike the beginning (red spectrum). This may be due to the oxidation of iso-propanol to acetone. When the IR spectra at the beginning and the end of the experiment are observed, it is seen that the solutions remain the same.

Discussion

Used for the first time in 1899 for cadaver storage, formaldehyde (Figure VII) has still been used effectively for over 100 years (16). Formaldehyde is a bactericidal, fungicidal, and insecticide, although it has a decreasing effect over time. The widespread use of formaldehyde as a preservative supports that formaldehyde has perfect antiseptic properties and in this way prohibits the decay of organisms, tanning tissues without damaging the structures (16). Formaldehyde is classified as medium-high level (4-8% aqueous formaldehyde mixture) and high-level (70% alcohol and 8% formaldehyde composition) disinfectant (17). It has a wide range of effects on microorganisms. It devastates corrosive organisms when transported by a suitable means that allows

them to diffuse these organisms; moreover, it reacts with proteins, forming novel chemical structures (resins) that are not durable and unsuitable as nutrients for living things (17). However, even though formaldehyde is a perfect tissue fixative, its use often results in tissues resulting in excessive stiffness, a major drawback (18). Apart from hardening, formaldehyde has other few drawbacks for preserving purposes (17). It coagulates the blood rapidly, turns the tissues gray when mixed with the blood, removes stains, dries out tissues, narrows capillaries, deteriorates over time, and has a disagreeable odor. Also, excessive formalin is shown to form a precipitate when the mummified cadaver is left unprotected for an extended range of time in the dissection laboratory (19).

Formaldehyde (Methanal), CH_2O , is an extremely reactive gas shaped by the synthesis gas of hydrocarbons or by the oxidation of methanol. Its 37% aqueous solution is known as formalin. Formaldehyde gas is further produced by the burnout of organic substances and can be generated secondary to carbon monoxide with water in the air from photochemical reactions including almost all types of hydrocarbon toxins (16). Formaldehyde is rapidly metabolized to methylene glycol and formic acid; It is generated endogenously in people and animals and further occurs owing to the metabolism of numerous xenobiotic agents (16). Due to these problems, specific biological exposure indicators like formaldehyde levels or metabolites in blood or urine have been approved to be inefficient exposure evaluations (16).

Ethanol is widely used as an alcoholic solvent and anti-infective agent in embalming processes (Figure 1). Also, in some literature, it is recommended to wash out excess formaldehyde with ethanol (16,20). There is partially uncertain literature on the effect of ethanol as a liquid preservative. Ethanol, at minimal when integrated with glycerin, the tertiary structure of the protein by affecting the hydrate coating reversible manner denatures. Hydrogen bridge bonds are broken (21). Ethanol tends to decrease the activity of the central nervous system (16).

Easily accessible isopropanol is noted as a better antiseptic and germicidal agent than ethanol (Figure 6). Isopropanol has a specific odor, but it is not unpleasant (22).

Acetone is one of the other fixative agents used in histopathology. It acts as an effective lipid solvent that causes tissue fragility. Besides tissue fixation, they are primarily used as an agent for dehydration in tissue processing. It is not recommended for use in automatic tissue processors due to their highly volatile and flammable nature (11).

In the study by Barbara M. Scholz-Böttcher on mummy residues at the Heidelberg (Germany) museum, camphor, aromatic compounds (e.g. toluene, dimethyl styrene derivatives dimethoxy benzene, tetra methoxy phenol), monoterpenes (e.g. pinene, cymene) and sesquiterpenes (e.g. kadinatrien, kadalen) were detected (23). In the study conducted by Timotty, Toluene (60 mL), Tertiary Butyl alcohol (25 mL), Ethyl alcohol (15 mL), Phenol 5 g, Naphthalene 20 g, and Canada Balsam (10 drops in Xylene) were used as embalming fluid for the storage of insects (24).

Toluene is a colorless, volatile aromatic solvent and has disinfectant properties against various viruses and bacteria (25).

Generally, 10% aqueous formalin solution is used to preserve animal and human bodies (26). Another possibility to protect cadavers in descriptive anatomy teaching is the use of glycerol, alcohol, and phenol (26). The most commonly used fixative solutions in Brazil for anatomical studies are formalin, ethyl alcohol, glycerin, and phenol (26). Phenol was first used as an anatomical embalming fluid in the mid-19th century by Laskowski (1886) (16). Initially, he used the 1:20 ratio of phenol: glycerine mixture and then the 1:1:4:20 ratio of phenol: Boric acid: alcohol: glycerin mixture as the embalming liquid (16). Woodburne and Lawrence (1952) developed a new embalming formulation including phenol-formaldehyde, using isopropanol instead of alcohol and sorbitol instead of glycerin (16, 22). Erskin (1961) reported that the embalming fluid consisting of ethanol, formaldehyde, glycerin, and phenol and also containing salicylic acid, sodium arsenate, and 6-chlorophyll provides excellent dissection for cadavers over 3 years (16). In the last step of the cadaver conservation procedure developed by Logan (1983), alcohol, glycerin, phenol, and low formaldehyde were used as a preservative solution in the local injection of preservative solution for arterial protection (16). In

studies conducted at Kawasaki School of Medicine on arterial patterns as embalming fluid, 95% ethyl alcohol (7.6 L) and 35% formalin (1.3 L) as fixative, diethylene glycol as protective (2.7 L), liquefied phenol as mold protective (1.3 L) and water (8.0 L) were used (16). O'Sullivan and Mitchell (1993) investigated that formaldehyde, industrial methylated spirits water, phenol, and glycerol were used in different proportions in embalming fluids obtained from 16 medical schools in the United Kingdom, and detected that phenol indicated disinfectant quality enhancing properties in all of them (27). In 2007, Silva, compared two solutions used to preserve the 112 cadavers in terms of color, odor, and flexibility in Hospital Cochin of Rene Descartes University, in France, a Laskowski solution with an altered Larssen solution (16). The altered Larssens (MLS) solution contained 100 mL of 10% formalin, 200 g chloral hydrate, 400 mL glycerin, 200 g sodium bicarbonate, 200 g of sodium sulfate, 180 g sodium chloride, and 2 L distilled water. The Laskowski solution consists of 200 mL ethanol, 800 mL glycerin, 50 g phenol, and 50 mg boric acid (16,26). In the study, 96.6% of the students found the Larssen solution more satisfactory in protecting cadavers for surgical training (26).

Phenol is a colorless liquid or a white solid crystal, and it was used as a disinfectant in medicine in 1867 (16). Phenol has bacteriostatic properties at a small concentration of 0.2% and is effective against various bacteria, fungi, and viruses (16). This effect occurs in the form of deactivating enzymes, effectively attacking and destroying the cell wall because of its lipophilic form, denaturing proteins and protein products. Liquefied phenol not only effectively prevents mold but also not indicate the graying effect seen in formaldehyde (16). In our study, it was determined that the colors of the heart tissues were preserved in the solutions numbered 3 and 5 including phenol.

The readily available isopropanol (Propan-2-ol) is found a better antiseptic and germicidal agent than ethanol. Isopropanol has a specific odor, but not an unfavorable one (16). In addition to formaldehyde, embalming fluids contain a variety of other chemicals such as several aliphatic alcohols (methanol, ethanol, and isopropanol), chelating agents (EDTA), surfactants

(sulfonates and sodium lauryl sulfate), deodorants (eugenol derivatives and safrole derivatives), dyes [eosin (yellowish-orange), erythrosine (red) and ponceau red] and disinfectants [salicylic acid and sulfanilamide (sulfa-base antibacterial)] (28).

In this study, solvents such as Toluene, Phenol, isopropanol, and ethoxyphenol were chosen due to their anti-infective, antiseptic, germicidal agent properties. Among them, ethoxyphenol in Solution 4 was used as a fixative for the first time and this solution was introduced to the literature as an alternative to phenol and ethyl alcohol. In addition, Solution 4 and Solution 5 were prepared for the first time in different amounts and mixtures and used as fixatives. While the deterioration of the solutions was not detected in the IR spectrum of the solutions numbered 4 and 5, the conversion to formic acid was detected in the formaldehyde solution number 1. Thus, alternative fixatives that are non-toxic and protect the tissues for a longer period, have been developed against formaldehyde which is toxic and has a limited usage time.

Conclusion

Heart tissues were evaluated for hardness, color, and odor over one-year period using new fixative solutions. As a result of the studies, it has been determined that the endocardium and myocardium layers of the heart tissues are better protected in Solution 4 and Solution 5 than in Solution 1 (formaldehyde solution). Solution 4 and Solution 5 were found to have superior fixative properties than Solution 1. From the FTIR data obtained, it was determined that solution 4 and solution 5 did not turn into harmful chemicals for health. In the IR spectrum of the 1st formaldehyde solution, the conversion of formaldehyde to formic acid was determined. As a result of this study, colorless, odorless, non-toxic fixative solutions that do not deteriorate in contact with air have been developed as an alternative to formaldehyde.

Acknowledgments

In this study, Hitit University Laboratories were used.

References

1. Ten Brinke B, Klitsie PJ, Timman R, et al. Anatomy Education and Classroom Versus Laparoscopic Dissection-Based Training: A Randomized Study at One Medical School. *Academic Medicine* 2014;89(5):806-810.
2. Ghosh SK. Cadaveric dissection as an educational tool for anatomical sciences in the 21st century. *Anatomical Sciences Education* 2017;10(3):286-299.
3. Franchi T. The Impact of the Covid-19 Pandemic on Current Anatomy Education and Future Careers: A Student's Perspective. *Anatomical Sciences Education* 2020;13(3):312-315.
4. Boduç E, Allahverdi T. Student Opinions on the Importance and Detail of the Accumulation of Anatomy Knowledge Integrating General Surgery. *Middle Black Sea Journal of Health Science* 2020;6:385-389.
5. Williams AD, Greenwald EE, Soricelli RL, DePace DM. Medical students' reactions to anatomic dissection and the phenomenon of cadaver naming. *Anatomical Sciences Education* 2014;7(3):169-180.
6. Memon I. Cadaver Dissection is Obsolete in Medical Training A Misinterpreted Notion. *Medical Principles and Practice* 2018;27(3):201-210.
7. Aziz MA, Mckenzie JC, Wilson JS, Cowie RJ, Ayeni SA, Dunn BK. The human cadaver in the age of biomedical informatics. *Anatomical Record* 2002;269(1):20-32.
8. Estai M, Bunt S. Best teaching practices in anatomy education: A critical review. *Annals of Anatomy* 2016;208:151-157.
9. Ninh LN, Tangkawattana S, Sukon P, Takahashi N, Takehana K, Tangkawattana P. Neutralizing formaldehyde in chicken cadaver with urea and urea fertilizer solution. *Journal of Veterinary Medical Science* 2018;80(4):606-610.
10. Bamisi OD, Alese MO. Effects of various fixatives and temperature on the quality of glycogen demonstration in the brain and liver tissues. *Ann Diagn Pathol* 2020; 48:151604.
11. Singh H, Bishen KA, Garg D, Sukhija H, Sharma D, Tomar U. Fixation and Fixatives: Roles and Functions-A Short Review. *Dental Journal of Advance Studies* 2019;07(02):51-55.
12. Kazarian SG, Chan KLA. Applications of ATR-FTIR spectroscopic imaging to biomedical samples. *Biochimica et Biophysica Acta - Biomembranes* 2006;1758(7):858-867.
13. Li C, Fan H, Sun Y, Tian W, Ma G. Toxicity of aristolochic acid in a rat model investigated by Fourier transform infrared spectroscopy combined with chemometric analysis: An exploratory study. *Vibrational Spectroscopy* 2021;117:103307.
14. Baran MF, Açıy H. Antimicrobial Activity Of Silver Nanoparticles Synthesized with Extract of Tomato Plant Against Bacterial and Fungal Pathogens. *Middle Black Sea Journal of Health*

Science 2019;5:67-73.

15. Öztürkler Y, Baran A, Evecen M, Ak K, Ileri IK. Comparison of Ovine Spermatozoal Morphological Features after Staining of Fixation and Assessment of Morphological Abnormalities in Dead/Live Spermatozoa. Turkish Journal of Veterinary and Animal Sciences 2001;25(5):675-680.

16. Brenner E. Human body preservation-old and new techniques. Journal of Anatomy 2014;224(3):316-344.

17. Mayer R.G. Embalming: History, Theory, and Practice. Fifth Edition. New York: Mac Graw Hill Medical Publishing, 2012; 143-210.

18. Richins CA, Roberts EC, Zeilmann JA. Improved fluids for anatomical embalming and storage. The Anatomical Record 1963;146(3):241-243.

19. Bradbury SA, Hoshino K. An improved embalming procedure for long-lasting preservation of the cadaver for anatomical study. Cells Tissue Organs 1978;101(2):97-103.

20. Björkman N, Nielsen P, Hornshøj Møller V. Removing formaldehyde from embalmed cadavers by percolating the body cavities with dilute ethanol. Acta anatomica 1986;126(2):78-83.

21. Hammer N, Löffler S, Feja C, et al. Ethanol-glycerin fixation with thymol conservation: A potential alternative to formaldehyde and phenol embalming. Anatomical Sciences Education 2012;5(4):225-233.

22. Woodburne RT, Lawrence CA. An improved embalming fluid formula. The Anatomical record 1952;114(3):507-514.

23. Scholz-Böttcher BM, Nissenbaum A, Rullkötter J. An 18th century medication "Mumia vera aegyptica" - Fake or authentic? Organic Geochemistry 2013;65:1-18.

24. Gibb T.J. Insect Collection and Identification. Second Edition. Cambridge: Academic Press; 2020; 73-124.

25. Yamanaka T, Bannai H, Tsujimura K, Nemoto M, Kondo T, Matsumura T. Comparison of the virucidal effects of disinfectant agents against equine influenza A virus. Journal of Equine Veterinary Science 2014;34(5):715-718.

26. Silva RMG, Matera JM, Ribeiro AACM. New alternative methods to teach surgical techniques to veterinary medicine students despite the absence of living animals. Is that an academic paradox? Anatomia, histologia, embryologia 2007;36(3):220-224.

27. O'Sullivan E, Mitchell BS. An improved composition for embalming fluid to preserve cadavers for anatomy teaching in the United Kingdom. Journal of Anatomy 1993;182(2):295-297.

28. Rohrig TP. Embalming Artifacts. Postmortem Toxicology 2019;123-139.