



EDİTÖRE MEKTUP / LETTER TO THE EDITOR

Traumatic neuroma involving the right mental foramen

Sağ mental forameni içeren travmatik nöroma

Jasmine Shanthi Kamath¹, Raghavendra Kini², Vathsala Naik³

¹A. B. Shetty Memorial Institute of Dental Sciences, NITTE University Department of Oral Medicine and Radiology, Nithyananda Nagar, Derlakatte, Mangalore -Karnataka, India

²A. J. Institute of Dental Sciences, Department of Oral Medicine and Radiology, Mangalore

³BIDS, Department of Oral Medicine and Radiology, Bangalore.

Cukurova Medical Journal 2017;42(4):785-787

Dear Editor,

Traumatic neuroma earlier called, as Amputation neuroma is a disorder of the peripheral nerves usually induced by trauma or surgery. This lesion develops most commonly in the mental foramen area, lower lip and tongue. They are the sequelae to any traumatic event affecting the nerve and represent an amplified reaction consisting of reactive hyperplasia of the proximal end of the nerve and are not considered to be true neoplasms^{1,2}.

A 51-year-old male patient, reported to the Department Of Oral Medicine and Radiology, with a chief complaint of a painful swelling in the right side of the lower jaw since a week. Pain was elicited only on manipulating the area. Patient was hypertensive and was undergoing treatment for the same. Patient had undergone extraction 5 years back. The post extraction period was uneventful.

Extra oral examination revealed facial symmetry. A diffuse swelling was present on the lower third of the right side of the face, measuring 3X3 cms, antero-posteriorly extending from the corner of the mouth to 5 cms ahead of the angle of the mandible. Superior-inferiorly extending from 1 cms below the imaginary line joining from the corner of the mouth to the tragus of the ear to the inferior border of the mandible. (Figure 1A) The skin over the swelling was stretched and of normal colour. No secondary

changes were seen. On palpation, all inspectory findings were confirmed. The swelling was circular in shape, firm and mildly tender. The borders were well defined, the skin over the swelling was pinchable, and the swelling was fixed to the underlying structures. It was non-compressible, non-fluctuant, with no palpable pulsations. Regional lymph nodes were non palpable.

On intra-oral inspection, a diffuse swelling was noticed in the lower right buccal vestibule region measuring 2x2 cms, obliterating the vestibule in the premolar region. (Figure 1B) The overlying mucosa was normal in colour. No visible pulsations were seen. On palpation, all inspectory findings were confirmed regarding size and shape. The borders were well defined; the swelling was firm, fixed to the underlying bone and was tender. The teeth in the region did not show any mobility and were non-tender on percussion. No palpable pulsations were present.

Vitality testing was done using an electric pulp tester, which revealed all the teeth in the fourth quadrant to have normal response. Fine needle aspiration was done, which did not yield any fluid.

Intra oral periapical radiography (IOPAR) with respect to the lower right premolar region, mandibular right lateral occlusal and panoramic radiographs were advised. IOPAR did not reveal any dental pathology, although the mental foramen

Yazışma Adresi/Address for Correspondence: Dr. Jasmine Shanthi Kamath, A. B. Shetty Memorial Institute of Dental Sciences, NITTE University Department of Oral Medicine and Radiology, Nithyananda Nagar, Derlakatte, Mangalore - Karnataka, India. E-mail: jshanthik@gmail.com

Geliş tarihi/Received: 26.02.2017 Kabul tarihi/Accepted: 14.03.2017

appeared to be very prominent. Mandibular lateral occlusal radiograph did not reveal any cortical expansion, perforations or calcified structures. Panoramic radiograph revealed, prominent right mental foramen, measuring about 1 cm in diameter. (Figure 1C, D, E) An excisional biopsy was advised. Cross sectional view of the excised tissue showed encapsulated bundles of nerve tissue with wavy nuclei. Collagen fibres surrounded the nerve tissues. Areas of haemorrhage and extravasated RBC's were seen. All features were suggestive of traumatic neuroma. (Figure F) Patient remained symptom free at one-week post-surgery.

Traumatic neuromas are infrequently seen in the oral cavity with a few cases reported so far. A study done by Jones and Franklin reported the frequency of traumatic neuromas to be only 0.34%³. Cahn in

1939 reported the first traumatic neuroma occurring in the mental foramen. Usual intraoral sites are the mental foramen as was in this case, lower lip and tongue; with some rare reports in the palate^{4,5}. These lesions occur at any age, but are frequently diagnosed in young and middle-aged females. With a female-to-male ratio of 2:1; unlike the case reported here which was seen in an older male. The clinical signs range from a firm nodule with mild pain on palpation of the area to severe neuralgic pain. They can be classified based on the site of occurrence into extra-osseous and intra-osseous varieties⁶⁻⁸. Surgical excision of the neuroma is the treatment of choice. Other second-line therapeutic options reported in literature are stereotactic radiosurgery, steroid injections, sympathetic ganglion block, percussion, and ultrasonic therapy. Spontaneous remission has also been reported⁹.

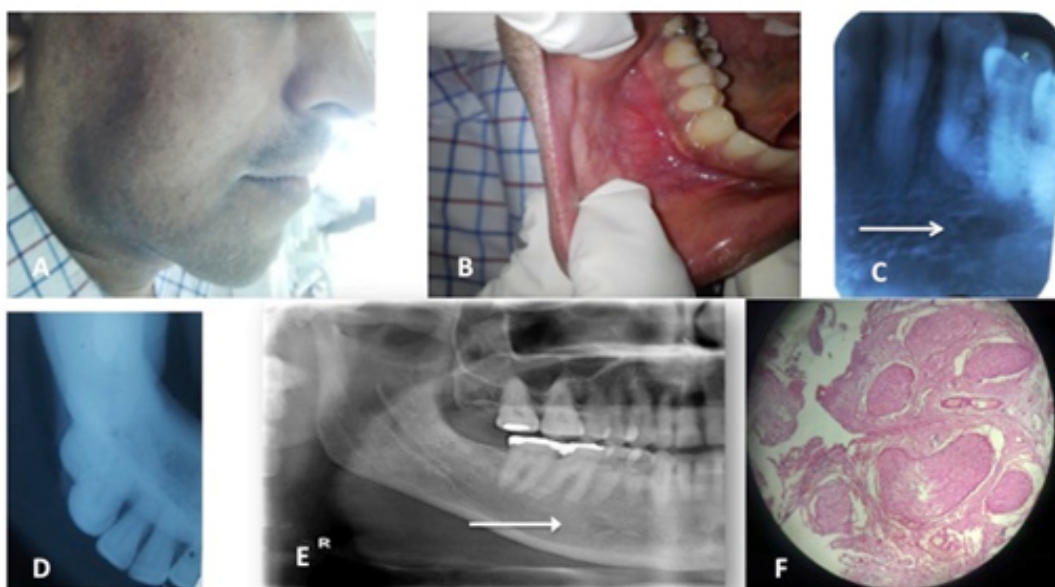


Figure 1A. Extra-oral photograph showing swelling on the right lower third of face

Figure 1B. Intra-oral photograph showing obliteration of the right lower buccal vestibule

Figure 1C. IOPAR showing prominent right mental foramen.

Figure 1D. Cropped panoramic radiograph showing ill defined radiolucency in the right mental foramen

Figure 1E. Mandibular lateral occlusal radiograph showing no pathology,

Figure 1F. Encapsulated bundles of nerve tissue were evident with wavy nuclei

REFERENCES

1. Gregg JM. Studies of traumatic neuralgias in the maxillofacial region: surgical pathology and neural mechanisms. *J Oral Maxillofac Surg.* 1990;48:228-37.
2. Rasmussen OC. Painful traumatic neuromas in the oral cavity. *Oral Surg Oral Med Oral Pathol.* 1980;49:191-5.
3. Jones AV, Franklin CD. An analysis of oral and maxillofacial pathology found in adults over a 30-year period. *J Oral Pathol Med.* 2006;35:392-401.
4. García IA, Galiano AA, Gutiérrez R, José J, Moreno M. Traumatic neuroma of the inferior alveolar nerve: a case report. *Med Oral Pathol Oral Cir Bucal.*

- 2008;13:E186-8.
5. Eguchi T, Ishida R, Ara H, Hamada Y, Kanai I. A diffuse traumatic neuroma in the palate: a case report. *J Med Case Rep.* 2016;10:1-5.
 6. Foltán R, Klíma K, Špačková J, Sedý J. Mechanism of traumatic neuroma development. *Med Hypotheses.* 2008;71:572–6.
 7. Yang J, Wang C, Kao W, Wang Y. Traumatic neuroma of bilateral mental nerve: a case report with literature review. *Taiwan J Oral Maxillofac Surg.* 2010;21:252–60.
 8. Peszkowski MJ, Larsson A. Extraosseous and intraosseous oral traumatic neuromas and their association with tooth extraction. *J Oral Maxillofac Surg.* 1990;48:963-7.
 9. Jham BC, Costa NL, Batista AC, Mendonça EF. Traumatic neuroma of the mandible: a case report with spontaneous remission. *J Clin Exp Dent.* 2014;6:e317-20.