

The Use of Gore-Tex Surgical Membrane in Preventing Spinal Epidural Fibrosis (Experimental Study)

Spinal Epidural Fibrozisin Önlenmesinde Gore-Tex Cerrahi Membranın Yeri (Deneysel Çalışma)

İsmail Ertan SEVIN¹, Selin BOZDAG^{1,2}, Hasan Kamil SUCU¹, Hamdi BEZIRCIOĞLU³

¹Beyin ve Sinir Cerrahisi Kliniği, İzmir Katip Çelebi Üniversitesi, Atatürk Eğitim ve Araştırma Hastanesi, İzmir, Turkey

²Beyin ve Sinir Cerrahisi Kliniği, Kastamonu Eğitim ve Araştırma Hastanesi, Kastamonu, Turkey

³Beyin ve Sinir Cerrahisi Kliniği, İzmir Atatürk Eğitim ve Araştırma Hastanesi, İzmir, Turkey

Öz

Spinal dural defektlerin onarılmasında zaman zaman dura greftlerine ihtiyaç duyulmaktadır. Duraplasti için ideal bir materyal arayışı halen tartışmalı bir konudur. Bu çalışmada Wistar-Albino cinsi, 260-380 gr ağırlığında, 26 adet erişkin erkek sıçanlar kullanılmıştır. Sıçanlar, Kontrol (n=10), Fasya (n=6) ve Gore-Tex (politetrafluoroetilen) Cerrahi Membran (n=10) grupları olmak üzere üç gruba ayrılmıştır. Sıçanlara laminektomi uygulanıp, dura defekti yaratılmış ve daha sonra sırasıyla 'defekt açık bırakılmış', 'fasya ile duraplasti' ve 'Gore-Tex cerrahi membran ile duraplasti' uygulanmıştır. Cerrahi operasyon sonrası 60. günde, sıçanlara ötenazi uygulanmış ve operasyon bölgesinde granülasyon dokusu ve yapışıklıkların değerlendirilmesi amacıyla histopatolojik incelemeler yapılmıştır. Her üç grupta da defekt bölgesini granülasyon dokusunun doldurduğu görülmüştür. Fasya grubunda, fasyanın dura mater ve nöral doku ile granülasyon dokusu arasında bir bariyer teşkil ettiği ancak yoğun granülasyon dokusuyla dolduğu ve yapışıklık olduğu gözlenmiştir. Gore-Tex cerrahi membran grubunda ise Gore-Tex cerrahi membranın dura mater ve nöral doku ile granülasyon dokusu arasında yapışıklığı önleyen iyi bir fiziksel bariyer oluşturduğu, granülasyon dokusunun Gore-Tex cerrahi membrana yapışmadığı bulunmuştur.

Anahtar Kelimeler: Dura Defekti, Duraplasti, Epidural Fibrozis, Gore-Tex

Abstract

Dural grafts are sometimes necessary for repairing spinal dural defects. The search for an ideal material for duraplasty remains a controversial topic. Twenty-six adult male Wistar-Albino rats, weighing 260-380 g, were used. The rats were divided into three groups: Control (n=10), Fascia (n=6), and Gore-Tex (polytetrafluoroethylene) Surgical Membrane group (n=10). After laminectomy was performed on the rats, a dural defect was created. Then, one of the procedures 'leaving the defect open,' 'duraplasty with fascia,' and 'duraplasty with Gore-Tex surgical membrane' was performed. On the 60th day after surgery, the rats were euthanized, and histological investigations were conducted to examine the granulation tissue and adhesions in the operative area. It was observed that granulation tissue filled the defect area in all three groups. In the fascia group, it was observed that the fascia formed a barrier between the dura mater and neural tissue and the granulation tissue, but it was filled with dense granulation tissue and there was adhesion. It was found that the granulation tissue did not adhere to the Gore-Tex surgical membrane in the Gore-Tex surgical membrane group, and the Gore-Tex surgical membrane created an excellent physical barrier preventing adhesion between the dura mater and neural and the granulation tissues.

Keywords: Dural Defect, Duraplasty, Epidural Fibrosis, Gore-Tex

Introduction

Spinal dural defects often occur as a result of spinal dysraphism, Chiari malformation, vascular malformations, and tumor operations. After such operations, complications such as CSF leaks, pseudo meningocele, infection, arachnoiditis, and strain due to adhesions may occur (1). Dural grafts are often needed to repair spinal dural defects after these surgical procedures. The search for an ideal material for duraplasty remains current in clinical and experimental studies.

Autografts obtained from the temporal fascia, cranial periosteum, or fascia lata are popular in the

repair of cranial dural defects (2,3). Gore-Tex (polytetrafluoroethylene) materials are used in various products, such as high-performance fabrics and sealants. Although the medical uses of Gore-Tex are still being actively researched, it is a material that has entered active use in general surgery, plastic surgery, and cardiovascular surgery (4). In neurosurgery, most experimental studies have focused on its beneficial effects in preventing postoperative peridural fibrosis. However, most of these studies were conducted for defects in the cranial dura, and less importance was given to the spinal dura (5,6). To assess the role of Gore-Tex surgical membrane in the repair of spinal dural defects and compare it to autologous fascia graft, a spinal dural defect was surgically generated in rats, and the effects of this material were studied histopathologically in this study.

Material and Method

26 Wistar-Albino adult male rats (260-380 g) were utilized in this study. The Animal Experiments Local Ethics Committee obtained the necessary approval for the study. The rats were allocated into

	ORCID No
İsmail Ertan SEVIN	0000-0002-6542-925X
Selin BOZDAG	0000-0002-3355-8954
Hasan Kamil SUCU	0000-0002-2795-9049
Hamdi BEZIRCIOĞLU	0009-0008-1115-030X

Başvuru Tarihi / Received: 04.11.2023
Kabul Tarihi / Accepted : 08.02.2024

Adres / Correspondence : Selin BOZDAG
İzmir Atatürk Eğitim ve Araştırma Hastanesi Beyin ve Sinir Cerrahisi Kliniği, Basın Sitesi, Karabağlar/İzmir
e-posta / e-mail : selin.bzdg@gmail.com

three distinct groups: the control group, the Gore-Tex Surgical Membrane group, and the fascia group. The study started with ten animals each for the control, fascia and Gore-Tex groups, with the idea that this would be sufficient for statistical evaluation. However, four animals in the fascia group died and the study continued without replacement. Therefore, the study was completed with six animals in the fascia group, while there were ten animals in the other groups.

Anesthesia was induced by administering a mixture of ketamine hydrochloride and xylazine (5/10 mg/kg, intramuscularly) to the rats. The rats were allowed to breathe spontaneously throughout the operation.

Operation technique

Rats were fixed on the dissection table in the prone position. Then, the area from the mid-lower thoracic region to the sacrum was shaved. The operation area was cleaned with 10% povidone-iodine solution, and a midline 4 cm skin incision was made. Fascia was cut bilaterally, and paravertebral muscles were stripped subperiosteally. A single-level lumbar total laminectomy was performed, and a dural defect was created at that distance (using loop glasses).

In the control group, the dural defect was left open. In the fascia group, a 1 cm autologous fascia graft was taken from the lumbar region and sutured to the defective area with 5/0 silk. In the Gore-Tex surgical membrane group, a 1 cm Gore-Tex Surgical Membrane was fixed with 5/0 silk, and dural repair was performed. Then, the layers were closed following the anatomy, and the operation was terminated. After the intervention, 400000 IU procaine penicillin was given to all rats for prophylactic purposes for five days.

Until the experiment's two-month duration, the rats were monitored in groups of 2 in standard cages, with ad-libitum feeding and daily wound care. At the end of the experiment, the rats were sacrificed by giving carbon dioxide euthanasia within a chamber.

Histopathological examinations

The thoracolumbar spine region was taken en bloc and fixed in 10% buffered formalin. It was then decalcified in 20% formic acid for three days. After decalcification, 2 mm thick samples were taken, and paraffin blocks were prepared. Sections of paraffin blocks were stained with hematoxylin-Eosin and histopathologically examined. To microscopically evaluate the adhesion to the dura mater, three levels of scoring were made, similar to the scoring of He et al. (7),

Grade 0 = when the dura mater was free of the scar tissue.

Grade 1 = when only thin fibrous band(s) between the scar tissue and dura mater were observed.

Grade 2 = when continuous adherence was observed but was less than two thirds of the laminectomy defect.

Grade 3 = when scar tissue adherence was large, more than two thirds of the laminectomy defect, and/or extended to the nerve roots.

Statistical analysis

The Shapiro-Wilk test was used to determine whether the data showed normal distribution. A comparative analysis among three groups was conducted utilizing the Kruskal-Wallis test. The Dunn-Bonferroni test was used as a post hoc test. According to the post-power analysis, the effect size for the adhesion difference between the groups was obtained as partial $\eta^2 = 0.291$ and statistical power = 0.732, with a type 1 error of 0.05. IBM SPSS Version 22 program was used for statistical tests.

Results

After laminectomy, dense connective tissue with fibroblasts was determined to fill the operation region in the control group. It was observed that the dura was thickened and completely adhered to the granulation tissue in the posterior (Figure 1). In the fascia group, in the histopathological examination of the levels where the fascia autograft was placed, it is seen that the dura is thickened, the operation area is again filled with dense granulation tissue, the fascia forms a barrier between the dura mater and the granulation tissue, but the fascia shows adhesion with the dura mater (Figure 2). In the Gore-Tex group, granulation tissue covered the laminectomy defect area with the Gore-Tex surgical membrane. Still, there was no adhesion to the Gore-Tex surgical membrane. In this region, it is observed that the Gore-Tex surgical membrane creates a mechanical barrier between the dura mater, neural tissue, and granulation tissue (Figure 3). Descriptive statistics of the groups are shown in Table-1.

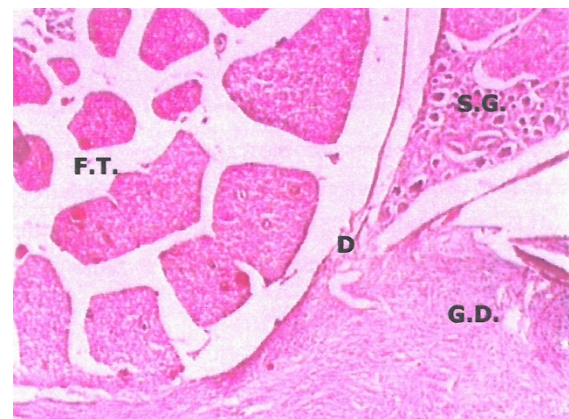

Figure 1. Findings of adhesion of granulation tissue with the dura mater and neural tissue in the laminectomy area. G.D., granulation tissue; D, dura mater; F.T., filum terminale; S.G., sympathetic ganglion. (HE x 44).

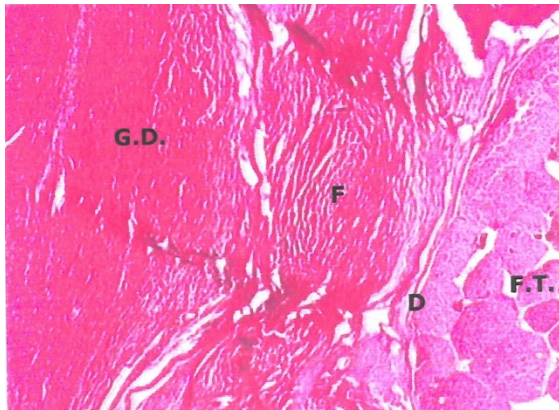


Figure 2. It is seen that fascia forms a barrier between the dura mater and neural tissue and granulation tissue but cannot prevent adhesion. G.D., granulation tissue; D,dura mater; F.T., filum terminale; F, Fascia. (HE x 27.5).

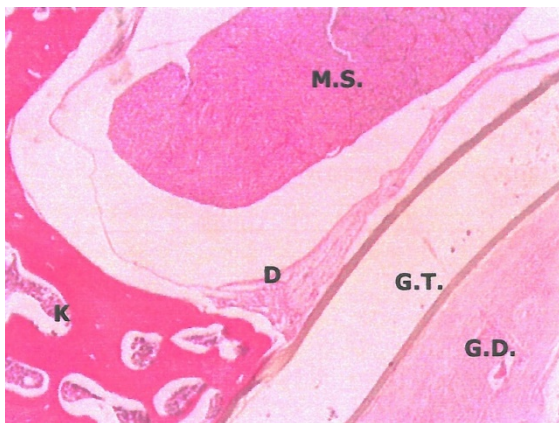

Figure 3. Although the dura mater thickens where the Gore-Tex Surgical Membrane is applied, no adhesion is observed. K, bone; G.D., granulation tissue; D, dura mater; M.S., medulla spinalis; G. T., Gore-Tex Surgical Membrane. (HE x 27.5).

The data did not show a normal distribution ($p=0.022$, the Shapiro-Wilk test). Then, it was understood that the three groups were different ($p=0.028$, the Kruskal Wallis test). Gore-Tex group was found better than both the control and the fascia group. The details of pairwise comparison results between the groups are shown in Table-2.

Discussion

After laminectomy, fibroblasts originating from the deep surfaces of the paravertebral muscles migrate to the laminectomy area and replace the epidural hematoma found there, causing dense scar tissue to form (8,9). Ligamentum flavum, posterior longitudinal ligament, bone, and annulus fibrosus are known as the sources of fibroblasts. Factors that stimulate the chemotaxis and migration of fibroblasts include blood products resulting from the breakdown of red blood cells (10,11).

Dural grafts are needed for dural defects occurring after spinal dysraphism, Chiari malformation, vascular malformations, tumor operations, and other surgical procedures (3,5,6,12). Among the many materials used to prevent the formation of epidural granulation tissue and dural adhesions, the most accepted ones are those that create physical barriers (6,8,10,13,14). Researchers LaRocca and Macnab placed Gelfoam and a silastic sheath between the dura and muscles to prevent the formation of peridural granulation tissue after laminectomy (8). Yong-Hing et al. (13) and Chen et al. (14) investigated the effectiveness of applying Gelfoam and free fat grafts to the laminectomy area. These studies found that Gelfoam breaks down by creating a foreign body reaction and has no effect on epidural granulation tissue and adhesions to the dura.

Table 1. Summary of parameters in each group.

	Control Group	Groups Fascia Group	Gore-Tex Group	Test value	Test Statistics		
					<i>p</i>	partial η^2	Power
Number of Animals	10	6	10				
Adhesion scores to the dura mater							
Mean \pm SD	2.0 \pm 0.7 ^a	2.0 \pm 0.0 ^a	1.2 \pm 0.8 ^b	7.138 [†]	0.028	0.291	0.732
95.0% Confidence interval	(1.5-2.5)	(2.0-2.0)	(0.6-1.7)				
Median	2	2	1				
Min; Max	1; 3	2; 2	0; 2				

Data are given as mean \pm standard deviation (95.0% Confidence interval) and median (min; max). [†]: Kruskal-Wallis H test, a and b superscripts indicate differences between groups. There are no statistically differences between groups with the same superscripts. The *p* values of the Dunn-Bonferroni post hoc test comparing adhesion scores between groups: Control Group vs Fascia Group $p=1.000$, Control Group vs Gore-Tex Group $p=0.031$, Fascia Group vs Gore-Tex Group $p=0.019$.

Table 2. The *p* values of the Dunn-Bonferroni post hoc test comparing adhesion scores between groups.

	Control Group	Fascia Group	Gore-Tex Group
Control Group	NA	1.000	0.031
Fascia Group	1.000	NA	0.019
Gore-Tex Group	0.031	0.019	NA

*Purple: NA; Green: All *p* values <0.05 ; Blue: All *p* values >0.05

Another dural graft material is lyophilized dura taken from human cadavers. It is used in the repair of spinal dural defects and meningomyeloceles. However, it has the disadvantage of carrying infectious diseases. Jakob-Creutzfeld (JCD) cases transmitted via lyophilized human dura mater have been reported (15-19).

It has been suggested that steroids inhibit fibroblast proliferation and mucopolysaccharide

protein synthesis. Based on this idea, steroidal materials and direct depot steroids have been applied to the laminectomy area experimentally and clinically, and it has been reported that adhesion is less in the areas where steroids are used (13,14).

Among the dural graft materials, autogenic fat grafts have the best results in repairing spinal dural defects and are very useful in preventing granulation tissue formation after lumbar laminectomy (3). Nevertheless, alternative graft materials become necessary when the donor areas are afflicted or compromised by disease, the person refuses graft removal for cosmetic reasons, or in traumatic and emergency cases where additional time cannot be spent for autogenous graft harvesting (12,20).

Another material is the Gore-Tex surgical membrane. Developed in 1969 and trademarked by W.L. Gore & Associates, Gore-Tex is a fabric membrane renowned for its exceptional waterproofing capabilities. It consists of expanded polytetrafluoroethylene (PTFE). It is a soft, synthetic, biologically inert, non-absorbable material that can be easily shaped and sutured (10). Its less porous and densely intertwined fibrous structure suppresses cell proliferation and creates minimal adhesion. It is used for various purposes, such as preventing tissue adhesion in cardiovascular surgery (21,22). Vakis et al., in their case series in 2006, stated that the Gore-Tex surgical membrane helps prevent adhesions after decompressive craniectomies (5). In their study on pediatric Chiari malformation patients 2008, Attenello et al. found the Gore-Tex surgical membrane superior to the pericranial autograft (6). In a study by Park et al., the Gore-Tex surgical membrane was compared with collagen-coated vicryl mesh and lyophilized spinal dural allograft material. It was more beneficial than these two materials in preventing arachnoidal adhesions and inflammation after spinal dural repair (1). Again, it was recommended in this study to do experimental trials comparing the Gore-Tex surgical membrane to autologous fascia.

Many studies have used dural materials for cranial dural repair (3,5,6,12,23), and there has been very little experimental research on spinal duraplasty. (4,10,24,25). In this study, we aimed to prevent the granulation tissue from coming to the epidural space and the resulting granulation tissue from adhering to the dura mater and nerve roots by placing a physical barrier between the granulation tissue and the dura mater, and we compared the effects of autologous fascia taken from the lumbar region and Gore-Tex surgical membrane. Based on the results obtained, it was observed that the fascia formed a physical barrier between the dura mater and neural tissue and the granulation tissue, whereas the granulation tissue adhered to the fascia. These findings make us think it will create difficulties in cases requiring reoperation. However, the Gore-Tex surgical membrane could interrupt the contiguity

between the granulation tissue, the dura mater, and the neural tissue. It has been observed that even if epidural granulation tissue forms, no adhesion to the Gore-Tex surgical membrane occurs, and therefore, it is superior to autologous fascia. These findings are consistent with Kurt et al. in 2009 and Topsakal et al. in 2004 (4,25).

Conclusion

This study showed that the granulation tissue did not adhere to the Gore-Tex surgical membrane, and the Gore-Tex surgical membrane created an excellent physical barrier preventing adhesion between the dura mater and neural and granulation tissues. The biologically inert nature of the Gore-Tex surgical membrane, its compatibility with the body, appropriate placement on the dural defect, and an ease of suturing can be considered surgical advantages.

Acknowledgements

We would like to thank dear Dr. Mine Tunakan, who made significant contributions to the preparation of this study.

Conflict of interest statement

The author declares that the research was conducted in the absence of any commercial or financial relationships that could be construed as a potential conflict of interest.

Ethics Committee Approval: The Ege University Animal Experiments Local Ethics Committee granted the necessary approval for the study (dated 12.03.2002 and numbered 2002.08).

Funding: The study did not receive any financial support.

References

1. Park YK, Tator CH. Prevention of arachnoiditis and postoperative tethering of the spinal cord with Gore-Tex surgical membrane: an experimental study with rats. *Neurosurgery*. 1998;42(4):813-23; discussion 23-4.
2. Thammavaram KV, Benzel EC, Kesterson L. Fascia lata graft as a dural substitute in neurosurgery. *South Med J*. 1990;83(6):634-6.
3. Keller JT, Ongkiko CM Jr, Saunders MC, et al. Repair of spinal dural defects. An experimental study. *J Neurosurg*. 1984;60(5):1022-8.
4. Kurt G, Cemil B, Celik B, et al. Comparison of Oxiplex and Gore-Tex effectivity in an experimental peridural fibrosis model. *Neurocirugia (Astur)*. 2009;20(4):360-6.
5. Vakis A, Koutentakis D, Karabetsos D, et al. Use of polytetrafluoroethylene dural substitute as adhesion preventive material during craniectomies. *Clin Neurol Neurosurg*. 2006;108(8):798-802.
6. Attenello FJ, McGirt MJ, Garcés-Ambrossi GL, et al. Suboccipital decompression for Chiari I malformation: outcome comparison of duraplasty with expanded

- polytetrafluoroethylene dural substitute versus pericranial autograft. *Childs Nerv Syst.* 2009;25(2):183-90.
7. He Y, Revel M, Loty B. A quantitative model of post-laminectomy scar formation. Effects of a nonsteroidal anti-inflammatory drug. *Spine (Phila Pa 1976).* 1995;20(5):557-63; discussion 79-80.
 8. LaRocca H, Macnab I. The laminectomy membrane. Studies in its evolution, characteristics, effects, and prophylaxis in dogs. *J Bone Joint Surg Br.* 1974;56b(3):545-50.
 9. Özgül Önal M, Yiğittürk Y, Elbe H, et al. Leptinin yara iyileşmesi üzerine in vitro etkisinin büyüme faktörleri üzerinden incelenmesi. *Muğla Sıtkı Koçman Üni Tıp Derg.* 2023;10(1):19-28.
 10. Kocabaş M, Alparslan Ş, Çokluk C, et al. Tavşanlarda laminektomi sonrası yapışıklığın önlenmesinde Gore-Tex cerrahi membran kullanılması. *Türk Nöro Derg.* 1999;9(1):42-6.
 11. Robertson JT, Meric AL, Dohan FC, et al. The reduction of postlaminectomy peridural fibrosis in rabbits by a carbohydrate polymer. *J Neurosurg.* 1993;79(1):89-95.
 12. Maurer PK and McDonald JV. Vicryl (polyglactin 910) mesh as a dural substitute. *J Neurosurg.* 1985;63(3):448-52.
 13. Yong-Hing K, Reilly J, de Korompay V, et al. Prevention of nerve root adhesions after laminectomy. *Spine (Phila Pa 1976).* 1980;5(1):59-64.
 14. Chen PQ, Yang CY, Su CJ, et al. Prevention of postlaminectomy membrane: experimental and clinical observations. *Taiwan Yi Xue Hui Za Zhi.* 1989;88(1):57-61.
 15. Esmonde T, Lueck CJ, Symon L, et al. Creutzfeldt-Jakob disease and lyophilised dura mater grafts: report of two cases. *J Neurol Neurosurg Psychiatry.* 1993;56(9):999-1000.
 16. Masullo C, Pocchiari M, Macchi G, et al. Transmission of Creutzfeldt-Jakob disease by dural cadaveric graft. *J Neurosurg.* 1989;71(6):954-5.
 17. Leads from the MMWR. Creutzfeldt-Jakob disease in a second patient who received a cadaveric dura mater graft. *Jama.* 1989;261(8):1118.
 18. Pritchard J. TV, Kalb R. Rapidly progressive dementia in a patient who received a cadaveric dura mater graft. *MMWR Morb Mortal Wkly Rep.* 1987;36(4):49-50,55.
 19. Thadani V, Penar PL, Partington J, et al. Creutzfeldt-Jakob disease is probably acquired from a cadaveric dura mater graft. Case report. *J Neurosurg.* 1988;69(5):766-9.
 20. Nordstrom MR, Wang TD, Neel HB. Dura mater for soft-tissue augmentation. Evaluation in a rabbit model. *Arch Otolaryngol Head Neck Surg.* 1993;119(2):208-14.
 21. Harada Y, Imai Y, Kurosawa H, et al. Long-term results of the clinical use of an expanded polytetrafluoroethylene surgical membrane as a pericardial substitute. *J Thorac Cardiovasc Surg.* 1988;96(5):811-5.
 22. Minale C, Nikol S, Hollweg G, et al. Clinical experience with expanded polytetrafluoroethylene Gore-Tex surgical membrane for pericardial closure: a study of 110 cases. *J Card Surg.* 1988;3(3):193-201.
 23. Takci E, Kadioglu HH, Bahceci H, et al. Deneysel kranial dural defektlerin onarımında dehidrate human dura mater greftlerinin kullanımı histopatolojik değerlendirme. *Türk Nöro Derg.* 2001;11(3):178-84.
 24. Ozveren MF, Turkmen CS, Tanik C, et al. Experimental use of polytetrafluoroethylene graft for prevention of peridural fibrosis in dogs. *Türk Nöro Derg.* 1999;9(2):25-33.
 25. Topsakal C, Akpolat N, Erol FS, et al. Seprafilm is superior to Gore-Tex in the prevention of peridural fibrosis. *J Neurosurg.* 2004;101(2):295-302.